

FIRST AID™

CASES

for the

USMLE STEP 2 CK

SECOND EDITION

- 344 high-yield cases teach you how to work through questions on the exam •
- Active-recall questions and answers reinforce key concepts •
- Organized the same as *First Aid for the USMLE Step 2 CK* for parallel study •
- Completely updated based on student feedback •

TAO LE • ELIZABETH EBY HALVORSON

FIRST AID™

CASES FOR THE USMLE STEP 2 CK

Second Edition

TAO LE, MD, MHS

Assistant Clinical Professor of Pediatrics and Medicine
Division of Allergy and Clinical Immunology
Department of Pediatrics
University of Louisville

ELIZABETH EBY HALVORSON, MD

Vanderbilt School of Medicine
Class of 2009
Resident
Department of Pediatrics
Wake Forest University Baptist Medical Center



Medical

New York / Chicago / San Francisco / Lisbon / London / Madrid / Mexico City
Milan / New Delhi / San Juan / Seoul / Singapore / Sydney / Toronto

Copyright © 2010, 2007 by Tao Le. All rights reserved. Except as permitted under the United States Copyright Act of 1976, no part of this publication may be reproduced or distributed in any form or by any means, or stored in a database or retrieval system, without the prior written permission of the publisher.

ISBN: 978-0-07-162926-3

MHID: 0-07-162926-2

The material in this eBook also appears in the print version of this title: ISBN: 978-0-07-162570-8, MHID: 0-07-162570-4.

All trademarks are trademarks of their respective owners. Rather than put a trademark symbol after every occurrence of a trademarked name, we use names in an editorial fashion only, and to the benefit of the trademark owner, with no intention of infringement of the trademark. Where such designations appear in this book, they have been printed with initial caps.

McGraw-Hill eBooks are available at special quantity discounts to use as premiums and sales promotions, or for use in corporate training programs. To contact a representative please e-mail us at bulksales@mcgraw-hill.com.

Medicine is an ever-changing science. As new research and clinical experience broaden our knowledge, changes in treatment and drug therapy are required. The authors and the publisher of this work have checked with sources believed to be reliable in their efforts to provide information that is complete and generally in accord with the standards accepted at the time of publication. However, in view of the possibility of human error or changes in medical sciences, neither the authors nor the publisher nor any other party who has been involved in the preparation or publication of this work warrants that the information contained herein is in every respect accurate or complete, and they disclaim all responsibility for any errors or omissions or for the results obtained from use of the information contained in this work. Readers are encouraged to conform the information contained herein with other sources. For example and in particular, readers are advised to check the product information sheet included in the package of each drug they plan to administer to be certain that the information contained in this work is accurate and that changes have not been made in the recommended dose or in the contraindications for administration. This recommendation is of particular importance in connection with new or infrequently used drugs.

TERMS OF USE

This is a copyrighted work and The McGraw-Hill Companies, Inc. ("McGraw-Hill") and its licensors reserve all rights in and to the work. Use of this work is subject to these terms. Except as permitted under the Copyright Act of 1976 and the right to store and retrieve one copy of the work, you may not decompile, disassemble, reverse engineer, reproduce, modify, create derivative works based upon, transmit, distribute, disseminate, sell, publish or sublicense the work or any part of it without McGraw-Hill's prior consent. You may use the work for your own noncommercial and personal use; any other use of the work is strictly prohibited. Your right to use the work may be terminated if you fail to comply with these terms.

THE WORK IS PROVIDED "AS IS." MCGRAW-HILL AND ITS LICENSORS MAKE NO GUARANTEES OR WARRANTIES AS TO THE ACCURACY, ADEQUACY OR COMPLETENESS OF OR RESULTS TO BE OBTAINED FROM USING THE WORK, INCLUDING ANY INFORMATION THAT CAN BE ACCESSED THROUGH THE WORK VIA HYPERLINK OR OTHERWISE, AND EXPRESSLY DISCLAIM ANY WARRANTY, EXPRESS OR IMPLIED, INCLUDING BUT NOT LIMITED TO IMPLIED WARRANTIES OF MERCHANTABILITY OR FITNESS FOR A PARTICULAR PURPOSE. McGraw-Hill and its licensors do not warrant or guarantee that the functions contained in the work will meet your requirements or that its operation will be uninterrupted or error free. Neither McGraw-Hill nor its licensors shall be liable to you or anyone else for any inaccuracy, error or omission, regardless of cause, in the work or for any damages resulting therefrom. McGraw-Hill has no responsibility for the content of any information accessed through the work. Under no circumstances shall McGraw-Hill and/or its licensors be liable for any indirect, incidental, special, punitive, consequential or similar damages that result from the use of or inability to use the work, even if any of them has been advised of the possibility of such damages. This limitation of liability shall apply to any claim or cause whatsoever whether such claim or cause arises in contract, tort or otherwise.

DEDICATION

To the contributors to this and future editions, who took time to share their knowledge, insight, and humor for the benefit of all those who yearn to pass their boards.

and

To our families, friends, and loved ones, who encouraged and assisted us in the task of assembling this guide.

This page intentionally left blank

CONTENTS

Contributing Authors	xv
Senior Reviewers	xvii
Preface	xix
Acknowledgments	xxi
How to Contribute	xxiii
Cardiology	1
Case 1: Abdominal Aortic Aneurysm	2
Case 2: Acute Cardiogenic Pulmonary Edema	3
Case 3: Acute Coronary Syndrome	4
Case 4: Aortic Dissection	6
Case 5: Acute Myocardial Infarction—Long-Term Management	8
Case 6: Aortic Regurgitation	9
Case 7: Atrial Fibrillation	10
Case 8: Cardiac Tamponade	12
Case 9: Congestive Heart Failure	14
Case 10: Deep Venous Thrombosis	16
Case 11: Dilated Cardiomyopathy (Alcoholic)	18
Case 12: Diastolic Heart Failure	20
Case 13: Aortic Stenosis	21
Case 14: Hypercholesterolemia	22
Case 15: Hypertension—Essential	23
Case 16: Hypertension—Renal Artery Stenosis	24
Case 17: Hypertrophic Obstructive Cardiomyopathy	26
Case 18: Infective Endocarditis	28
Case 19: Myocardial Infarction	30
Case 20: Papillary Muscle Rupture	32
Case 21: Pericarditis	34
Case 22: Peripheral Vascular Disease	36
Case 23: Mitral Regurgitation	37
Case 24: Second-Degree Heart Block	38
Case 25: Wolff-Parkinson-White Syndrome	40
Dermatology	43
Case 1: Acanthosis Nigricans	44
Case 2: Acne Vulgaris	46
Case 3: Atopic Dermatitis	47

Case 4: Basal Cell Carcinoma	48
Case 5: Bullous Pemphigoid	50
Case 6: Herpes Simplex	51
Case 7: Hidradenitis Suppurativa	52
Case 8: Kaposi Sarcoma	53
Case 9: Lichen Planus	54
Case 10: Molluscum Contagiosum	56
Case 11: Pemphigus	58
Case 12: Pityriasis Rosea	60
Case 13: Psoriasis	62
Case 14: Stevens-Johnson Syndrome	64
Case 15: Varicella-Zoster Virus	66
Case 16: Tuberous Sclerosis	68
Case 17: Onychomycosis	69
Case 18: Melanoma	70
Endocrinology	71
Case 1: Acromegaly	72
Case 2: Cushing's Syndrome	74
Case 3: Adrenal Insufficiency (Addison's Disease)	76
Case 4: Diabetes Insipidus	77
Case 5: Diabetes Mellitus, Type 1	78
Case 6: Diabetic Ketoacidosis	79
Case 7: Hyperthyroidism (Graves' Disease)	80
Case 8: Hypokalemia (Hyperaldosteronism)	82
Case 9: Hyperparathyroidism	84
Case 10: Hypothyroidism (Hashimoto's Thyroiditis)	85
Case 11: Multiple Endocrine Neoplasia, Type I	86
Case 12: Metabolic Syndrome	88
Case 13: Multiple Endocrine Neoplasia, Type II	89
Case 14: Osteoporosis	90
Case 15: Paget's Disease of Bone	92
Case 16: Pheochromocytoma	94
Case 17: Syndrome of Inappropriate Antidiuretic Hormone Secretion	96
Case 18: Thyroid Nodule	98
Case 19: Subacute Granulomatous Thyroiditis (de Quervain's Thyroiditis)	100
Epidemiology and Preventive Medicine	101
Case 1: Bias and Confounding	102
Case 2: Bioterrorism	104
Case 3: Breast Cancer Screening	106
Case 4: Cohort Studies	108
Case 5: Health Care Screening	109
Case 6: Incidence and Prevalence	110
Case 7: Influenza Vaccine	112

Case 8: Obesity Effects on Health	114
Case 9: Randomized Clinical Trial	116
Case 10: Sensitivity and Specificity	118
Case 11: Reliability and Validity	120
Case 12: Positive Predictive Value, and Negative Predictive Value	121
Ethics and Legal Issues	123
Case 1: Confidentiality and Disclosure	124
Case 2: End-of-Life Issues (Advance Directives and Withdrawal of Care)	125
Case 3: Informed Consent	126
Case 4: Minors	127
Gastrointestinal	129
Case 1: Acute Cholecystitis	130
Case 2: Acute Pancreatitis	132
Case 3: Achalasia	134
Case 4: Carcinoid	135
Case 5: Colorectal Cancer	136
Case 6: Celiac Disease	138
Case 7: Diverticulitis	139
Case 8: Esophageal Carcinoma	140
Case 9: Gastroesophageal Reflux Disease	141
Case 10: Hemochromatosis	142
Case 11: Hiatal Hernia	144
Case 12: Inflammatory Bowel Disease	146
Case 13: Liver Cirrhosis	148
Case 14: Irritable Bowel Syndrome	150
Case 15: Peptic Ulcer Disease	151
Case 16: Primary Sclerosing Cholangitis	152
Case 17: Pseudomembranous Colitis	153
Case 18: Small Bowel Obstruction	154
Case 19: Spontaneous Bacterial Peritonitis	156
Case 20: Viral Hepatitis	157
Case 21: Wilson's Disease	160
Case 22: Zollinger-Ellison Syndrome	162
Hematology/Oncology	163
Case 1: Acute Myelogenous Leukemia	164
Case 2: Acute Lymphoblastic Leukemia	166
Case 3: Amyloidosis	167
Case 4: Chronic Lymphocytic Leukemia	168
Case 5: Factor V Leiden	170
Case 6: Fanconi's Anemia	171
Case 7: Glucose-6-Phosphate Dehydrogenase Deficiency	172
Case 8: Hairy Cell Leukemia	174

Case 9: Hemophilia	175
Case 10: Hodgkin's Lymphoma	176
Case 11: Microcytic Anemia	178
Case 12: Multiple Myeloma	180
Case 13: Idiopathic Thrombocytopenic Purpura	182
Case 14: Neutropenia	183
Case 15: Polycythemia	184
Case 16: Sickle Cell Anemia	186
Case 17: α -Thalassemia	188
Case 18: Hemorrhage, Drug-Induced	190
Case 19: Thrombotic Thrombocytopenic Purpura with Hemolytic Uremic Syndrome	191
Case 20: Porphyria	192
Case 21: Transplant Rejection	193
Case 22: von Willebrand's Disease	194
Infectious Disease	195
Case 1: AZT-Induced Anemia	196
Case 2: Chlamydia	197
Case 3: Gonococcal Infection	198
Case 4: Histoplasmosis	200
Case 5: Infectious Mononucleosis	201
Case 6: Lyme Disease	202
Case 7: Malaria	204
Case 8: Methicillin-Resistant <i>Staphylococcus aureus</i>	206
Case 9: Necrotizing Fasciitis	208
Case 10: Neutropenic Fever	209
Case 11: Osteomyelitis	210
Case 12: Pneumocystosis	212
Case 13: Endocarditis	214
Case 14: Rocky Mountain Spotted Fever	215
Case 15: Septic Arthritis	216
Case 16: Thrombophlebitis	217
Case 17: Urinary Tract Infection	218
Musculoskeletal and Connective Tissue	219
Case 1: Ankylosing Spondylitis	220
Case 2: Carpal Tunnel Syndrome	222
Case 3: Compartment Syndrome	223
Case 4: Dermatomyositis	224
Case 5: Duchenne Muscular Dystrophy	225
Case 6: Herniated Lumbar Disk	226
Case 7: Gout	228
Case 8: Fibromyalgia	229
Case 9: Juvenile Rheumatic Arthritis	230
Case 10: Legg-Calvé-Perthes Disease	231

Case 11: Osteosarcoma	232
Case 12: Rheumatoid Arthritis	234
Case 13: Scleroderma	236
Case 14: Spinal Stenosis	238
Case 15: Systemic Lupus Erythematosus	240
Case 16: Slipped Capital Femoral Epiphysis	242
Case 17: Osteoarthritis	244
Case 18: Takayasu Arteritis	245
Case 19: Temporal Arteritis	246
Case 20: Polymyalgia Rheumatica	247
Neurology	249
Case 1: Amyotrophic Lateral Sclerosis	250
Case 2: Dementia	252
Case 3: Epidural Abscess	254
Case 4: Epidural Hematoma	256
Case 5: Glaucoma	258
Case 6: Glioblastoma Multiforme	260
Case 7: Guillain-Barré Syndrome	262
Case 8: Headache	264
Case 9: Huntington's Disease	266
Case 10: Infantile Spasms	267
Case 11: Internuclear Ophthalmoplegia	268
Case 12: Benign Positional Paroxysmal Vertigo	269
Case 13: Meningitis	270
Case 14: Multiple Sclerosis	272
Case 15: Myasthenia Gravis	275
Case 16: Partial Complex Seizures	276
Case 17: Stroke	278
Case 18: Parkinson's Disease	281
Case 19: Subacute Combined Degeneration	282
Case 20: Subarachnoid Hemorrhage	284
Case 21: Subdural Hematoma	286
Case 22: Tonic-Clonic Seizures	288
Case 23: Tabes Dorsalis	290
Obstetrics	291
Case 1: Abortion	292
Case 2: Contraception	293
Case 3: Deep Venous Thrombosis	294
Case 4: Disseminated Intravascular Coagulation	295
Case 5: Ectopic Pregnancy	296
Case 6: Fetal Monitoring	298
Case 7: Gestational Diabetes	300
Case 8: Hydatidiform Mole	302

Case 9: Hypertension	303
Case 10: Infertility	304
Case 11: Isoimmunization	305
Case 12: Mastitis	306
Case 13: Normal Labor	307
Case 14: Normal Physiology of Pregnancy	308
Case 15: Nutrition in Pregnancy	309
Case 16: Placental Abruption	310
Case 17: Perineal Laceration	312
Case 18: Placenta Previa	313
Case 19: Postpartum Infection	314
Case 20: Postpartum Hemorrhage	316
Case 21: Preeclampsia	317
Case 22: Postterm Pregnancy	318
Case 23: Prenatal Screening	320
Case 24: Preterm Labor	321
Case 25: Preterm Premature Rupture of Membranes	322
Case 26: Pyelonephritis	323
Case 27: TORCH Infections	324
Case 28: Sheehan's Syndrome	326
Gynecology	327
Case 1: Amenorrhea, Primary	328
Case 2: Amenorrhea, Secondary	330
Case 3: Breast Cancer	331
Case 4: Bacterial Vaginosis	332
Case 5: Cervical Cancer	334
Case 6: Chancroid	336
Case 7: Fibrocystic Breast Disease	338
Case 8: Endometriosis	340
Case 9: Fibroids	342
Case 10: Genital Warts	344
Case 11: Menopause	345
Case 12: Ovarian Cancer	346
Case 13: Cervicitis	347
Case 14: Pelvic Inflammatory Disease	348
Case 15: Polycystic Ovarian Syndrome	350
Case 16: Postmenopausal Bleeding	351
Case 17: Primary Syphilis	352
Case 18: Toxic Shock Syndrome	353
Case 19: Trichomonas	354
Case 20: Urinary Incontinence	356
Case 21: Vulvovaginal Candidiasis	357

Pediatrics	359
Case 1: Abuse	360
Case 2: Chronic Granulomatous Disease	362
Case 3: Congenital Adrenal Hyperplasia	364
Case 4: Congenital Infections	365
Case 5: Crohn's Disease	366
Case 6: Developmental Dysplasia of the Hip	368
Case 7: Croup	370
Case 8: Developmental Milestones	371
Case 9: Down Syndrome	372
Case 10: Duodenal Atresia	374
Case 11: Failure to Thrive	376
Case 12: Febrile Seizure	377
Case 13: Henoch-Schönlein Purpura	378
Case 14: Hirschsprung Disease	380
Case 15: Intussusception	382
Case 16: Kawasaki Disease	384
Case 17: Meningitis	385
Case 18: Necrotizing Enterocolitis	386
Case 19: Omphalocele	387
Case 20: Otitis Media	388
Case 21: Physiologic Jaundice	389
Case 22: Pyloric Stenosis	390
Case 23: Respiratory Distress in the Newborn	391
Case 24: Respiratory Syncytial Virus Infection	392
Case 25: Tay-Sachs Disease	393
Case 26: Tetralogy of Fallot	394
Case 27: Varicella	396
Case 28: Ventricular Septal Defect	398
Case 29: Wilms' Tumor	399
Psychiatry	401
Case 1: Amphetamine Intoxication	402
Case 2: Alcoholism	404
Case 3: Anorexia Nervosa	405
Case 4: Attention-Deficit/Hyperactivity Disorder	406
Case 5: Autism	407
Case 6: Bulimia	408
Case 7: Cocaine Dependence	410
Case 8: Conduct Disorder	412
Case 9: Delirium	413
Case 10: Dissociative Fugue	414
Case 11: Domestic Violence	415
Case 12: Factitious Disorder	416
Case 13: Generalized Anxiety Disorder	417

Case 14: Major Depression	418
Case 15: Personality Disorder, Cluster A	420
Case 16: Opioid Withdrawal	422
Case 17: Bipolar I Disorder	423
Case 18: Personality Disorder, Cluster B	424
Case 19: Personality Disorder, Cluster C	425
Case 20: Schizophrenia	426
Case 21: Posttraumatic Stress Disorder	428
Case 22: Somatization Disorder	429
Case 23: Tourette’s Syndrome	430
Case 24: Suicidal Ideation	432
Pulmonary	433
Case 1: Acute Respiratory Distress Syndrome	434
Case 2: Acute Respiratory Failure	436
Case 3: Asthma	438
Case 4: Atypical Pneumonia	440
Case 5: Chronic Obstructive Pulmonary Disease	441
Case 6: Emphysema	442
Case 7: Lung Cancer	443
Case 8: Idiopathic Pulmonary Fibrosis	444
Case 9: Mesothelioma	446
Case 10: Pulmonary Embolus	447
Case 11: Pleural Effusion	448
Case 12: Pneumothorax	450
Case 13: Pulmonary Hypertension	452
Case 14: Sarcoidosis	453
Case 15: Tuberculosis	454
Case 16: Wegener’s Granulomatosis	456
Case 17: Sleep Apnea	458
Renal/Genitourinary	459
Case 1: Acid-Base Disorders	460
Case 2: Acute Interstitial Nephritis	461
Case 3: Acute Kidney Injury	462
Case 4: Acute Tubular Injury	464
Case 5: Benign Prostatic Hyperplasia	466
Case 6: Chronic Kidney Disease	468
Case 7: Erectile Dysfunction	470
Case 8: Glomerulonephritis	472
Case 9: Hypercalcemia of Malignancy	474
Case 10: Hyperkalemia	476
Case 11: Hyponatremia	478
Case 12: Hyperosmolar Hyperglycemic State	479
Case 13: Hypocalcemia	480

Case 14: Nephrolithiasis	482
Case 15: Nephrotic Syndrome	483
Case 16: Polycystic Kidney Disease	484
Case 17: Renal Cell Carcinoma	486
Case 18: Renal Tubular Acidosis	487
Case 19: Renovascular Hypertension/Secondary Hypertension	488
Case 20: Testicular Cancer	490
Case 21: Traumatic Urethral Injury	491
Selected Topics in Emergency Medicine	493
Case 1: Acetaminophen Overdose	494
Case 2: Anaphylactic Shock	495
Case 3: Appendicitis, Acute	496
Case 4: Bites, Animal and Human	498
Case 5: Burn, Thermal	500
Case 6: Atrial Fibrillation	502
Case 7: Carbon Monoxide Poisoning	503
Case 8: Cardiac Arrest	504
Case 9: Deep Vein Thrombosis (DVT)	505
Case 10: Drowning	506
Case 11: Organophosphate Poisoning, Acute	508
Case 12: Retinal Detachment	510
Case 13: Supraventricular Tachycardia	512
Case 14: Sepsis	514
Case 15: Syncope	515
Case 16: Testicular Torsion	516
Case 17: Trauma, Fracture, Orbital	517
Case 18: Mesenteric Ischemia, Acute	518
Case 19: Trauma, Fracture, Pelvis	519
Case 20: Trauma, Penetrating, Neck	520
Case 21: Wernicke's Encephalopathy	522
Case 22: Trauma, Penetrating, Abdomen	524
Appendix	525
Index	533
About the Authors	551

This page intentionally left blank

CONTRIBUTING AUTHORS

Karl Benedict Bezak

Vanderbilt University School of Medicine
Class of 2010

Yuriy Bronshteyn

Vanderbilt University School of Medicine
Class of 2010

Elizabeth Eby Halvorson, MD

Vanderbilt University School of Medicine
Class of 2009
Resident
Department of Pediatrics
Wake Forest University Baptist Medical Center

Kim Jiramongkolchai

Vanderbilt University School of Medicine
Class of 2010

Jackie Landess

Vanderbilt University School of Medicine
Class of 2010

Mark Newton, MD

Vanderbilt University School of Medicine
Class of 2009

John W. Wood, MD

Resident
Department of Otolaryngology
Jackson Memorial Hospital
University of Miami

This page intentionally left blank

SENIOR REVIEWERS

Ebere Chukwu, MD

Clinical Fellow
Department of Medicine
Division of Cardiovascular Medicine
Vanderbilt University School of Medicine

Nathaniel Clark, MD

Assistant Professor
Department of Psychiatry
Vanderbilt University Medical Center

Titus Daniels, MD

Assistant Professor
Department of Medicine
Vanderbilt University School of Medicine

Agnes Fogo, MD

John L. Shapiro Professor of Pathology and Professor of Medicine
and Pediatrics
Department of Pathology
Vanderbilt University School of Medicine

G. Waldon Garriss III, MD

Assistant Professor of Internal Medicine and Pediatrics
Associate Chair of Ambulatory Education
Associate Director of Internal Medicine-Pediatrics Residency Program
Associate Director of Internal Medicine Residency Program
Department of Medicine
Vanderbilt University School of Medicine

Joyce Johnson, MD

Professor
Department of Pathology
Vanderbilt University School of Medicine

Greg Plemmons, MD

Assistant Professor
Department of Pediatrics
Division of Hospital Medicine
Monroe Carell Jr. Children's Hospital at Vanderbilt

Camiron Pfennig, MD

Assistant Professor
Department of Emergency Medicine
Assistant Director, Undergraduate Medical Education
Vanderbilt University School of Medicine
Department of Medicine
Vanderbilt University School of Medicine

Derek Riebau, MD

Assistant Professor
Department of Neurology
Stroke Center
Vanderbilt University School of Medicine

Charles Rush, MD

Assistant Professor and Clerkship Director
Department of Obstetrics and Gynecology
Vanderbilt University School of Medicine

Heidi Schaefer, MD

Assistant Professor
Department of Medicine
Vanderbilt University School of Medicine

Richard Stein, MD

Professor
Department of Medicine
Vanderbilt University School of Medicine

Thomas Talbot, MD, MPH

Assistant Professor of Preventive Medicine
Department of Medicine
Vanderbilt University School of Medicine

Amy Weeks, MD

Assistant Professor
Department of Obstetrics and Gynecology
Vanderbilt University School of Medicine

John Zic, MD

Assistant Professor
Department of Medicine
Division of Dermatology
Vanderbilt University School of Medicine

This page intentionally left blank

PREFACE

With *First Aid Cases for the USMLE Step 2 CK*, we continue our commitment to providing students with the most useful and up-to-date preparation guides for the USMLE Step 2 CK. This new edition represents an outstanding effort by a talented group of authors and includes the following:

- Commonly asked question stems on the USMLE Step 2 CK integrated into a single USMLE-style case
- Concise yet complete explanations
- Two-column format for easy self-quizzing
- High-yield images, diagrams, and tables complement the questions and answers
- Organized as a perfect supplement to *First Aid for the USMLE Step 2 CK*

We invite you to share your thoughts and ideas to help us improve *First Aid Cases for the USMLE Step 2 CK*. See How to Contribute, p. xxiii.

Louisville, KY
Winston-Salem, NC

Tao Le
Elizabeth Eby Halvorson

This page intentionally left blank

ACKNOWLEDGMENTS

This has been a collaborative project from the start. We gratefully acknowledge the thoughtful comments and advice of the residents, international medical graduates, and faculty who have supported the authors in the development of *First Aid Cases for the USMLE Step 2 CK*.

Additional thanks to the following for reviewing manuscript: Daniel Birchmore, MD and Meredith Pugh, MD.

Thanks to our publisher, McGraw-Hill, for the valuable assistance of their staff. For enthusiasm, support, and commitment to this challenging project, thanks to our editor, Catherine Johnson. For outstanding editorial work, we thank Isabel Nogueira. A special thanks to Rainbow Graphics for remarkable production work. For support and encouragement throughout the process, we are grateful to Thao Pham, Selina Franklin, and Louise Petersen.

Louisville, KY
Winston-Salem, NC

Tao Le
Elizabeth Eby Halvorson

This page intentionally left blank

HOW TO CONTRIBUTE

To continue to produce a high-yield review source for the USMLE Step 2 CK exam, you are invited to submit any suggestions or corrections. The First Aid Team also offers paid internships in medical education and publishing ranging from three months to one year (see below for details). Please send us your suggestions for:

- High-yield USMLE Step 2 CK cases
- New facts, mnemonics, diagrams, and illustrations
- Low-yield cases to remove

For each entry incorporated into the next edition, you will receive a \$10 gift certificate, as well as personal acknowledgment in the next edition. Diagrams, tables, partial entries, updates, corrections, and study hints are also appreciated, and significant contributions will be compensated at the discretion of the authors. Also let us know about material in this edition that you feel is low yield and should be deleted.

The preferred way to submit entries, suggestions, or corrections is via our blog:

www.firstaidteam.com.

Otherwise, please send entries, neatly written or typed, or on disk (Microsoft Word), to:

**First Aid Team
914 N. Dixie Avenue, Suite 100
Elizabethtown, KY 42701**

NOTE TO CONTRIBUTORS

All entries become property of the authors and are subject to editing and reviewing. Please verify all data and spellings carefully. In the event that similar or duplicate entries are received, only the first entry received will be used. Include a reference to a standard textbook to facilitate verification of the fact. Please follow the style, punctuation, and format of this edition if possible.

INTERNSHIP OPPORTUNITIES

The author team is pleased to offer part-time and full-time paid internships in medical education and publishing to motivated medical students and physicians. Internships may range from three months (e.g., a summer) up to a full year. Participants will have an opportunity to author, edit, and earn academic credit on a wide variety of projects, including the popular *First Aid* series. English writing/ editing experience, familiarity with Microsoft Word, and Internet access are required. Go to our blog **www.firstaidteam.com** to apply for an internship. A sample of your work or a proposal of a specific project is helpful.

This page intentionally left blank

Cardiology

Case 1	2
Case 2	3
Case 3	4
Case 4	6
Case 5	8
Case 6	9
Case 7	10
Case 8	12
Case 9	14
Case 10	16
Case 11	18
Case 12	20
Case 13	21
Case 14	22
Case 15	23
Case 16	24
Case 17	26
Case 18	28
Case 19	30
Case 20	32
Case 21	34
Case 22	36
Case 23	37
Case 24	38
Case 25	40

► **CASE 1**

A 90-year-old man with a history of coronary artery disease, hypertension, and a 30-pack-year smoking history presents to the outpatient clinic for his annual checkup. He denies recent complaints, although reports that he has not been as “active” lately. He has a history of good adherence to health maintenance recommendations, and results of recent colonoscopy and prostate examination are negative. He takes aspirin, metoprolol, and an occasional multivitamin. He admits to having problems with smoking cessation. Vital signs include a temperature of 37.0°C (98.6°F), blood pressure of 120/80 mm Hg, pulse rate of 60/min, and respiratory rate of 10/min. Physical examination shows a thin, elderly man with mottled skin. His head, ears, eyes, nose, and throat (HEENT); neck; chest; and cardiac examinations are unremarkable. His abdomen is nontender and nondistended, but a pulsating mass is palpated approximately 2 cm superior to his umbilicus, 1 cm left of midline.

- **What is the most likely diagnosis?** A pulsatile abdominal mass suggests an abdominal aortic aneurysm (AAA). Approximately 30% of AAAs are discovered during routine physical examinations, although they are more difficult to detect in obese patients or when the aneurysm is small.

 - **What is the epidemiology of this condition?** AAAs occur almost exclusively in people > 60 years old (approximately 4–9% of people > 60 have an AAA) and account for approximately 15,000 deaths per year in the United States. An AAA is associated with advanced age, atherosclerosis, smoking, hypertension, and a family history of AAA.

 - **What is the natural history of this condition?** Most, if not all, AAAs tend to grow. Morbidity and mortality are related primarily to the risk of rupture, which is directly proportional to aneurysm size (risk is markedly increased in aneurysms > 5.5 cm in diameter), and may be independently related to the rate of aneurysm growth. The risk of rupture is also increased by female gender, continued smoking, uncontrolled hypertension, and increased aortic wall stress.

 - **What is the most appropriate treatment for this condition?** The primary management decision in patients with AAAs is either surgery (open or endovascular) or watchful waiting. All symptomatic AAAs should be promptly repaired; repair is also recommended for patients with asymptomatic AAAs that are > 5.5 cm in diameter or have grown 0.5 cm within a 6-month period. Patients with smaller aneurysms should be referred to a vascular specialist and followed by abdominal ultrasound; they should be prescribed β -blockers to control hypertension and counseled to cease smoking.

 - **What is the prognosis for this patient over time?** In a recent trial of about 1000 patients with medium-sized aneurysms, those who received early elective surgery had significantly better survival rates than those who underwent surveillance only. This patient’s prognosis depends on the size of his aneurysm, rate of growth, blood pressure control, and smoking cessation, as well as the chosen treatment strategy.
-

► **CASE 2**

A 63-year-old woman with a history of diabetes mellitus and hypertension presents to the emergency department complaining that she feels short of breath. She reports that she began having difficulty breathing over the past week, which has progressed to the point that she can no longer walk up one flight of stairs without feeling short of breath. She was previously able to walk five blocks before becoming short of breath. She denies any history of heart or lung disease, cough or hemoptysis, chest pain, swelling of the extremities, or fever. She takes no medication. Vitals signs include a temperature of 37.0°C (98.6°F), blood pressure of 170/90 mm Hg, pulse rate of 95/min, respiratory rate of 22/min, and oxygen saturation of 92% on room air. Physical examination reveals that her lungs have crackles at the bases bilaterally, and her cardiac examination reveals a point of maximum impulse at the sixth intercostal space at the midaxillary line. There is no clubbing, cyanosis, or edema of the extremities. X-ray of the chest reveals perivascular haziness, interstitial edema, and an enlarged cardiac silhouette.

-
- | | |
|---|---|
| <p>■ What conditions should be included in the differential diagnosis?</p> | <p>In a patient with new-onset dyspnea, tachypnea, borderline hypoxemia, crackles, interstitial pulmonary edema, and cardiomegaly, the differential diagnosis includes both cardiac and pulmonary disease. Lung infections, pulmonary edema, pulmonary hemorrhage/contusion, pneumothorax, pulmonary embolism, mechanical impairment of ventilation, anemia, sepsis, and acute heart failure should be included in the differential.</p> |
| <p>■ What is the most likely diagnosis?</p> | <p>Acute cardiogenic pulmonary edema. This patient's acute dyspnea in the presence of crackles, pulmonary edema, and cardiomegaly suggest an acute exacerbation of chronic heart failure. Systolic dysfunction is the most common cause of cardiogenic pulmonary edema and is most often due to coronary artery disease, hypertension, valvular heart disease, or idiopathic dilated cardiomyopathy. However, this patient's long-standing hypertension, diabetes, cardiomegaly, advanced age, and female gender all increase the likelihood of diastolic dysfunction. Acute diastolic dysfunction can occur during episodes of ischemia or with hypertension. Elevated blood pressure during an episode of congestive heart failure should raise the suspicion of diastolic dysfunction.</p> |
| <p>■ What tests could be used to confirm the diagnosis?</p> | <p>An echocardiogram is the most important diagnostic test in the workup of new congestive heart failure. It can distinguish possible etiologies and evaluate the severity of the disease. A preserved ejection fraction and left ventricular hypertrophy on echocardiography would support the clinical diagnosis of diastolic dysfunction. In addition, an arterial blood gas, plasma B-type natriuretic peptide, CBC (to evaluate for anemia), serum electrolytes (to evaluate for renal dysfunction), a 12-lead electrocardiogram (to evaluate for ischemia/infarction), and a TSH level (to evaluate for hypothyroidism) or hyperthyroidism should be considered in the workup of this patient's dyspnea.</p> |
| <p>■ What is the most appropriate treatment for this patient?</p> | <p>Patients with acute hypoxemia should receive supplemental oxygen, regardless of the etiology. If necessary, noninvasive positive pressure ventilation may be utilized. Intravenous morphine sulfate can be used to decrease sympathetic outflow, which can reduce patient anxiety and vascular tone, decreasing cardiac filling pressures and improving cardiac output. Loop diuretics such as furosemide are important in the management of acute cardiogenic pulmonary edema, leading to volume reduction and improved cardiopulmonary pressure dynamics. In refractory disease, inotropic support with dopamine, dobutamine, or milrinone may be considered. If myocardial ischemia is suspected, appropriate management is indicated.</p> |
-

► **CASE 3**

A 70-year-old man presents to the emergency department complaining of central chest pain that has been getting worse in the past 3 days, although he reports he is not in pain currently. He reports a history of “squeezing” pain in his chest for the past 5 years that occurs occasionally with physical exertion and resolves with rest; this pain has been occurring at rest for the past 3 days, is occurring more frequently (up to 6 times per day), and lasts a few minutes longer than usual. His medical history is significant for hypertension, hypercholesterolemia, a 40-pack-year smoking history, and a family history of heart disease. Vital signs include a temperature of 37.0°C (98.6°F), blood pressure of 130/90 mm Hg, pulse rate of 80/min, respiratory rate of 12/min, and oxygen saturation of 99% on room air. His physical examination is remarkable for slightly decreased breath sounds bilaterally and a normal cardiac examination. X-ray of the chest reveals clear lungs with a normal-sized heart and mediastinum. An ECG is shown in Figure 1-1.

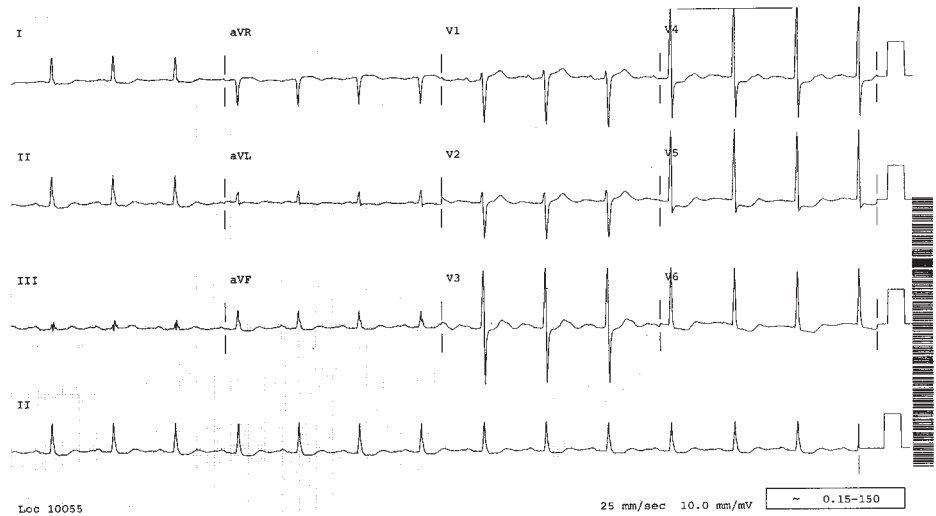


FIGURE 1-1. (Reproduced, with permission, from Fuster V, Alexander RW, O'Rourke RA, eds.; Roberts R, King SB III, Nash IS, Prystowsky EN, assoc. eds. *Hurst's The Heart*, 11th ed. New York: McGraw-Hill, 2004; Fig. 51-5.)

■ **What is the most likely diagnosis?**

This patient's clinical presentation and the ECG showing ST-segment depression of > 1 mm in leads V4–V6 (see Figure 1-1) is consistent with ischemia and should be considered acute coronary syndrome (ACS). ACS can be subdivided into ST-elevation myocardial infarction (STEMI), unstable angina and non–ST-elevation myocardial infarction (NSTEMI); an ST-elevation MI cannot be diagnosed in this case given the absence of ST elevation on ECG. Unstable angina and NSTEMI can be distinguished by the presence of positive serum biomarkers for an NSTEMI (troponin I, CK, CK-MB); regardless, their treatment is similar.

- What are the immediate next steps in management?
 - ABCs (Airway, Breathing, Circulation) assessed and secured
 - 12-lead ECG
 - Cardiac monitor
 - Oxygen
 - IV access
 - Resuscitation equipment at hand
 - Chewed oral aspirin (162 or 325 mg)
 - Nitrates and morphine
 - Heparin
 - β -blocker (if no hypotension, in cardiogenic shock or high degree AVN block)
 - Insulin as needed to normalize blood glucose

- What is the pathophysiology of this condition?

All syndromes of myocardial ischemia fall on the same spectrum of pathophysiologic changes. Ischemic chest pain (angina) is produced when myocardium becomes ischemic; this occurs when the oxygen demand of the myocardial tissue outstrips its supply. Typically, stable angina is due to increased myocardial demand (exertion, tachycardia, positive inotropy) in the presence of diminished oxygen supply (fixed stenotic coronary artery lesion, anemia). Unstable angina is thought to occur when a stable coronary atherosclerotic plaque acutely ruptures and thromboses, leading to a suddenly decreased blood supply that threatens a particular region of myocardium. An NSTEMI occurs when this leads to infarction (measured by serum biomarkers) without ST-segment elevation. An ST-elevation MI (STEMI) occurs due to transmural injury, causing ST elevations.

- What is the most appropriate next step in management?

The next step, after immediate medical therapy as described above, is risk stratification using the Thrombolysis in Myocardial Infarction (TIMI) risk score to determine how aggressive a therapeutic approach is warranted. The TIMI risk scores gives one point for the presence of each of the following:

 - Age \geq 65 years.
 - Presence of $>$ two risk factors for coronary heart disease.
 - Prior coronary stenosis of $>$ 50%.
 - Presence of ST-segment deviation on initial ECG.
 - At least two anginal episodes in prior 24 hours.
 - Elevated serum cardiac biomarkers.
 - Use of aspirin in prior 7 days.

There are two options for management of patients who present with an acute coronary syndrome due to unstable angina or NSTEMI:

 - An early invasive strategy: This option is used for high-risk patients (i.e., those with TIMI risk score 3 and above, patients with elevated cardiac enzymes, ST-segment depression, recurrent angina, sustained ventricular tachycardia or hemodynamic instability, or prior PCI or CABG). Coronary angiography is performed between 4 and 24 hours after admission, followed by appropriate revascularization with PCI or CABG.
 - Patients with only one or two points undergo stress testing, with subsequent invasive imaging depending on the stress test results or recurrence of anginal symptoms.

► **CASE 4**

A 62-year-old man with a history of poorly controlled hypertension comes to the emergency department complaining of 1 hour of intense pain in his chest. He was climbing the stairs at home when he felt a sudden, sharp pain in the center of his chest, and felt light-headed. He still feels light-headed and reports that the pain is a “stabbing,” 10 out of 10 pain that radiates throughout his chest. He denies any other medical history, but on further questioning reveals that he smokes one pack of cigarettes daily and takes his metoprolol only when he feels “sick” or has a headache. Vital signs include a temperature of 37.0°C (98.6°F), blood pressure of 170/100 mm Hg, pulse rate of 85/min, and respiratory rate of 15/min. Physical examination shows a well-developed, well-nourished, uncomfortable man with slight diaphoresis. His HEENT and neck examinations are unremarkable. His lung fields are clear to auscultation and he has good breath sounds bilaterally. His heart has a regular rate and rhythm with a 2/6 diastolic murmur along the right sternal border. Examination of his extremities reveals an absent right radial pulse. His abdominal and neurologic examinations are unremarkable. X-ray of the chest shows clear lung fields and a widened mediastinum.

- **What is the most likely diagnosis?** The sudden onset of sharp or “tearing” chest pain should immediately suggest an acute aortic dissection, one of the most life-threatening causes of chest pain. The pulse deficit in the right upper extremity, light-headedness, and widened mediastinum on chest x-ray further point to aortic dissection. These findings also indicate that the dissection is occurring in the ascending aorta and involves at least the right brachiocephalic and right common carotid arteries. Tobacco use and hypertension are the two most common risk factors for aortic dissection.
-

- **How is this condition classified?** Aortic dissections are classified using one of two anatomic systems:
 - The DeBakey classification:
 - Type 1: Dissection of ascending and descending thoracic aorta
 - Type 2: Dissection of ascending aorta only
 - Type 3: Dissection of descending aorta only
 - The Stanford classification:
 - Type A: Any dissection involving the ascending aorta
 - Type B: All other dissections

Given his light-headedness (may reflect carotid artery involvement) and the murmur (may represent aortic insufficiency), this patient likely has a Stanford type A dissection.
-

- **In addition to tobacco use and hypertension, what other risk factors are often present in patients with this condition?**
 - Aortic coarctation.
 - Bicuspid aortic valve.
 - Collagen disorders (e.g., Marfan’s syndrome, Ehlers-Danlos syndrome).
 - Crack cocaine use.
 - Inflammatory vascular disorder (e.g., Takayasu’s arteritis, giant cell arteritis, rheumatoid arthritis, syphilitic aortitis).
 - Preexisting aortic aneurysm.
 - Previous cardiac procedures (e.g., aortic valve replacement, cardiac catheterization, coronary artery bypass grafting).
 - Turner’s syndrome.
-

- **What is the most appropriate treatment for this condition?**

Dissections involving the ascending aorta are surgical emergencies, whereas dissections confined to the descending aorta are initially treated medically. Hemodynamically unstable patients should be intubated and undergo transesophageal echocardiography (TEE) at the bedside. Intravenous β -blockers should be titrated to the lowest tolerable blood pressure. Patients may present with hypotension for a variety of reasons, including blood loss, cardiac tamponade, or cardiac muscle failure; therefore, inotropic agents should be avoided until the etiology of hypotension is established. Definitive management in this patient with a presumed Stanford type A dissection is prompt surgical repair.

► **CASE 5**

A 55-year-old homeless man presents to the emergency department complaining of chest pain, profuse sweating, and shortness of breath. ECG demonstrates ST elevation in leads V4–5 and elevation in troponin I. The man consents to cardiac catheterization but tells the attending cardiologist that he will not be able to take medicine after leaving because he has no money or insurance. Forty minutes later, he is taken to the catheterization lab, where a 70% occlusion of the LAD is evident and a stent is placed.

■ **Should a bare metal stent (BMS) or drug-eluting stent (DES) be placed?**

BMS. The most important post-stent considerations are restenosis and thrombosis. A DES has lower rates of restenosis and target lesion revascularization but has higher rates of late stent thrombosis (LST). Because of the risk of LST, clopidogrel and aspirin must be taken for 12 months following DES placement. Indications for BMS placement include the following:

- Patients poorly compliant with dual antiplatelet therapy with aspirin and clopidogrel or who may require cessation of antiplatelet therapy for surgery within the year.
- Patients who are at high risk for bleeding, such as those on long-term warfarin therapy.

■ **What medications should post-MI patients be prescribed to reduce mortality?**

- Antiplatelet therapy: aspirin indefinitely and clopidogrel for at least 1 month (BMS) or 12 months (DES).
- β -blocker.
- ACE inhibitor.
- Aldosterone inhibitor (for patients on ACE inhibitor with EF < 40% and intact renal function).
- Statin.

■ **What are the causes of acute renal failure immediately following PCI?**

- Atheroembolism: suggested by persistent renal failure > 7 days, other signs of embolism such as digital ischemia or SMA syndrome, and transient eosinophilia and hypocomplementemia.
- Radiocontrast nephropathy.
- Hemodynamic instability: renal hypoperfusion during periods of hypotension.

■ **What is reperfusion injury (RI), and what are the symptoms?**

RI is a poorly understood process of injury to cardiac myocytes and vascular endothelium caused by restoring blood flow after occlusion. It is thought to be due to production of oxygen free radicals, altered metabolism and Ca^{2+} handling, and inflammatory activation.

Manifestations include:

- Myocardial stunning: prolonged postischemic dysfunction of viable tissue salvaged by reperfusion.
- Microvascular dysfunction: endothelial dysfunction may result in vasoconstriction, platelet and WBC activation, increased oxygen production, and protein extravasation. This may result in a “no flow” phenomenon.
- Lethal reperfusion injury: contraction band necrosis may occur with reperfusion of severely ischemic myocardium.
- Arrhythmias: due to a combination of the above processes.

■ **What is the incidence of sustained ventricular arrhythmia following MI?**

Sustained arrhythmias last > 30 seconds. Sustained ventricular arrhythmia occurrence with STEMI is approximately 10% and with NSTEMI 2.1%. Those who develop sustained ventricular arrhythmias greater than 48 hours after MI should undergo ICD placement due to the risk of recurrence.

► CASE 6

A 75-year-old man with a history of Marfan's syndrome presents to his physician complaining of a 6-month history of shortness of breath. He says his exercise tolerance has gradually decreased from 10 blocks on level ground to about 1 block and is limited by shortness of breath. He also reports shortness of breath at night, as well as generalized fatigue, occasional palpitations, and feeling like his heart is "pounding," especially when he lies on his left side. On physical examination, he appears in no acute distress and is a tall, thin man with a marfanoid body habitus. Vital signs include a temperature of 37.0°C (98.6°F), blood pressure of 160/50 mm Hg, pulse rate of 80/min, respiratory rate of 12/min, and oxygen saturation of 99% on room air. He has a laterally displaced point of maximum impulse; distant heart sounds; a high-pitched, blowing early diastolic murmur heard best at the left sternal border that is decreased by the Valsalva maneuver; clear lungs; and peripheral pulses with sharp upstrokes and downstrokes.

-
- | | |
|---|---|
| <p>■ What is the most likely diagnosis?</p> | <p>Progressive dyspnea in a patient with a widened pulse pressure and a diastolic murmur suggests aortic regurgitation or insufficiency (AR) or mitral stenosis. In this patient, who also has "water-hammer" peripheral pulses and Marfan's syndrome (an AR risk factor), AR is the most likely diagnosis.</p> |
| <p>■ What is the pathophysiology of this condition?</p> | <p>With an incompetent aortic valve, a portion of the ejected systolic stroke volume leaks back into the left ventricle (LV) during diastole, leading to an increased LV end-diastolic volume. The LV enlarges and the myocardium hypertrophies in response to this increased wall stress to maintain normal LV end-diastolic pressure and an adaptively increased stroke volume. Over time, the LV thins and dilates in response to this volume overload.</p> |
| <p>■ What other physical signs may accompany this condition?</p> | <ul style="list-style-type: none"> ■ Becker's sign: visible pulsations of retinal arteries and pupils. ■ deMusset's sign: a head bob with each heartbeat. ■ Duroziez's sign: systolic and diastolic bruit when the femoral artery is partially compressed. ■ Gerhard's sign: systolic pulsations of the spleen. ■ Hill's sign: popliteal cuff systolic pressure exceeding brachial pressure by > 60 mm Hg. ■ Mayne's sign: > 15 mm Hg decrease in diastolic blood pressure with arm elevation. ■ Mueller's sign: systolic uvular pulsations. ■ Quincke's pulses: capillary pulsations in fingertips or lips. ■ Rosenbach's sign: systolic pulsations of the liver. ■ Traube's sign: systolic and diastolic sounds over the femoral artery (pistol-shot pulse). |
| <p>■ What are the next steps in management?</p> | <p>An echocardiogram is essential and will confirm the diagnosis by evaluating the degree of valvular dysfunction and myocardial compensation. Initial management includes vasodilation, diuresis, and possibly digoxin, depending on systolic function. Once medical therapy is begun, workup for causes and assessment of need for valve surgery should be undertaken. In asymptomatic patients with severe AR who have left ventricular enlargement and normal LV systolic function, surgery may be forgone for vasodilator therapy, which reduces afterload and effectively shunts a greater proportion of the ejection fraction into the systemic circulation. In this patient with Marfan's syndrome, the most important determinant of the need for surgery is the diameter of the aortic root, as aortitis of any cause (syphilis, rheumatologic diseases) can dilate the aorta and cause aortic insufficiency.</p> |
-

► **CASE 7**

A 75-year-old man with a past medical history of diabetes mellitus and hypertension presents to the emergency department complaining of the sudden onset of shortness of breath accompanied by palpitations beginning 6 hours ago. The palpitations last for approximately 10 minutes at a time and recur at least once an hour. He admits to a 5-year history of intermittent similar symptoms. He denies chest pain, cough, or lightheadedness. He takes no medications and does not smoke cigarettes, but admits to drinking six to eight beers per day over the past 3 days. Vital signs include a temperature of 37.2°C (98.9°F), blood pressure of 135/90 mm Hg, pulse rate of 130/min, and respiratory rate of 22/min. The patient is speaking in full sentences, has a midline trachea, and has no inspiratory rales, dullness to percussion, or increased tactile fremitus over the lung fields. His heart examination is notable for an irregularly irregular rhythm without murmurs; there is no chest wall tenderness. An ECG is shown in Figure 1-2.

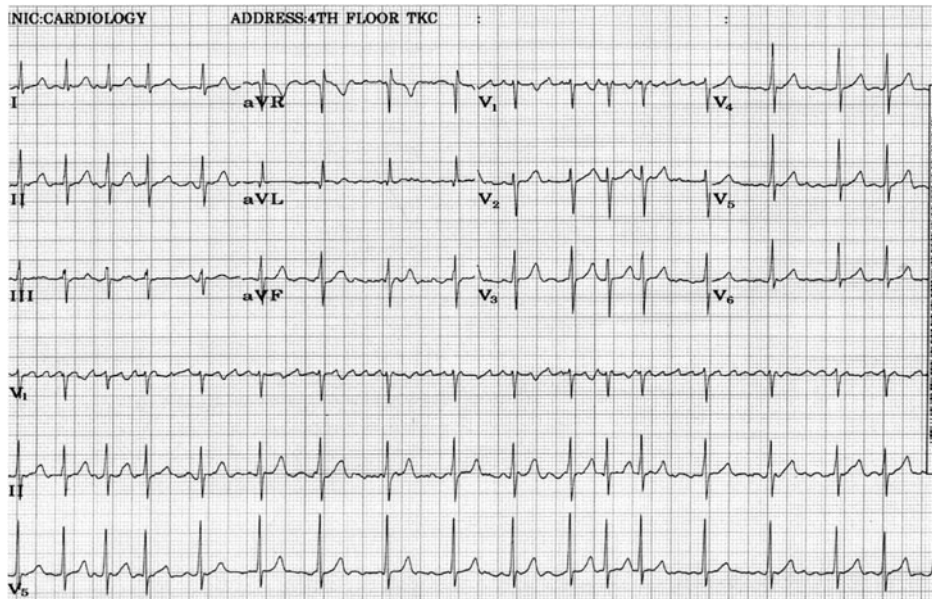


FIGURE 1-2. ECG characteristic of atrial fibrillation. (Reproduced, with permission, from Fuster V, Alexander RW, O'Rourke RA, eds.; Roberts R, King SB III, Nash IS, Prystowsky EN, assoc. eds. *Hurst's The Heart*, 11th ed. New York: McGraw-Hill, 2004: Fig. 29-1.)

-
- **What is the most likely diagnosis?** Atrial fibrillation (AF). This is the most common chronic arrhythmia, and the only common arrhythmia in which the ventricular rate can be rapid and irregular. Atrial flutter is often confused with AF; however, atrial flutter has a rapid regular ventricular response with a rate about 150 beats per minute and the characteristic ECG finding of flutter waves.
-
- **How is this condition classified?**
 - First detected (at initial presentation)
 - Recurrent (having occurred more than once)
 - Paroxysmal (episodes lasting < 7 days)
 - Persistent (episodes lasting > 7 days)
 - Permanent (failed cardioversion, lasted > 1 year, or if further attempts to terminate the rhythm are considered futile)
-

- What risk factors are associated with an increased incidence of this condition?

Hypertensive and coronary heart disease are the most common underlying disorders in patients with AF, although the other main causes can be remembered using the mnemonic “**THE ATRIAL FIBS**”:

Thyroid disease (hyperthyroidism, thyrotoxicosis)

Hypothermia

Embolism (pulmonary)

Alcohol

Trauma (cardiac contusion)

Recent surgery (e.g., CABG)

Ischemia

Atrial enlargement

Lone/idiopathic

Fever/anemia/high-output states

Infarct

Bad valves (mitral stenosis)

Stimulants (caffeine, theophylline, cocaine, amphetamine)

-
- What is the most appropriate treatment for this condition?

ABCD: Anticoagulation, Beta-blockers, Calcium channel blockers/ Cardioversion, Digoxin.

For recurrent paroxysmal AF with minimal or infrequent symptoms, anticoagulation (with warfarin) and rate control (with β -blockers or calcium channel blockers) are the current ACC/AHA/ESC guidelines.

For patients with recurrent persistent or permanent AF, or for patients with frequent or disabling symptoms, antiarrhythmic drug therapy is indicated for rhythm control in addition to rate control and anticoagulation. Alternatively, surgery, ablation, or implantable devices may be used in patients who cannot tolerate antiarrhythmic drug therapy.

In patients with acute-onset AF and hemodynamic instability, electrical cardioversion is indicated. If the duration of the AF is unknown or > 48 hours, or the patient is at high risk of embolization, transesophageal echocardiography (TEE) is performed to locate atrial clots prior to cardioversion. Alternatively, cardioversion may be delayed for 6 weeks for anticoagulation with warfarin to minimize the risk of embolization in a stable patient.

► **CASE 8**

A 23-year-old man is brought by ambulance to the emergency department after being stabbed in the chest during a fight. The initial history discloses he has no allergies, takes no medications, has no significant past medical history, and last ate about 3 hours ago. He complains of severe pain in his chest and of difficulty breathing. Vital signs include a temperature of 37.0°C (98.6°F), blood pressure of 85/50 mm Hg during expiration and 60/palpable during inspiration, pulse rate of 120/min, respiratory rate of 20/min, and oxygen saturation of 96% on room air. Physical examination shows a well-developed, well-nourished man with tattered and blood-stained clothing, and no evidence of other penetrating or blunt trauma including head trauma. His HEENT examination is unremarkable. His neck examination shows a jugular venous pressure of about 15 cm H₂O; he has a midline trachea, no subcutaneous crepitus, and no obvious neck wounds. His chest is clear to auscultation and he has good breath sounds bilaterally. A 2-cm linear wound is present about 2 cm to the left of his sternum at the level of the nipple. His heart sounds are distant and tachycardic but have a regular rhythm. His abdominal, extremity, and neurologic examinations are unremarkable. X-ray of the chest shows clear lung fields, no pneumothorax, no pleural effusion, and a moderately enlarged heart.

■ What conditions should be included in the differential diagnosis?	In an emergent setting, acute chest pain, hypotension, tachypnea, and tachycardia suggest acute aortic dissection, acute myocardial infarction, cardiac tamponade, and tension pneumothorax.
■ What is the most likely diagnosis?	In a 23-year-old man with no past medical history, a myocardial infarction is unlikely. The absence of tracheal deviation and radiographic evidence of pneumothorax in conjunction with the presence of good breath sounds bilaterally makes a tension pneumothorax very unlikely. Cardiac tamponade is more likely than aortic dissection due to its classic physical findings of elevated jugular venous pressure, distant heart sounds, and hypotension (Beck's triad), as well as pulsus paradoxus (decrease of systolic blood pressure by > 10 mm Hg during inspiration) and an enlarged heart on x-ray of the chest. Kussmaul's sign (failure of descent or a paradoxical increase of jugular venous pressure on inspiration) may also be present.
■ What tests and/or imaging tools should be used to confirm the diagnosis?	Trauma patients such as this one will often receive a focused abdominal sonogram for trauma (FAST), which includes ultrasonography of the heart and selected abdominal organs and spaces. ECG will show globally decreased voltages indicating signal attenuation by pericardial fluid, and rarely, electrical alternans (beat-to-beat variability in QRS complexes due to swinging of the heart in accumulated pericardial fluid). Chest x-ray films are usually unremarkable in acute tamponade, unless sufficient fluid has accumulated to enlarge the cardiac silhouette (> 200 mL). Echocardiography is strongly recommended in all patients with suspected pericardial disease. Two-dimensional echocardiographic evidence of tamponade includes collapse of the right atrium, left atrium, or the right ventricle during diastole, or failure of the inferior vena cava to collapse with inspiration. On Doppler examination, filling patterns across the mitral and tricuspid valve show increased respiratory variation.

- **What is the most appropriate treatment for this condition?**

In hemodynamically unstable patients such as this one, urgent removal of the pericardial fluid by pericardiocentesis is indicated. In patients whose tamponade is due to hemorrhage from cardiac rupture (a possibility in this patient), emergent surgery is indicated, as well as aggressive medical stabilization of hemodynamics. Volume resuscitation must be considered, as tamponade pathophysiology is greatly worsened by hypovolemia.

► **CASE 9**

A 70-year-old man presents to the emergency department complaining of increased shortness of breath with minimal exercise, cough, and fatigue. These symptoms began 2 weeks ago and have progressed gradually. He reports he used to feel this way “all the time” years ago but that this has not happened much since he began using his inhalers and his “water pill.” He also has a history of chronic obstructive pulmonary disease (COPD), congestive heart failure (CHF), coronary artery disease (CAD), diabetes mellitus, hypertension, and 30-pack-year of smoking. He denies swelling of the extremities, fever or chills, productive cough, chest pain, or palpitations. He cannot remember the names of his medications but says he has not missed any doses. When asked about his diet, he says he has been eating more hot soup since the weather has gotten colder. His temperature is 37.5°C (99.5°F), blood pressure is 135/90 mm Hg, heart rate is 90/min, respiratory rate is 18/min, and oxygen saturation is 94% on room air. Examination of the neck reveals mild jugular venous distention. Examination of the lungs reveals loud crackles throughout the lung fields bilaterally. Examination of the heart reveals a laterally displaced point of maximum impulse with no murmurs, rubs, or gallops. There is mild clubbing of the extremities, as well as pitting edema of the lower extremities to the knee, bilaterally. His plasma brain natriuretic peptide level on rapid bedside assay is 500 pg/mL, and an x-ray of the chest reveals perivascular haziness, interstitial edema, and an enlarged cardiac silhouette.

■ **What conditions should be included in the differential diagnosis?**

CAD, COPD, and CHF each may present with dyspnea on exertion and fatigue. It is of primary importance to distinguish between them when evaluating the presenting symptoms. Etiologies of gradually worsening shortness of breath and fatigue can include both cardiac and pulmonary diseases, including the following:

- Anemia.
- Heart failure secondary to ischemia/infarction, dysrhythmia, valvular dysfunction, infection, or volume overload.
- Lung infections (pneumonia, bronchitis, bronchiectasis).
- Mechanical impairment of ventilation.
- Pulmonary edema.
- Pulmonary embolism.
- Sepsis.

■ **What is the most likely diagnosis?**

CHF exacerbation leading to pulmonary edema. This patient’s dyspnea, jugular venous distension, and tachypnea in the presence of crackles, pulmonary edema, elevated brain natriuretic peptide (BNP) level, and cardiomegaly suggest an acute exacerbation of CHF. An exacerbation of COPD is unlikely given that this patient does not have fever, productive cough, or wheezing. Additionally, the patient reported increasing intake of soup, a particularly salty food, which can significantly increase water retention, thereby worsening CHF. A mnemonic for the causes of recurrent CHF is **FAILURE**:

Forgot medication

Arrhythmia/anemia

Ischemia/infarct/infection

Lifestyle (increased sodium intake, decreased exercise); most common cause

Upregulation (increased cardiac output due to pregnancy, hyperthyroidism, etc.)

Renal failure

Embolus (pulmonary)

■ How is this condition classified?	The American College of Cardiologists and American Heart Association developed guidelines in 2001 for the classification and treatment of CHF (see Table 1-1).
■ What are the typical laboratory and imaging findings in this condition?	<p>In addition to an x-ray of the chest that may show pulmonary edema, patients with CHF exacerbations may have the following:</p> <ul style="list-style-type: none"> ■ Decreased hematocrit (anemia may exacerbate CHF). ■ Increased potassium, creatinine, and blood urea nitrogen levels (renal failure may exacerbate CHF). ■ Increased plasma BNP level, which is usually elevated in CHF exacerbations. ■ A chest radiograph showing cardiomegaly, cephalization of pulmonary vessels, and/or pleural effusion. ■ ECG changes showing left ventricular hypertrophy, arrhythmias, or ischemia or low-voltage or old infarcts (in fact, a normal ECG makes systolic dysfunction highly unlikely). ■ ECG showing abnormal ventricular size (dilated, hypertrophic, or restrictive cardiomyopathy) or function (systolic or diastolic).
■ What is the most appropriate treatment for this patient?	<p>This patient appears to have stage C heart failure as defined by Table 1-1. His physical exam and x-ray of the chest show evidence of myocardial hypertrophy, and he is having recurrent symptoms. He should be admitted to the hospital for a trial of intravenous diuresis (which often succeeds when oral diuretics fail). An echocardiogram should be obtained to evaluate for left ventricular structural abnormalities as well as determine an ejection fraction. He should be prescribed an ACE inhibitor or an angiotensin receptor blocker (given his atherosclerosis, hypertension, and diabetes mellitus), a diuretic (given his evidence of fluid retention), and digitalis (if his ejection fraction is less than 25%, as this has been shown to reduce hospitalization). He should also receive frequent blood pressure and weight monitoring, exercise counseling, and possibly an aldosterone antagonist (depending on his ejection fraction). In addition, he should take aspirin and a statin for his CAD.</p>

TABLE 1-1. Stages of Congestive Heart Failure

STAGE	DESCRIPTION	TREATMENT
A	Patient is high risk for developing CHF (hypertension, CAD, diabetes mellitus, or family history), but has no evident signs or symptoms.	Manage hypertension, smoking, obesity, exercise, hyperlipidemia, alcohol use. Use angiotensin-converting enzyme (ACE) inhibitors in patients with diabetes, hypertension, atherosclerosis.
B	Patient has structural heart disease but has never had symptoms of CHF.	ACE inhibitors, β -blockers.
C	Patient has structural heart disease with prior or current symptoms of CHF.	Diuretics, ACE inhibitors, β -blockers, dietary salt restriction, digitalis.
D	Patient has marked symptoms of CHF at rest despite maximal therapy.	Mechanical assist devices, transplant, intravenous inotropes, hospice care.

► **CASE 10**

An 85-year-old woman who underwent colon cancer surgery 2 months ago is brought to the clinic by her daughter because she has been complaining of painful swelling of her left leg. The patient says she has been feeling otherwise well except for a 2-week history of pain, swelling, and redness in her upper left calf. She denies any history of similar problems in the past and denies acute or repetitive trauma to the area; she says that, in fact, she has been avoiding exercise or walking unnecessarily since her surgery. She denies any other medical or surgical history and takes atenolol and aspirin daily. Vital signs include a temperature of 37.0°C (98.6°F), blood pressure of 135/90 mm Hg, pulse rate of 60/min, and respiratory rate of 12/min. Her physical examination demonstrates no jugular venous distention; clear lung fields; a regular heart rate and rhythm without murmurs, rubs, or gallops; and a normal abdomen. Her left calf has pitting edema and is approximately 4 cm larger in circumference than the right calf. It is erythematous on the posterior aspect and tender to palpation. Neurologic and skin examinations are otherwise unremarkable.

■ What conditions should be included in the differential diagnosis?	The differential diagnosis of pain and swelling in a lower extremity includes cellulitis, deep venous thrombosis, knee injury, lymphangitis or lymph obstruction, muscle strain or tear, popliteal (Baker's) cyst, superficial thrombophlebitis, and venous insufficiency.
■ What is the most likely diagnosis?	Given the clinical presentation, deep venous thrombosis (DVT) is the most likely diagnosis.
■ What other risk factors are associated with an increased incidence of this condition?	In addition to hereditary thrombophilia (factor V Leiden, protein C and S deficiency, antithrombin III deficiency, prothrombin gene mutation, etc.), many acquired DVT risk factors have been identified and include antiphospholipid antibody syndrome, congestive heart failure, hormone replacement therapy, hyperhomocysteinemia, hyperviscosity, immobilization, inflammatory bowel disease, leukocytosis, malignancy, myeloproliferative disorders, nephrotic syndrome, oral contraceptives, paroxysmal nocturnal hemoglobinuria, pregnancy, presence of a central venous catheter, sickle cell anemia, surgery (especially orthopedic), tamoxifen, and trauma.
■ What tests and/or imaging tools could be used to confirm the diagnosis?	Compression ultrasonography is the first-line test for patients with a suspected DVT, with a positive predictive value of 94%. The gold standard test for diagnosing DVT is contrast venography, but it is too invasive to use on a regular basis. Impedance plethysmography is a noninvasive alternative and is used primarily in cases of recurrent DVT. A D-dimer assay is often used clinically to help rule out DVT, as it has very high sensitivity. Magnetic resonance venography has high sensitivity and specificity, but cost and availability prevent its regular use.

- **What is the most appropriate treatment for this patient after the diagnosis is confirmed?**

IV unfractionated heparin, low-molecular-weight heparin (enoxaparin), or adjusted-dose IV heparin for at least 5 days.

Warfarin can usually be started in conjunction with heparin, once the PTT is therapeutic for 24 hours. Warfarin should be continued for 3–6 months in patients with non-time-limiting proximate causes (e.g., cancer, thrombophilia) or for a longer duration for recurrent DVT.

Heparin should be discontinued when the patient's International Normalized Ratio (INR) has been therapeutic on warfarin for 2 consecutive days.

An inferior vena caval filter is indicated if there is a contraindication to, complication of, or failure of oral anticoagulation therapy in patients with (or at high risk of) proximal vein thrombosis or pulmonary embolism.

► **CASE 11**

A 46-year-old man with a history of chronic alcohol abuse presents to the clinic with a chief complaint of swelling in his feet and lower legs. He says the swelling started within the past year and has been persistent despite elevating his feet at night. He denies any significant medical history, takes no medications, and does not use tobacco. He reports 20 years of drinking six to eight beers daily and reports that he has tried to “cut down” his alcohol intake recently, but still drinks approximately four beers per night. On further questioning, he reveals that he has been feeling more fatigued than normal, and says he cannot walk as far as he used to without getting short of breath. Vital signs include a temperature of 37.0°C (98.6°F), blood pressure of 125/70 mm Hg, pulse rate of 80/min, and respiratory rate of 14/min. Physical examination reveals distended jugular veins. His chest exam is clear, and his heart has a regular rate and rhythm with no murmurs or gallops. He has normal bowel sounds but has a protuberant abdomen with shifting dullness and a fluid wave. He has pitting edema to mid-calf bilaterally with good distal pulses. An x-ray of the chest is shown in Figure 1-3.

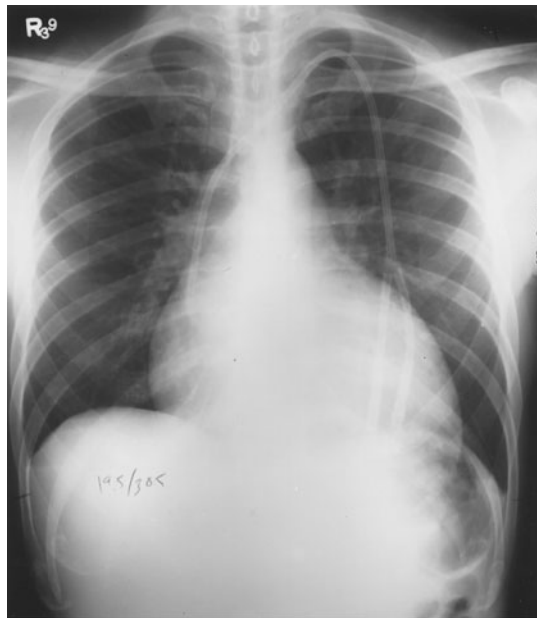

FIGURE 1-3. (Reproduced, with permission, from Tintinalli JE, Kelen GD, Stapczynski JS, Ma OJ, Cline DM. *Tintinalli's Emergency Medicine*, 6th ed. New York: McGraw-Hill, 2004: Fig. 61-3.)

■ **What conditions should be included in the differential diagnosis?**

This patient is exhibiting symptoms and signs of excess interstitial fluid accumulation: shortness of breath, ascites, and peripheral edema. The differential diagnosis should thus focus on disease states known to cause subacute or chronic fluid accumulation:

- Congestive heart failure (dilated cardiomyopathy, hypertrophic cardiomyopathy, restrictive cardiomyopathy, valvular heart disease, high-output failure).
- Liver disease.
- Lymphatic obstruction.
- Nephrotic syndrome or sodium retention.
- Venous insufficiency.

- **What is the most likely diagnosis?** This patient satisfies the requirements for alcoholic cardiomyopathy on history, physical exam, and chest x-ray: congestive heart failure, cardiomegaly (see Figure 1-3), and a history of heavy and prolonged alcohol intake. Alcoholic cardiomyopathy is caused by a direct, toxic effect of alcohol on the myocardium and is perpetuated by deficiencies that often accompany long-term alcoholism such as thiamine (wet beriberi), hypomagnesemia, and hypokalemia. It is the leading cause of secondary, nonischemic dilated cardiomyopathy in the United States.

 - **What other symptoms are common in patients with this condition?** Patients with alcoholic cardiomyopathy often display symptoms and signs common to heart failure of any cause, such as dyspnea, orthopnea, paroxysmal nocturnal dyspnea, palpitations, angina or chest discomfort, syncope, fatigue, weakness, decreased exercise tolerance, anorexia, and/or nausea. In addition, signs of chronic liver disease such as jaundice, spider angiomas, and hepatomegaly should also be sought out.

 - **What is the most appropriate treatment for this patient?**

Echocardiography will confirm the diagnosis and define the extent of disease. Alcoholic cardiomyopathy will appear as a four-chamber dilatation, with thin-walled ventricles, decreased ejection fraction, and absence of wall motion abnormalities.

Abstinence from alcohol is associated with a favorable course of the cardiomyopathy, and may help prevent fibrosis of the myocardium.

Salt restriction and loop diuretics are mainstays of treatment for the acute congestive phase of heart failure from any cause.

ACE inhibitors, β -blockers (when euvolemic), and digoxin should be prescribed as indicated for control of blood pressure and prevention of myocardial remodeling.

Any nutritional deficiencies (e.g., hypokalemia or hypomagnesemia) should be corrected.
-

► **CASE 12**

An 80-year-old woman with a history of chronic hypertension presents to the clinic for a routine examination. She notes that over the past couple of years she has had progressive mild shortness of breath on exertion and in the middle of the night, as well as mild foot swelling. She denies cough, chest pain, palpitations, light-headedness, or fatigue. She denies that it is very bothersome but would like to know if it is dangerous to her health. She has never been hospitalized, and denies any significant medical history other than high blood pressure, although she admits to being poorly adherent to her medications. She denies a smoking history and family history of similar problems. Vital signs include a temperature of 37.0°C (98.6°F), blood pressure of 170/110 mm Hg, pulse rate of 80/min, and respiratory rate of 18/min. Physical examination reveals a lack of jugular venous distention and a laterally displaced point of maximum impulse, with no murmurs, rubs, or gallops, a clear lung exam, and 2+ pitting edema to midleg bilaterally. An ECG shows left atrial enlargement and left ventricular hypertrophy with repolarization abnormalities. Echocardiography shows an ejection fraction of 65% and a thickened left ventricular wall.

■ What conditions should be included in the differential diagnosis?	In this patient with subacute symptoms and signs suggestive of heart failure (dyspnea on exertion, peripheral edema, paroxysmal nocturnal dyspnea) the differential includes congestive heart failure, lung disease, atrial fibrillation, and ischemic heart disease.
■ What is the most likely diagnosis?	Clinical heart failure in the setting of chronic hypertension and echocardiographic evidence of normal systolic function and thickened myocardium indicate that diastolic dysfunction is the likely cause of symptoms. However, the specific cause of her heart failure is likely chronic hypertensive cardiac left ventricular (LV) hypertrophy. Other common causes of diastolic dysfunction include amyloidosis, diabetes, constrictive pericarditis, hemochromatosis, coronary artery disease, sarcoidosis, severe aortic regurgitation, and severe mitral regurgitation.
■ What other tests should be considered for this patient?	Many patients with symptoms and signs of heart failure also give a history of angina or ischemic heart disease. These patients should undergo either stress testing or cardiac catheterization. Catheterization can help determine the presence and extent of coronary disease as well as measure ventricular and atrial pressure dynamics. Stress echocardiography can illustrate chamber size, motion, and response to exercise, thus aiding in the diagnosis of coronary disease and diastolic dysfunction.
■ What is the most appropriate treatment for this condition?	The general principles of treatment in diastolic dysfunction are to control hypertension, control any arrhythmia, control edema (pulmonary and peripheral), and stabilize any underlying coronary artery disease. Diuretics can reduce both blood pressure and edema; however, ACE inhibitors, angiotensin II receptor blockers, calcium channel blockers, and β -blockers are often required to fully control the patient's hypertension. Atrial fibrillation is controlled as in the general population, although a greater emphasis is placed on rhythm control to restore the atrial diastolic "kick." Finally, any coronary heart disease should be fully evaluated and treated.

► CASE 13

A 72-year-old man with a history of peripheral vascular disease presents to the clinic complaining of having shortness of breath for the past month. He had previously been able to climb two flights of steps with little difficulty, but now cannot climb one flight without severe shortness of breath. On further questioning, he reports occasional chest pain on heavy exertion, and says 1 week earlier he fainted after climbing the stairs from his basement. He denies a history of heart or lung problems, high cholesterol, diabetes, smoking, or family history of heart or lung disease. On physical examination, he appears in no acute distress, and his vital signs include a temperature of 37.0° C (98.6° F), blood pressure of 140/80 mm Hg, pulse rate of 80/min, respiratory rate of 12/min, and oxygen saturation of 99% on room air. There is a slow rise of the carotid upstroke, a sustained apical impulse, and a quiet S2, as well as a 3/6 harsh systolic ejection murmur heard best at the second intercostal space at the right sternal border.

-
- | | |
|---|---|
| <ul style="list-style-type: none"> ■ What is the pathophysiology of volume shifts in this condition? | <p>Unlike aortic regurgitation, which leads to left ventricular volume overload and compensatory chamber enlargement, AS leads to left ventricular pressure overload and compensatory left ventricular concentric hypertrophy; this adaptation maintains normal wall stress and cardiac output in the face of increased systolic pressure from the stenotic valve. As the disease progresses and the valve further narrows, the left ventricle becomes less compliant, and diastolic dysfunction can develop, which can lead to symptoms as well as eventual systolic dysfunction. Shortness of breath occurs due to increased filling pressures during exercise as well as failure of cardiac output to meet the body's demands. Angina in AS can occur due to underlying coronary disease (50% of patients with AS), increased myocardial oxygen demand due to increased left ventricular mass, or decreased oxygen supply due to compression of intramyocardial coronary arteries during prolonged systolic contraction, impaired diastolic relaxation (especially during tachycardia), and reduced coronary flow reserve.</p> |
| <ul style="list-style-type: none"> ■ What is the most likely diagnosis? | <p>In a patient with the classic triad of dyspnea on exertion, angina, and syncope, aortic stenosis (AS) is the first disease that should come to mind. Of course, each of these symptoms has its own differential diagnosis, but the presence of all three suggests AS. The physical exam findings of a delayed carotid upstroke, a sustained apical impulse, and a systolic murmur further support the diagnosis.</p> |
| <ul style="list-style-type: none"> ■ What are the next steps in management? | <p>In patients with suspected AS, an echocardiogram is an essential diagnostic tool that can assess the degree of valvular stenosis and the peak and mean gradients across the valve, which can help calculate the valve area. Patients with symptomatic AS or a critical valve area < 0.8 cm² should be referred to a cardiac surgeon for valve replacement, as mortality from AS after symptoms have appeared is approximately 90% within 3 years without valve replacement</p> |
| <ul style="list-style-type: none"> ■ What is the main surgical consideration, and how does it affect long-term treatment? | <p>The primary consideration is which type of valve to use: mechanical or bioprosthetic. Mechanical valves, in general, result in better outcomes; they are preferred in patients with expected long life spans, those with a preexisting mechanical valve in a different location, those already requiring warfarin therapy due to thromboembolism risk factors, and those < 65 years old. A bioprosthetic valve, however, is preferred in patients who cannot or will not take warfarin and those > 65 years old who have no thromboembolic risk factors.</p> |
-

► **CASE 14**

A 40-year-old man with a history of hypertension presents to the clinic for his annual checkup. He denies recent complaints, and his history and physical examination are unremarkable except for a blood pressure of 150/90 mm Hg. He currently takes hydrochlorothiazide for his hypertension. He is found to have a total serum cholesterol of 250 mg/dL, low-density lipoprotein (LDL) cholesterol of 200 mg/dL, and high-density lipoprotein (HDL) cholesterol of 50 mg/dL on a routine fasting lipid profile. He has no family history of coronary artery disease and does not smoke.

■ **What is the epidemiology of this condition?**

Hypercholesterolemia is one major modifiable risk factor for coronary artery disease, which is associated with approximately one-half of all deaths in men and women over age 65. Hypercholesterolemia is a subset of “dyslipidemia,” which can be defined as a total cholesterol, LDL cholesterol, triglyceride, apo-B, or Lp(a) concentrations above the ninetieth percentile, or HDL cholesterol or apo A-1 concentrations below the tenth percentile of the general population.

Hypercholesterolemia can be defined as a serum total cholesterol > 200 mg/dL on two separate occasions, an LDL cholesterol > 130 mg/dL, or an HDL cholesterol < 30 mg/dL. The prevalence of dyslipidemia is as high as 80% in individuals with “premature” coronary artery disease (occurring before age 55 in men and before age 65 in women), compared with up to 48% of age-matched controls. All patients > 20 years old should have a fasting lipid profile conducted every 5 years.

■ **What are the secondary causes of this condition?**

- Alcoholism
 - Cushing’s disease
 - Diabetes mellitus
 - Diuretic use
 - Familial hypercholesterolemia
 - Hepatic disease
 - Hypothyroidism
 - Obesity
 - OCP use
 - Nephrotic syndrome
-

■ **What physical signs may be found in patients with severe forms of this condition?**

Xanthomas (eruptive nodules in skin over tendons), xanthelasmas (yellow fatty deposits in skin around eyes), and lipemia retinalis (creamy appearance of retinal vessels) are physical manifestations of severely increased LDL cholesterol or triglycerides.

■ **What is the most appropriate management for this patient to reduce his risk of morbidity and/or mortality?**

Management of hypercholesterolemia is based on the stratification of the patient’s risk for coronary artery disease; these risk factors include:

- Smoking
- Hypertension (on treatment, or > 140/90 mm Hg)
- HDL cholesterol < 40 mg/dL
- Family history of “premature” coronary artery disease in first-degree relatives
- Age > 45 in men or > 55 in women

HDL cholesterol > 60 mg/dL removes one point from the tally of risk factors. This patient has only one risk factor (hypertension), making his LDL cholesterol goal < 160 mg/dL. Because his current LDL cholesterol is 200 mg/dL, he is a candidate for both lifestyle change and lipid-lowering medication therapy, for example, statins.

► CASE 15

A 35-year-old black man with no significant past medical history presents to the outpatient clinic for a follow-up examination 4 weeks after he was noted to have a blood pressure of 150/80 mm Hg on a routine health maintenance examination. He has no complaints, takes no medications, and does not smoke or use alcohol or other drugs. His family history is significant for a father with high blood pressure and a maternal grandmother who died of breast cancer. His blood pressure on this visit is 150/90 mm Hg.

-
- | | |
|---|---|
| <p>■ What is the most likely diagnosis?</p> | <p>Primary (essential) hypertension. Hypertension is defined as a systolic blood pressure > 140 mm Hg or a diastolic blood pressure > 90 mm Hg on three separate measurements at least 2 weeks apart. Although this patient has only had two measurements, it is likely that he will have a third that satisfies the criteria for diagnosing hypertension. Although primary hypertension is technically idiopathic, and therefore a diagnosis of exclusion, it represents 95% of all cases of hypertension. Thus, it is reasonable for physicians to begin therapy for primary hypertension without undertaking a full workup for causes of secondary hypertension, especially if there is a family history of hypertension.</p> |
| <p>■ What risk factors are associated with an increased incidence of this condition?</p> | <ul style="list-style-type: none"> ■ Family history of hypertension or heart disease ■ High-sodium diet ■ Obesity ■ Older age ■ Race (blacks > whites) ■ Smoking |
| <p>■ What are common complications associated this condition?</p> | <p>Because hypertension is asymptomatic until complications develop, patients who do not receive regular medical care may develop the sequelae of untreated hypertension. Specifically, untreated hypertension leads to end-organ damage:</p> <ul style="list-style-type: none"> ■ Heart—hypertrophy, myocardial infarction, CHF ■ Brain—stroke, TIA ■ Kidney—chronic kidney disease, renal failure ■ Vasculature—peripheral vascular disease ■ Eye—retinopathy |
| <p>■ What is the most appropriate treatment for this patient?</p> | <p>The patient should return in 4–6 weeks for a third blood pressure measurement. If it is elevated, therapy is indicated.</p> <p>First-line therapy is lifestyle change, specifically weight reduction (to a BMI between 18 and 25 kg/m²), dietary change (begin a diet rich in fruits, vegetables, and low-fat dairy products), and sodium restriction, along with regular aerobic physical activity, moderation of alcohol consumption, and cessation of tobacco use. If lifestyle modification is inadequate, thiazide diuretics are inexpensive and effective first-line therapy for otherwise healthy patients.</p> <ul style="list-style-type: none"> ■ Population-specific approaches: <ul style="list-style-type: none"> ■ ACE inhibitor: diabetes, heart failure, post-STEMI, LV dysfunction. ■ β-blockers: post-MI, stable patients with heart failure. ■ α-blockers: benign prostatic hyperplasia. <p>Periodic surveillance tests of end-organ involvement (ECG and serum BUN/Cr) should be conducted, as well as periodic electrolyte monitoring of those on diuretics.</p> |
-

► **CASE 16**

A 60-year-old white man with a history of coronary artery disease, peripheral vascular disease status post-femoral artery–posterior tibial artery bypass grafting, osteoarthritis, and a 3-year history of hypertension presents to the clinic for a routine blood pressure check. He has had no complaints since his last checkup 6 months ago. He is taking hydrochlorothiazide, metoprolol, lisinopril, diltiazem, pravastatin, and aspirin. Vital signs include a temperature of 37.0°C (98.6°F), blood pressure of 160/95 mm Hg, pulse rate of 70/min, and respiratory rate of 10/min. His physical examination is notable for an abdominal bruit auscultated to the right of midline at the level of the umbilicus. Laboratory values are as follows:

Sodium: 140 mEq/L
Potassium: 4.1 mEq/L
Chloride: 98 mEq/L
Bicarbonate: 23 mEq/L
BUN: 22 mg/dL
Creatinine: 1.8 mg/dL
Glucose: 110 mg/dL

A magnetic resonance angiogram (MRA) is ordered, and shown in Figure 1-4.

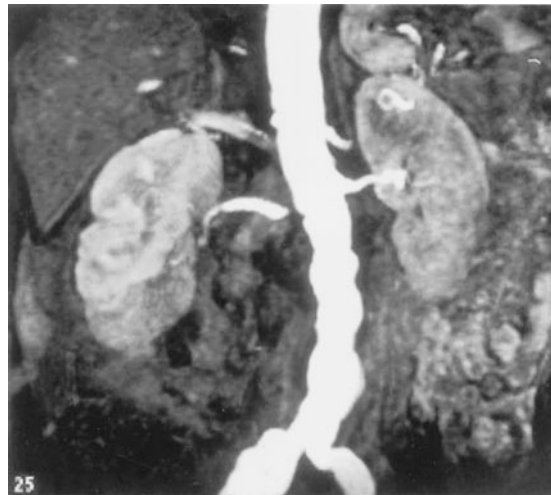


FIGURE 1-4. (Reprinted, with permission, from Brunicaudi FC, Andersen DK, Billar TR, Dunn DL, Hunter JG, Matthews JB, Pollock RE, Schwartz SI. *Schwartz's Principles of Surgery*, 8th ed. New York: McGraw-Hill, 2005: Fig. 22-83.)

■ **What conditions should be included in the differential diagnosis?**

In a patient > 50 years old with recent-onset hypertension, it is important to look for secondary causes of hypertension, especially if the high blood pressure is refractory to standard medical therapy (as in this patient) or uncontrolled after a period of being controlled. It is also important to determine if the patient is adhering to his or her medication regimen. The most common causes of secondary hypertension can be remembered by the mnemonic **CHAPS**:

- Cushing's syndrome
- Hyperaldosteronism
- Aortic coarctation
- Pheochromocytoma
- Stenosis (renal artery)

■ What is the most likely diagnosis?	In this patient with widespread atherosclerotic disease (coronaries, peripheral vasculature), recent-onset and refractory hypertension, a high serum creatinine, and a magnetic resonance angiogram (MRA) showing bilateral stenosis of the renal arteries (see Figure 1-4), renal artery stenosis is the most likely diagnosis.
■ What are the most common causes of this condition?	The two most common causes of renal artery stenosis are fibromuscular dysplasia (in female patients < 25) and atherosclerotic disease (in patients > 50).
■ What is the most appropriate treatment for this condition?	Therapy is generally recommended for patients with > 75% stenosis bilaterally. The recommended treatment in patients with hypertension refractory to medical therapy is percutaneous angioplasty with stenting. Open surgery is an alternative if angioplasty fails or there is a concomitant need for aortic surgery. In addition, all patients with atherosclerosis should be treated for this systemic disease, including coronary artery disease, peripheral vascular disease, and stroke prevention. Aggressive lipid management, with goals of LDL cholesterol of < 100 mg/dL, possibly even 70 mg/dL, should be considered.

► **CASE 17**

A 17-year-old cross-country runner presents to his primary care physician complaining of occasional chest pain (CP) and light-headedness during meets. He says that when he gets out of breath, he feels like he might pass out and his chest feels “tight.” After a thorough examination, the physician assures him that everything is okay but tells him that he should stay well hydrated and be careful not to run too hard in the heat. That afternoon, the patient returns to school and, after climbing stairs to reach his classroom, loses consciousness and falls to the floor. He quickly regains consciousness but is taken to the emergency room.

■ What is the most likely diagnosis?	Hypertrophic obstructive cardiomyopathy (HOCM) is characterized by thickening of the septal myocardium below the aortic valve. This is the most common cause of sudden cardiac death (SCD) in individuals < 30 years old. Symptoms include chest pain, dyspnea (most common), syncope, palpitations, and sudden death.
■ What is an ECG likely to show?	Up to 30% of asymptomatic patients have a normal ECG, but a normal ECG is very uncommon in symptomatic patients and is likely to show left axis deviation, tall R waves with widening of QRS, prominent Q waves in inferior and lateral leads.
■ What is the next step in diagnosis?	Echocardiography is the test of choice. All patients should undergo Holter monitoring and stress testing. Those with chest pain or dyspnea should be evaluated for inducible flow obstruction using Valsalva or amyl nitrate. Patients with severe symptoms should undergo cardiac catheterization.
■ Should this patient’s relatives be screened for this condition?	HOCM is autosomal dominant, and all first-degree relatives > 12 years old should automatically undergo screening. Children < 12 years should be screened if they are symptomatic or considered high risk.
■ What is the most appropriate management for this condition?	<ul style="list-style-type: none">■ Competitive sports, strenuous exercise, and dehydration should be avoided.■ Asymptomatic patients should not be treated medically.■ Patients with a history of chest pain or syncope:<ul style="list-style-type: none">■ β-blockers resolve CP and syncope in one-third of patients; no reduction in risk of SCD.■ Amiodarone reduces risk of SVT and life-threatening ventricular arrhythmias; may reduce risk of SCD.■ Nondihydropyridine calcium channel blockers may improve LV compliance and pressure gradients, reducing diastolic pressures and improving exercise tolerance.■ Disopyramide may be used if patients do not respond to β-blockers and calcium channel blockers.■ Severely affected patients with large pressure gradients who have failed medical therapy:<ul style="list-style-type: none">■ Surgical myotomy of intraventricular septum—symptomatic relief in 75% patients.
■ What five risk factors confer increased risk for SCD when present with this condition?	<ul style="list-style-type: none">■ Family history of SCD■ Syncope■ Nonsustained ventricular fibrillation■ Hypotension in response to exercise■ LV hypertrophy > 3 cm

- **Should all patients have an ICD placed for prevention of SCD?**

No. According to American Heart Association guidelines, the following groups should have ICD placed:

- History of single episode of SCD.
 - High-risk patients: two or more of the five major risk factors.
 - End-stage HOCM with LV dysfunction, thinning, and chamber dilation.
 - Single SCD risk factor: individualized decision process.
-

► CASE 18

A 77-year-old man is brought to the emergency department by his daughter after he developed weakness in his right upper extremity. She says that he has been sick for the past two weeks with fever, chills, and night sweats and that he has lost nearly 4.5 kg (10 lb) during that time. He had attributed these symptoms to the flu, but he could not move his left arm when he woke this morning. He denies other symptoms. On further questioning, his general health is good except for poorly controlled hypertension, and he underwent an aortic valve replacement 2 months ago. Physical examination is remarkable for upper left hemiplegia, the click of his prosthetic valve, and the image below on funduscopic exam. Vital signs include a temperature of 38.9°C (102.0 °F), blood pressure of 114/55 mm Hg, and pulse of 115/min.

- | | |
|--|--|
| ■ What is the most likely diagnosis? | Given the patient's history and physical findings, the most likely diagnosis is infective endocarditis (IE). |
| ■ What tests and/or imaging tools could be used to confirm the diagnosis? | <p>This diagnosis should be made by:</p> <ul style="list-style-type: none">■ Three blood cultures separated by at least 1 hour from different venipuncture sites.<ul style="list-style-type: none">■ Stable patients and those who have received prior antibiotics should not be treated empirically.■ Unstable patients should receive empiric treatment once these cultures are obtained.■ Echocardiography should be done in all patients with moderate suspicion of IE.<ul style="list-style-type: none">■ TTE should be attempted first in most cases. TEE should be used if TTE is nondiagnostic.■ ECG baseline should be obtained.■ Antibiotic treatment is organism specific and usually lasts 4–6 weeks for native valves and at least 6 weeks for prosthetic valves. |
| ■ What are the Duke criteria? | <p>These criteria are widely used to make the clinical diagnosis of IE. IE is considered present for (1) two major criteria, (2) one major and three minor criteria, or (3) five minor criteria.</p> <ul style="list-style-type: none">■ Major criteria:<ul style="list-style-type: none">■ Positive blood cultures × 2 for typical IE organisms.■ Echocardiography: oscillating intracardiac mass on valve or supporting structures, in the path of regurgitant jets, or on implanted material in the absence of an alternative anatomic explanation, or abscess, or new partial dehiscence of prosthetic valve or new valvular regurgitation.■ Minor criteria:<ul style="list-style-type: none">■ Predisposing heart condition or IV drug use.■ Temp > 38.0 °C (100.4 °F).■ Vascular phenomena: arterial emboli, mycotic aneurysm, intracranial bleed, Janeway lesions.■ Immunologic phenomena: glomerulonephritis, Roth's spots, Osler's nodes.■ Positive blood culture not meeting major criteria specifics.■ Echocardiographic findings not meeting major criteria specifics. |
-

- **What are the indications for prompt surgical intervention?**
 - Refractory CHF caused by new/worsening valve dysfunction.
 - Prosthetic valves—approximately 40% require surgery.
 - Perivalvular infection.
 - Uncontrolled infection.
 - *Staphylococcus aureus*.
 - Nearly all prosthetic valves should be operative.
 - Native aortic or mitral valve with TTE evident vegetations and remain septic during initial week of therapy.
-

► **CASE 19**

A 60-year-old man is brought to the emergency department with severe chest pain. He says it began about an hour ago while he was climbing stairs and has persisted, despite resting. He describes it as “tightness” in the center of his chest. He has been short of breath, nauseated, and sweating since the pain began. On questioning, he reports a history of similar pain brought on by exertion, but it usually resolves with rest. He also has a history of diabetes mellitus type 2, hypertension, and a 30-pack-year smoking history. His father and cousin both died of heart attacks in their seventies. He takes metformin, hydrochlorothiazide, and a multivitamin. Vital signs include a temperature of 37.0°C (98.6°F), blood pressure of 150/90 mm Hg, pulse rate of 100/min, respiratory rate of 15/min, and oxygen saturation of 99% on room air. Results of physical examination are unremarkable. X-ray of the chest reveals clear lungs with a normal-sized heart and mediastinum. An ECG is shown in Figure 1-5.

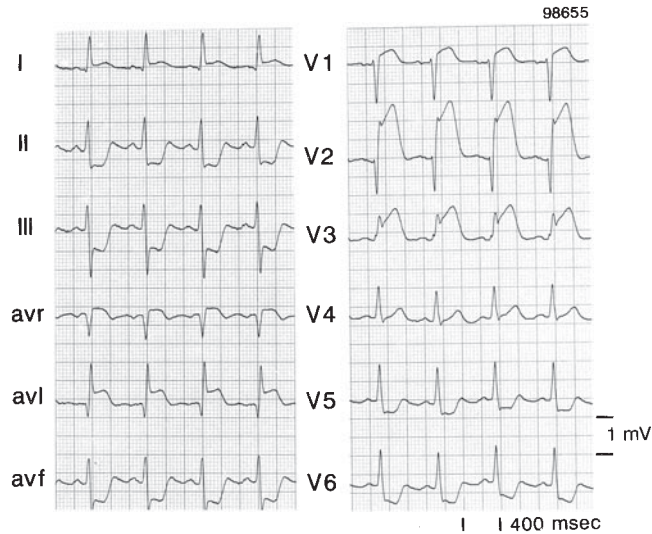


FIGURE 1-5. (Reproduced, with permission, from Fuster V, Alexander RW, O'Rourke RA, eds.; Roberts R, King SB III, Nash IS, Prystowsky EN, assoc. eds. *Hurst's The Heart*, 11th ed. New York: McGraw-Hill, 2004: Fig. 53.1.)

■ **What is the most likely diagnosis?**

In this patient with “tight” chest pain, diabetes, a history of angina, a family history of heart disease, and an ECG showing ST-segment elevation in leads V1–V3, aVL, and aVR (see Figure 1-5), the most likely diagnosis is an acute anterior wall myocardial infarction (MI). Note the “reciprocal” ST-segment depression in leads V5–V6, II, III, and aVF, which occurs frequently in transmural infarction.

■ **What is the most appropriate acute treatment for this condition?**

First steps include morphine, oxygen, nitrates, aspirin (MONA), heparin/LMWH and β -blockers (unless hemodynamically compromised). Patients with chest pain < 12 hours' duration, ECG evidence of ST elevation in contiguous leads, and a history consistent with an acute coronary syndrome, with or without serum biomarkers of MI, should be triaged to either primary percutaneous coronary intervention (PCI) or thrombolytic therapy to establish reperfusion of the myocardium as quickly as possible.

- PCI is preferred over lytic therapy if the “door-to-balloon” time is < 90 minutes. A glycoprotein IIb/IIIa inhibitor and clopidogrel should be given.
- Coronary artery bypass grafting after acute MI is reserved for patients with refractory ischemia, triple-vessel or left main artery disease, cardiogenic shock, complications of PCI or mechanical complications of the MI, or if the patient has absolute contraindications to PCI or thrombolysis.

Also, hypokalemia and hypomagnesemia should be treated to prevent arrhythmic complications. This patient, and all diabetic patients, will also benefit from tight glycemic control in both the acute ischemic period as well as the long term.

■ **What are the complications associated with this condition?**

The most clinically significant complications of an acute MI include mechanical complications and arrhythmic complications. Mechanical complications, their diagnosis, and management are noted in Table 1-2.

TABLE 1-2. Diagnosis and Management of Mechanical Complications in Acute MI

COMPLICATION (Most Occur Within 5 Days)	DIAGNOSIS	MANAGEMENT
Left ventricular free wall rupture	Severe right heart failure/shock/death (full rupture with cardiac tamponade) or recurrent chest pain, nausea, restlessness, agitation, transient hypotension, ECG findings of pericarditis (partial or contained rupture).	ECG and echocardiogram, followed by pericardiocentesis. If aspirated fluid is blood, proceed to surgery immediately. Hemodynamic support with fluids, inotropes, pressors, intra-aortic balloon counterpulsation.
Interventricular septal rupture	Hypotension and new murmur, confirmed by pulmonary artery (PA) catheter or Doppler echocardiography.	Hemodynamic support with afterload reduction, and surgery.
Papillary muscle rupture	Hemodynamic compromise and new murmur, confirmed by PA catheter or Doppler echocardiography.	Hemodynamic support with afterload reduction, and surgery.

► **CASE 20**

A 57-year-old investment banker presents to the emergency department with crushing substernal chest pain radiating to his left jaw. A 12-lead ECG demonstrates tall R waves in V1–V3 and a normal axis; troponin levels were elevated. No murmur was appreciated on initial examination. He is given morphine, aspirin, nitrates, and Plavix and is placed on supplemental oxygen. He is then taken to the catheterization lab, where a drug-eluting stent is placed. After 4 days, he is feeling well and walking in the hospital hall with a medical student checking his pulse oximeter. After 2 minutes, the patient begins sweating and states that he does not feel well. He promptly loses consciousness and falls to the floor. The medical student calls for help, places the patient back on oxygen, checks the patient’s blood pressure and auscultates the patient’s chest. He hears a blowing holosystolic murmur that radiates throughout the precordium and rales as the patient breathes.

- **What is the most likely diagnosis?** Papillary muscle rupture following MI. Symptoms often include chest pain, acute hypotension, and pulmonary edema. A holosystolic murmur may be heard throughout the precordium. Echocardiography is the modality of choice for diagnosis; begin with TTE, but proceed to TEE if TTE is nondiagnostic. Afterload reduction with nitrates, nitroprusside, or an aortic balloon pump followed by prompt surgical intervention is essential.
- **What was the distribution of ischemic injury?** The ECG pattern described most likely represents a posterior infarct. The “mirror test” involves inverting the ECG, then reading the image as it appears in a mirror. Furthermore, papillary muscle rupture is much more likely to occur in the setting of a posterior MI because the posteromedial muscle has a single blood supply through the posterior descending artery, but the other muscles are supplied by both the LAD and LC arteries.
- **What are the characteristics of the major murmurs?** See Table 1-3 and Figure 1-6.

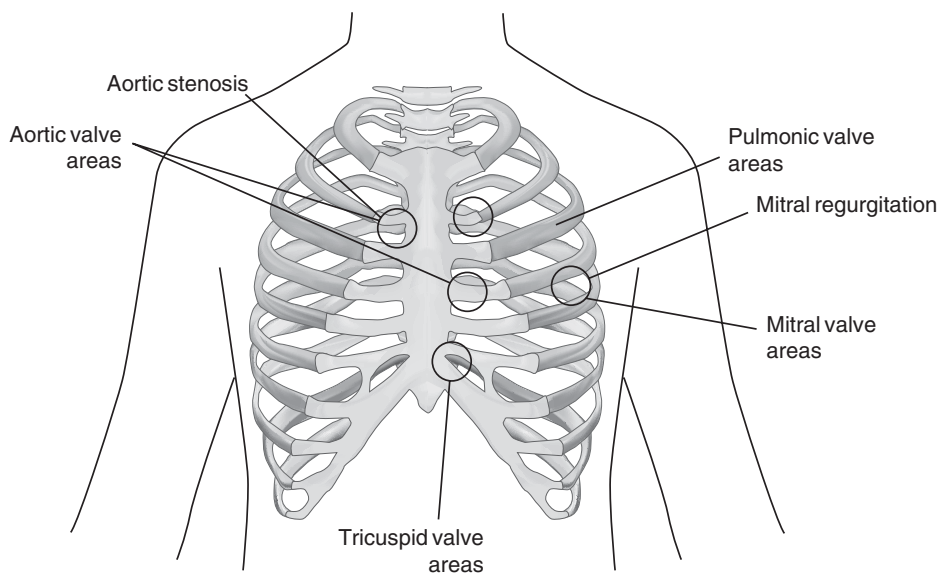


FIGURE 1-6. Sites of precordial auscultation for maximal cardiac valve sounds and murmurs. (Modified, with permission, from LeBlond RF, Brown DD, DeGowin RL. *DeGowin’s Diagnostic Examination*, 9th ed. McGraw-Hill, 2009: Fig. 8-18.)

TABLE 1-3. Major Cardiac Murmur Characteristics

MURMUR	TIMING	LOCATION	SPECIFIC SIGNS	+ VENOUS RETURN
Mitral regurgitation	Holosystolic	PMI	Handgrip	+
Tricuspid regurgitation	Holosystolic	R&L MSB	Inspiration (Carvallo's sign)	+
HOCM	Early/midsystolic	LLSB	- Handgrip	-
Mitral prolapse	Midsystolic	LLSB/PMI	+ Handgrip	-
Aortic stenosis	Midsystolic	RUSB	Crescendo-decrescendo	+
ASD	Late systolic		Fixed split S2	
VSD	Holosystolic	LLSB	+ Handgrip	
Aortic regurgitation	Early diastolic	LUSB	Squatting Valsalva Head bobbing Wide pulse pressure Decrescendo	
Pulmonic stenosis	Early systolic	LMSB	Inspiration Crescendo-decrescendo	
Mitral stenosis	Middiastolic	PMI in lateral decubitus	+ Opening snap with inspiration	
Tricuspid stenosis	Middiastolic	R&L MSB	- Opening snap with inspiration	
PDA	Continuous		Machinery murmur	

Increase afterload—handgrip.

Venous return—decreased by Valsalva, sit-to-stand. Increased by squatting, leg raise, inspiration.

LSB, lower sternal border; USB, upper sternal border; MSB, midsternal border; PMI, point of maximal impulse.

► **CASE 21**

A 55-year-old man comes to the emergency department complaining of sharp chest pain progressively worsened over the past day. He localizes the pain to the middle of his chest and describes it as a “9 out of 10” sharp pain that is worse with deep inspiration and lying flat; sitting forward seems to reduce the pain temporarily. He denies any medical history and takes no medications. Vital signs include a temperature of 38.0°C (100.4°F), blood pressure of 120/90 mm Hg, pulse rate of 95/min, respiratory rate of 12/min, and oxygen saturation of 99% on room air. His physical examination shows no jugular venous distention; clear lung fields; regular heart rate and rhythm without murmurs, rubs, or gallops; and no tenderness to chest palpation. His abdominal, extremity, musculoskeletal, and neurologic examinations are normal. X-ray of the chest reveals clear lungs with a normal-sized heart and mediastinum. An ECG shows diffuse ST-segment elevation with upward concavity and “reciprocal” PR-segment changes (PR depression in leads with ST elevation, and vice versa).

-
- **What is the most likely diagnosis?** Acute pericarditis. A chest x-ray with clear lung fields helps rule out pneumonia and pneumothorax. Patients with pericarditis with significant effusions may have the following signs (**PERIC**): **P**ulsus paradoxus, **E**CG changes, **R**ub (pericardial friction rub), **I**ncreased jugular venous pressure, and **C**hest pain.
-
- **What tests and/or imaging tools could be used to confirm the diagnosis?** Pericarditis is mainly a clinical diagnosis. However, a radiograph of the chest should be done to rule out other diseases that can present with similar chest pain, such as pneumonia and pneumothorax. An echocardiogram can be done to confirm a diagnosis of pericarditis by demonstrating pericardial thickening or a pericardial effusion. Although many patients with pericarditis do not have concurrent pericardial effusions, the presence of an effusion in a clinical presentation such as this one is very specific for pericarditis.
-
- **What risk factors are associated with an increased incidence of this condition?** Most cases of pericarditis are idiopathic but have presumed viral or autoimmune etiology. Other identifiable causes of pericardial disease include other infectious agents (bacterial, mycobacterial, fungal, and parasitic), radiation, neoplastic, postinfarction, trauma, rheumatic and nonrheumatic autoimmune diseases, drugs, and metabolic causes (uremia, hypothyroidism). The mnemonic **CARDIAC RIND** can be used to remember the major causes:
- Collagen vascular disease
 - Aortic dissection
 - Radiation
 - Drugs
 - Infections
 - Acute renal failure (uremia)
 - Cardiac (myocardial infarction)
 - Rheumatic fever
 - Injury
 - Neoplasms
 - Dressler’s syndrome
-

- **What is the most appropriate treatment for this condition?**

Treatment for pericarditis involves treating the underlying cause, as well as performing pericardiocentesis, if necessary, for large effusions or cardiac tamponade. In this patient, because there is no apparent cause for his clinical syndrome, further testing may include complete blood count (given the mild fever), antinuclear antibody titers, tuberculin skin testing, serology, and blood cultures. An ECG should also be obtained. Finally, during the workup, the pain of pericarditis can be treated with indomethacin if kidney function is normal. In cases of recurrent pericarditis, prednisone can be beneficial in a select population of patients with persistent pain such as those who have failed NSAID and colchicine (in general, use as a last resort as it can potentially lead to further recurrence).

► **CASE 22**

A 65-year-old man presents to his primary care physician with the chief complaint of leg pain. He notes that his buttocks and thighs ache bilaterally, left worse than right, when he walks more than a few blocks; the pain resolves with rest. He denies any history of trauma or problems with his joints; his past medical history is significant for a 40-pack-year smoking history and an acute myocardial infarction (MI) at the age of 61 years. When questioned, he admits to impotence beginning a few months prior to his MI. On physical examination, he is seated comfortably on the table in no acute distress. His heart and lung exams are within normal limits. His radial pulses are 2+ and symmetric, but his femoral and dorsalis pedis pulses are diminished bilaterally. The skin on his legs is cool to the touch and appears shiny, with very little hair growth. There is no swelling or erythema of his hip or knee joints.

■ What is the most likely diagnosis?	Intermittent claudication, due to peripheral vascular disease (PVD). Given his description of buttock and hip pain with associated impotence, he likely has aortoiliac occlusion, also known as Leriche's syndrome. His history of MI further supports a diagnosis of vascular disease. Intermittent claudication is frequently the presenting symptom of PVD, which can progress to rest pain and ischemia as arterial occlusion worsens. The location of the pain within the lower extremity reflects the location of the occlusion. Other conditions to rule out include osteoarthritis and "pseudoclaudication" due to lumbar spinal stenosis.
■ What tests and/or imaging tools could be used to confirm the diagnosis?	Doppler ultrasound can be used to detect occlusions of blood flow and to calculate the ankle-brachial index (ABI). The ABI is the ratio of the systolic blood pressure at the ankle and the arm. An ABI > 0.9 is normal; intermittent claudication occurs at values < 0.9, while rest pain typically occurs at values < 0.4. Ultrasound can often identify the location and extent of the occlusion, which is necessary if surgical interventions are planned. CT angiography with runoff can further delineate anatomical details prior to surgery.
■ What risk factors are associated with an increased incidence of this condition?	Risk factors for PVD are similar to those for coronary atherosclerosis and include diabetes mellitus, hyperlipidemia, cigarette smoking, hypertension.
■ What is the most appropriate treatment for this patient?	This patient, who does not have rest pain or evidence of ischemia, is a candidate for conservative management. This includes immediate tobacco cessation and control of underlying conditions, such as diabetes, hypertension, and hyperlipidemia. Exercise, as tolerated, promotes the development of collateral circulation. Antiplatelet agents, including aspirin, may also improve symptoms.
■ What are the treatment options for patients who fail conservative therapy?	Angioplasty and stenting may be helpful, depending on the location of the occlusion. Endovascular or open arterial bypass surgery can be used to restore distal blood flow. If ischemia and necrosis have progressed significantly, amputation of the affected area becomes necessary.
■ What is the natural history of this condition?	In a study of patients with intermittent claudication, 70–80% had stable symptoms, 10–20% had worsening symptoms, and 1–2% had critical ischemia at 5 years. However, 20% had a nonfatal MI or stroke, while 15–30% died from cardiovascular causes; atherosclerosis in the peripheral arteries is an important marker for atherosclerosis throughout the body, and these patients require a workup for coronary, carotid, and renal artery disease.

► CASE 23

A 69-year-old woman with a history of hypertension and rheumatic heart disease in childhood presents to the clinic complaining of worsening shortness of breath with exertion, fatigue, and occasional palpitations. On physical examination, she appears in no acute distress, and her vital signs include a temperature of 37.0°C (98.6°F), blood pressure of 140/80 mm Hg, pulse rate of 80/min, respiratory rate of 12/min, and oxygen saturation of 99% on room air. Her physical examination is remarkable for mild crackles in both lung fields bilaterally, a laterally displaced point of maximum impulse, a diminished S1, and a 3/6 holosystolic murmur heard best at the apex and radiating to the axilla. The murmur is reduced with Valsalva maneuver.

-
- | | |
|---|--|
| <p>■ What is the most likely diagnosis?</p> | <p>Mitral regurgitation (MR). In a patient with subacute or worsening dyspnea, fatigue, palpitations, and a systolic murmur, the two most important etiologies to consider are MR and aortic stenosis. The murmur of aortic stenosis usually occurs in early systole, radiates to the carotids, and is associated with a slow carotid upstroke; the murmur of MR is usually holosystolic, radiates to the axilla, and is associated with a “bounding” carotid pulse, similar to aortic regurgitation. Echocardiography is essential to confirm the diagnosis as well as to appropriately stage the disease (measuring ventricular diameter, flow velocities, extent of regurgitation, etc.).</p> |
| <p>■ What is the pathophysiology of the progression of this condition?</p> | <p>The mechanisms that cause symptoms include a dilated, eccentrically hypertrophied left ventricle that has remodeled to compensate for the increased volume load due to backward flow. This eventually results in systolic dysfunction and increased left atrial and pulmonary venous volumes. Left atrial enlargement can result in atrial fibrillation, as suggested by this patient’s palpitations.</p> |
| <p>■ What medical management options exist?</p> | <p>Patients with symptoms of mitral regurgitation benefit from acute vasodilator therapy (which reduces preload on the left ventricle, thereby reducing the “stretching” pressure on the mitral valve orifice) or β-blockers, calcium channel blockers, hydralazine, or diuretics to reduce afterload and encourage forward flow. However, as mentioned above, patients with chronic symptomatic MR should be referred for surgery. Additionally, patients with rheumatic MR and atrial fibrillation, or history of systemic embolization should receive anticoagulation. Patients with nonrheumatic MR should also receive anticoagulation, if they have atrial fibrillation or a history of embolization.</p> |
| <p>■ What surgical management options exist?</p> | <p>The surgical options in chronic mitral regurgitation include mitral valve repair (also known as mitral valve annuloplasty) and mitral valve replacement. Repair has been shown to have better outcomes than replacement, although replacement is indicated in the following situations:</p> <ul style="list-style-type: none"> ■ Extensive calcification or degeneration of a leaflet or annulus. ■ Prolapse of more than one-third of the leaflet tissue. ■ Active endocarditis. ■ Extensive chordal fusion, calcification, or papillary muscle rupture. |
-

► **CASE 24**

A 70-year-old man with a history of hypertension is brought to the emergency department by his wife after having a “fainting” spell 2 hours earlier. He denies any preceding light-headedness, nausea, diaphoresis, chest pain, palpitations, or confusion; his wife reports “he just collapsed and woke up 15 seconds later.” She denies witnessing any convulsive movements or any postictal symptoms. He has a history significant only for hypertension that is controlled with metoprolol. Vital signs include a temperature of 37.0°C (98.6°F), blood pressure of 125/70 mm Hg, pulse rate of 60/min, and respiratory rate of 10/min. His chest is clear, his heart examination reveals a regular rate and rhythm with no murmurs or gallops, he has normal bowel sounds, and has unremarkable extremity and neurologic examinations. An ECG taken on arrival is shown in Figure 1-7.

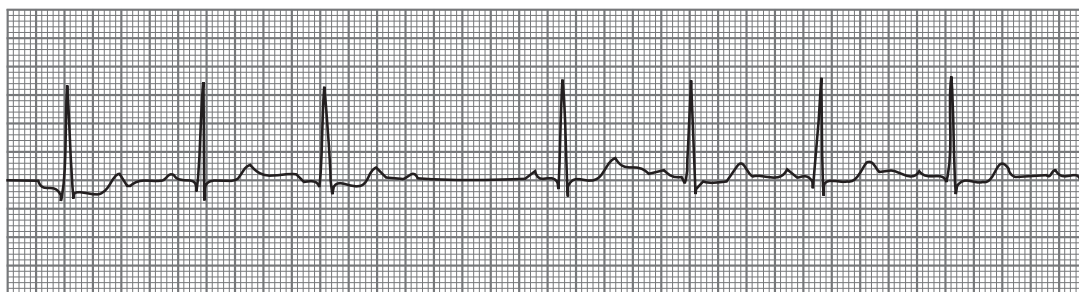


FIGURE 1-7. (Reproduced, with permission, from Hay WW Jr, Levin MJ, Sondheimer JM, Detering RR. *Current Pediatric Diagnosis & Treatment*, 17th ed. New York: McGraw-Hill, 2005: Fig. 19-11.)

-
- | | |
|--|--|
| ■ What is the most likely diagnosis? | Second-degree atrioventricular block (Mobitz type II). This type of bradyarrhythmia is defined by an electrocardiogram that shows normal PR intervals with P waves that intermittently fail to conduct to the ventricles, resulting in “dropped” QRS complexes, as this patient’s ECG shows. The failure of P waves to conduct to the ventricles can result in dizziness or syncope; faster heart rates can worsen the block, and maneuvers that slow the sinus rate may facilitate improved conduction. |
| <hr/> | |
| ■ How is this condition classified? | Atrioventricular block is classified into three groups based on electrocardiographic criteria: first degree (lengthened PR interval indicating slowed conduction, without missed ventricular beats), second degree (occasional missed beats, with or without PR interval prolongation), and third degree (complete conduction block with dissociation of atrial and ventricular activity). Second-degree heart block can be subdivided into two types: Mobitz type I (also known as Wenckebach), in which progressive PR elongation precedes a nonconducted P wave, and Mobitz type II, in which the PR interval remains unchanged prior to a nonconducted P wave. |
| <hr/> | |
| ■ What drugs are contraindicated in this condition? | Digitalis, calcium channel blockers (verapamil more than diltiazem), amiodarone, adenosine, and β -blockers can all slow AV conduction and cause or contribute to AV block; they should not be used in patients with second or third degree AV block in the absence of a pacemaker. |
-

■ **What is the pathogenesis of this condition?**

About half of the cases of atrioventricular block are caused by idiopathic, progressive fibrotic, and sclerodegenerative changes in the cardiac conduction system. These changes can affect only the AV node or the His-Purkinje system (causing first-, second-, or third-degree heart block), or a combination of conducting tissues, leading to left or right bundle branch block. Ischemic heart disease is the cause of about 40% of cases; 20% of patients with acute myocardial infarctions develop some kind of atrioventricular block, and approximately 10–20% develop bundle branch or fascicular blocks.

■ **What is the most appropriate treatment for this patient?**

The first step in management is searching for reversible causes of slowed conduction, such as ischemia, increased vagal tone, and drugs that slow conduction. Therefore, this patient should have an ECG and serial cardiac enzymes to evaluate for myocardial ischemia, especially if a new left bundle branch block is present. The first step in management should be to discontinue his β -blocker, as this may be the etiology of heart block. There are other medications that can be prescribed for hypertension that will not affect his conduction system. Finally, according to the ACC/AHA/NASPE guidelines for permanent pacemaker indications, symptomatic high-degree atrioventricular block may be treated with permanent pacemaker placement.

► **CASE 25**

A 45-year-old man with no significant medical history is brought by his wife to the emergency department (ED) complaining of a fainting episode earlier that morning after breakfast. He reports no memory of the event; he says he was getting up from the table, and the “next thing he knew” he was lying on the kitchen floor. His wife reports he was unconscious for about 15 seconds. He denies other symptoms, including prodromal light-headedness, nausea, vision changes, diaphoresis, chest pain, shortness of breath, or vertigo. His wife denies witnessing any convulsive movements and denies any signs of confusion in her husband following the episode. The patient admits to recently increasing his caffeine intake to two cups of coffee per morning. Vital signs include a temperature of 37.0°C (98.6°F), blood pressure of 120/80 mm Hg, pulse rate of 110/min, and respiratory rate of 10/min. His physical examination is notable for a regular tachycardia without murmurs, rubs, or gallops, and unremarkable HEENT, lung, and neurological examinations. His 12-lead ECG from the ED and from his outpatient clinic 2 weeks ago are shown as Figures 1-8 and 1-9, respectively.

-
- | | |
|--|---|
| ■ What conditions should be included in the differential diagnosis? | This patient’s syncopal episode can be explained by a sudden reduction in cardiac output resulting from a cardiac dysrhythmia. The differential diagnosis of narrow-complex tachycardias includes sinus tachycardia, atrial fibrillation, atrial flutter, multifocal atrial tachycardia, atrioventricular nodal reentrant tachycardia (AVNRT), atrioventricular reciprocating tachycardia (AVRT), and paroxysmal atrial tachycardia; these can be subdivided into regular and irregular. |
| ■ What is the most likely diagnosis? | This ECG shows retrograde P waves after QRS (Figure 1-9). Both AVRT and AVNRT have retrograde P waves, but AVNRT usually has a pseudo R wave in V1 which is actually the p wave buried in the terminal portion of the QRS. Also, the R-P interval with AVRT is long because retrograde conduction to the atrium is via the AV node, which conducts slowly; the opposite is true for typical AVNRT which is the more common form of AVNRT, AVRT is most likely . In addition, the old ECG (Figure 1-8) shows a Wolff-Parkinson-White (WPW) pattern of abnormal ventricular activation (“pre-excitation”), as evidenced by the widened QRS complex with a “delta”-wave and a short PR interval best seen in V5 and V6. |
| ■ What is the pathophysiology of this condition? | The presence of a “tract” that connects the atria to the ventricles and bypasses the AV node is a setup for danger. Normally, the AV node “decrementally conducts”; that is, impulses take longer to conduct through the AV node at faster heart rates, a nicely self-limiting safety mechanism. A bypass tract can therefore potentially conduct fast arrhythmias (atrial fibrillation or flutter) directly to the ventricles in a 1:1 ratio, leading to life-threatening ventricular rates of 300 bpm or greater. WPW syndrome is the combination of ventricular pre-excitation (earlier ventricular activation due to the bypass tract) with paroxysmal tachyarrhythmias that produce syncope or presyncope. |
-

- What are the possible pharmacologic and nonpharmacologic treatments for this patient?

Patients with only the WPW pattern (preexcitation delta waves on ECG) are not treated unless their livelihood, mental well-being, insurability, or the public safety would be affected by a spontaneous tachyarrhythmia or ECG abnormality. For primary drug therapy, amiodarone can be used chronically in patients with a limited life expectancy or with contraindications to catheter ablation. Of note, AV nodal blockers are contraindicated in patients with WPW and atrial fibrillation or some wide-complex tachycardias, given that blockade of the AV node may lead to preferential conduction down the bypass tract

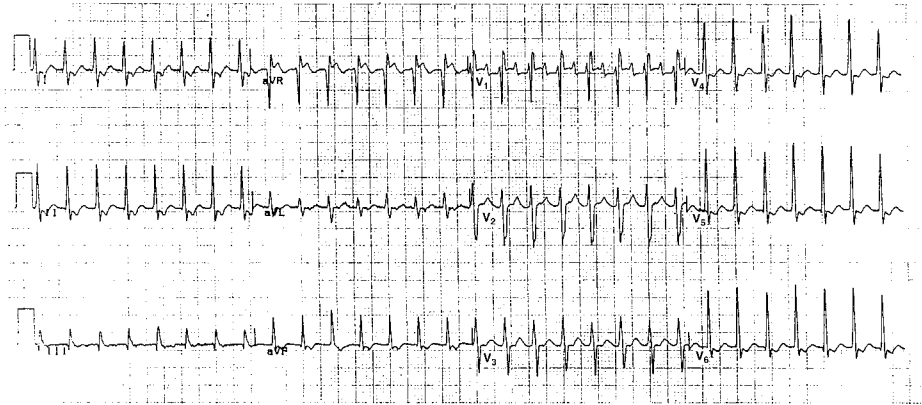


FIGURE 1-8. (Reproduced, with permission, from Crawford MH. *Current Diagnosis & Treatment in Cardiology*, 2nd ed. McGraw-Hill, 2003: Fig. 19-11A.)

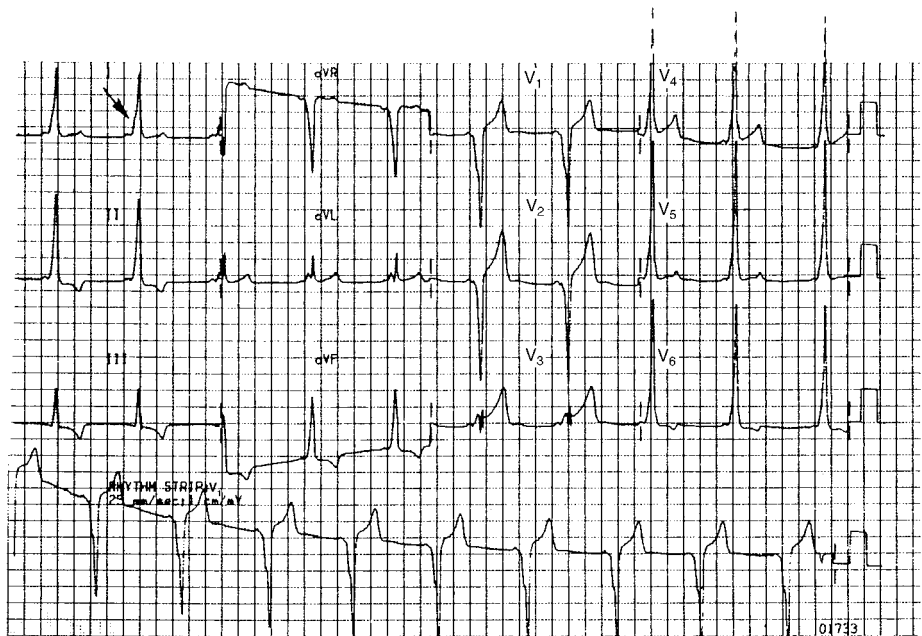


FIGURE 1-9. (Reproduced, with permission, from Crawford MH. *Current Diagnosis & Treatment in Cardiology*, 2nd ed. McGraw-Hill, 2003: Fig. 19-12.)

Dermatology

Case 1	44
Case 2	46
Case 3	47
Case 4	48
Case 5	50
Case 6	51
Case 7	52
Case 8	53
Case 9	54
Case 10	56
Case 11	58
Case 12	60
Case 13	62
Case 14	64
Case 15	66
Case 16	68
Case 17	69
Case 18	70

► **CASE 1**

A 32-year-old obese woman presents to her primary care physician's office for a preemployment physical. She states that she is in good health, but she has noticed darkening areas around her axillae and under her breasts. She first noticed the dark areas a few years ago but has not paid much attention to them. Her family history is remarkable for obesity, heart disease, hypertension, and type 2 diabetes mellitus. On physical examination, the patient is a well-appearing but obese female. Her blood pressure is 135/85 mm Hg, and her heart rate is 80/min. Her body mass index (BMI) is 32 kg/m². Examination of the skin shows prominent skin lines in the patient's axilla (Figure 2-1), posterior neck, and underneath her breasts. There are also dark, "dirty-appearing," velvety plaques in these regions.

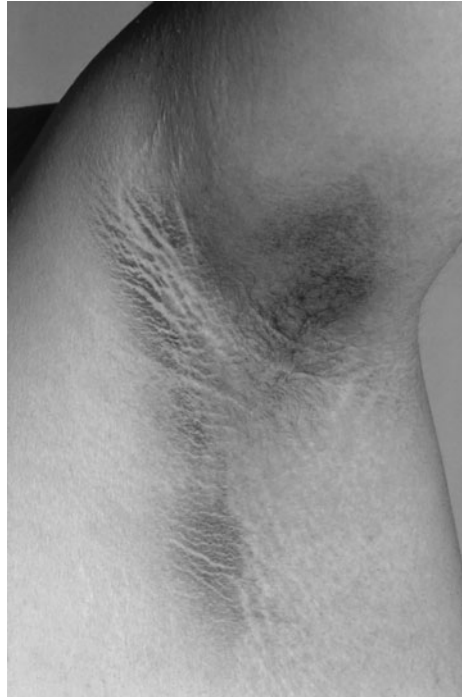

FIGURE 2-1. (Reprinted, with permission, from Wolff K, Johnson RA, Saurmond D. *Fitzpatrick's Color Atlas & Synopsis of Clinical Dermatology*, 5th ed. New York: McGraw-Hill, 2005: Fig. 5-1.)

-
- | | |
|---|---|
| ■ What is the most likely diagnosis? | Acanthosis nigricans (AN) is consistent with the appearance of thickened, dark, dirty-appearing, velvety plaques with prominent skin lines in flexural areas. Prevalence is equal among men and women but is much more common in persons with darker skin pigmentation. |
| <hr/> | |
| ■ How is this condition classified? | It is classified into two broad categories: <ul style="list-style-type: none"> ■ Benign (more common), which is usually associated with underlying diabetes or insulin resistance ■ Malignant (far less common), which is associated with an underlying malignancy |
| <hr/> | |
| ■ What is the pathophysiology of this condition? | It is mostly likely caused by factors that stimulate epidermal keratinocyte and dermal fibroblast production in the skin. In benign AN, the factor is believed to be insulin or insulin-like growth factor; in malignant AN, it is believed to be a factor produced by the tumor or in response to the tumor, possibly transforming growth factor- α . |
-

- **What other conditions are associated with this condition?**
- Adverse Drug Reactions
- Endocrine disorders:
 - Diabetes
 - Cushing's syndrome
 - **HAIR-AN** syndrome (**H**yper**A**ndrogenism, **I**nsulin **R**esistance, and **A**canthosis **N**igricans)
 - Insulin resistance (AN may predict the later development of type 2 diabetes)
 - Malignancy (usually gastrointestinal or lung cancers)
 - Obesity

■ **What test(s) should be done for a patient with this condition?** Patients with acanthosis nigricans should receive a fasting glucose test to rule out diabetes mellitus.

■ **What are the typical findings on skin biopsy?** The histological findings of acanthosis nigricans on skin biopsy are hyperkeratosis with proliferation of melanocytes.

■ **What is the most appropriate treatment for this condition?** The treatment of acanthosis nigricans is treatment of the underlying disorder. This includes weight loss for treatment of obesity and insulin resistance or searching for an occult malignancy.

► **CASE 2**

A 16-year-old boy presents to his pediatrician complaining of “pimples.” He first noticed the bumps on his forehead around the hairline a few weeks ago, and since that time, new groups have come and gone on his nose and also on both cheeks. The bumps vary in appearance, some about the size of a pencil point and black, while others are white, a little larger, and have a ring of red around them. He has tried washing his face more often, but that has not helped. He does not complain of any constitutional symptoms. On physical examination, the patient is anxious but well appearing, and has papules and pustules ranging in size from 1 to 3 mm over his forehead, cheeks, nose, and upper back around his shoulders. The papules are black and smaller than the pustules, ringed with a thin erythematous border, and painful when pressed.

■ What is the most likely diagnosis?	Acne vulgaris. This is a common skin disease characterized by non-inflammatory follicular papules (comedones) and by inflammatory papules, pustules, and nodules. It affects areas of the body that contain the highest concentration of sebaceous glands, mainly the face, upper chest, and back. A comedone can be a “whitehead” (closed comedone) or a “blackhead” (open comedone) without any signs of inflammation.
■ What is the pathophysiology of this condition?	The cause of acne vulgaris is multifactorial. Current research demonstrates that follicular epidermal hyperproliferation triggered by increased androgens, changes in skin lipid composition, and/or inflammatory cytokines play a role in acne outbreaks. Subsequent plugging of the follicle by excess sebum secretion leads to colonization by <i>Propionibacterium acnes</i> , which contributes to local inflammation.
■ What is the epidemiology of this condition?	Acne vulgaris affects a large proportion of the population (85–100%) at some point in life. However, men are more commonly affected initially during adolescence, and women are more commonly affected in adulthood. Prevalence is similar in African-Americans and Caucasians.
■ How is this condition classified?	Acne vulgaris is classified by the presence and severity of inflammation: <ul style="list-style-type: none">■ Comedonal: No inflammatory lesions present.■ Mild inflammatory: comedones, inflammatory papules.■ Moderate inflammatory: comedones, inflammatory papules, pustules.■ Nodulocystic: comedones, inflammatory papules, pustules, nodules greater than 5 mm in diameter, scarring often present.
■ What factors may contribute to an increased incidence of this condition?	Though external causes of acne vulgaris are rarely identified, medications such as steroids, lithium, some antiepileptics, and iodides can promote acne. Congenital adrenal hyperplasia, polycystic ovarian syndrome and other endocrine disorders that involve excess androgens may also promote development.
■ What tests and/or imaging tools could be used to confirm the diagnosis?	Acne vulgaris is a clinical diagnosis; however, female patients with dysmenorrhea or hirsutism require a formal hormonal evaluation. In patients without response to typical treatments (topical retinoids, topical antibiotics, benzoyl peroxide, and/or systemic tetracyclines) skin lesion culture to rule out gram-negative folliculitis is indicated.
■ What are possible complications of this condition?	<ul style="list-style-type: none">■ Physical pain from skin inflammation■ Psychological suffering related to poor self-image■ Severe inflammatory variants are associated with fever, arthritis, and other systemic symptoms
■ What is the prognosis for patients with this condition?	By age 25, 5% of men still have acne, while 12% of women do. By age 45, both sexes are at 5%. Therefore, the overall prognosis is good; however, long-lasting psychosocial impairment and skin scarring may be evident.

► **CASE 3**

A 13-month-old girl is brought to the pediatrician by her parents for itchy rashes on her arms, legs, and cheeks. The rashes appeared gradually over the past few weeks and seem to be worsening. Her skin has always been dry, and her parents have used baby lotion on her since she was a few weeks old. She has not had fevers or any recent illnesses. On physical examination, she has scaly, crusted, pink, ill-defined patches on the flexural surfaces of her arms and legs. Both cheeks are also red, with notable excoriations. The remainder of her examination is normal.

■ What is the most likely diagnosis?	Atopic dermatitis or eczema. This is a very common condition, which affects approximately 15% of children in the United States. Its association with other atopic disorders, asthma, and allergic rhinitis remains controversial.
■ How does patient age affect disease presentation?	<p>There are three distinct stages of the disease:</p> <ul style="list-style-type: none"> ■ Infantile: patients < 1 year have exudative, crusted patches on their extensor and flexural surfaces, cheeks, and scalp, while the diaper area is spared. ■ Childhood: patches have less exudate and are found in the flexural areas, especially the antecubital and popliteal fossae. ■ Adulthood: ~40% of patients clear the disease by adulthood; distribution is similar to childhood, but patches are more localized and lichenified.
■ What is the pathogenesis of this condition?	The most accepted theory of eczema is a break in the permeability of the epidermis, allowing antigenic agents to contact the body's immune cells and cause inflammation in the skin. Permeability depends on interactions between skin keratinocytes and structural proteins, including filaggrin; mutations in this protein are frequently found in eczema patients. These interactions also affect the skin's ability to hold water, which is impaired in eczema.
■ What conditions should be included in the differential diagnosis?	<ul style="list-style-type: none"> ■ Contact dermatitis ■ Seborrheic dermatitis ■ Drug reactions <p>In infants, other considerations include:</p> <ul style="list-style-type: none"> ■ Psoriasis ■ Scabies ■ Wiskott-Aldrich syndrome ■ Hyperimmunoglobulin E syndrome
■ What is the most appropriate long-term treatment for this condition?	Chronic treatment of eczema involves minimizing symptoms and preventing exacerbations. Trigger factors for these patients can include heat, perspiration, and low humidity, which should be avoided if possible. Bacterial and viral skin infections should be promptly treated. Pruritus can be minimized with antihistamines. Consistent skin hydration is also crucial. Patients should bathe once daily, pat their skin dry, and then immediately apply the strongest moisturizer they can tolerate (ointment > cream > lotion).
■ What is the most appropriate treatment for patients experiencing a flare?	Eczema flares involve increased inflammation of the skin. Initial treatment should include topical glucocorticoids, which are available in different potencies. High potency steroids are not used in the skin folds nor on the face, because of a high risk of atrophy. For patients who need prolonged therapy, topical calcineurin inhibitors (such as tacrolimus or pimecrolimus) can be used. Systemic immunosuppression may be necessary for those that fail topical therapy.

► **CASE 4**

A 56-year-old man presents to his dermatologist for evaluation of a lesion on his nose (Figure 2-2). He has had other similar lesions on his face that were treated with surgical excision. He is of Irish descent and has a long history of sun exposure from working as a farmer. On physical examination, the patient has clear evidence of sun damage and looks much older than his stated age. There are well-healed surgical scars on his forehead, nose, and left cheek. An erythematous, smooth papule with a translucent surface is observed on the left side of the patient's nose.

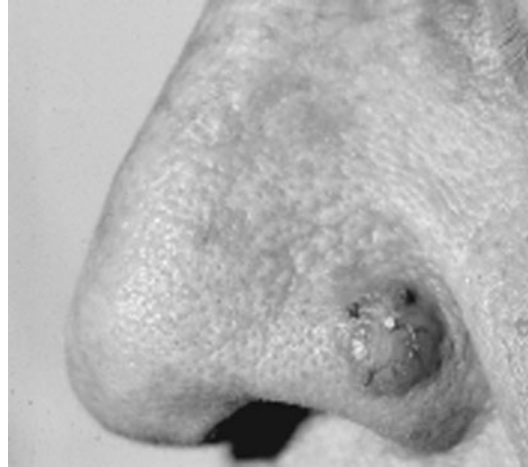


FIGURE 2-2. (Reproduced, with permission, from Wolff K, Johnson RA, Sturmond D. *Fitzpatrick's Color Atlas & Synopsis of Clinical Dermatology*, 5th ed. New York: McGraw-Hill, 2005: Fig. 11-11B.)

-
- **What is the most likely diagnosis?** Basal cell carcinoma (BCC). Basal cell carcinomas are the most common type of cancer. The nodular variant typically appears as a pearly colored papule, though the surface may appear translucent and fine telangiectasias may be present. They appear on sun-exposed areas of skin, are slow growing, and rarely metastasize.

 - **How is this condition classified?** There are a number of different subtypes of BCCs based on histopathology:
 - Nodular
 - Superficial
 - Sclerosing/morpheaformThis patient likely has a nodular BCC, the most common subtype.

 - **What is the epidemiology of this condition?** BCC affects all races and skin types, but is more likely to be found in individuals with fair skin. Historically, men are twice as likely to be affected as women, given greater overall sun exposure. Incidence increases with age, and those under 40 are uncommonly affected except in the presence of a genetic syndrome.

 - **What risk factors are associated with an increased incidence of this condition?** Risk factors for BCC include both environmental (chronic exposure to ultraviolet radiation/sunlight, chronic arsenic exposure, therapeutic radiation, past sunburns, and the use of tanning beds) and patient factors (fair skin, light-colored eyes, red hair, childhood freckling, northern European descent, older age, immunosuppression, and basal cell nevus syndrome).
-

■ **What conditions should be considered in the differential diagnosis?**

- Actinic keratosis
- Intradermal nevus
- Squamous cell carcinoma
- Basal cell carcinoma
- Seborrheic keratosis

■ **What are the typical findings on skin biopsy?**

Skin biopsy of a basal cell carcinoma reveals characteristic basophilic palisading cells with retraction.

■ **What is the most appropriate treatment for this condition?**

A variety of treatment options exist for BCC. Factors to consider in choosing the best treatment option include patient characteristics, tumor characteristics, and features of the various treatment modalities (i.e., cost, cure/recurrence rates, morbidity). The treatment options include both surgical and nonsurgical interventions. Surgical options include cryosurgery, electrosurgery, surgical excision, and Mohs' micrographic surgery. Nonsurgical options include radiation therapy, 5-fluorouracil cream, imiquimod cream, or photodynamic therapy.

► **CASE 5**

A 66-year-old man presents to his primary care physician complaining of recurrent outbreaks of blisters all over his body. The blisters slowly increase in size and become tense and pruritic. When the blisters break open, clear fluid drains. Painful erosions develop after the blisters collapse. On physical examination, the patient has multiple blisters in different stages concentrated mostly on his upper arms and thighs. There are a few erythematous plaques, a number of large, tense bullae, and scattered deep erosions and crusts. Nikolsky's sign is negative. He does not have any lesions on the mucous membranes.

■ What is the most likely diagnosis?	Bullous pemphigoid. Bullous pemphigoid is a chronic blistering disease characterized by prodromal erythematous edematous plaques that may develop into large, tense blisters filled with clear fluid. The collapsed bullae leave erosions and crusts. The condition is often more pruritic than painful, and the mucous membranes are rarely involved. Nikolsky's sign (separation of the outer layer of the epidermis when lateral pressure is applied to the skin) is negative.
■ What is the epidemiology of this condition?	Bullous pemphigoid has been reported to affect all age groups but occurs far more commonly in persons aged 60 and older. Since it is so uncommon, its frequency is unknown, though it probably affects men and women equally without predilection for race.
■ What is the pathophysiology of this condition?	Bullous pemphigoid is caused by IgG autoantibodies that bind the BP1 and BP2 proteins present in hemidesmosomes in the skin basement membrane. This activates complement and inflammatory mediators. Immune cells attracted to the area release proteases that degrade hemidesmosomes and lead to blister formation.
■ What test could be used to confirm the diagnosis?	The diagnosis of bullous pemphigoid is confirmed by direct immunofluorescence (DIF). Immunostaining a skin biopsy specimen in bullous pemphigoid demonstrates IgG and complement C3 deposition in a fluorescent linear band at the dermal-epidermal junction.
■ What are the treatment options for this condition?	Treatment is aimed at reducing the inflammatory response and autoantibody production. For mild cases, topical steroids may be used, but more severe cases may require systemic steroid therapy. Systemic steroid-sparing agents such as azathioprine, mycophenolate mofetil, cyclophosphamide, or methotrexate may be used in combination with oral prednisone. For patients who are unable to tolerate systemic steroids, azathioprine, dapsone, or tetracycline plus nicotinamide may be used.
■ What adverse events are associated with treatment?	There are several conditions related to the long-term use of immunosuppressants: secondary skin infections, malignancy, bone marrow suppression, growth retardation (in children), adrenal insufficiency, and osteoporosis.
■ What is the prognosis for patients with this condition?	Patients require treatment from 6 to 60 months, after which long-term remission is likely. Most mortality occurs secondary to effects of the medications. Also, these medications may exacerbate comorbid conditions such as hypertension, diabetes mellitus, and heart disease that commonly affect this population.

► **CASE 6**

An 18-year-old man presents to his primary care physician for his annual checkup. Before leaving the office, he complains of a few bumps near his lips that cause him significant pain. He recalls a strange tingling and burning sensation near the left corner of his lips that occurred a week ago. A few days later, he saw a small group of bumps appear in the same area. Physical examination is normal except for small groups of 2-mm vesicles on an erythematous base around the left angle of his mouth.

■ What is the most likely diagnosis?	Herpes simplex infection (HSV-1 or HSV-2) causing herpes labialis. HSV-1 causes oral lesions in approximately 80% of cases and genital lesions in 20% of cases, while for HSV-2 the opposite is true. Herpes viruses can cause a variety of diseases, including gingivostomatitis, keratoconjunctivitis, encephalitis, genital disease, and newborn infection.
■ What is the epidemiology of this condition?	In the United States, antibodies to HSV-1 are found in 80% of the population, while antibodies to HSV-2 are found in 20%. For genital herpes, the incidence is 500,000–1,000,000 cases per year, with a prevalence of 40–60 million infected individuals.
■ What is the pathophysiology of this condition?	HSV-1 is spread by respiratory droplets or direct exposure to infected saliva. HSV-2 is transmitted by genital contact involving mucous membranes or intact skin. The virus causes cellular necrosis, with fluid build-up between the dermis and epidermis, creating vesicles. The fluid is then absorbed, a scab forms, and healing is completed without scarring. The virus travels from the site of infection to the sensory dorsal root and remains latent until a recurrent outbreak occurs; these are triggered by UV radiation, trauma, emotional or psychological stress, and immunosuppression.
■ What other symptoms are common in patients with this condition?	Many primary infections are asymptomatic; however, when symptomatic they are often more severe than recurrences. Prodromal symptoms include burning, itching, tingling, and pain prior to vesicle appearance. Symptoms that can occur with the outbreak of the lesion include fever, general malaise, headache, anorexia, myalgias, dysuria with genital lesions, and sore throat with oral lesions.
■ What tests and/or procedures could be used to confirm the diagnosis?	Depending on the type of infection caused by HSV, tests and procedures will differ. For skin lesions, a viral culture is typically more sensitive than a Tzanck smear; however, this can depend on the duration of viral shedding. For ocular involvement, a slit-lamp examination for dendritic keratitis should be done. If encephalitis is a concern, a lumbar puncture looking for lymphocytic pleocytosis and PCR for HSV DNA is useful.
■ What is the most appropriate treatment for this condition?	HSV medications inhibit the replication of viral DNA but do not cure the disease. For primary outbreaks of genital herpes and HSV encephalitis, acyclovir is used; however, it is not recommended for primary outbreaks of oral-labial herpes as seen in this patient. Topical 1% trifluridine is used for herpes simplex keratoconjunctivitis. Recurrent outbreaks of oral-labial herpes may be treated with acyclovir, while daily suppressive doses of valacyclovir may be used for recurrent genital outbreaks.
■ What is the prognosis for patients with this condition?	There is a high recurrence rate for patients with genital HSV-2 infection. More than 85% of patients with one symptomatic episode will experience another.

► **CASE 7**

A 38-year-old woman presents to her primary care physician with a complaint of pain and bumps in both of her armpits. The bumps have come and gone over the past several months and are red, warm, and painful to the touch. She has also noticed intermittent drainage and has tried applying several over-the-counter creams and baby powder to the area, without improvement. On physical examination, she is an obese woman with a body mass index of 35 kg/m² and is profusely sweating, with stains on her shirt about her axillae. Her exam is otherwise normal except for multiple raised, hard nodules in her axillae bilaterally that cause the patient considerable pain and drain a thick yellow liquid when pressed.

■ What is the most likely diagnosis?	Hidradenitis suppurativa. This is a chronic condition characterized by painful swollen nodules in areas of the body where apocrine sweat glands are located (axillae, areola of the nipple, groin, perineum, circumanal, and periumbilical regions). It is a chronic acneiform infection of the apocrine glands that can involve surrounding cutaneous tissue and fascia.
■ What is the epidemiology of this condition?	Hidradenitis suppurativa is a relatively common disorder thought to affect 1–2% of the population. Females are more commonly affected than males (4:1 or 5:1 ratio). Ingrown hairs are a predisposing factor, so individuals with tightly curled hair tend to be affected more frequently.
■ What is the pathophysiology of this condition?	Hidradenitis suppurativa results from a follicular occlusion that blocks drainage from the apocrine glands and causes perifolliculitis. Therefore, it is a disorder of the terminal follicular epithelium located in areas rich in apocrine glands.
■ What risk factors are associated with an increased incidence of this condition?	Hidradenitis suppurativa is associated with excessive heat, perspiration, tight clothing, obesity, cigarette smoking, stress, and probable genetic disposition. There is also an association with Graves' disease and Hashimoto's thyroiditis.
■ What are the typical laboratory findings in this condition?	Culture of the exudate will yield a variety of saprophytic and pathogenic bacteria, with a large proportion of staphylococci and streptococci.
■ What is the most appropriate treatment for this condition?	For large, painful, fluctuant nodules, incision and drainage may be necessary if the lesion does not open spontaneously; however, most will resolve on their own. General surgery consultation is appropriate for the removal of sinus tracts, curettage, or exteriorization of the gland. For severe cases, skin grafts may be considered. Appropriate antibiotics should be given if cellulitis is suspected or if the patient is febrile. Admission to the hospital is warranted if the patient appears toxic.
■ What is the prognosis for patients with this condition?	While individual lesions usually heal in 10–30 days, with or without drainage, recurrence is common, and progressive scarring and sinus tracts may develop. Spontaneous and complete resolution occurs in only rare cases.

► **CASE 8**

A 24-year-old new patient presents to a local clinic for evaluation of a dark spot on the roof of her mouth. She first noticed the discoloration while she was brushing her teeth, but she does not remember exactly when it first appeared. It does not itch nor cause her any pain or trouble eating. Her family history is unremarkable; however, she has been working as a sex worker since the age of 18 and does not routinely use a condom for protection. The patient appears comfortable, with a heart rate of 90/min, respirations of 12/min, and temperature of 37.0° C (98.5° F). Her physical examination is normal except for a 2 × 2-cm, violaceous, slightly raised plaque on her rear right palate.

■ What is the most likely diagnosis?	Kaposi sarcoma (KS). This is a spindle cell tumor thought to be of endothelial cell lineage. It has a variable course ranging from minimal mucocutaneous disease to extensive organ involvement. It is strongly associated with human herpesvirus 8, which is transmitted in the saliva.
■ What is the epidemiology of this condition?	The incidence of KS was low in the United States before the AIDS epidemic, peaked in 1989, then declined to its current level, around 2500 cases per year. Incidence remains highest in African-American males.
■ How is this condition classified?	<ul style="list-style-type: none"> ■ Epidemic/AIDS-related: occurs in advanced HIV infection and is the most common presentation. Most clinically aggressive form. ■ Immunocompromised: occurs following solid-organ transplant or aggressive immunosuppression; rare but more common in patients at risk for classic form. ■ Classic/sporadic: occurs primarily in men of Mediterranean and Eastern European background with an age of onset at 50–70 years old; has a protracted and indolent course. ■ Endemic: occurs primarily in men but also in women and children who are HIV seronegative in Africa; may have indolent or aggressive course.
■ What conditions should be included in the differential diagnosis?	<ul style="list-style-type: none"> ■ Bacillary angiomatosis ■ Hematoma ■ Purpura ■ Dermatofibroma ■ Hemangioma
■ What test and/or procedure could be used to confirm the diagnosis?	Patients suspected of being infected with KS should have an HIV test, followed by a CD4 count and viral load if positive. A biopsy of the affected area will be necessary to establish a definitive diagnosis.
■ What is the most appropriate treatment for this condition?	For HIV patients, the initiation of HAART is paramount and has been shown to significantly change the clinical course of KS. Radiation, laser or cryotherapy is suitable for local therapy in individuals who have cosmetically unacceptable lesions or have locally advanced symptomatic disease; however, these therapies do not stop new lesions from forming. Chemotherapy and cytokine therapy is used for symptomatic or life-threatening visceral disease as well as rapidly progressive mucocutaneous disease.
■ What is the prognosis for patients with this condition?	Most patients with epidemic (HIV-associated) KS do not die of the disease, and patients on HAART tend to have an indolent course and recover spontaneously. Overall, morbidity may result from cosmetically disfiguring cutaneous lesions, lymphedema, gastrointestinal involvement, or pulmonary involvement. The most common cause of mortality is uncontrollable hemorrhage from pulmonary involvement.

► **CASE 9**

A 55-year-old woman with a history of hepatitis C infection presents to her primary care physician's office complaining of vulvar itching. On further questioning, she mentions that she has noticed lesions on both wrists. They are also pruritic but not as bothersome as the vulvar itching. On physical examination, sharply defined, flat-topped, polygonal, violaceous papules are observed on the flexor surface of the wrists. The surfaces of the lesions are shiny with fine white lines. Similar lesions are also seen on the vulva. Examination of the buccal mucosa reveals a white, lacelike pattern. A representative image of the wrist lesion is shown in Figure 2-3.

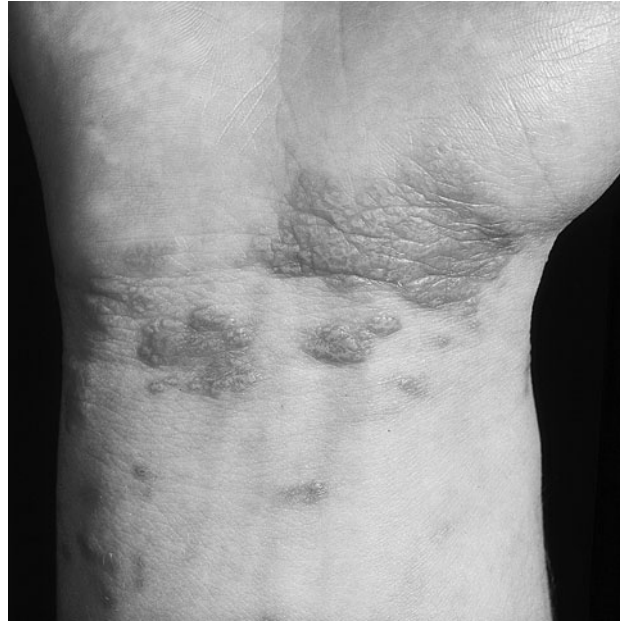

FIGURE 2-3. (Reproduced, with permission, from Wolff K, Johnson RA, Saurmond D. *Fitzpatrick's Color Atlas & Synopsis of Clinical Dermatology*, 5th ed. New York: McGraw-Hill, 2005: Fig. 7-4.)

■ What is the most likely diagnosis?	Lichen planus. Lichen planus is a cell-mediated inflammatory disease that involves the skin and mucous membranes.
■ What is the epidemiology of this condition?	Lichen planus has been reported in 1% of new patient visits at health clinics. It affects men and women equally and has no predilection for race. More than two-thirds of patients are aged 30–60 years, but it can affect any age.
■ What are the clinical manifestations of this condition?	Lichen planus is characterized by flat-topped, polygonal, sharply defined, pruritic, violaceous papules that are grouped together and confluent. The papules are generally found on the inner wrists and lower legs. A network of fine white lines on the surface of the papules or plaques (Wickham's striae) is also seen. The mucosal surfaces frequently display a reticulate white hyperkeratosis. The skin, nails, mucous membranes, vulva, and penis are the most commonly affected areas. Remember the "4 P's" of lichen planus: P olygonal, P urple, P ruritic P apules.

<ul style="list-style-type: none"> ■ What conditions should be included in the differential diagnosis? 	<p>The diagnosis of lichen planus is generally based on the clinical appearance of lesions in characteristic locations. Other similar conditions include:</p> <ul style="list-style-type: none"> ■ Drug-related lichenoid eruptions: the offending agent should be removed. ■ Chronic graft-versus-host disease: can produce a lichenoid reaction similar to lichen planus. ■ Secondary syphilis: the white, lacelike patterns on the buccal mucosa or genitalia are absent in secondary syphilis.
<ul style="list-style-type: none"> ■ What disease(s) are associated with this condition? 	<p>Lichen planus is strongly associated with hepatitis C viral infection, chronic active hepatitis, and primary biliary cirrhosis.</p>
<ul style="list-style-type: none"> ■ What are typical findings on skin biopsy? 	<p>The epidermis is hyperkeratotic, with irregular acanthosis and focal thickening in the granular layer. Degenerative keratinocytes known as Civatte bodies are found in the lower epidermis. Direct immunofluorescence reveals globular deposits of IgM and complement mixed with apoptotic keratinocytes.</p>
<ul style="list-style-type: none"> ■ What are possible complications from this condition? 	<p>Potential complications include a high rate of recurrence and possible neoplastic degeneration in oral lesions. Hypertrophic lesions may also leave residual areas of hyperpigmentation.</p>
<ul style="list-style-type: none"> ■ What are the treatment options for this condition? 	<p>Treatment options include topical steroids and oral antihistamines for the itch. In more severe cases, cyclosporine, oral retinoids, oral prednisone, or PUVA may be necessary.</p>

► **CASE 10**

A 4-year-old boy is brought to the pediatrician's office by his mother for "bumps" on the child's abdomen that have been present for over a month. The mother reports first noticing the lesions shortly after the child started attending day care. She has tried a variety of topical over-the-counter medications, but nothing has helped. She is concerned because the lesions seem to be increasing in number and spreading across the child's abdomen. The child is otherwise healthy. On physical examination, the child is well appearing. Multiple 2- to 5-mm dome-shaped, shiny papules, most with a central umbilication are observed on the child's abdomen (Figure 2-4). Two similar lesions are also observed around the child's left eye.

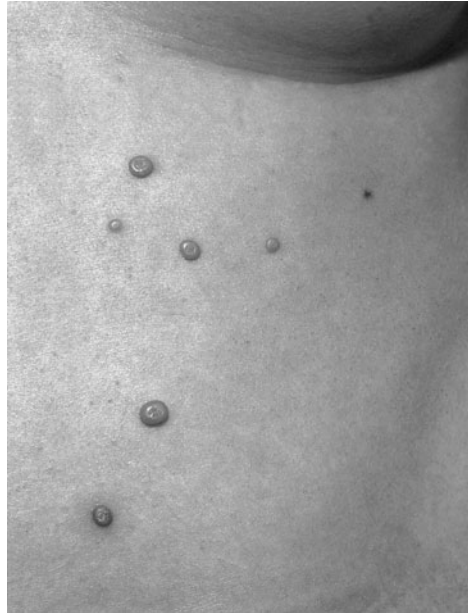


FIGURE 2-4. (Reprinted, with permission, from Wolff K, Johnson RA, Saurmond D. *Fitzpatrick's Color Atlas & Synopsis of Clinical Dermatology*, 5th ed. New York: McGraw-Hill, 2005: Fig. 25-1.)

-
- **What is the most likely diagnosis?** Molluscum contagiosum. Lesions of molluscum contagiosum are single or more often multiple rounded, dome-shaped, waxy papules 2–5 mm in diameter. They are umbilicated and contain a caseous plug. This condition is common throughout the United States and accounts for 1% of all skin disorders diagnosed; incidence is higher in HIV-infected individuals.

 - **What is the pathophysiology of this condition?** Molluscum contagiosum is caused by a poxvirus infection. Viral replication occurs within the cytoplasm, leading to characteristic intracytoplasmic inclusion bodies known as Henderson-Paterson bodies or molluscum bodies. The virus is spread by direct skin contact or by autoinoculation through scratching or touching a lesion.
-

■ How does this condition present?	In children, it commonly occurs on the trunk, arms, face, and legs, while in immunocompetent adults, lesions are generally found in the perianal and perigenital regions and are considered to be sexually transmitted. In immunocompromised children or adults with HIV/AIDS; for example, lesions tend to be larger, more numerous, and more widespread.
■ How is the diagnosis made?	The diagnosis is generally clinical and based on the characteristic appearance of the lesions. In addition, applying Giemsa or Wright's stain to the expressed contents of a papule reveals characteristic Henderson-Paterson bodies.
■ What are the treatment options for this condition?	In adults, treatment options include curettage, cryotherapy, or laser therapy though most lesions need only be treated for cosmetic purposes. Lesions in the genital regions should be treated to prevent further spread via sexual contact. In children, the chemical blistering agent cantharidin may be a better option due to its ease of application, although it should not be used around the eye. HIV/AIDS patients should be placed on antiretroviral therapy as well to aid in eradication of the infection.
■ What is the prognosis for patients with this condition?	Molluscum contagiosum is generally a self-limited infection in immunocompetent individuals and should resolve in a few months with no sequelae. In HIV/AIDS patients, the infection may have a longer course and lead to superinfection and conspicuous cosmetic deformities with psychological effects.

► **CASE 11**

A 52-year-old man presents to his primary care physician complaining of sores in his mouth, axillae, and on his chest. He states that the sores on his chest and axillae start as blisters but tend to break open when rubbed or if pressure is applied to them. The patient also reports recent weight loss and overall malaise. His oral intake has been limited by pain. On physical examination, the patient is tired appearing with scattered erosions over his axillae and trunk. There are also visible erosions in the oropharynx. No bullae are observed. When pressure is applied to the skin with a sliding motion, the skin rubs off.

■ What is the most likely diagnosis?	Pemphigus. Pemphigus has three primary subtypes: vulgaris (the most common form, 70%), pemphigus foliaceus, and paraneoplastic pemphigus. It is an uncommon disease, with frequency depending on the population studied; mean age of onset is 50–60 years.
■ What is the pathophysiology of this condition?	Pemphigus is characterized by shallow, painful erosions and blisters on the skin and mucosal surfaces that easily rupture with friction or pressure (Nikolsky's sign). The disease is caused by autoantibodies against desmocollins and desmogleins (transmembrane desmosomal proteins) in the epidermis that disrupt cell-cell interactions and lead to blistering.
■ What are the typical skin biopsy findings in this condition?	Histopathology shows an intraepidermal blister, acantholysis, and suprabasal separation of the epidermis, leaving a row of basal cells attached to the basal membrane. Direct immunofluorescence staining of the skin biopsy reveals IgG autoantibodies surrounding the perimeter of the keratinocytes.
■ What conditions should be included in the differential diagnosis?	<p>In cases in which oral erosions predominate, the differential should include:</p> <ul style="list-style-type: none">■ Aphthae■ Erythema multiforme■ Herpes simplex virus■ Lichen planus <p>In cases in which widespread erosions predominate, the differential should include:</p> <ul style="list-style-type: none">■ Impetigo■ Pyoderma■ Toxic epidermal necrolysis■ Other bullous conditions (see Table 2-1)
■ What is the most appropriate treatment for this condition?	The lesions should be treated as burns, and the patient given oral steroids that must be continued to prevent recurrence of the disease. Other agents such as azathioprine or cyclophosphamide may be used in conjunction with steroids to decrease the steroid dose and lessen the side effects related to high-dose steroids. In severe cases, plasmapheresis may be required.

TABLE 2 - 1 . Differentiation of Pemphigus from Bullous Pemphigus

	PEMPHIGUS	BULLOUS PEMPFIGOID
Location	Mucous membranes, skin	Always the skin, usually the arms and thighs, rarely mucous membranes
Autoantibody target	Desmocollins, desmogleins	BP1 and BP2
Location of autoantibodies	Intercellular	Epidermal-dermal junction
Location of blister	Intraepidermal, shallow	Subepidermal, deep
Nikolsky's sign	Positive	Negative
Symptoms	Painful	Itchy

► **CASE 12**

An 18-year-old black man visits his primary care physician because of a rash he has noticed over the past few days that continues to spread. On further questioning, the man mentions he noticed a pinkish, oval area on his chest that first appeared 2 weeks prior. On physical examination, the patient is healthy and well appearing. Examination of his skin reveals a crop of small, oval macules with a peripheral rim of scale, scattered over the trunk in a “Christmas tree pattern.” The area where the first patch appeared has an area of central clearing with a cigarette paper–like scale. The patient’s rash is shown in Figure 2-5.

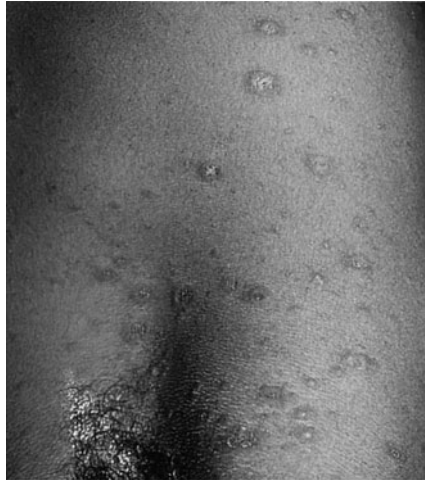

FIGURE 2-5. (Reproduced, with permission, from Kasper DL, Braunwald E, Fauci AS, Hauser SL, Longo DL, Jameson LJ, Isselbacher KJ, eds. *Harrison’s Principles of Internal Medicine*, 16th ed. New York: McGraw-Hill, 2005: Fig. 47-6.)

■ What is the most likely diagnosis?	Pityriasis rosea. Pityriasis rosea is an acute eruption thought to be viral in etiology.
■ What is the epidemiology of this condition?	Pityriasis rosea commonly occurs in clusters, with seasonal predilection to spring and autumn. It affects older children and young adults and is somewhat more common in females than males. It has a low rate of reoccurrence.
■ What is the natural history of this condition?	Pityriasis rosea generally begins with a “herald” patch. The herald patch is a single, round or oval, salmon-colored patch or plaque that appears on the neck, chest, or back several days or weeks before the rest of the lesions develop. The herald patch then becomes scaly with a cigarette paper–like scale and begins to clear centrally. Following the appearance of the herald patch, crops of smaller, oval macules or small patches begin to develop. These lesions generally appear over the trunk and proximal extremities. They generally spread from the top down. The symmetrical appearance of these lesions along cleavage lines gives rise to the description of this rash as a “Christmas tree pattern.”

<ul style="list-style-type: none"> ■ What conditions should be included in the differential diagnosis? 	<ul style="list-style-type: none"> ■ Secondary syphilis ■ Drug eruptions ■ HIV seroconversion illness ■ Lyme disease ■ Psoriasis ■ Tinea corporis
<ul style="list-style-type: none"> ■ Which viruses have been associated with this condition? 	<p>Human herpesvirus 6 and human herpesvirus 7 have been associated with this condition in some cases.</p>
<ul style="list-style-type: none"> ■ How is the diagnosis made? 	<p>The diagnosis of pityriasis rosea is relatively easy to make clinically. A history of a herald patch and the characteristic morphology and distribution of the skin lesions support the diagnosis. The lack of symptoms other than pruritus lends further support to the diagnosis of pityriasis rosea. All patients with suspected pityriasis rosea should have an RPR or VDRL serologic test to rule out syphilis.</p>
<ul style="list-style-type: none"> ■ What is the most appropriate treatment for this condition? 	<p>Treatment is generally not needed. Midpotency topical steroids can be used to control the itching. For more severe or refractory cases, phototherapy may be helpful.</p>

► **CASE 13**

A 19-year-old man presents to his primary care physician complaining of a rash on the extensor surfaces of his elbows and knees. The patient has no past medical history and is otherwise healthy. On physical examination, the patient's vital signs are normal. Well-demarcated, dark red plaques with silvery-white scales are present on the extensor surfaces of the elbows and knees bilaterally. Examination of the nails reveals the presence of pitting. A representative image is shown in Figure 2-6.

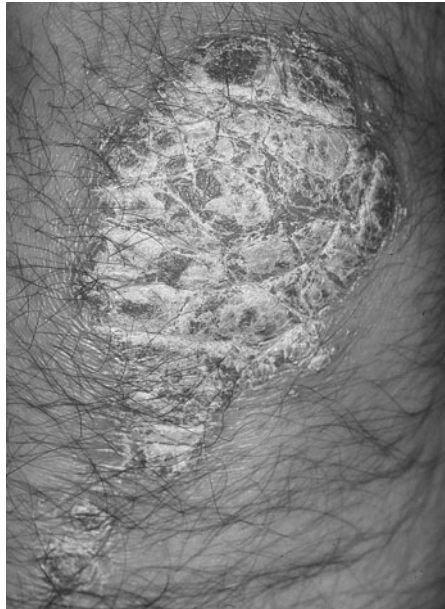

FIGURE 2-6. (Reproduced, with permission, from Wolff K, Johnson RA, Suurmond D. *Fitzpatrick's Color Atlas & Synopsis of Clinical Dermatology*, 5th ed. New York: McGraw-Hill, 2005: Fig. 3-2.)

-
- **What is the most likely diagnosis?** Psoriasis. Psoriasis is a chronic, noncontagious, multisystem, inflammatory disorder that manifests itself on extensor skin surfaces and tends to wax and wane depending on systemic and environmental factors such as stress and infection. Plaque psoriasis is the most common type, presenting with focal, raised, inflamed, edematous plaques on the scalp, trunk, and limbs, often covered with a silvery scale. Almost 20% of patients will have an oligoarticular arthritis.

 - **What is the epidemiology of this condition?** Psoriasis is a relatively common condition that affects 2–2.6% of the United States population. Caucasians are more commonly affected than African-Americans and women more than men, with a median onset at 28 years of age. It is also less common in the tropics as opposed to more northern climates.

 - **What is the pathogenesis of this condition?** Psoriasis is a T cell–mediated inflammatory disorder that leads to epidermal hyperproliferation. Various cytokines have been implicated in the pathogenesis, including TNF- α .
-

<ul style="list-style-type: none"> ■ How is the diagnosis made? 	<p>The diagnosis of psoriasis is typically made clinically by the characteristic findings on skin examination. Occasionally, a skin biopsy is necessary for a definitive diagnosis. The biopsy findings include acanthosis (increased thickness of the stratum spinosum), parakeratosis (retained nuclei in the stratum corneum cells), and Monro's microabscesses (collections of neutrophils in the stratum corneum).</p>
<ul style="list-style-type: none"> ■ What are the clinical subtypes of this condition? 	<ul style="list-style-type: none"> ■ Guttate psoriasis ■ Inverse psoriasis ■ Nail psoriasis ■ Plaque psoriasis ■ Pustular psoriasis ■ Erythrodermic psoriasis
<ul style="list-style-type: none"> ■ What is the most appropriate treatment for this condition? 	<p>Mild to moderate psoriasis can be treated with topical corticosteroids, topical calcipotrene, and adjuncts such as stress reduction, moisturizers, and salicylic acid as a scale-removing agent. Phototherapy may also be helpful. More severe cases of psoriasis should be treated with systemic agents such as methotrexate, acitretin, or cyclosporine. Immunomodulatory agents such as infliximab and etanercept are alternative choices for severe cases especially for those with arthritis.</p>

► **CASE 14**

A 35-year-old woman presents to the emergency department complaining of flulike symptoms, sores in her mouth, and a rash on her chest and arms. She also complains of painful skin. She denies any drug allergies, but she does report recently starting a new antiseizure medication for her epilepsy. On physical examination, the patient is febrile, with blood pressure of 125/85 mm Hg and pulse of 100/min. A symmetric eruption of targetoid patches, many with central vesicles, is present over the chest, arms, and face.

-
- **What is the most likely diagnosis?** Stevens-Johnson syndrome (SJS). Stevens-Johnson syndrome is an exfoliative mucocutaneous disease that may be life threatening. A Caucasian predominance has been reported, along with a male-to-female ratio of 2:1. Most patients are in their second to fourth decades of life.

 - **What is the pathophysiology of this condition?** The syndrome is an immune complex–mediated hypersensitivity disorder that can be caused by many drugs (penicillins, sulfas, and anticonvulsants), *Mycoplasma pneumoniae*, viral infections (HSV), or malignancies; it may also be idiopathic. Cell death results in separation of the epidermis from the dermis. The death receptor, Fas, and its ligand, FasL, as well as inflammatory cytokines have been linked to this disorder.

 - **How is the diagnosis made?** The diagnosis of SJS is primarily a clinical diagnosis made by the characteristic targetoid patches or plaques often studded with vesicles on less than 10% of the skin surface and mucous membranes. In more difficult cases, skin biopsy can be performed. The biopsy shows perivascular mononuclear infiltrates with eosinophils in the papillary dermis. Degeneration of the basal layer may also be seen with subepidermal blister formation in more severe cases.

 - **What possible complications are associated with this condition?** The major potential complications of SJS are fluid-electrolyte imbalances from transepidermal fluid losses. Superimposed bacterial infections may lead to sepsis and, in severe cases, death.

 - **What is the most appropriate treatment for this condition?** The patient should be treated similarly to a burn patient, with careful monitoring of fluid and electrolyte balance. Treatment of SJS depends on early diagnosis and removal of the offending agent or identification and treatment of the underlying disease. Corticosteroids should be used with caution, but may be helpful in early cases. In severe cases of SJS, intravenous γ -globulin may be used, although there is conflicting data on its efficacy.

 - **This condition is considered to be part of a continuum with two other conditions. How do all three conditions compare?** See Table 2-2.
-

TABLE 2 - 2. Erythema Multiforme, SJS, and Toxic Epidermal Necrolysis

	ERYTHEMA MULTIFORME	SJS*	TOXIC EPIDERMAL NECROLYSIS
% Body surface area involvement	< 10%	< 10%	> 30% or sheets of denuded skin
Cutaneous vs. mucosal involvement	Usually involves only skin	Involves skin and mucosa	Involves skin and mucosa

*Patients with 10–30% involvement are classified as having SJS-TEN overlap with intermediate prognosis.

► **CASE 15**

A 65-year-old man presents to his primary care physician complaining of severe pain on the left side of his trunk. In addition to the pain, he complains of a rash that extends from the right side of his midback to the right side of his abdomen. He reports feeling ill a few days prior to developing the rash. On physical examination, the patient appears uncomfortable and in pain. Examination of the skin reveals grouped vesicles on an erythematous base in a unilateral dermatomal distribution along the patient's trunk, as shown in Figure 2-7.

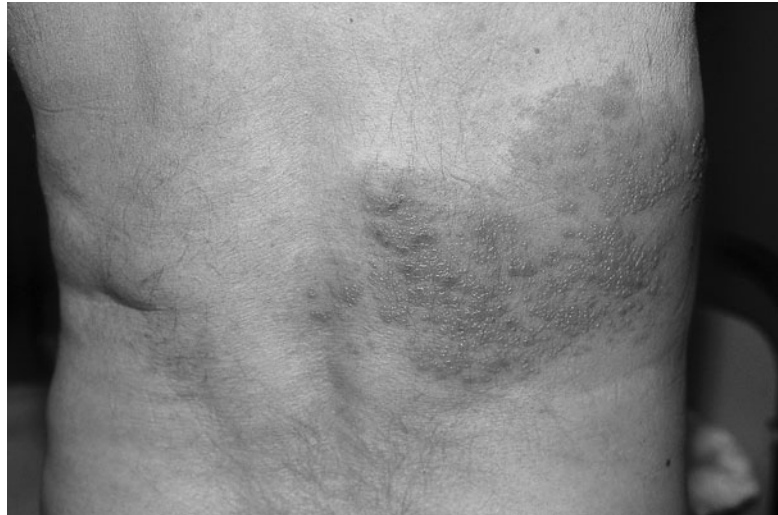

FIGURE 2-7. (Reproduced, with permission, from Wolff K, Johnson RA, Suurmond D. *Fitzpatrick's Color Atlas & Synopsis of Clinical Dermatology*, 5th ed. New York: McGraw-Hill, 2005: Fig. 25-41.)

■ What is the most likely diagnosis?	Varicella-zoster virus (VZV) infection (also known as herpes zoster or shingles). The virus is a double-stranded DNA virus of the Herpesviridae family.
■ What is the epidemiology of this condition?	The incidence of herpes zoster appears to increase with age, with the majority of cases occurring in individuals older than the age of 55. It has no predilection for race or gender; however, immunocompromised individuals are more susceptible to the condition. A herpes zoster vaccine for older adults has proven successful in reducing the incidence of disease.
■ What is the pathophysiology of this condition?	Primary infection with VZV occurs when contact with the mucosa of the respiratory tract or conjunctiva results in chickenpox. The virus then lies dormant in the sensory dorsal root ganglia. This dormancy may be permanent or may become reactivated during conditions of decreased cellular immunity, resulting in herpes zoster.
■ What are the clinical manifestations of this condition?	Reactivation leading to herpes zoster is characterized by a prodrome of fever, dysesthesias, malaise, and headache that precedes the vesicular eruption by a few days. Grouped vesicles develop unilaterally along any dermatome including the face; these lesions tend to crust over within 7–10 days at which point they are no longer infectious. Full resolution occurs in 3–4 weeks. Pain is the most common symptom and may both precede the rash and continue after it resolves for several months (postherpetic neuralgia).

■ **How is the diagnosis made?**

The diagnosis of herpes zoster should be made clinically. However, if the diagnosis is uncertain, a viral culture or Tzanck smear can be performed to look for multinucleated giant cells.

■ **What possible complications are associated with this condition?**

- Bacterial superinfection.
 - Herpes zoster oticus (Ramsay Hunt syndrome)—the triad of ipsilateral facial paralysis, ear pain, and vesicles in the auditory canal and auricle.
 - Meningitis.
 - Motor neuropathy.
 - Ocular complications (uveitis, keratitis) when the ophthalmic branch of the trigeminal cranial nerve is affected.
 - Postherpetic neuralgia.
 - Immunosuppressed hosts have an increased risk for severe complications related to VZV.
-

► **CASE 16**

A 15-year-old girl presents to a pediatric dermatologist with small pink papules over her nose and cheeks. She has had the papules for some time and has been treating them like acne. The papules have not resolved despite a number of different acne treatments. She also complains of a rough patch of skin on her lower back that she has had for as long as she can remember. On physical examination, multiple small, pink papules are observed in a nasolabial distribution on the face. A cobblestone textured plaque with an orange peel–like surface is observed on the lumbosacral region. A total of four hypopigmented, flame-shaped macules are scattered over the trunk and extremities.

-
- **What is the most likely diagnosis?** Tuberous sclerosis (TS). The physical findings of angiofibromas (the pink papules), a shagreen patch (connective tissue nevus with orange peel consistency), periungual fibromas, and three or more ash-leaf spots (hypopigmented macules) are consistent with a diagnosis of tuberous sclerosis. Tuberous sclerosis is one of the neurocutaneous syndromes (also included are neurofibromatosis 1 and neurofibromatosis 2). TS has a highly variable clinical course. The symptoms associated with TS are due to small, benign tumors that grow on many organs including the skin, eyes, brain, and kidneys.
-
- **What are some of the other clinical manifestations of this condition?**
- Neurologic: seizures, infantile spasms (seizures beginning in the first year of life), mental retardation.
 - Cardiac: rhabdomyomas.
 - Ophthalmologic: retinal lesions including mulberry tumors, phakomas.
 - Renal: hamartomas or polycystic disease.
 - Pulmonary: angiomyolipomas leading to cystic or fibrous changes.
-
- **What is the etiology of this condition?** TS is an autosomal-dominant condition, although only one-third of cases are familial. Spontaneous mutations or mosaicism account for the nonfamilial cases. TS is thought to result from mutations in either the TSC1 gene on chromosome 9q34 or the TSC2 gene on chromosome 16p13.3. TSC1 codes for the hamartin protein, while TSC2 codes for the tuberin protein. Tuberin and hamartin are thought to form a protein complex that acts as a negative regulator of the cell cycle.
-
- **What are the typical CT scan findings in this condition?** The classic findings on CT scan of the head of a patient with tuberous sclerosis are calcified tubers in the periventricular region. The tubers are considered hamartomatous in nature and may be referred to as glioneuronal hamartomas. The lesions may rarely transform into malignant astrocytomas.
-
- **What are the recommendations for follow-up of patients with this condition?** Patients with TS with no potentially serious problems should have annual follow-up visits that include physical examination, ophthalmic and funduscopic examinations, growth evaluation, assessment of development, and evaluation of school progress. Renal ultrasound should be performed at the time of initial diagnosis and every 1–3 years beginning at adolescence. CT scan of the abdomen or MRI should be performed if any major changes develop. Head CT or MRI should be performed every 1–3 years. Patients with an identified cardiac rhabdomyoma should be followed by cardiology.
-

► **CASE 17**

An 85-year-old man presents to his primary care physician with trouble walking. He states that over the past several weeks he has been having considerable pain around the toes of his right foot whenever he stands. This same pain makes it impossible for him to play in his daily racquetball matches with colleagues. Physical examination reveals a healthy-looking male who appears younger than his stated age. A powerful odor is present when he removes his athletic shoes. The rest of the exam is normal except for brown, thick, opacified nail plates on three of the five toes on his right foot that cause him pain when touched.

■ What is the most likely diagnosis?	Onychomycosis. Onychomycosis (OM) refers to a fungal infection that affects the toenails or fingernails. The fungus may involve any component of the nail unit, including the nail matrix, nail bed, or nail plate. Fortunately, this condition is not life threatening, but it can cause pain, discomfort, and serious physical and functional limitations.
■ What is the epidemiology of this condition?	The incidence of OM in North America is reported between 2–13%, with a recent increase that can be traced to a large immigration of dermatophytes, especially <i>Trichophyton rubrum</i> from West Africa and Southeast Asia. OM affects all races. Men are typically more affected than women; however, candidal infections affect women more often than men. Adults are 30 times more likely to have OM than children, with as many as 90% of cases occurring in elderly people.
■ How is this condition classified?	<ul style="list-style-type: none"> ■ Distal lateral subungual OM: most common form; thickened, opacified nail plate, discolored white to brown; subungual hyperkeratosis: onycholysis; edge of the nail becomes severely eroded. ■ White superficial OM: white speckled powdery patches on the nail plate; nail becomes roughened and crumbles easily. ■ Proximal subungual OM: nail plate becomes white proximally and normal distally; leukonychia in proximal nail fold. ■ Candidal OM: erythematous swelling of the nail fold or separation of the nail plate from its bed.
■ What risk factors are associated with an increased incidence of this condition?	Risk factors for OM include a family history, increasing age, poor health, prior trauma, warm climate, participation in sports or exercise, immunosuppression, communal bathing, or occlusive footwear.
■ What tests could be used to confirm the diagnosis?	Clinical features of OM are usually diagnostic; however, direct microscopy of a nail sample in KOH solution can help identify the presence of fungi. To identify the specific pathogen, a fungal culture can be prepared.
■ What is the most appropriate treatment for this condition?	Topical agents should only be used in patients unable to take systemic treatment; alone, these treatments are unable to penetrate all layers of the nail plate. Old oral medications such as griseofulvin and ketoconazole have been replaced with the more efficacious itraconazole and terbinafine, which penetrate the nail plate within days of starting therapy.
■ What is the prognosis for patients with this condition?	Studies suggest that a 75% cure rate is possible with oral medications, but this has been hard to measure. Regardless, fungal infections of the fingernails have a much more favorable prognosis than fungal infections of the toenails.

► **CASE 18**

A 52-year-old white man presents to the dermatologist after his wife noticed a dark, bleeding lesion on his back. The patient was unaware of the lesion until his wife pointed it out; she reports first noticing it a few months prior. The lesion has since changed shape, and she grew more concerned when she noticed it bleeding. The patient reports that he used to spend summers working as a lifeguard when he was much younger and rarely used sunblock. On physical examination, a 7-mm asymmetric macule with irregular borders and nonuniform color is observed on the right upper back.

■ **What is the most likely diagnosis?** Melanoma. A changing, asymmetric pigmented lesion with irregular borders, color variegation, and a diameter > 6 mm should make one think of melanoma. Lesions are commonly found on the trunk in men and on the legs in women. While accounting for 4% of all skin cancers, it accounts for 74% of all skin cancer deaths. Lesions generally occur as solitary lesions, and up to 50% arise from normal-appearing skin. The **ABCDEs of melanoma** stand for **A**symmetric shape, **B**order irregularities, **C**olor variegation, **D**iameter > 6 mm, and **E**nlargement.

■ **What risk factors are associated with an increased incidence of this condition?**

- Excessive sun exposure
- Sun-sensitive skin (fair skin)
- Family history of melanoma or dysplastic nevus syndrome
- Xeroderma pigmentosum
- Large number of nevi (common or atypical)
- Dysplastic nevi

The Fitzpatrick mnemonic for melanoma risk (**MMRISK**) is:

- **M**oles: atypical (atypical nevus) (> 5)
- **M**oles: common moles (numerous, > 50)
- **R**ed hair and freckling (often these persons have few or no moles)
- **I**nability to tan: Fitzpatrick skin phototypes I (always burns, never tans) and II (always burns, minimal tan)
- **S**unburn: severe sunburn, especially before age 14
- **K**indred: family history of melanoma

■ **What are the subtypes of this condition?**

- Superficial spreading: 70% of all melanomas.
- Nodular: arises rapidly, “blueberry-like” nodules.
- Acral-lentiginous: more common in males, Asians, and African-Americans. Appears on palms, soles, mucous membranes, and nails.
- Lentigo maligna: flat, “geographic shape,” occurs in sun-exposed areas.

■ **What test and/or procedure could be used to confirm the diagnosis?** When melanoma is suspected, an excisional biopsy should be performed to confirm the diagnosis. An incisional biopsy may be indicated for large lesions or if the suspicion for melanoma is low.

■ **What is the most appropriate treatment for this condition?** After the diagnosis is confirmed, the area should be re-excised with appropriate margins; the recommended margins are based on tumor thickness. Sentinel node biopsies are recommended for tumors ≥ 1 mm in thickness or with high-risk histology. Adjuvant therapy should be considered for patients with a high risk for metastatic disease. Optimal adjuvant therapy strategies are still being elucidated, but options include interferon- α or melanoma vaccines. Melanoma vaccines are being tested in clinical trials. Systemic chemotherapy should be initiated for metastatic disease.

Endocrinology

Case 1	72
Case 2	74
Case 3	76
Case 4	77
Case 5	78
Case 6	79
Case 7	80
Case 8	82
Case 9	84
Case 10	85
Case 11	86
Case 12	88
Case 13	89
Case 14	90
Case 15	92
Case 16	94
Case 17	96
Case 18	98
Case 19	100

► **CASE 1**

A 45-year-old man presents to his primary care physician accompanied by his wife complaining of recurrent headaches for the past 3 months. He has experienced at least two headaches a week and rates the pain 7–8 out of 10. The headaches occur at all times of the day. Sometimes the pain is accompanied by loss of peripheral vision; however, the patient notes that he has experienced vision loss in the absence of the headaches as well. This winter, he notes that neither his hat nor his gloves fit properly anymore. His wife mentions that he stopped wearing his wedding band last year because it began to cut off the blood supply. Vital signs include a blood pressure of 150/90 mm Hg, heart rate of 82/min, and respiratory rate of 14/min. His physical examination is remarkable only for the position of the point of maximal impulse, which is along the left midaxillary line at the level of the sixth rib.

- **What is the most likely diagnosis?** Acromegaly, which results from autonomous hypersecretion of growth hormone (GH). Overt symptoms commonly include enlargement of the extremities (Figure 3-1), tongue, and other connective tissues. However, the disease has numerous physiologic complications. The diagnosis is often missed, because extremely high GH levels can be associated with exercise prior to the test, a nonfasting sample, hepatic or renal failure, poor nutrition, diabetes, or treatment with estrogens, β -blockers, or clonidine. To remember the common symptoms and complications, think of the **ABCDEF** of acromegaly: **A**rthralgia/**A**rthritis, **B**lood pressure raised, **C**arpal tunnel syndrome, **D**iabetes, **E**nlarged organs, and **F**ield defect.

 - **What is the pathogenesis of this condition?** Acromegaly is caused by unregulated autonomous overproduction of GH by the somatotroph cells of the anterior pituitary. In the vast majority of cases, this overproduction results from the presence of a pituitary adenoma. Excess GH in the bloodstream leads to increased production of insulin-like growth factor 1 (IGF-1) by the liver, which in turn stimulates bone proliferation and generalized tissue hypertrophy. Under normal conditions, IGF-1 inhibits GH release from the pituitary.

 - **What is the next step in management?** Once a patient is suspected of having acromegaly, the next step is measurement of both serum GH concentration after a glucose load and IGF-1. Because GH levels fluctuate widely over the course of a day and increase in response to fasting, a random or fasting glucose is not helpful.

An oral glucose load prior to GH measurement is given because it suppresses serum GH levels to < 2 ng/mL in healthy subjects but will not change GH levels in acromegaly patients. IGF-1 (once corrected for age) is the single best test for the diagnosis of acromegaly. Once acromegaly has been confirmed, the next step is MRI of the pituitary.
-

- **What is the most appropriate treatment for this condition?**

Treatment of acromegaly is aimed at symptomatic relief, restoration of normal pituitary function, preservation of surrounding brain tissue, and normalization of serum GH levels. Management options include surgery, medications, and radiation. Transsphenoidal resection of the adenoma is often rapidly effective in reducing pressure on surrounding brain structures and restoring serum GH levels to the normal range. However, for tumors > 10 mm in diameter or for patients with GH levels > 40 ng/mL, medications should be prescribed to shrink the adenoma. Both bromocriptine and octreotide (synthetic somatostatin) can be used. Radiation can be used as an adjunct for patients with complex tumor margins; total resection of the adenoma may not be possible in these individuals.

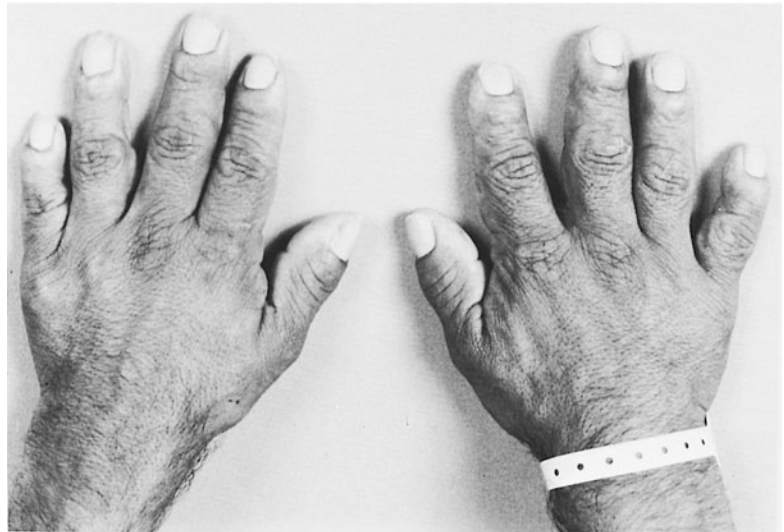

FIGURE 3-1. Markedly increased soft tissue bulk and blunt fingers in a middle-aged man with acromegaly. (Reproduced, with permission, from Greenspan FS, Gardner DG. *Basic and Clinical Endocrinology*, 7th ed. New York: McGraw-Hill, 2006: Fig. 5-19.)

► **CASE 2**

A 29-year-old woman presents to her gynecologist for her annual examination. She has been having irregular menstrual cycles for the past 2 years; the intervals between her periods have extended as long as 3 or 4 months. She denies painful cramps but notes that the periods are heavier than before the irregularity began. She and her husband have been trying to conceive for the past year but have not been successful. She denies pain during intercourse. She notes that she has been gaining weight for the past year, estimating that she is nearly 9.1 kg (20 lb) heavier than she was at her last annual checkup. Upon examination, she is 160 cm (5'3") tall and weighs 77 kg (170 lb). Her face is round and flushed, and her weight is concentrated around her abdomen; her arms and legs are comparatively thinner. Her breast and pelvic examinations are unremarkable, with the exception of thick, reddish-purple streaks around her breasts.

- **What is the most likely diagnosis?** Cushing's syndrome. Cushing's syndrome refers to the group of signs and symptoms associated with abnormally elevated levels of corticosteroids, whether from exogenous glucocorticoids (e.g., iatrogenic) or from conditions associated with overproduction of cortisol or ACTH. Cushing's syndrome is five times more common in females than in males. Cushing's must be distinguished from other causes of hypercortisolism (alcohol abuse, depression, anorexia nervosa) as well as from familial syndromes and other conditions that share some of the symptoms (polycystic ovarian syndrome, ovarian tumors, congenital adrenal hyperplasia, genetic predisposition to rotund body type). If left untreated, Cushing's syndrome can lead to numerous complications, including hypertension, diabetes, severe infections, disability due to fracture and necrosis of the femoral head, and psychosis.

 - **What signs and symptoms are characteristic of this condition?**

In order of decreasing frequency:

 - Central obesity, including moon facies and buffalo hump.
 - Facial plethora.
 - Glucose intolerance.
 - Muscle weakness.
 - Hypertension.
 - Psychological changes (irritability, anxiety, depression).
 - Dermatological changes (easy bruisability, acne, oily skin, and purple striae on abdomen, thighs and/or breasts).
 - Hirsutism.
 - Oligomenorrhea or amenorrhea.
 - Impotence.
 - Ankle edema.
 - Bone weakness (often leading to backache and vertebral fractures).

 - **What is the pathogenesis of this condition?** There are multiple possible causes. Approximately half of patients with Cushing's syndrome have Cushing's disease, in which the anterior pituitary over secretes ACTH due to a small benign pituitary adenoma (typically < 5 mm in diameter). One-third of cases can be traced to a unilateral adrenal tumor and are independent of ACTH stimulation. Less commonly, Cushing's syndrome is caused by ectopic sources of ACTH, such as small cell carcinoma of the lung. Remember: in Cushing's, you have plenty of Cortisol, whereas Addison's causes Autoimmune destruction of the adrenals.
-

- **What tests and/or imaging tools could be used to confirm the diagnosis?**

Hypercortisolism can most easily be detected with a dexamethasone challenge, in which 1 mg is administered orally around 11 P.M., and serum cortisol is collected at 8 A.M. the following morning. A serum cortisol level $< 5 \mu\text{g/dL}$ almost conclusively rules out Cushing's syndrome. However, antiseizure drugs and estrogens can cause a false-positive result. Hypercortisolism can be further confirmed with an elevated 24-hour urine cortisol level, followed by a plasma ACTH measurement. ACTH levels $< 20 \text{ pg/mL}$ are suggestive of an adrenal tumor, while higher levels indicate pituitary or ectopic sources of ACTH. If the syndrome is determined to be ACTH dependent, a pituitary tumor will be apparent on $\sim 50\%$ of MRI scans. CT scanning is used to search for ectopic sources of ACTH and shows the source in 60% of cases.

-
- **What is the most appropriate treatment for this condition?**

Patients with Cushing's disease respond best to transsphenoidal resection of the pituitary adenoma. In most cases, the rest of the pituitary resumes normal function; however, some patients may require hydrocortisone replacement therapy. Adrenal adenomas are treated with unilateral adrenalectomy.

► **CASE 3**

A 40-year-old man presents to his primary care physician with a month-long history of fatigue, light-headedness, and muscle weakness. He notes decreased appetite and a 4.5-kg (10-lb) weight loss over this time, as well as darkening of his skin, particularly over his appendectomy scar, his knuckles, his belt line, and both knees. The light-headedness is particularly severe when he gets out of bed in the morning or rises from a seated position. Throughout the interview, the patient appears irritable and agitated. His blood pressure is 115/70 mm Hg supine and 90/60 mm Hg standing. Relevant laboratory findings are as follows:

WBC count: 11,000/mm³
Absolute neutrophil count: 620/mm³
Total eosinophil count: 475/ μ L
Serum Na⁺: 125 mEq/L
Serum K⁺: 5.9 mEq/L
Serum glucose: 64 mg/dL (fasting)

-
- **What is the most likely diagnosis?** A history of fatigue, malaise, generalized weakness, decreased appetite, and/or weight loss is concerning for adrenal insufficiency (primary or secondary), malignancy, intrinsic gastrointestinal disease, anorexia nervosa, multiple sclerosis, and AIDS. The presence of the following complex of findings is most consistent with adrenal insufficiency: hyponatremia, hypoglycemia, hypotension, and moderate neutropenia with relative eosinophilia. Further, hyperkalemia and hyperpigmentation suggest a diagnosis of primary (Addison's disease) as opposed to secondary adrenal insufficiency.

 - **What is the pathogenesis of this condition?** In Addison's, autoimmune destruction of the adrenal glands renders them unable to produce sufficient amounts of cortisol and sometimes aldosterone. Cortisol deficiency results in hypotension, hypoglycemia, neutropenia, and increased levels of ACTH. Elevated ACTH causes characteristic hyperpigmentation (not a feature of secondary adrenal insufficiency caused by pituitary apoplexy). Aldosterone deficiency (which also does not occur in secondary adrenal insufficiency) results in hyperkalemia and further worsens hypotension. Hyponatremia reflects increased ADH secretion caused by cortisol deficiency.

 - **What tests could be used to confirm the diagnosis?** Hyponatremia and hyperkalemia are suggestive of the disease. A cosyntropin test, in which synthetic ACTH is administered and a serum cortisol is obtained within 1 hour, can be used to confirm the diagnosis. When present early in the morning, low cortisol levels accompanied by high levels of ACTH are diagnostic. In this patient, serum cortisol and plasma ACTH measured around 8 A.M. might be 1.2 μ /dL and 350 pg/dL, respectively. Remember: in Cushing's, you have plenty of Cortisol, whereas Addison's causes Autoimmune destruction of the adrenals.

 - **What is the most appropriate treatment for this condition?** Treatment involves replacement of glucocorticoids and mineralocorticoids. In mild cases, oral glucocorticoid replacement is sufficient; however, fludrocortisone acetate may be needed to stimulate sodium retention.
-

► CASE 4

A healthy 24-year-old woman was involved in an automobile accident, and sustained a fracture of her jaw, multiple facial bone fractures, and a brief loss of consciousness. In the emergency department, an intravenous infusion of 5% dextrose in 0.45% normal saline at 125 mL/hr was started. Twelve hours after admission to the hospital, she was awake and alert but had difficulty swallowing and talking because of her injuries, and she complained of extreme thirst. Her urine output was 500–600 mL/hr. Laboratory studies showed that her serum sodium concentration was 156 mEq/L with a plasma osmolality of 320 mOsm/kg. Her urine osmolality was 65 mOsm/kg.

- | | |
|--|---|
| ■ What is the most likely diagnosis? | Diabetes insipidus (DI). The disease occurs in two forms: central and nephrogenic; though both are rare, the central (CDI) form is more common. CDI is caused by damage to the hypothalamus, posterior pituitary, or the connection between them, usually from surgery, tumor, infection, or (as in this case) head injury. Whatever the cause, the lesion disrupts the release of vasopressin, or antidiuretic hormone (ADH). Without vasopressin, the body is unable to signal the collecting ducts of the kidneys to reabsorb water from the tubular filtrate and return it to the bloodstream. Nephrogenic DI, on the other hand, usually occurs as a result of an inherited defect that renders the kidneys unable to reabsorb water from the tubules and return it to the circulation. DI can also occur as a side effect of drugs such as lithium or amphotericin B, or in association with polycystic kidney disease. |
| ■ What are the usual osmoregulatory responses to hypernatremia? | The body normally responds to hypernatremia through renal water conservation and the sensation of thirst. In contrast, this patient is polyuric instead of oliguric, reflecting a defect in the kidneys' ability to appropriately concentrate urine. She is complaining of thirst, so this limb of the osmoregulatory system is intact. |
| ■ What other conditions should be included in the differential diagnosis of polyuria? | Polyuria can be due to excessive water intake (primary polydipsia with secondary polyuria) or excessive renal water loss (primary polyuria). The urine osmolality is commonly used to differentiate between these two. Water diuresis, as in diabetes insipidus, is defined by a urine osmolality < 150 mOsm/kg. Solute (or osmotic) diuresis, as in diuretic-induced polyuria, poorly controlled diabetes mellitus, and postobstructive diuresis, is defined by a urine osmolality > 300 mOsm/kg. |
| ■ What type of intravenous fluids would be most appropriate for this patient? | The patient's free water deficit should be aggressively corrected with electrolyte-free water (5% dextrose in water) until she can resume oral water intake. Giving her sodium-containing solutions (e.g., normal or half-normal saline) would only exacerbate the polyuria by superimposing a solute diuresis on the existing water diuresis. |
| ■ What other treatment will this patient require for the polyuria? | She should receive exogenous vasopressin. Because the clinical situation may change (within hours to a few days) with the possible release of ADH stores from necrotic pituitary tissue, she should receive a short-acting form of the hormone. The preferred choice would be aqueous vasopressin, which lasts 4–6 hours, delivered subcutaneously or intramuscularly. |
-

► **CASE 5**

A 7-year-old boy is brought to the pediatrician by his parents for new-onset bedwetting and weight loss. They state that he is eating and drinking more than usual but continues to lose weight. He has been using the bathroom more during the day in addition to his accidents at night. He has also complained of changes in his vision. On physical examination, the child is alert and oriented with stable vital signs; there are no abnormal physical findings. Laboratory tests reveal a plasma glucose of 280 mg/dL.

■ What is the most likely diagnosis?	Type 1 diabetes mellitus (DM). This is an autoimmune condition that leads to irreversible destruction of the insulin-producing β cells in the pancreatic islets of Langerhans. The resulting insulin deficiency manifests as abnormal glucose metabolism, with high plasma and urine glucose levels leading to polydipsia and polyuria, respectively. It typically presents in non-obese children and young adults and is associated with HLA-DR3 and -DR4.
■ What tests could be used to confirm the diagnosis?	In this patient, the random plasma glucose > 200 mg/dL with characteristic symptoms is adequate confirmation. In other circumstances, a fasting (> 8 -hour) plasma glucose > 126 mg/dL on two occasions or a two-hour postprandial glucose > 200 mg/dL on two occasions are required.
■ What treatment should be initiated for this patient?	The child and family should be taught self-monitoring of blood glucose, which will need to be performed multiple times daily. An insulin regimen should be initiated and will typically combine a longer-acting type (such as NPH or glargine) with shorter-acting types (such as regular, lispro, or aspart) around meals. The physician will monitor both the family's log of glucose levels and the child's hemoglobin A _{1c} (HbA _{1c}) level, which reflects long-term glucose control, and will adjust the regimen accordingly.
■ What additional screening tests will be required for this patient?	<ul style="list-style-type: none">■ Frequent BP checks with tight control (ACE inhibitors as needed).■ Foot exams to test sensation and perfusion, and rule out injury.■ Annual dilated-eye exams.■ Annual microalbuminuria screening.■ Lipid profile every 2–5 years.
■ The child has persistent early-morning hyperglycemia. What is this phenomenon?	Dawn phenomenon: during sleep, increased secretion of growth hormone and other peptides, decreases the effectiveness of insulin, leading to high glucose levels early in the morning. This can be addressed by moving the evening dose of insulin closer to bedtime.
■ What are the chronic complications of this condition?	<ul style="list-style-type: none">■ Retinopathy: develops at least 3–5 years after diagnosis; treated with laser photocoagulation therapy for retinal neovascularization.■ Nephropathy: prevent with good BP control (ACE inhibitors).■ Neuropathy: prevent foot injury with careful exams and good footwear; late complications include autonomic dysfunction.■ Macrovascular: cardiovascular, cerebrovascular, and peripheral vascular disease; control BP, LDL, and triglycerides; prescribe baby aspirin.

► **CASE 6**

A 20-year-old college student presents to the emergency department after 24 hours of nausea, vomiting, and severe abdominal pain. Two days prior, he attended an end-of-semester party at which he drank at least six beers. He notes that he has lost about 9.1 kg (20 lb) in the past 3 weeks, despite being excessively hungry and thirsty. He also mentions having experienced frequent urination for the past month. On physical examination, he appears pale and diaphoretic, and his breath smells fruity. He has a pulse of 130/min, blood pressure of 100/65 mm Hg, and respiratory rate of 20/min. Relevant laboratory test results are as follows:

Serum Na⁺: 143 mg/dL
 Serum Cl⁻: 101 mg/dL
 Serum glucose: 550 mg/dL
 Serum bicarbonate: 6 mEq/L
 Serum pH: 7.2
 Serum ketones: positive

-
- | | |
|--|--|
| ■ What is the most likely diagnosis? | The triad of hyperglycemia, anion gap metabolic acidosis, and ketonemia is pathognomonic for diabetic ketoacidosis (DKA). The early symptoms of DKA include polyuria, polydipsia, abdominal pain, and nausea and vomiting, evolving to coma over about 24 hours. DKA must be distinguished from gastroenteritis or another abdominal process causing nausea and vomiting. In addition, alcohol poisoning or a central nervous system infection may result in loss of consciousness, vomiting, and dehydration, similar to the events in this case. |
| ■ What is the pathogenesis of this condition? | Diabetic ketoacidosis occurs due to relative or absolute insulin deficiency. It can be the initial presentation of type 1 diabetes mellitus, or it may result from complications of the disease or from poor insulin management. Hyperglycemia induced by stress, excess alcohol consumption, or incorrect insulin dosing can force the body to make ketones as an emergency source of energy, since it is unable to absorb glucose for fuel in the absence of adequate insulin function. Uncontrolled, this leads to a drop in blood pH, severe dehydration, shock, and exhaustion. After > 36 hours of severe vomiting and hyperventilation, a ketoacidotic coma can develop. Remember the “5 I’s” for the precipitating factors: I nfection, I schemia, I nfarction, I gnorance (poor control), I ntoxication. |
| ■ What are the typical laboratory findings in this condition? | Hyperglycemia (> 250 mg/dL), metabolic acidosis (blood pH < 7.3), low serum bicarbonate (< 15 mEq/L), and serum positive for ketones are diagnostic of diabetic ketoacidosis. Remember that ketone bodies are seen most often in type one diabetes. |
| ■ What is the most appropriate treatment for this condition? | Immediate therapy should consist of hospitalization to administer insulin as well as fluid and electrolyte correction. Subsequently, a regular insulin regimen should be instituted to reduce the patient’s chances of future episodes of diabetic ketoacidosis. |
-

► **CASE 7**

A 39-year-old woman is seen in the emergency department after having fainted while exercising with her husband. She notes that, despite having maintained the same exercise regimen for the past few years and increasing her caloric intake, she has lost about 6.8 kg (15 lb) over the past 2 months. Furthermore, she sweats much more than she used to, even when not exercising. Her bowel movements have become more frequent, and her menstrual cycles are more irregular. Her blood pressure is 130/80 mm Hg, pulse is 112/min, and respiratory rate is 16/min. She finds it difficult to sit still during the physical examination. Her skin is moist and warm. She has mild proptosis bilaterally. The rest of her examination is unremarkable. Laboratory tests reveal the following:

TSH: 0.5 μ U/mL
Total triiodothyronine (T_3): 300 ng/dL
Total thyroxine (T_4): 25 μ g/dL
TSH-R antibodies: positive

-
- **What is the most likely diagnosis?** Graves' disease. It is eight times more common in women than in men and generally manifests between the ages of 20 and 40 years. It can be distinguished from other thyroid disorders by proptosis, a marked swelling of the periorbital tissues (Figure 3-2). Graves' disease must be differentiated from other causes of hypermetabolism, such as pheochromocytoma and acromegaly, or simply acute viral illness. High estrogen states can mimic the menstrual symptoms of hyperthyroidism and must be ruled out. Drugs such as amiodarone, clofibrate, and methadone may also cause similar symptoms.
-
- **What is the pathogenesis of this condition?** Graves' disease is an autoimmune condition that results in excess synthesis and release of thyroid hormones, sometimes accompanied by an enlarged gland. Autoantibodies form against the thyroid-stimulating hormone receptor (TSH-R) in thyroid epithelial cell membranes, where they bind with high affinity and cause overstimulation of the receptor, resulting in excess production of T_3 and T_4 . Remember the presentation of hyper-**THYROIDISM**:
Tremor
Heart rate up
Yawning (fatigability)
Restlessness
Oligomenorrhea and amenorrhea
Intolerance to heat
Diarrhea
Irritability
Sweating
Muscle wasting and weight loss
-
- **What tests and/or imaging tools can be used to confirm the diagnosis?** Primary hyperthyroidism is generally diagnosed via low serum TSH accompanied by elevated T_3 and T_4 . The diagnosis of Graves' disease can specifically be confirmed via the presence of antibodies against the TSH receptor.
-

- **What is the most appropriate treatment for this condition?**

Radioactive thyroid ablation, thyroidectomy, and antithyroid drugs (methimazole or propylthiouracil) should all be considered in a patient with hyperthyroidism. Surgical intervention is generally more successful than medical management, particularly in patients with large goiters. Levothyroxine should be given after surgery or ablation to prevent hypothyroidism. In this patient, either ablation or antithyroid medications may be appropriate first steps, since she does not have a palpable thyroid.

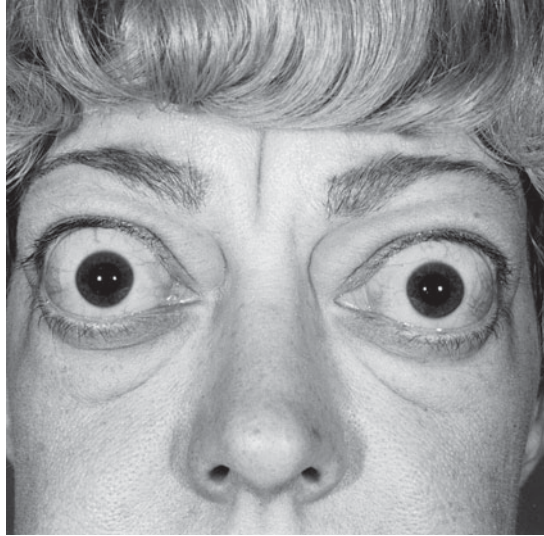

FIGURE 3-2. Severe ophthalmopathy associated with this condition.

(Reproduced, with permission, from Riordan-Eva P, Whitcher JP. *Vaughan & Asbury's General Ophthalmology*, 16th ed. New York: McGraw-Hill, 2006: Fig. 13.3.)

► **CASE 8**

A 33-year-old woman presents to her family physician for a follow-up visit. Two months ago, during a visit for a viral upper respiratory infection, her blood pressure had been 140/90 mm Hg. Her physician noted this and requested that she return for further evaluation when her infection resolved. The patient is in generally good health and denies medical problems. Today, her blood pressure is 190/100 mm Hg, heart rate is 80/min, and respiratory rate is 14/min. Her physical examination is otherwise unremarkable. Relevant laboratory values are as follows:

Serum glucose: 100 mg/dL (nonfasting)
Serum Na⁺: 147 mg/dL
Serum K⁺: 2.5 mg/dL
Serum pH: 7.55
Serum HCO₃⁻: 32 mg/dL
Serum osmolality: 275 mOsm/kg
Urine osmolality: 530 mOsm/kg

■ What are the ECG changes associated with this condition?	As the serum potassium concentration falls, the initial changes is T wave flattening, followed by development of a U wave and ST segment depression. With more severe hypokalemia, the P-wave amplitude may be increased, and the QRS may widen (Figure 3-3).
■ What is the most likely diagnosis?	The constellation of hypertension accompanied by hypokalemia and metabolic alkalosis is typical of hyperaldosteronism (defined as an excess of serum aldosterone). There are two forms: primary (adrenal hypersecretion, Conn's syndrome) and secondary (extra-adrenal production). Conn's syndrome affects females twice as often as males.
■ What is the pathogenesis of this condition?	Excess aldosterone increases the sodium-potassium exchange in the distal convoluted tubules of the kidneys. As a result, sodium is retained within the body, and potassium is excreted. High sodium levels lead to retention of water with subsequent increases in extracellular fluid volume and blood pressure. The metabolic alkalosis arises from increased urinary H ⁺ excretion, mediated both by hypokalemia and the direct stimulatory effect of aldosterone on distal renal tubular acidification. Potassium depletion eventually leads to muscle weakness and fatigue because the muscle membranes are hyperpolarized (typically when serum potassium drops below 2.5 mg/dL).

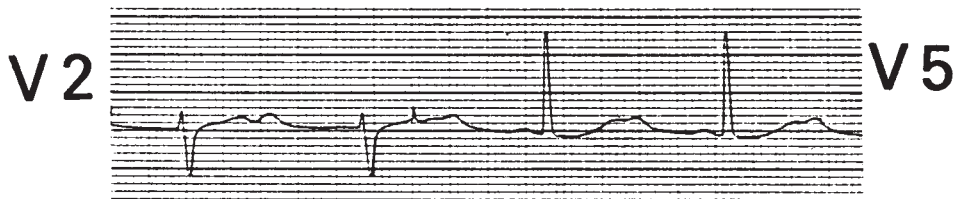


FIGURE 3-3. Electrocardiographic manifestation of hypokalemia. (Reproduced, with permission, from Fuster V, Alexander RW, O'Rourke RA, eds; Roberts R, King SB III, Nash IS, Prystowsky EN, assoc. eds. *Hurst's The Heart*, 11th ed. New York: McGraw-Hill, 2004: Fig. 13-36.)

- **What tests and/or imaging tools could be used to confirm the diagnosis?**

Elevated plasma and urine aldosterone levels and decreased serum renin levels confirm the diagnosis of primary Conn's syndrome. In contrast, both renin and aldosterone are elevated in secondary hyperaldosteronism (e.g., renovascular hypertension). A CT or MRI scan should be obtained to aid in determining whether the primary hyperaldosteronism is caused by bilateral adrenal hyperplasia or by a solitary adenoma.

-
- **What is the most appropriate treatment for the hypokalemia, metabolic alkalosis, and hypertension?**

Patients with primary hyperaldosteronism due to bilateral adrenal hyperplasia are treated with potassium-sparing diuretics (e.g., spironolactone), which effectively treat both the hypokalemia and the metabolic alkalosis. Antihypertensive agents are often additionally required. The most appropriate treatment for a solitary adenoma (Conn's syndrome) is laparoscopic adrenalectomy.

► **CASE 9**

A 40-year-old woman is brought to the emergency department with confusion and left lower quadrant abdominal pain. One hour earlier, her husband found her wandering around the house looking for the family dog, which had died 3 years ago. The patient is unable to describe the pain but is clearly in distress and is holding her left side. Her husband mentions that she was treated for a kidney stone at the same hospital 9 months earlier. Since then, she has lost approximately 6.8 kg (15 lb) and regularly complains of fatigue and muscle weakness. Upon examination, her blood pressure is 136/72 mm Hg, heart rate is 115/min, and respiratory rate is 16/min. There is tenderness with guarding in the left lower quadrant, as well as tenderness over her lower back. The patient is alert but is not oriented to time or place. Relevant laboratory values are as follows:

Serum Na⁺: 152 mg/dL
Serum K⁺: 3.2 mg/dL
Serum Ca²⁺: 17.3 mg/dL
Serum phosphate: 1.7 mg/dL
Serum Cl⁻: 121 mg/dL

-
- **What is the most likely diagnosis?** Primary hyperparathyroidism. Hyperparathyroidism must be distinguished from a large number of other possible causes of hypercalcemia, some of which are as simple as dehydration. Many malignant tumors cause hypercalcemia, though not always in the setting of bony metastases; instead, they may secrete parathyroid-related protein (PTHrP), which mimics the effects of parathyroid hormone (PTH). Hematologic cancers (e.g., multiple myeloma), various leukemias and lymphomas, and some granulomatous infections (via macrophage production of vitamin D) can also increase serum calcium. Remember this mnemonic for the presentation of hyperparathyroidism: Painful **bones**, renal **stones**, abdominal **groans**, and psychiatric **overtones** (mental status changes).

 - **What is the pathogenesis of this condition?** Primary hyperparathyroidism is characterized by excess secretion of PTH, usually by one or multiple parathyroid glands (rarely by a parathyroid carcinoma). PTH induces bone resorption and elevates blood calcium. Excess serum calcium leads to increased excretion of calcium and phosphate by the kidneys, which results in hypercalciuria and can lead to the formation of kidney stones. Furthermore, prolonged elevation of PTH compromises bone integrity and can lead to fractures or cystic lesions in the skeleton. Secondary and tertiary hyperparathyroidism are less common and originate in the kidneys.

 - **What is the prognosis for patients with this condition?** Successful resection of parathyroid adenomas generally leads to resolution of hyperparathyroidism. Bone damage also tends to repair itself if high levels of PTH are normalized.

 - **What tests and/or imaging tools could be used to confirm the diagnosis?** Hypercalcemia in the presence of elevated PTH is the hallmark of primary hyperparathyroidism; it is typically accompanied by hypophosphatemia and high urinary excretion of calcium. Serum calcium is typically > 10.5 mg/dL, and ionized calcium is usually > 5.4 mg/dL. Levels of serum phosphate will generally be < 2.5 mg/dL. Plasma chloride and uric acid levels may also increase; alkaline phosphatase will be elevated if bone is markedly affected.

 - **What is the most appropriate treatment for this condition?** In this patient, the treatment of choice would be surgical parathyroidectomy, since she is symptomatic. Oral administration of large amounts of fluids can be used acutely to alleviate hypercalcemia.
-

► **CASE 10**

A 34-year-old mother of two children presents to her primary care physician for a routine checkup. She has been feeling weak and tired for the past 3 months and notes constipation, with bowel movements approximately three times per week. She attributes the fatigue to the increase in menstrual flow and painful cramps she has observed for the past six cycles. For the past 2 months, she has also experienced a general lack of interest in her hobbies and finds it difficult to get out of bed each morning to care for her children. On physical examination, she appears to be shivering slightly. She weighs 11.3 kg (25 lb) more than she did at her last visit 12 months ago. Her blood pressure is 125/75 mm Hg, pulse is 55/min, and respirations are 12/min. A 5-cm, nontender neck mass is palpable, and her skin is dry and cold. Delayed relaxation of deep tendon reflexes is also noted. Her physician orders blood tests that reveal the following:

Hemoglobin: 9.7 g/dL

TSH: 14 μ U/mL

Total triiodothyronine (T_3): 60 ng/dL

Total thyroxine (T_4): 3.2 μ g/dL

Thyroid peroxidase antibodies: positive

-
- **What is the most likely diagnosis?** Hashimoto's thyroiditis (also known as chronic autoimmune thyroiditis). The diagnosis of Hashimoto's must be differentiated from other conditions that can cause similar symptoms, such as primary amyloidosis, pernicious anemia, depression, acute psychiatric illness, menstrual disorders, or hyperlipidemias. Drugs such as androgens, glucocorticoids, phenobarbital, phenytoin, salicylates, and sertraline can also affect thyroid hormone metabolism and clearance.

 - **What is the pathogenesis of this condition?** Primary hypothyroidism typically results from thyroid disease, as opposed to insufficient thyroid-stimulating hormone (TSH) from the anterior pituitary. Hashimoto's thyroiditis is the most common cause of hypothyroidism in the United States and other iodine-sufficient areas. The mechanism of the disease is thought to be mediated by T cells, which recognize thyroid antigens and launch a cytotoxic attack. The high serum concentrations of antithyroid antibodies present in most patients with Hashimoto's are thought to play little, if any, role in the pathogenesis. The incidence of Hashimoto's thyroiditis is 10–20 times higher in women than in men.

 - **What tests could be used to confirm the diagnosis?** Primary hypothyroidism can be either subclinical or overt. Subclinical hypothyroidism manifests as a high TSH level with normal T_3 and T_4 levels. Overt hypothyroidism manifests as a high TSH accompanied by low T_3 and T_4 , usually with clinical symptoms of hypothyroidism. In clinically hypothyroid patients, routine testing for antithyroid antibodies is not required because nearly all will have chronic autoimmune thyroiditis. However, the presence of antibodies against thyroid peroxidase is predictive of a more severe, protracted course.

 - **What is the most appropriate treatment for this condition?** Treatment with levothyroxine and regular monitoring of TSH and T_3/T_4 levels is suggested for this patient. Regular monitoring is recommended to avoid precipitating hyperthyroidism via excess levothyroxine or myxedema through insufficient medication.
-

► **CASE 11**

A 29-year-old woman presents to her primary care physician with left-sided pain that has waxed and waned in severity over several hours. The pain started in her left flank but is now most intense in her left labial region. Her gynecologic history is notable for 12 months of amenorrhea. She is not pregnant but does report irregular milky discharge from both breasts for many months. Last week, she was diagnosed with peptic ulcer disease and given a prescription for omeprazole, which she has been taking as directed. Upon examination, the patient is clearly in distress. She cannot lie flat on the examination table and initially refuses to let the physician palpate her abdomen. Her blood pressure is 110/70 mm Hg, heart rate is 120/min, and respiratory rate is 19/min. Her examination is notable only for some left lower quadrant tenderness. Bowel sounds are normal. Relevant laboratory results include a serum glucose level of 100 mg/dL (nonfasting), a serum Ca²⁺ level of 12.3 mg/dL, and a serum gastrin level of 253 pg/mL (nonfasting).

■ **What is the most likely diagnosis?**

Multiple endocrine neoplasia type 1 (MEN1). The multiple endocrine neoplasia syndromes are inherited as autosomal dominant traits and affect a specific combination of endocrine glands. MEN1 (also called Wermer's syndrome) is quite rare, affecting approximately 2–10 of every 100,000 individuals, and affects men and women equally. It targets the parathyroid glands, pancreas, and pituitary (**3 P's**). In rare cases, the adrenal cortex is also involved, and some patients even develop carcinoid tumors in the thorax or abdomen. The differential diagnosis for MEN1 includes sporadic or familial tumors of the parathyroids, pancreas, or pituitary. Hypercalcemia can lead to increased gastrin levels, mimicking a gastrinoma. Similarly, routine consumption of H₂-blockers or proton pump inhibitors can also increase gastrin secretion. A useful mnemonic for MEN1 is “**Please Please Pay Attention to peptic ulceration, you worms**”:

- Adenomas of:
 - Pituitary
 - Pancreatic islets
 - Parathyroid
 - Adrenal cortex
 - Associated with **peptic ulceration**
 - Syndrome is called “**Wermer's syndrome**”

■ **What is the pathogenesis of this condition?**

Hyperparathyroidism: MEN1 usually affects the parathyroid glands first. Excess secretion of parathyroid hormone (PTH) leads to hypercalcemia. If untreated, this can lead to kidney stones or irreversible tubular injury. Some patients remain hyperparathyroid and asymptomatic for many years, while others manifest the symptoms by age 20. However, nearly all MEN1 patients develop hyperparathyroidism by age 50.

- Enteropancreatic endocrine adenomas:
 - One-third of MEN1 patients will develop gastrinomas (Zollinger-Ellison syndrome); resulting high levels of gastrin stimulate excess acid production and lead to formation of severe gastric and duodenal ulcers. These patients are at much greater risk of gastric or intestinal rupture.
 - Approximately 15% of MEN1 patients develop insulinomas, which cause fasting hypoglycemia. Other hormone-secreting tumors, such as glucagonomas and somatostatinomas, rarely develop but are associated with serious complications. Eventually, about 50% of MEN1 patients will develop pancreatic tumors.

- Pituitary adenomas: Nearly 25% of MEN1 patients develop prolactinomas, which cause the galactorrhea and amenorrhea in women and decreased libido in men. Other patients may develop ACTH-secreting tumors and consequent Cushing’s syndrome/ disease.

■ **What tests could be used to confirm the diagnosis?**

Blood work can be used to assess the various abnormalities that may be seen in MEN1, such as serum calcium and glucose abnormalities. Patients will typically have varying degrees of hypercalcemia (parathyroid involvement) and fasting hypoglycemia (insulinomas). Growth hormone and prolactin levels may be elevated (pituitary tumors). Gastrinomas can be detected by measuring serum gastrin levels following secretin challenge. Genetic testing for the *menin* gene is now possible and is a valuable tool for family members of a proband.

■ **What is the most appropriate treatment for this condition?**

- Hyperparathyroidism: Surgical treatment of the hyperparathyroidism experienced by MEN1 patients is often warranted. Typically, three of the four parathyroids are removed; only a portion of the smallest one is left in the neck, and its function must be monitored carefully. Patients with complete parathyroidectomy must receive daily calcium and vitamin D supplements.
- Enteropancreatic endocrine adenomas:
 - Patients with Zollinger-Ellison syndrome are treated with proton pump inhibitors, which control the amount of acid secreted by the stomach. In severe cases, surgical removal of the entire stomach may be necessary.
 - The development of malignant pancreatic tumors is gradual and difficult to monitor. It is not clear that aggressive surgery improves survival of MEN1 patients.
- Pituitary adenomas: Small prolactinomas don't require treatment unless they cause menstrual irregularities. Dopamine agonists can be used to shrink larger tumors. However, in some refractory cases, surgery and radiotherapy may be warranted.

■ **What is the prognosis for patients with this condition?**

Because MEN1 has such a complex constellation of abnormalities, the prognosis for these patients depends upon the success of individual treatments and the chances of recurrence. Careful monitoring is required to reduce the latter.

► **CASE 12**

A 49-year-old man presents to his primary care physician for a work-related physical examination. He is in generally good health, though he admits to being in worse physical shape than he was 5 years ago. He attributes this to a career change that has him working at a desk instead of on his feet all day. He has tried repeatedly to start a new exercise regimen over the past year but generally only manages to exercise three times each month. He eats three meals a day but admits to a love of junk food. He drinks alcohol daily, typically one or two beers with dinner. He smoked one pack of cigarettes a day for 20 years before quitting last year. His blood pressure is 160/95 mm Hg, pulse is 90/min, and respiratory rate is 16/min. He is 168 cm (5'6") tall and weighs 90.7 kg (200 lb). His last full checkup was nearly 3 years earlier, so his physician recommends a full panel of blood work. Relevant results are as follows:

Serum glucose: 145 mg/dL (fasting)
Serum total cholesterol: 208 mg/dL
Serum triglycerides: 410 mg/dL
Serum HDL: 26 mg/dL
Serum LDL: 173 mg/dL
Serum pH: 7.42

■ What is the most likely diagnosis?	Metabolic syndrome. The mechanism underlying metabolic syndrome is one of insulin resistance in combination with abdominal obesity. The constellation of abnormalities also includes dyslipidemias (which promote plaque formation in the arterial vasculature), hypertension, and a hypercoagulable state.
■ What are the typical laboratory findings in this condition?	Patients with metabolic syndrome generally have hypertriglyceridemia (> 150 mg/dL), fasting hyperglycemia (> 100 mg/dL), and reduced high-density lipoprotein levels (< 40 mg/dL in males and < 50 mg/dL in females). Furthermore, they typically have larger waist circumferences and higher blood pressures than healthy individuals of the same age.
■ What drugs are contraindicated in this condition?	Medications should be chosen with care to avoid worsening any of the conditions associated with metabolic syndrome. For example, β -blockers should be avoided for blood pressure control since they could worsen hyperglycemia.
■ What is the most appropriate treatment for this condition?	Initial management should focus on reducing risk factors for major cardiovascular disease; in this patient, smoking cessation certainly helped. Control of glucose and LDL levels and blood pressure would be necessary. Additionally, lifestyle modifications would improve the patient's long-term prognosis. Diet and exercise should be tailored with the goal of bringing the patient's body mass index (BMI) under 25 kg/m ² (currently 32.3 kg/m ²). The patient should sharply reduce his intake of saturated fats and cholesterol.
■ What are some of the complications associated with this condition?	If left unchecked, metabolic syndrome can progress to full-blown type 2 diabetes. In addition, patients have a markedly increased risk of myocardial infarction and stroke as a result of their hypercoagulability and dyslipidemias.

► **CASE 13**

A 29-year-old woman presents with a 1-week history of a neck mass. She noticed the mass while showering one day and is very concerned because her mother and grandfather both died of thyroid cancer at an early age. She denies any history of neck radiation or heat or cold intolerance. On examination, her temperature is 37.0°C (98.6°F), pulse is 85/min, and blood pressure is 136/90 mm Hg. She has a firm, nontender 3-cm neck nodule located anteriorly just to the left of midline, immediately beneath the thyroid cartilage. The nodule rises when the patient swallows. There is palpable cervical adenopathy bilaterally. Relevant laboratory findings are as follows:

Serum Na ⁺ : 140 mg/dL	Serum Ca ²⁺ : 10.5 mg/dL
Serum K ⁺ : 3.9 mg/dL	Serum phosphate: 1.1 mg/dL
Serum glucose: 90 mg/dL	Serum parathyroid hormone: 70 pg/mL

-
- **What is the most likely diagnosis?** Multiple endocrine neoplasia type 2a (MEN2a). This patient has a thyroid mass concerning for malignancy (based on the presence of lymphadenopathy), a family history of thyroid cancer, and serum laboratory values (calcium, phosphate, and parathyroid hormone [PTH]) consistent with primary hyperparathyroidism. The differential diagnosis of a thyroid mass concerning for malignancy in a patient with a strong family history of thyroid cancer includes familial medullary thyroid cancer (FMTC) and multiple endocrine neoplasia type 2b (MEN2b). However, neither FMTC nor MEN2b patients have hyperparathyroidism. MEN2a is an autosomal dominant disorder characterized by (1) medullary thyroid cancer (MTC), (2) pheochromocytoma (PCC), and (3) primary parathyroid hyperplasia (PPH). Nearly all MEN2a patients develop MTC, often early in life, while a smaller percentage develop PCC or PPH. MEN2b, also an autosomal dominant disorder, is characterized by (1) MTC, (2) PCC, and (3) mucosal neuromas/intestinal ganglioneuromas, (4) developmental abnormalities, and (5) characteristic body type (including decreased upper/lower body ratio and Marfanoid body habitus). MTC occurs in almost all patients and usually develops at an earlier age and is more aggressive than in MEN2a. Both syndromes affect men and women equally.
-
- **What is the etiology of this condition?** The underlying defect in the MEN2 syndromes is a germline defect in the RET proto-oncogene.
-
- **What should be included in the preoperative evaluation for patients with this condition?** The treatment for MTC includes thyroidectomy. However, due to the high incidence of PCC in patients with MEN2a/2b, all MTC patients (whether they have confirmed MEN2a/2b or not) should be evaluated for PCC, and coexisting PCC should be removed before thyroidectomy. Undiagnosed PCC can cause significant morbidity (or even death) during thyroid surgery.
-
- **What are the typical laboratory findings in this condition?** A characteristic feature of MTC is the production of calcitonin. Basal serum calcitonin concentrations usually correlate with tumor mass and are almost always high in patients with a palpable tumor. Primary hyperparathyroidism is characterized by elevated PTH levels in the face of elevated calcium and decreased phosphate levels. Patients with PCC have elevated levels of both 24-hour urinary fractionated metanephrine and plasma fractionated metanephrine. Additionally, genetic testing for RET gene mutations in the proband and his or her “at risk” family members is essential to prevent the morbidity and mortality associated with MTC.
-

► **CASE 14**

A 65-year-old woman presents with a history of low back pain. She began menopause at age 48 and did not receive hormone replacement therapy. Her mother had a hip fracture at age 71. She spends several hours each day outside gardening and consumes 1500 mg of calcium and 800 IU of Vitamin D each day. She denies any history of loose stools, weight loss, fever, chills, night sweats, or neurological problems. On examination, she is 1.5-m (4'11") tall and weighs 45 kg (100 lb). Lumbar-spine films reveal a new vertebral fracture at the L4 level and diffusely decreased radiodensity and loss of trabecular structure in her bones. Dual-energy x-ray absorptiometry of the hip reveals a bone mineral density T score of -1.5 . Relevant laboratory results are as follows:

Serum Ca^{2+} : 9.1 mg/dL
Serum phosphate: 3.5 mg/dL
Serum alkaline phosphatase: 110 U/L
Serum calcidiol: 21 ng/mL

■ **What is the most likely diagnosis?**

Postmenopausal osteoporosis, which is a common disease with a spectrum of manifestations ranging from asymptomatic bone loss to disabling hip fracture. A history of pathologic fractures (fractures that are caused by minor or trivial trauma) in a postmenopausal woman is strongly suggestive of a diagnosis of osteoporosis, regardless of bone mineral density findings. Alternatively, osteoporosis is also defined as a T score less than -2.5 in a patient with no fractures or risk factors (a "T score" is the number of standard deviations that the bone-mineral density measurement is above or below the mean bone density of normal young adults). Osteopenia is defined as a T score between -1 and -2.5 in patients with no pathologic fractures. In patients with osteoporosis, acute or chronic back pain is common and most often due to vertebral fractures. The following secondary causes of pathologic fracture should always be ruled out:

- Primary hyperparathyroidism: not consistent with patient's normal calcium, phosphate, and alkaline phosphatase values (see Table 3-1).
- Vitamin D deficiency (osteomalacia) due to inadequate intake, lack of exposure to sunlight, or malabsorption: ruled out by the normal calcidiol level and the history of adequate supplementation (800 IU/day), ample sunlight exposure, and the absence of malabsorptive symptoms.
- Multiple myeloma (MM): the patient has no constitutional symptoms suggestive of malignancy; however, complete blood count with differential examination and a routine urinalysis are warranted to screen for findings such as elevated urine protein or anemia, that might suggest MM.

■ **What is the pathogenesis of this condition?**

Osteoporosis is a progressive metabolic bone disease characterized by decreased bone density (bone mass per unit volume) with fragility and microarchitectural disruption of bone structure. In premenopausal women, estrogen helps to slow bone resorption. In postmenopausal women, relative estrogen deficiency removes one natural barrier to bone resorption. Skeletal weakness leads to fractures from minor trauma, particularly in the thoracic and lumbar spine, wrist, and hip. In contrast to osteomalacia, the bone in osteoporosis is mineralized normally. Additionally, calcium, phosphate, and alkaline phosphatase levels are all normal (see Table 3-1).

■ What risk factors are associated with an increased incidence of this condition?

Risk factors include: increased age, low body weight, maternal history of osteoporosis, excessive alcohol use, smoking, and (most important) history of a previous fracture.

■ What is the most appropriate treatment for this condition?

- Nonpharmacologic
 - Calcium and vitamin D: all patients with established osteoporosis should receive calcium and vitamin D supplementation to enhance mineralization of newly formed bone. Recommended daily doses are 1200 to 1500 mg of calcium and 600 to 800 IU of vitamin D.
 - Physical activity: muscle strengthening, balance training, and assessment of physical hazards in the home all protect against falls.
 - Lifestyle modification: stopping smoking and excessive alcohol use slows disease progression.
- Pharmacologic
 - Antiresorptive agents (inhibit osteoclast activity).
 - Postmenopausal hormone replacement therapy: no longer widely used due to concerns about the long-term use of estrogen (including risk of breast cancer and cardiovascular disease).
 - Selective estrogen-receptor modulators (raloxifene): decrease risk of vertebral (but not nonvertebral) fractures while decreasing the risk of breast cancer.
 - Bisphosphonates (alendronate, risedronate): reduce incidence of hip, vertebral, and nonvertebral fractures; may cause esophagitis, so are not recommended for patients with upper gastrointestinal disease (e.g., gastroesophageal reflux disease).
 - Calcitonin: may decrease risk of vertebral (but not nonvertebral) fractures.
 - Anabolic agents (act on osteoblasts to stimulate bone formation).
 - Parathyroid hormone: decreases risk of both vertebral and nonvertebral fractures.

TABLE 3-1. Calcium, Phosphate, and Alkaline Phosphatase Levels in Disorders Commonly Affecting Bone

	CA ²⁺	PHOSPHATE	ALKALINE PHOSPHATASE
Osteoporosis	N	N	N
Hyperparathyroidism	↑	↓	↑
Paget's disease of bone	N (sometimes ↑)	N	↑↑↑
Osteomalacia	↓	↓	↑*

N = normal.

*In patients with an elevated alkaline phosphatase, a normal serum calcidiol level effectively rules out osteomalacia as the underlying cause of bone disease.

► **CASE 15**

A 53-year-old man is brought to the emergency department after tripping over his cat in his living room. He is hard of hearing and shouts that he did not see the cat because he was forcing his baseball cap onto his head. He cannot put weight on his right leg and feels severe pain in his right thigh. The patient also notes that he has been experiencing pain in both legs for the past few months. The pain is throbbing and persists for a few hours, and then subsides. A heating pad helps to soothe the ache, but the patient has not used any medication for the pain. He is otherwise in good health and denies any history of hepatobiliary disease. Upon examination, his left leg and hip appear to have full range of motion. His right leg is limited on both abduction and adduction; medial rotation causes severe pain. X-ray of the hip reveals multiple spiral fractures of the right femoral diaphysis. Relevant laboratory values include the following:

Serum Ca²⁺: 9.0 mg/dL
Serum phosphate: 3.0 mg/dL
Serum alkaline phosphatase: 500 U/L
Serum calcidiol: 20 ng/mL

-
- **What is the most likely diagnosis?** Paget's disease of bone. Also known as osteitis deformans, the disease affects approximately 3% of individuals over the age of 40 years. Men are affected more often than women, and individuals in the northeastern United States are more frequently affected than are those in other areas of the country. However, many are not diagnosed because of the gradual onset of the disease; often, only one or two bones may be affected. Primarily, the spine, pelvis, skull, femur, and tibia are susceptible, although the disease can affect any bone in the body. Pain is generally the first symptom; bone weakness and fractures develop later. If the skull is involved, a patient's hat size may increase, and nerve compression can lead to deafness. If serum calcium is also elevated, hyperparathyroidism should be ruled out.

 - **What is the pathogenesis of this condition?** Paget's is a disease of bony remodeling in which increased bone resorption is followed by highly disorganized new bone formation. The new bone is soft and porous, which leads to bending, brittleness, arthritis, and stress fractures. The bone becomes increasingly vascular and palpably warm. Remember the symptoms and sequelae of Paget's disease with the mnemonic **PANICS**: Pain, Arthralgia, Nerve compression/Neural deafness, Increased bone density, Cardiac failure, and Skull/Sclerotic vertebrae/Sarcomas (osteosarcomas).

 - **What tests and/or imaging tools could be used to confirm the diagnosis?** See Table 3-1. X-rays can be used to observe changes in bone due to Paget's disease (Figure 3-4), especially bowing. Additionally, a radioisotope bone scan can be used to highlight regions of increased bone resorption (Figure 3-5) before symptoms become apparent on plain films.

 - **What is the most appropriate treatment for this patient?** Acute management of this patient involves stabilization and monitoring of the fracture. However, longer-term treatment must focus on suppression of Paget's disease. Medical management revolves around reducing bone breakdown and stabilizing newly formed bone. Bisphosphonates, generally used to treat osteoporosis, can also be useful in Paget's. Patients are encouraged to increase dietary calcium intake. In addition, exercise can keep joints flexible and reduce pain by strengthening muscles that stabilize joints; however, exercises must be chosen carefully to minimize fracture risk. NSAIDs are effective for pain management.
-

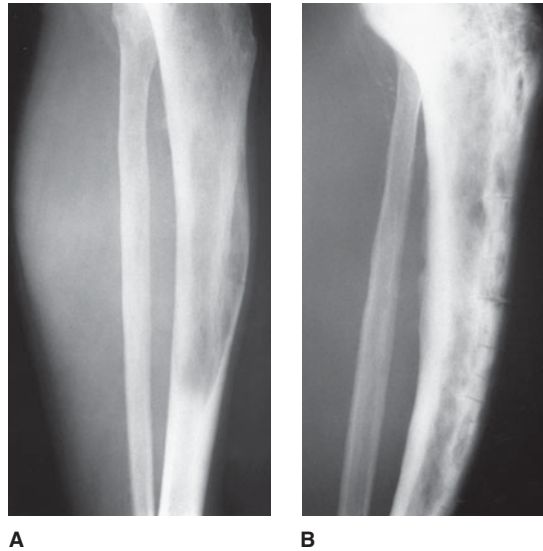


FIGURE 3-4. Early and late radiographs of Paget's disease of the tibia, taken when the patient was 45 years old (A) and 65 years old (B). (Reprinted, with permission, from Skinner HB. *Current Diagnosis & Treatment in Orthopedics*, 3rd ed. New York: McGraw-Hill, 2003: Fig. 6-89.)

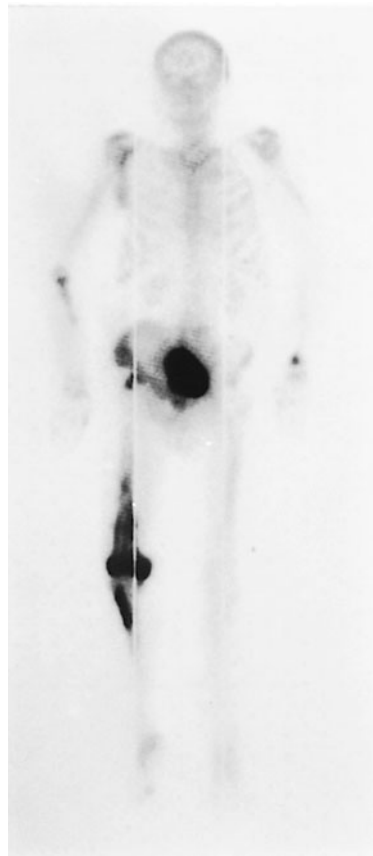


FIGURE 3-5. Bone scan of patient with Paget's disease of the skull, spine, pelvis, right femur, and acetabulum. (Reproduced, with permission, from Greenspan FS, Gardner DG. *Basic and Clinical Endocrinology*, 7th ed. New York: McGraw-Hill, 2004: Fig. 8-33.)

► **CASE 16**

A 32-year-old man presents to his primary care physician after experiencing a severe headache for 1 week. He rates the pain as 8 out of 10 and says that it is nearly constant. He has taken 650 mg acetaminophen every 6 hours for the past 5 days but has not gained significant relief. He has been in generally good health for most of his life, but has lost 2.7 kg (6 lb) in the past month. He has also begun feeling extremely anxious and “shaky,” which he attributes to job-related stress. However, he admits that the level of anxiety exceeds the gravity of his problems at work. He has stopped exercising because of abdominal pain that makes it difficult to lift weights; he cannot localize the pain, noting that his entire abdomen aches at times. He also notes that he sweats much more than he used to and cannot drink enough water to compensate. Upon examination, he is trembling as he sits on the examination table. His blood pressure is 220/160 mm Hg, heart rate 148/min, and respiratory rate 17/min. His abdomen is soft and nontender; bowel sounds are normal. On two occasions during the visit, he experiences severe nausea but does not vomit.

-
- **What is the most likely diagnosis?** Pheochromocytoma (PCC). A tumor of the adrenal medulla which overproduces epinephrine, norepinephrine, or dopamine, leading to hypertension, tachycardia, palpitations, and tremors. Use the “10% rule” with these tumors: 10% are malignant, 10% are bilateral, 10% are extra-adrenal, 10% are pediatric, 10% are familial, 10% are recurring, 10% are associated with multiple endocrine neoplasias, and 10% present with a stroke. PCC may sometimes be confused clinically with thyrotoxicosis, as many of the symptoms are similar. In addition, use of substances such as amphetamines and cocaine can cause similar symptoms, as can clonidine withdrawal. PCC can cause ECG changes and chest pain suggestive of acute cardiac events; these must be ruled out.

 - **What is the pathogenesis of this condition?** PCC’s cause sympathetic overload as a result of excess production of catecholamines by neoplastic chromaffin cells. The resulting vasoconstriction causes a dramatic increase in blood pressure. Patients experience other symptoms such as headaches, sweating, tachycardia, palpitations, anxiety, tremors, and hypermetabolism. In 10% of cases, PCCs are a component of multiple endocrine neoplasia syndromes types 2a and 2b. Consider PCC in young patients with paroxysmal hypertension and/or the classic **TSH** triad of PCC: **T**achycardia, **S**weating, **H**eadache. Use the abbreviation TSH to associate pheochromocytomas with the thyroid gland (i.e., PCCs warrant a workup for MEN syndromes 2a and 2b, both of which are associated with medullary carcinoma of the thyroid).

 - **What are the typical laboratory findings in this condition?** Patients with PCC have elevated levels of both 24-hour urinary fractionated metanephrines and plasma fractionated metanephrine.

 - **What imaging tools could be used to confirm the diagnosis?** A CT scan of the abdomen (Figure 3-6) can be used to confirm the diagnosis if a pheochromocytoma is suspected. MR imaging can also be helpful; both modalities have a sensitivity > 98%. Nuclear medicine scans, such as SPECT imaging with [¹²³I]m-iodobenzylguanidine ([¹²³I] mIBG) and PET imaging with ¹⁸F-labeled deoxyglucose (¹⁸FDG), can also be used to detect tumors that are not visible with other modalities.
-

- **What is the most appropriate treatment for this condition?**

The treatment of choice is laparoscopic excision of the tumor; an open laparotomy is necessary for large tumors that cannot effectively be removed via laparoscopy. However, the patient's blood pressure must be reduced and maintained pharmacologically for approximately 1 week (or until electrocardiographic changes are corrected) before surgery is attempted.

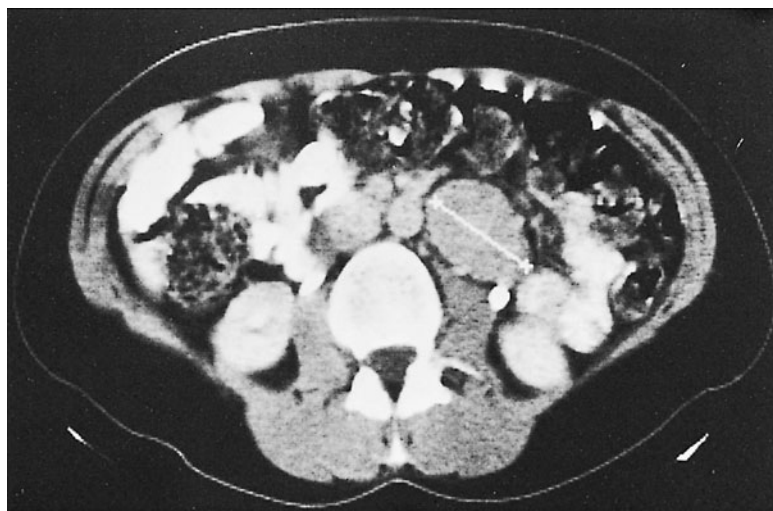


FIGURE 3-6. Left infrarenal paraganglioma, CT scan. (Reproduced, with permission, from Greenspan FS, Gardner DG. *Basic and Clinical Endocrinology*, 7th ed. New York: McGraw-Hill, 2004: Fig. 11-9.)

► **CASE 17**

A 62-year-old man is brought into the emergency department after experiencing a generalized tonic-clonic seizure. He was recently diagnosed with small cell carcinoma of the lung but is taking no medications and has not received chemotherapy. Physical examination reveals a patient in the postictal state. His blood pressure is 138/86 mm Hg, and heart rate is 76/min without orthostatic changes. He has no lower extremity edema. Relevant laboratory findings are as follows:

Serum:

Na⁺: 105 mEq/L BUN: 5 mg/dL
K⁺: 4.0 mEq/L Creatinine: 1.0 mg/dL
Cl⁻: 70 mEq/L Glucose: 85 mg/dL
HCO₃⁻: 25 mmol/L

Urinalysis:

Na⁺: 91 mEq/L
K⁺: 64 mEq/L
Urea nitrogen: 140 mg/L

■ What is the most likely diagnosis?	The patient has a history of lung cancer, a common cause of the syndrome of inappropriate antidiuretic hormone secretion (SIADH). A normal blood pressure and the lack of orthostatic changes indicate euvoolemia.
■ What is the differential diagnosis for euvolemic hyponatremia?	Considerations include reset osmostat, excessive water intake (primary or psychogenic polydipsia), and impaired urine-diluting ability due to increased circulating vasopressin levels and/or vasopressin effect (SIADH, secondary adrenal insufficiency, hypothyroidism, congestive heart failure, cirrhosis, and nephrotic syndrome). Patients with thiazide-induced hyponatremia may also be clinically euvolemic.
■ What are the diagnostic criteria for this condition?	The diagnostic criteria for SIADH are (1) hyponatremia with accompanying low serum osmolality; (2) elevated urine osmolality; and (3) absence of conditions such as congestive heart failure, cirrhosis, renal insufficiency, and adrenal/thyroid insufficiency. Remember SIADH: Spasms, Isn't any pitting edema (key to differential diagnosis), Anorexia, Disorientation (and other psychoses), and Hyponatremia.
■ Why are the other conditions in the differential less likely?	The other disorders in the differential are unlikely for the following reasons: <ul style="list-style-type: none">■ Reset osmostat: serum sodium is rarely below 125 mEq/L, and neurologic symptoms are unusual.■ Psychogenic polydipsia: look for maximally dilute urine ($U_{osm} < 100$ mOsm/kg). The urine osmolality for this patient is $U_{osm} = 2(U_{Na} + U_K) + U_{urea\ nitrogen}/2.8 = 2(91 + 64) + 140/2.8 = 360$ mOsm/kg. There is no history of thiazide diuretic use or of another disorder that would cause increased circulating ADH levels.
■ What is the therapeutic goal for a patient with severe hyponatremia?	The goal is to raise body fluid tonicity to treat the neurologic manifestations of cerebral edema. Rapid correction of serum sodium, however, carries a risk of central pontine myelinolysis.

■ **What is the most appropriate treatment for hyponatremia?**

Aggressive intervention for hyponatremia may be achieved with a hypertonic (3%) saline solution. The serum sodium may be raised by 5 mEq/L over the first 2–3 hours, then at no more than 0.5 mEq/L/hour, to a level of no more than 130 mEq/L. The total amount of sodium required is calculated as follows: 5 mEq/L \times total body water (TBW) = 5 \times (0.6 \times 60 L) = 180 mEq. TBW, rather than extracellular fluid volume, is used because a hypertonic solution redistributes water from the intracellular to the extracellular compartment, so the effective volume of distribution is the TBW. TBW is estimated in liters as two-thirds of a patient's weight in kilograms.

► **CASE 18**

A 44-year-old woman presents to her primary physician for her annual checkup. She is healthy and denies any medical problems. She has a blood pressure of 110/75 mm Hg, pulse 72/min, and respiratory rate 14/min. Her physical examination is remarkable only for a discrete, firm, nontender mass, approximately 0.9 cm in diameter, palpable just lateral to the midline of the neck which rises when the patient swallows.

■ **What aspects of the patient's history should be inquired about?**

The greatest concern in a patient with a thyroid nodule is the risk of malignancy; the patient's risk factors for thyroid cancer should be determined. A history should be taken of the following:

- Symptoms of hyper- or hypothyroidism.
- Compressive symptoms (dyspnea, coughing, choking, dysphagia, hoarseness).
- A prior history of head or neck radiation.
- Any family history of thyroid cancer or endocrine abnormalities.

Less than 1% of patients with a hyperfunctioning nodule have carcinoma, whereas 10–20% of patients with hypofunctioning nodule do. Compressive symptoms or a history of ionizing radiation to the neck are very concerning for malignancy and are considered indications for surgery. A family history of thyroid cancer, hyperparathyroidism, or pheochromocytoma warrants a full-workup for multiple endocrine neoplasia (MEN), including testing for mutations in the RET oncogene and measuring serum calcitonin levels (see Case 13). Additionally, the presence of regional lymphadenopathy on physical exam (not noted in the current patient) raises the index of suspicion for malignancy.

■ **What is the most appropriate next step in management?**

After a thorough history and physical exam, it is appropriate to obtain a TSH level in a patient with a thyroid nodule.

- If the patient has a low TSH, with or without signs or symptoms of thyrotoxicosis (e.g., weight loss, heat sensitivity, exophthalmos, etc.), it is appropriate to perform an I-123 scintiscan (radioisotope scan) to confirm the presence of a “hot” (i.e., functional, probably non-malignant) nodule. Depending on the severity of thyrotoxicosis, treatment ranges from observation to pharmacological management with propylthiouracil or methimazole.
 - If the patient has a normal or high TSH, a fine needle aspiration (FNA) of the nodule should be performed. FNA poses little risk to the patient and can firmly establish a diagnosis in approximately two-thirds of cases. Indeterminate results warrant repeat FNA. If a repeat FNA does not provide a diagnosis, I-123 scintigraphy should be performed. “Cold” nodules on scintigraphy are then treated surgically whereas “hot” nodules are observed or treated pharmacologically depending on the clinical picture.
-

- **What is the most appropriate treatment for this condition?**

If the nodule is suspicious for malignancy, total thyroidectomy is the treatment of choice (suspicious nodules are so classified by the presence of any of the following: a history of head/neck radiation; compressive symptoms; an FNA showing malignant cells; or an indeterminate FNA with follow-up radioisotope testing showing a “cold” nodule). Medullary carcinoma and anaplastic carcinoma typically require more aggressive surgical resection and adjuvant treatment. Since this patient is < 45 years of age and her tumor is < 1 cm in diameter, she may only require partial thyroidectomy, depending on histologic subtype, particularly if she has no cervical lymph node involvement. T_4 is prescribed postoperatively for about 2 months to suppress TSH during the initial weeks of follow-up. It is discontinued approximately 6 weeks before a whole-body ^{131}I scan is used to evaluate residual thyroid tissue. The patient must also be monitored long-term for early diagnosis of recurrence or metastasis.

► **CASE 19**

A 33-year-old woman presents to her primary care physician with neck pain. The pain began 2 weeks ago, is constant and sharp, and radiates to her jaw and ears. Over the past few weeks, she has also been having occasional loose stools and experiencing fatigue, malaise, and myalgias. She has no history of medical problems but does report having a “cold” 4 weeks ago. On examination, her temperature is 37.9°C (100.2°F), pulse 96/min, and blood pressure 134/82 mm Hg. There is diffuse enlargement of the thyroid gland, which is exquisitely tender to even mild palpation. Relevant laboratory results include:

TSH: 1.0 μ U/mL
Total triiodothyronine (T_3): 300 ng/dL
Total thyroxine (T_4): 20 μ g/dL

-
- **What is the most likely diagnosis?** Subacute granulomatous thyroiditis (SGT; also called de Quervain’s thyroiditis), which is characterized by the combination of (1) neck pain (often radiating to the jaw), (2) exquisite thyroid tenderness, and (3) diffuse goiter. The patient’s clinical and biochemical hyperthyroidism (loose stools, decreased TSH, elevated triiodothyronine [T_3] and thyroxine [T_4]) are consistent with early-stage SGT.
-
- **What is the pathogenesis of this condition?** SGT is likely caused either by a viral infection of the thyroid gland or by a postviral inflammatory process. Most patients will report an upper respiratory infection that preceded the onset of neck pain by 2–8 weeks. Whatever factors initiate SGT, the resulting thyroid inflammation damages thyroid follicles and releases large quantities of T_4 and T_3 into the circulation, producing clinical and biochemical hyperthyroidism. The hyperthyroidism only lasts until the released T_4 and T_3 are metabolized. This damage to thyroid follicular cells and inhibition of TSH release by the elevated levels of T_3 and T_4 temporarily shuts down synthesis of new thyroid hormones.
-
- **What is the natural history of this condition?** SGT is characterized by a predictable course of thyroid function. Patients typically present in a hyperthyroid state lasting 2–8 weeks, become euthyroid for a very short time, and then become hypothyroid for another period of 2–8 weeks. The hypothyroidism lasts until the thyroid gland can generate sufficient thyroid hormones to restore the patient to euthyroid status. Nearly all patients eventually recover completely from SGT.
-
- **What conditions should be included in the differential diagnosis?** The differential diagnosis includes acute infectious thyroiditis (AIT) and hemorrhage into a thyroid gland. Both of these conditions can cause severe thyroid pain and tenderness, but typically present as a unilateral fluctuant neck mass with lateralized signs and symptoms (as opposed to bilateral and diffuse signs/symptoms in SGT). Also in contrast to SGT, AIT commonly presents with acute onset of pain with fever and chills, accompanied by normal thyroid function tests.
-
- **What is the most appropriate treatment for this condition?** Treatment is directed at alleviating thyroid pain and mitigating the symptoms of hyperthyroidism. Pain relief can be provided with nonsteroidal anti-inflammatory drugs with or without prednisone. Patients suffering from hyperthyroidism may benefit from β -blockers while they are in the thyrotoxic (early) phase of SGT.
-

Epidemiology and Preventive Medicine

Case 1	102
Case 2	104
Case 3	106
Case 4	108
Case 5	109
Case 6	110
Case 7	112
Case 8	114
Case 9	116
Case 10	118
Case 11	120
Case 12	121

► **CASE 1**

A physician reading a weekly medical journal comes across the results of a case-control study designed to identify risk factors for cerebral vascular accidents (CVAs). The study reports a significant association between CVAs and the routine use of sleeping pills (odds ratio = 0.62, $p \leq 0.035$). Before recommending that his patients stop using these to address insomnia, the physician decides to present the article for discussion at his monthly journal club to discuss the strengths and weaknesses of the study.

■ What types of bias may occur in this study?	Bias, a systematic error that occurs in a study and leads to a distorted estimate of association between exposure and risk of disease, is generally classified into two categories: selection bias and information (or observational) bias. Selection bias is any error that occurs due to the way in which subjects are sampled or identified. Information bias refers to any error that occurs in the process of collecting data and measuring information. Types of information bias include recall bias, interviewer bias, loss to follow-up bias, and misclassification bias. In case-control studies, the types of bias that tend to arise are recall bias and selection bias.
■ What type of bias may cause under- or overestimation of the true association?	Misclassification bias is a type of information bias that occurs when subjects are inaccurately categorized with respect to exposure or disease. Differential misclassification bias occurs when the proportion of misclassified subjects is nonrandom or the direction or magnitude of bias is not the same in all subjects (i.e., misclassification is more likely to happen to subjects in one arm of a study compared to those assigned to the others); this can result in either an over- or underestimate of the true association.
■ What type of bias would potentially underestimate the true association?	Nondifferential misclassification bias occurs when there are errors in categorizing subjects, but the errors are random and affect subjects in all arms of a study equally. This results in increased similarities between the exposed and nonexposed group. The true association between exposure and outcome tends to be underestimated.
■ How does confounding affect the results of a study?	Confounding is the effect of another factor on the exposure under study and outcome of interest. The confounding factor must be associated with both the exposure of interest, and, independent of the exposure, the factor must be a risk factor for the disease. Confounding may lead to an over- or underestimation of the true association between the exposure and outcome. Confounding may also lead to a change in direction of the observed effect.
■ What methods may be used to account for bias and confounding?	Bias is best avoided through careful study design and study conduct. Sources of bias should be identified, and the potential effects of bias on the results should be addressed. Confounding may be controlled during study design and statistical analysis. Subject restriction, matching, or randomization may be used to control for confounding, depending on the study design, and stratified analysis or multivariate analysis may be used during data analysis.

■ **How are associations classified?**

An association may be true (causal) or false (due to confounding). In causal associations, a change in the exposure causes a change in the exposure directly or indirectly through a series of intermediate steps. In associations due to confounding, a spurious relationship is established between the exposure of interest and the outcome due to the action of a confounder.

■ **How are causal relationships classified?**

Causal relationships are categorized by the exposure's necessity and ability to cause the outcome. The exposure is deemed necessary and sufficient, necessary but not sufficient, sufficient but not necessary, or neither sufficient nor necessary to cause the outcome.

► **CASE 2**

An employee at a federal government building in Washington, D.C., begins to experience symptoms that include a fever of 38.3°C (101.0°F), chills, headache, backache, vomiting, and abdominal pain. Within 4 days, the symptoms are followed by the development of a rash characterized by deep-seated, firm or hard, round, well-circumscribed vesicles. The lesions on the patient's arms appear to be in the same stage of development as those on his abdomen. Further investigation reveals that a suspicious package arrived in the office of the employees 2 weeks before the symptoms began.

- **What is the most likely diagnosis?** Smallpox. Smallpox is caused by the variola virus and is most efficiently spread by the respiratory system as well as via direct contact. It invades and multiplies, staying clinically silent for 12 days; a prodrome of constitutional symptoms begins a few days before a rash appears on the face and spreads proximal to distal. The usual cause of mortality (30%) is toxemia. Since 1978, there have been no reported cases.

 - **What criteria are important for diagnosis of this condition?** Smallpox is diagnosed based on a combination of major and/or minor criteria as defined by the Centers for Disease Control and Prevention (CDC). High-risk features include (1) a fever 38.3°C (101.0°F) or greater 1–4 days before the onset of rash with headache, backache, prostration, chills, vomiting, or severe abdominal pain, (2) deep seated round vesicles or pustules that may become umbilicated or confluent, and (3) lesions on multiple parts of the body at the same stage of development, as seen in the patient above.

 - **What conditions should be included in the differential diagnosis?** Varicella, disseminated herpes zoster, impetigo, drug eruption, contact dermatitis, erythema multiforme minor, erythema multiforme, enteroviral infections, disseminated herpes simplex, scabies, insect bites, molluscum contagiosum.

 - **What is the most appropriate treatment for this condition?** Local and state health officials, as well as the CDC, should be contacted and consulted once the diagnosis of smallpox is suspected. The patients should be placed into contact and airborne precautions. Patient contacts should then be vaccinated. Vaccinia immune globulin may be given for postexposure prophylaxis (within 1–3 days of exposure), but there is limited data supporting its effectiveness, and the supply is too small to be readily available during a smallpox outbreak. There are no currently established treatments for smallpox, but some experimental therapies are being evaluated.

 - **What other agents may be used in bioterrorist attacks?** According to the CDC, the highest priority agents (Category A) are those that can be easily disseminated or transmitted, result in high mortality, and have the potential for a major public health impact; these include anthrax, botulism, and smallpox. Category B agents are moderately easy to disseminate and cause moderate morbidity and low mortality; these include *Brucella* and ricin toxin. Category C agents include emerging pathogens that have the potential to be engineered for mass dissemination with the potential for high morbidity and mortality; these include Nipah virus or hantavirus.
-

■ **What steps should be taken when a bioterrorist attack is suspected?**

Bioterrorist attacks may be overt or covert in nature. Once a bioterrorist attack has been identified, the appropriate steps that should be taken include the following:

- Surveillance to identify new cases.
 - Public health response.
 - Confirmation and diagnostic testing.
 - Decontamination and therapy (including prophylaxis and vaccines).
 - Infection control and preparation for psychological effects of the attack.
-

► **CASE 3**

A 45-year-old woman presents to her primary care physician for her annual checkup. She has no current medical complaints, but she is concerned about her risk for breast cancer, as a good friend was recently diagnosed with the disease. The patient's family history is remarkable for breast cancer in her paternal aunt, who was diagnosed at age 66. There is no other family history of cancer.

■ **What are the major risk factors for breast cancer?**

- Age: Increasing age is the primary risk factor for breast cancer, as 85% of breast cancers occur in women over age 50.
- Estrogen exposure: Women with a greater exposure to estrogen are at an increased risk for breast cancer. Factors contributing to greater estrogen exposure include age at menarche (< 12), age at first birth (> 35), and late menopause.
- Genetic predisposition: A positive family history presents a modestly increased risk, but in women with multiple first-degree relatives with premenopausal breast cancer, the risk of breast cancer may be as high as 50%. This risk is associated with defects in the BRCA1 and BRCA2 genes.

Protective factors include breast-feeding, multiparity, exercise, late menstruation, early menopause, and oophorectomy prior to age 35.

■ **What is the epidemiology of this condition?**

The incidence of breast cancer has doubled over the last 60 years. It is estimated that the lifetime probability of a woman developing breast cancer is one in six. Breast cancer is second only to lung cancer in cancer mortality among women. The mortality rates have declined over the last decade, but the decline has been greater among white women than black women. The estimated mortality rates from 1998–2002 for white women was 25.9/100,000 while the rate for African-American women was 34.7/100,000.

■ **What are the different options for breast cancer screening?**

The three currently used methods for breast cancer screening are breast self-examination, mammography, and clinical breast examination. Upcoming screening technologies include full-field digital mammography, computer-assisted detection systems designed to recognize mammographic patterns, and magnetic resonance imaging for women at high risk for breast cancer.

■ **What are the current recommendations for breast cancer screening?**

Self-breast exams are recommended for women beginning in their early 20s, with a clinical breast exam every 3 years. Starting at age 40, yearly clinical examinations and mammograms should be performed. For women at high risk, the patient and provider should discuss how early prior to age 40 to begin yearly clinical exams with mammogram and MRI given the risk for false-positive studies and overdiagnosis. Women should be carefully instructed on how to perform breast self-exams and be educated about the benefits and limitations of breast self-exams.

■ **What are potential harms from screening?**

The sensitivity of mammography screening is between 70% and 90% (depending on a woman's age and breast density). This means that 10–30% of cases of breast cancer are missed at each screening (false-negative result). The specificity of mammography is > 90%. However, up to 10% of cases of “cancer” detected by mammography are not truly cancer (false-positive mammogram result). This can lead to more invasive diagnostic procedures as well as the psychological effects of potentially having breast cancer. Another concern with breast cancer screening is the potential for overdiagnosis. Overdiagnosis refers to conditions that would not have become clinically significant and would not have been detected if not for screening. This may result in unnecessary treatments as well as psychological consequences.

► **CASE 4**

A student working on her degree in public health plans to study the association between maternal vaginal infections during gestation and the development of schizophrenia in offspring. In preparation for her committee meeting, she must have a preliminary study design prepared. She has access to a large database of obstetric records with 30-year follow-up data on the mothers and offspring.

■ What is the most feasible study design given the available information?	Retrospective cohort study. In cohort studies, subjects are classified based on the presence or absence of an exposure. In a retrospective cohort study, all of the events of interest (exposure and outcome) have already occurred. In a prospective cohort, the exposures may have occurred, but the outcome has not yet occurred.
■ What are the advantages of this study design?	The major strengths of a cohort study design are the ability to study rare exposures and the ability to study multiple effects of a single exposure. In prospective cohort studies, another major strength is the ability to minimize selection bias.
■ What are the limitations of this type of study design?	The limitations of cohort studies include high costs, the need for large sample sizes to study rare diseases, and the potential for bias resulting from loss to follow-up.
■ How do prospective and retrospective cohort studies compare?	Prospective cohort studies tend to be more expensive and time consuming since the subjects must be followed forward in time until the outcome of interest develops. However, the potential for bias in assessing exposures and outcomes is often less. Retrospective cohort designs tend to be more efficient for studying diseases with long latency periods. These studies may be limited, however, by the reliance on data that was collected in the past: the desired data to answer the study question may not be available.
■ What potential biases are associated with cohort studies?	<ul style="list-style-type: none">■ Bias in the assessment of an outcome: assignment of subjects to a “disease” or “no disease” cohort is affected by the evaluator’s prior knowledge of who was exposed and who was not exposed.■ Information bias: the quality and extent of information collected is different for exposed and nonexposed persons.■ Bias from nonresponse and losses to follow-up: this can complicate the interpretation of study findings; for example, incidence rates in the exposed and nonexposed cohorts will be difficult to interpret.■ Analytic bias: strong preconceptions held by statisticians and epidemiologists analyzing the data may unintentionally introduce bias into the study.
■ What other study designs could be considered?	Another observational study design is the case-control study. Case-control studies are usually retrospective studies in which subjects are classified based on disease status. “Cases” have the disease; “controls” do not have the disease. Information is then collected regarding exposures to various etiologic factors. The advantages of the case-control study are smaller sample sizes, lower cost, ability to study rare disease, and the ability to measure multiple etiologic factors. The limitations to a case-control study include recall or survivorship bias as well as the inability to measure prevalence, incidence, or relative risk.

► **CASE 5**

A 50-year-old man presents to his primary care physician for a physical examination. He has not seen a physician in over 20 years. He was given a membership to the local gym as a birthday present and feels that he should be medically evaluated before starting his workouts. He weighs 78 kg (172 lb) and is 183 cm (72 in) tall with a BMI of 24 kg/m², blood pressure of 140/90 mm Hg, and heart rate of 86/min.

<p>■ What health care screening measures should be performed?</p>	<p>Patients aged 25–64 years should have the following screening measures performed:</p> <ul style="list-style-type: none"> ■ Height and weight: every year. ■ Blood pressure: every year. ■ Dental checkup: every year. ■ Screen for alcohol abuse and depression: every year. ■ HIV testing: every year. ■ Vaccination review: every year for influenza, update tetanus/pertussis. ■ Fecal occult blood test (FOBT) and digital rectal examination: every year starting at age 50 ■ Pap smear and bimanual pelvic examination (for women: every year starting when sexually active or at age 18). ■ Eye exam: every 2–4 years, baseline exam at age 40. ■ Cholesterol level: every 5 years. ■ Sigmoidoscopy or colonoscopy: every 5 years starting at age 50 (or age 40 for high-risk patients, i.e., first-degree relative with history of colon cancer).
<p>■ What are the current recommended cholesterol levels?</p>	<ul style="list-style-type: none"> ■ LDL: value < 100—optimal; 100–129—near optimal; 130–159—borderline high; 160–189—high; ≥ 190—very high. ■ HDL: value < 40—low; ≥ 60—high. ■ Total: value < 200—desirable; 200–239—borderline high; ≥ 240—high.
<p>■ What are the current recommendations for blood pressure values?</p>	<p>The 7th report of the Joint National Committee proposed the following:</p> <ul style="list-style-type: none"> ■ Normal blood pressure: systolic < 120 mm Hg <i>and</i> diastolic < 80 mm Hg. ■ Prehypertension: systolic 120–139 mm Hg <i>or</i> diastolic 80–89 mm Hg. ■ Stage 1 hypertension: systolic 140–159 mm Hg <i>or</i> diastolic 90–99 mm Hg. ■ Stage 2 hypertension: systolic ≥ 160 mm Hg <i>or</i> diastolic ≥ 100 mm Hg.
<p>■ What cancer screening measures are recommended for patients age 50 and older?</p>	<ul style="list-style-type: none"> ■ Skin examination: every year for patients aged 40 and older. ■ Prostate examination: every year for men aged 50 and older. ■ Clinical breast examination: every year for females aged 40 and older. ■ Mammography: every year for females aged 50 and older. ■ Pap smears: every year if sexually active or older than 18 years, and starting at age 30, every 3 years after three consecutively normal smears. ■ Fecal occult blood test/digital rectal examination: every year for patients aged 50 and older. ■ Flexible sigmoidoscopy: every 5 years for patients aged 50 and older or 40 and older for high-risk patients.

► **CASE 6**

A medical student conducts a study on gastrointestinal (GI) ulcers in a randomly chosen group of traders who work on the floor of the New York Stock Exchange. He enrolls a cohort of traders at the beginning of the fiscal year and will follow them for one year, contacting them each month to see if any of them has had any episodes of chronic epigastric pain that had brought them to see a physician for diagnostic workup. After one year, the cases of confirmed GI ulcer are tabulated and the results are shown below:

	CASES OF GI ULCER (Total)	TOTAL NUMBER OF TRADERS
Start of year	2	100
End of year	32	85

Note: 15 traders could not be contacted after 6 months.

- **What is the prevalence of ulcers at the start of the study?**

Disease prevalence refers to the number of individuals in a population who have a disease at a specific point in time. Prevalence estimates the risk or probability that an individual in the population will have the disease at the given point in time. Prevalence is calculated using the following formula:

$$P = \frac{\text{Number of existing cases of disease at a given time point}}{\text{Total population}}$$

For the case presented, $P = 2/100 = 0.02 \times 100 = 2\%$

- **When calculating incidence of disease, how is the denominator defined?**

Incidence refers to the number of new cases or events that occur in a population at risk during a given time period. It is important to remember when calculating incidence that only the population at risk should be used in the denominator. In the case presented, the population at risk for developing a GI ulcer at the start of the first year is $100 - 2 = 98$; two people already had an ulcer at the start of the study.

- **What is the cumulative incidence of ulcers during the first year?**

Cumulative incidence is a measure of incidence defined as the proportion of individuals who develop disease during a specific time period. It provides an estimate of the risk for developing disease during the specified time (i.e., one year). The formula for calculating cumulative incidence is:

$$CI = \frac{\text{Number of new cases of disease at a given time point}}{\text{Total population at risk during given time period}}$$

For the case presented, $CI = (32 - 2)/(85 - 2) = 36.1\%$

- What is the incidence rate of ulcers in this study?

Incidence rate refers to the rate of development of a disease in a population:

$$IR = \frac{\text{Number of new cases of disease at a given time point}}{\text{Total person - time of observation}}$$

Total person-time of observation is the sum of each individual's time at risk for the disease. It can also be thought of as the time each person was under observation and free from disease. In the case presented, 98 individuals were disease-free at the start of the study. However, 15 people were lost from the study after 6 months. There were 83 people remaining who were followed for 1 year. This yields 90.5 person-years of observation for the denominator (83 people followed for 1 year + 15 person followed for 0.5 year). The resulting incidence rate is $30/90.5 \text{ person-years} = 33.1\%$. Incidence rates can be used to estimate cumulative incidence if the incidence rate is low or if the time period under observation is short.

► **CASE 7**

A 65-year-old woman presents to her primary care physician for her yearly checkup. After the physician takes a detailed history of her chronic ailments, including emphysema and high blood pressure, she asks if the patient has received an influenza shot for the present year. The patient responds by saying, “Last year, the nursing home where I live made me get one, and it made me come down with the flu, so I don’t want it.” After educating the patient that the influenza vaccine is the single best way to protect against influenza, the patient agrees to receive one.

■ How is the influenza vaccine administered?	At present there are two options available: the traditional “flu shot” intramuscular injection and an intranasal spray vaccine. The injectable vaccine contains an inactivated killed virus; it is usually given in the arm and is approved for persons older than 6 months who are healthy or have chronic medical conditions. The spray contains live attenuated influenza virus that does not cause influenza. The nasal spray is approved for healthy persons between the ages of 2 and 49 years old.
■ When should the influenza vaccine be given?	For adults, the influenza vaccine is given one time once annually usually starting in September or whenever it becomes available during the influenza season. Although the timing and duration of influenza seasons vary depending on location, the flu season usually peaks in January or later. There is no benefit in delaying vaccination.
■ What risk factors make this patient a priority to receive an influenza vaccine?	This patient has several risk factors: <ul style="list-style-type: none">■ Age > 50 years.■ Chronic medical conditions: emphysema and high blood pressure.■ Lives in a nursing home. Other individuals who should get vaccinated are those who are aged 6 months to 19 years old, pregnant women, health care workers, and those who are in contact with those at high risk for complications from influenza.
■ Who should not receive the influenza vaccine?	These populations are not recommended to receive an influenza shot: <ul style="list-style-type: none">■ People who have a severe allergy to chicken eggs.■ People who have had a severe reaction to a previous influenza vaccination.■ People who have developed Guillain-Barré syndrome within 6 months of receiving the vaccine.■ Children < 6 months of age.■ People who have moderate to severe illness with fever (vaccination should be postponed until symptoms have resolved).
■ What adverse events are associated with influenza vaccination?	Side effects from the injection last only 1–2 days and can include soreness at the site of injection, low-grade fever, and aches. Side effects from the intranasal vaccine may include runny nose, headache, sore throat, and cough.

■ **How is the spread of disease classified epidemiologically?**

- Endemic: the rate of a disease stays the same within a given population, but some minor fluctuations may occur over time.
- Epidemic: the rate of a disease spreading through a population is greater than expected, i.e., plague in Europe, AIDS in Africa.
- Pandemic: an epidemic that occurs over several countries and affects a sizeable proportion of people in each.

■ **How are preventative health measures classified?**

- Primary: measures to prevent the disease from occurring, such as vaccines.
 - Secondary: measures to enhance early detection of disease and intervention.
 - Tertiary: measures to reduce the impact of disease and promote quality of life.
-

► **CASE 8**

A 24-year-old white woman presents to her family physician for an annual examination. The patient has always been somewhat overweight, but her weight has increased significantly since her last visit. She is 163 cm (5'3") tall and weighs 91 kg (200 lb). The patient does not express concern about her weight gain. She states that she enjoys eating “good food and lots of it” and that she has little desire to exercise. She works in customer relations and spends most of her day sitting at a desk answering phone calls.

■ **What is the patient’s body mass index (BMI)?**

The body mass index is calculated with the following formula: $BMI = \text{body weight (in kg)} / \text{height (in meters)}^2$. BMI is helpful in determining the degree of excess weight and thus distinguishing obesity (the presence of excess body fat) from being overweight (having a weight above the normal range). These BMI cutoffs for overweight and obesity vary by race. For Caucasians, overweight is defined as a BMI between 25 and 29.9 kg/m^2 , while obesity is defined as a BMI $> 30 \text{ kg/m}^2$. Severe or morbid obesity is defined as a BMI $> 40 \text{ kg/m}^2$. For this patient, her BMI is 34.2 kg/m^2 .

■ **What are some of the recognized causes of obesity?**

The major factors contributing to obesity are a sedentary lifestyle and increased caloric intake. Other causes include smoking cessation, drug-induced weight gain (e.g., insulin, certain antipsychotic medications, certain anticonvulsant drugs), neuroendocrine obesity (polycystic ovarian syndrome, Cushing’s syndrome, hypothalamic obesity), and genetic and congenital disorders (leptin deficiency, Prader-Willi syndrome).

■ **What is the role of fat distribution in assessing risk for obesity-related morbidity?**

Abdominal obesity (central obesity) increases the risk for heart disease, diabetes, hypertension, and certain cancers (such as breast cancer) in women. Abdominal obesity is generally assessed by measuring waist circumference. For adults with a BMI of 25–34.9 kg/m^2 , waist circumference of $> 102 \text{ cm}$ (40 in) for men or $> 88 \text{ cm}$ (35 in) for women is considered high risk. For patients with a BMI $> 35 \text{ kg/m}^2$ the value of these cutoff points is less clear.

■ **What comorbid conditions are strongly associated with obesity?**

- Cancer (breast, colon, endometrial, esophageal, kidney, prostate)
 - Diabetes mellitus
 - Gastroesophageal reflux disease
 - Heart disease
 - Hypertension
 - Osteoarthritis
 - Dyslipidemia
 - Gout
 - Hepatobiliary disease
 - Insulin resistance
 - Stroke
-

■ **What are the therapeutic options for treating obesity?**

Obese and overweight patients should first be evaluated for etiologic factors and comorbid conditions that require treatment. Patients should be counseled on diet, exercise, lifestyle, and weight loss goals. For obese patients who have failed to attain weight loss goals with diet and exercise, pharmacologic options are available. For individuals with a BMI > 40 kg/m² or > 35 kg/m² with other comorbidities who have failed to achieve weight loss goals with diet and exercise, bariatric surgery should be considered.

■ **What adverse events are associated with weight loss?**

The adverse events are cardiac arrhythmias, electrolyte derangements (most importantly hypokalemia), hyperuricemia, and psychological sequelae including depression and the development of eating disorders (particularly binge-eating disorders).

► **CASE 9**

An international clinical research group would like to evaluate a new COX-2 inhibitor that aims to limit prostaglandin production in HIV+ women as a means of preventing the development of cervical cancer. The team wishes to enroll HIV+ women from sites around the world and randomize them into two groups. One group will receive the study drug, while the other group receives a nonactive pill that appears identical to the study drug. Neither the investigators nor the subjects will know who is in which group until the end of the study. The women will be followed for 5 years with regular cervical exams every 6 months, using the development of in-situ cervical cancer as the outcome measure.

- | | |
|---|--|
| ■ What study design is being used by the study investigators? | Randomized clinical trial (RCT). A RCT is a common type of experiment used to assess the efficacy of a health care intervention or technology: in this case, a new pharmaceutical. This particular study is randomized in an attempt to equally distribute known and unknown confounders between the two groups. Since neither the subjects nor the investigators know who is receiving the study drug and who is receiving the placebo, the study is considered to be double-blinded and placebo-controlled. RCTs are considered the most reliable form of scientific research since they reduce spurious causality and bias. |
| ■ Why is it important that the placebo resemble the study drug? | In order to control for as many variables as possible in the study, the placebo drug should resemble the study drug in as many ways as possible (size, color, taste, etc). This is an attempt to control for the placebo effect, a measureable effect on the condition under study attributed to taking an inert pill not expected to have any effect. |
| ■ What components are necessary for informed consent? | <ul style="list-style-type: none">■ The subject must have the capacity to make a decision.■ The medical investigator must disclose information about the study in question.■ The subject must comprehend the relevant information.■ The subject must be able to voluntarily grant consent, without coercion. |
| ■ What is a possible null hypothesis and alternative hypothesis for the study? | Given the study description above, a possible null hypothesis (the assumption at the outset of an experiment that <i>no</i> difference exists between the two groups) is: "The study drug has no significant effect over placebo in this population." A possible alternative hypothesis (statement that opposes the null hypothesis) is: "The study drug has a significant effect over placebo in this population." |
| ■ What types of error exist in hypothesis testing? | Type I error is a rejection of the null hypothesis when it is in fact true. In this case, if in reality, the study drug was no better than placebo but the investigator concluded that it was, they would be committing type I error. Type II error, considered less serious, occurs when the null hypothesis is not rejected when it is in fact, false. In this case, if the investigators concluded that the study drug was no better than placebo, but it actually was, they would be committing Type II error. |
-

■ **What scale is being used to measure the outcome?**

In a study, there are many scales on which variables can be expressed:

- Nominal: variable that is determined by categories that cannot be ordered (i.e., hair color: blond, brown, gray, etc.).
- Ordinal: variable in which the order but not the distance between data points can be determined (i.e., low, medium, high).
- Continuous: variable that may have fractional values (i.e., age of subjects).
- Interval: variable in which the order and distance between data points can be determined (i.e., salaries: \$5000, \$10,000, \$15,000, etc.).
- Discrete: variable that is measured solely in whole units (i.e., integers).

In this case, the outcome for each patient can be described as developing cancer or not developing cancer; thus, it is a nominal variable.

► **CASE 10**

A 52-year-old woman presents to her primary care physician after suspicious microcalcifications were observed in her left breast tissue during a regular screening mammogram. She has been informed that a procedure will be necessary to make a definitive diagnosis, but she would like to undergo the least invasive procedure that will still yield a diagnosis. A friend of hers recently had a fine-needle aspiration biopsy (FNA) done, and the patient would like to know if this is a good diagnostic test. The results of a study comparing surgical excisional biopsy, the gold standard for obtaining a diagnosis, and FNA follow below:

SURGICAL BIOPSY			
RESULTS OF FNA	CANCER	NO CANCER	TOTAL
Positive	16	6	22
Negative	2	88	90
Total	18	94	112

- What are the possible outcomes of the fine-needle aspiration, assuming the test results may only be positive or negative?

For any test with only positive or negative results, four possible results may occur:

- True positive: test result is positive, and individual actually has disease.
- False positive: test result is positive, but individual does not have disease.
- False negative: test result is negative, but individual does in fact have disease.
- True negative: test result is negative, and individual does not have disease.

TEST RESULT	DISEASE	NO DISEASE
Positive	True positive (a)	False positive (b)
Negative	False negative (c)	True negative (d)

- What are two common parameters used to measure the validity of a diagnostic or screening test?

Sensitivity and specificity. Sensitivity is the probability that a diseased patient will have a positive test result. Specificity is the probability that a nondiseased person will have a negative test result. A sensitive test is good for ruling out disease because the number of false-negative tests is low (SnOUT), while a specific test is good for ruling in disease because the number of false-positive tests is low (SpIN). A test with high sensitivity is a good screening test while a test with high specificity is a good confirmatory test. An ideal test has both a high sensitivity and high specificity, but there is often a trade-off between the two.

- Calculate the sensitivity and specificity of the FNA test.

$$\text{Sensitivity} = \frac{a}{a + c} \times 100\%$$

Or in this case: $\text{Sensitivity} = \frac{16}{18} \times 100\% = 88.9\%$

$$\text{Specificity} = \frac{d}{b + d} \times 100\%$$

Or in this case: $\text{Specificity} = \frac{88}{94} \times 100\% = 93.6\%$

-
- How do sensitivity and specificity affect predictive value for the same disease population?

The higher the sensitivity of a diagnostic test, the less likely a person with a negative test will actually have the disease; therefore, the negative predictive value of the test will be greater. The higher the specificity of a diagnostic test, the less likely a person with a positive test will be disease free; therefore, the positive predictive value will be greater.

► **CASE 11**

A medical researcher has developed a tool to evaluate the effectiveness of new international health research training programs in encouraging medical students to pursue careers in international health. The evaluation is compared against currently measured external criteria such as length of training, quality of mentorship, length of time spent training abroad, foreign language training, productivity of research faculty, and student satisfaction; the endpoint evaluated is the number of students who, over time, incorporate international health into their career. The tool is administered to a select group of international health training programs for further evaluation.

- | | |
|--|---|
| ■ In order to be useful, this testing system must be valid. What does it mean to have a valid test? | An important feature of a test or instrument is validity. Validity refers to whether a test is measuring what it intends to measure. Validity is also known as accuracy. In the case presented, the testing instrument is considered valid if higher evaluation scores successfully predict a greater number of medical students incorporating international health into their careers. |
| ■ In regards to a measurement, what is reliability? | Reliability, or precision, is another important feature of an assessment tool or test. Reliability refers to the reproducibility of results or the consistency of measurements. Two important types of reliability are inter-rater reliability and test-retest reliability. Test-retest reliability refers to the similarity in test results when a single person interprets the test results repeatedly. Inter-rater reliability refers to how similar the results of a test are when the tests are interpreted by different people. |
| ■ How would this case demonstrate test-retest reliability? | In the case presented, the test would demonstrate test-retest reliability if there is a high correlation between scores for a program evaluated on two separate occasions (there must be no changes in the program between these time periods that would be expected to change the outcome). |
| ■ How would this case demonstrate inter-rater reliability? | In the case presented, the test would demonstrate high inter-rater reliability if two separate test evaluators produce similar scores based on the observed qualities of the program. |
-

► **CASE 12**

A new three-dimensional MRI imaging technique for the detection of renal artery stenosis has been developed. After positive results in small studies, it is being tested versus renal artery angiogram (the gold standard study for the diagnosis of renal artery stenosis) in 1000 women aged 35–55 years old with cardiac risk factors. The results are shown below. The prevalence of the disease being screened for in this population is 10%.

3D MRI RESULT	ANGIOGRAM RESULT		TOTAL
	Pos	NEG	
Positive	90	40	130
Negative	10	860	870
Total	100	900	1000

- How is positive predictive value (PPV) calculated?

Positive predictive value, or the probability that an individual actually has a disease given a positive test result, is calculated by dividing the total true positives by the total number with a positive test:

TEST RESULT	DISEASE	No DISEASE
Positive	True Positive (a)	False Positive (b)
Negative	False Negative (c)	True Negative (d)

Using the above table, $PPV = \frac{a}{a + b} \times 100$

For the diagnostic above, $PPV = \frac{90}{130} \times 100 = 69.2\%$

This means that approximately 7 out of 10 people with a positive test result will actually have the disease.

- How is negative predictive value (NPV) calculated?

Negative predictive value, or the probability that a person does not have the disease given a negative test result, is calculated by dividing the total number of true negatives by those who tested negative:

Using the table above, $NPV = \frac{d}{c + d} \times 100\%$

For the diagnostic above, $NPV = \frac{860}{870} \times 100\% = 98.9\%$

This means that almost everyone who tests negative for disease is truly disease free.

- How does disease prevalence affect the predictive value of a diagnostic test?

For a given sensitivity and specificity, diagnostic tests for diseases with a high prevalence will have a higher positive predictive value than tests for rare disease. Thus, the positive predictive value of a test for a rare condition can be increased by targeting groups that are at higher risk for developing the disease.

Ethics and Legal Issues

Case 1	124
Case 2	125
Case 3	126
Case 4	127

► **CASE 1**

A 53-year-old woman with a known diagnosis of breast cancer presents to her primary care physician complaining of lower back pain. A bone scan reveals “hot spots” in the L3–5 region, and a CT scan of the lower back confirms metastases to the bone. The patient requests that her husband not be informed of these new findings, as she does not want him or any other members of her family to know the extent of her disease.

■ What is the rule of confidentiality?	Information disclosed by a patient to his or her physician as well as information about a patient’s medical or surgical condition is confidential. A physician may not disclose such information to a third party without the expressed consent of the patient.
■ Can this right be waived?	A patient may waive the right to confidentiality, as in the case of information disclosed to an insurance company. A physician, however, may not waive this right without the patient’s expressed consent.
■ What is the Tarasoff decision?	If a patient intends to commit a violent crime, a physician has the duty, as stated by the Tarasoff rule, to warn and protect the intended victim through reasonable means.
■ What are the five other circumstances in which a physician’s ethical and legal responsibilities override the rule of confidentiality?	<ul style="list-style-type: none">■ A suicidal patient.■ A situation involving child or elder abuse.■ A patient with a reportable infectious disease (e.g., a physician is obligated to notify the appropriate health departments of all cases of tuberculosis).■ A patient with a gunshot or stab wound (the police should be notified).■ A patient who is impaired as an automobile driver.
■ What is the rule of disclosure?	Patients have the right to full disclosure regarding their medical status, prognosis, and treatment options. A physician cannot withhold such information from a patient, even with the expressed request from the patient’s family members.
■ When may a physician withhold information from a patient?	A physician may only withhold medical information from a patient in the event that the patient explicitly requests not to be told or when the physician determines that full disclosure will adversely affect the patient’s condition or the patient’s decision-making capacity. This is termed therapeutic privilege .

► CASE 2

A 67-year-old woman is unresponsive in the intensive care unit 2 weeks after sustaining anoxic injury to her brain. The patient has a known history of dilated cardiomyopathy with atrial fibrillation, for which she was closely monitored and taking several medications. Her husband found her unresponsive on the floor in their home upon returning from work 2 weeks ago. The patient has maintained a relatively normal cardiac rhythm since admission to the hospital but has evidence of severe cardiac compromise.

<ul style="list-style-type: none"> ■ What are examples of life-sustaining interventions? 	<p>Life-sustaining interventions include assisted ventilation, nutrition and fluid administration, and medicinal treatments, including antibiotics and dialysis. A patient has the right to refuse such interventions. Additionally, there is no ethical or legal difference between withholding and withdrawing these interventions.</p>
<ul style="list-style-type: none"> ■ What is an advance directive, and how is it binding? 	<p>A written advance directive, such as a living will, is a documented request by a patient that indicates the patient's wishes to withhold or withdraw medical treatment in the event of terminal illness or a persistent vegetative state. Patients may designate specific requests, including a request for DNR (do not resuscitate) or DNI (do not intubate). A patient's family and physicians have the ethical responsibility to respect a patient's written advanced directive.</p>
<ul style="list-style-type: none"> ■ Who should represent a patient who lacks decision-making capacity regarding end-of-life decisions? 	<p>Any patient who lacks capacity for decision making requires a surrogate decision maker to represent him or her, regardless of whether or not the patient has a written advance directive. Surrogate decision makers are given priority in the following order:</p> <ul style="list-style-type: none"> ■ A person holding a durable power of attorney (a legal document whereby an individual designates someone to act on his or her behalf should that individual become disabled or incapacitated). ■ A person designated orally or informally by the patient. ■ A person designated by a state-mandated hierarchy (e.g., spouse, adult child, etc.). ■ A person who is willing to serve in the surrogate role and who knows the patient's preferences and life goals.
<ul style="list-style-type: none"> ■ Is the use of palliative care always ethical and legal? 	<p>Palliative treatment is treatment given for the specific purpose of providing relief from pain and suffering. It is always ethical and legal to provide palliative care, even when the treatment provided may inadvertently hasten the patient's death.</p>
<ul style="list-style-type: none"> ■ What is physician-assisted suicide (PAS), and is it currently legal? 	<p>Physician-assisted suicide involves a physician prescribing a lethal agent to a patient for the specific purpose of the patient self-administering the agent to end his or her own life. PAS is currently illegal in the United States except in Oregon.</p>
<ul style="list-style-type: none"> ■ What is euthanasia, and is it currently legal? 	<p>Euthanasia is the administration of a lethal agent with the intent of ending the life of the individual receiving the agent. Euthanasia is opposed by the AMA Code of Medical Ethics and is currently illegal in the United States. It is not an acceptable method of alleviating a patient's pain. Any patient requesting euthanasia should be immediately evaluated for inadequate pain control and comorbid depression.</p>

► **CASE 3**

A 38-year-old man presents to an oncologist after being recently diagnosed with non-Hodgkin's lymphoma. The patient is the father of three young children and is notably distraught. He and his wife wish for "everything possible to be done." The physician begins to obtain informed consent for a specific treatment regimen.

■ Who has the right to refuse or accept treatment?	Only patients with proven decision-making capacity have the right to accept, refuse, or discontinue treatment. Incompetent patients or temporarily incapacitated patients (e.g., intoxicated patients or medically sedated patients) cannot refuse or discontinue treatment.
■ What is decision-making capacity?	Decision-making capacity refers to the ability of a patient to appreciate his or her medical or surgical condition and its consequences, understand information that is relevant to the condition, deliberate rationally about his or her values, and communicate a voluntary choice.
■ In the process of obtaining informed consent from a patient, what must the physician explain?	A physician must explain the nature of the intervention, the indication(s) for the intervention, the risks and benefits of the intervention, and any alternative options, including the option of no treatment. The patient must willingly accept, without any element of coercion, the medical or surgical intervention before a physician may proceed.
■ What are the two circumstances in which informed consent is not required from a patient?	When emergency treatment is necessary, consent is implied. Once the patient has been stabilized, formal written consent may be obtained. When patients lack decision-making capacity, informed consent may be obtained from a surrogate decision maker (i.e., a family member or legal guardian).
■ When may a physician refuse a patient's request for interventions?	A physician is not ethically obligated to provide an intervention when it is deemed futile. Thus, a physician may refuse a patient's or a family's request for further intervention(s) in the event that the following conditions are met: <ul style="list-style-type: none">■ There is no medical indication for the intervention.■ Maximal intervention is currently failing.■ A given intervention has previously failed.■ There is an established process available to the patient or family if s/he/they wish to continue to seek the intervention (e.g., transfer their care to another provider who will offer the desired intervention).

► **CASE 4**

A 16-year-old girl presents to her pediatrician with her mother, complaining of vague abdominal pain. She states that her pain began early this morning and that it is not associated with any nausea, vomiting, diarrhea, or abnormal vaginal discharge. Her last menstrual period was 3 weeks ago. She is afebrile and healthy appearing, although she is noticeably anxious. The pediatrician asks the mother to step out of the room to have a few moments alone with the patient, and upon further questioning, the patient admits to having recently had her first sexual encounter. She is concerned about being pregnant.

■ From whom must the physician receive consent to treat a minor?	Physicians must receive consent to provide medical treatment from the patient if she or he is 18 years of age or older and from the patient's legal guardian, usually a parent, if the patient is a minor. If the patient is an emancipated minor (see below), the patient may consent for his or her treatment.
■ Who is an emancipated minor?	Minors are emancipated if they are married or in the armed services. They are additionally considered emancipated for the purposes of obtaining medical care for pregnancy, sexually transmitted infections, and drug or alcohol abuse.
■ How does the rule of confidentiality apply to a minor?	Physicians have the obligation to discuss the medical care of a minor with the minor's legal guardian. If, however, the minor is emancipated, then the rule of confidentiality between physician and patient can only be broken with the explicit permission of the patient or if the patient is deemed a danger to him- or herself or another.
■ May a parent refuse medical treatment for his or her child?	A parent has the right to refuse medical treatment for his or her child provided that the lack of treatment does not pose a serious threat to the health of the child. For example, a parent has the right to refuse immunizations, as the lack of immunizations is not considered a serious threat to the child's safety.
■ What happens in emergency situations?	In an emergency situation, consent for treatment of a minor is implied when parents cannot be contacted. If parents request that treatment be withheld even though withholding treatment may jeopardize the child's safety, the physician may initiate treatment against the parents' wishes based on legal precedent.

Gastrointestinal

Case 1	130
Case 2	132
Case 3	134
Case 4	135
Case 5	136
Case 6	138
Case 7	139
Case 8	140
Case 9	141
Case 10	142
Case 11	144
Case 12	146
Case 13	148
Case 14	150
Case 15	151
Case 16	152
Case 17	153
Case 18	154
Case 19	156
Case 20	157
Case 21	160
Case 22	162

► **CASE 1**

A 42-year-old obese woman presents to the emergency department with abdominal pain of several hours' duration. The pain began shortly after she ate a slice of pizza at her son's birthday party. She describes the pain as constant and localized to the upper right side of her abdomen. She admits to having previous episodes of similar pain but adds that these episodes spontaneously resolved within a few hours. Physical examination reveals a temperature of 38.3°C (100.9°F), pulse of 113/min, and blood pressure of 126/82 mm Hg. Abdominal examination is significant for right upper quadrant tenderness with a positive Murphy's sign. A complete blood count reveals a mild leukocytosis of 15.2/mm³. An abdominal ultrasound is shown in Figure 6-1.

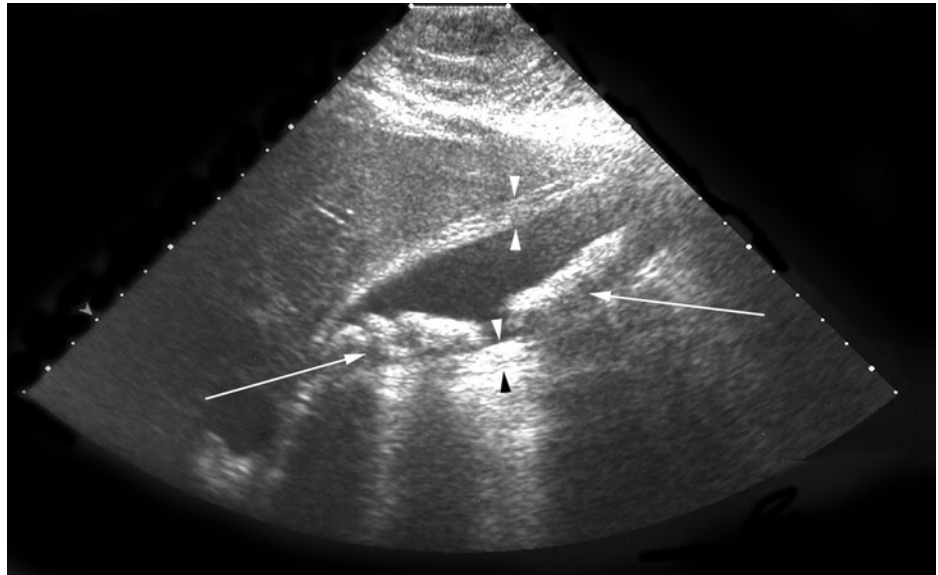


FIGURE 6-1. (Reproduced, with permission, from Brunicaudi FC, Andersen DK, Billiar TR, Dunn DL, Hunger JG, Matthews JB, Pollock RE, Schwartz SI. *Schwartz's Principles of Surgery*, 8th ed. New York: McGraw-Hill, 2005: Fig. 31.14.)

-
- **What is the most likely diagnosis?** Acute cholecystitis. Acute cholecystitis refers to gallbladder inflammation due to prolonged obstruction of the cystic duct, usually by a gallstone. Patients often have a history of biliary colic, especially after fatty food ingestion. Risk factors for acute cholecystitis include the “5 F’s”—Female, Fat (obesity), Fertile (risk increases during pregnancy), Forty (middle-aged), and Fair (Caucasian).
-
- **What are the signs and symptoms of this condition?** Symptoms are typically more severe and of longer duration than those of biliary colic and include:
 - Anorexia.
 - Inspiratory arrest on deep palpation of the right upper quadrant (Murphy’s sign).
 - Low-grade fever.
 - Mild icterus and rebound tenderness.
 - Nausea.
 - Right upper quadrant pain referred to the right scapula.
 - Vomiting.
-

- **What tests and/or imaging tools could be used to confirm the diagnosis?**

Abdominal ultrasound confirms the diagnosis by demonstrating gallstones, bile duct dilatation, gallbladder wall thickening, and pericholecystic fluid (see Figure 6-1). A sonographic Murphy's sign is both sensitive and specific. The absence of the gallbladder on nuclear imaging (HIDA), despite the presence of isotope in the liver and duodenum, is also diagnostic and remains the gold standard. Laboratory studies often reveal a mild leukocytosis and elevated serum bilirubin and aminotransferases. Abdominal plain films are rarely diagnostic since only 10–15% of gallstones are radiopaque.

-
- **What is the most appropriate treatment for this condition?**

Patients should be treated with inpatient fluid resuscitation, antibiotics, and analgesics. Cholecystectomy is the definitive treatment and, ideally, is performed laparoscopically within 2–3 days of onset of symptoms. Preoperative endoscopic retrograde cholangiopancreatography (ERCP) or intraoperative cholangiogram is also recommended to rule out the presence of choledocholithiasis. Patients with significant medical problems can be managed medically with a 4–6-week delay in surgical treatment. Critically ill patients who are ineligible for surgery should be treated with percutaneous cholecystostomy.

► **CASE 2**

A 42-year-old man presents to the emergency department because of pain in his back and around his umbilicus. The pain began 2 days ago after a long night of drinking at his favorite bar. He admits to vomiting twice in the past several hours, with only slight relief of his pain. His temperature is 38.3°C (100.9°F), pulse is 114/min, and blood pressure is 92/62 mm Hg. On physical examination, he appears anxious and is leaning forward in bed with his knees bent. Abdominal examination is notable for epigastric tenderness. Relevant laboratory findings include a WBC count of 15.2/mm³, hemoglobin of 16.2 g/dL, and serum amylase of 950 U/L.

■ What is the most likely diagnosis?	Acute pancreatitis. Acute pancreatitis is secondary to cholelithiasis or alcohol abuse in up to 90% of cases. Biliary pancreatitis is most commonly seen in women older than 50 years, while alcoholic pancreatitis is seen in men between 35 and 45 years old. The overall prevalence of acute pancreatitis is low and is estimated at 0.5%.
■ What is the etiology of this condition?	<ul style="list-style-type: none">■ Alcoholism.■ Gallstones (most common cause).■ Endoscopic retrograde cholangiopancreatography (ERCP).■ Hereditary (typically in patients aged < 20 years).■ Hypercalcemia.■ Hypertriglyceridemia (triglycerides typically > 1000 mg/dL).■ Idiopathic.■ Medication side effects (e.g., thiazide diuretics, azathioprine, 6-mercaptopurine, sulfonamides, estrogen).■ Scorpion stings (<i>Tityus trinitatis</i> in Trinidad).■ Trauma.■ Viral infections.
■ What are the signs and symptoms of this condition?	Acute pancreatitis: Acute pancreatitis presents with epigastric or periumbilical abdominal pain that radiates to the back, chest, flanks, and abdomen. The pain is exacerbated by the supine position. Nausea, vomiting, abdominal distention, low-grade fever, tachycardia, and hypotension are often found on physical examination. Signs of volume depletion indicate severe pancreatitis and should be managed aggressively. Presence of a Cullen sign (periumbilical discoloration) or a Grey Turner sign (flank discoloration) suggests retroperitoneal hemorrhage from the pancreatitis.
■ What tests and/or imaging tools could be used to confirm the diagnosis?	Acute pancreatitis is associated with increased serum amylase and lipase levels, although these can be normal or even low. Leukocytosis, hypocalcemia, and hyperglycemia are also common in acute or chronic pancreatitis. In the presence of normal serum amylase, a CT of the abdomen may confirm the diagnosis.
■ What is the most appropriate treatment for this condition?	Acute pancreatitis is a self-limiting condition and often subsides within 1 week of treatment. Treatment includes removal of the offending agent, if possible. Bowel rest is the mainstay of therapy. Other measures include analgesics for pain, aggressive volume resuscitation, and nasogastric suction. Enteral nutrition is preferred over parenteral nutrition when possible.

- **What are the complications associated with this condition?**

Complications of acute pancreatitis include pseudocysts, fistula formation, hypocalcemia, renal failure, pleural effusion (infected), pancreatic phlegmon/abscess, and sepsis. The risk of mortality secondary to acute pancreatitis can be predicted by scoring systems such as Ranson's criteria, Glasgow's criteria, and APACHE II scores. Ranson's criteria is shown in Table 6-1.

TABLE 6-1. Ranson's Criteria for Predicting Mortality Risk in Acute Pancreatitis

ON ADMISSION: GA LAW	AFTER 48 HOURS: C HOBBS	RISK OF MORTALITY
G lucose > 200 mg/dL	C alcium < 8.0 mg/dL	20% with 3–4 signs
A ge > 55 years	H ematocrit decrease > 10%	40% with 5–6 signs
L DH > 350 IU/L	O xygen PaO ₂ < 60 mm Hg	100% with ≥ 7 signs
A ST > 250 IU/dL	B ase excess < 4 mEq/L	
W BC > 16,000/mm ³	B UN increase > 5 mg/dL	
	S equestered fluid > 6 L	

► **CASE 3**

A 39-year-old G2P2 woman presents to her primary care physician with a sensation of undigested food in the back of her throat and chest pain following meals. She reports difficulty swallowing solids and liquids that started during her last pregnancy but has continued over the past year following delivery. On multiple occasions, she has found undigested food on her pillow in the morning. She reports losing 1.8 kg (12 lb) over the past 2 months due to the discomfort she feels after eating. She has been taking famotidine and omeprazole for her symptoms but reports no relief. Her physical exam is normal. Her abdomen is nontender, nondistended, and soft, with normal bowel sounds.

■ What is the most likely diagnosis?	Achalasia. Achalasia is thought to be due to degeneration or scarring of the esophageal myenteric plexus of Auerbach. Primary idiopathic achalasia accounts for the majority of cases seen in the United States. Secondary achalasia may be caused by gastric carcinoma infiltrating the esophagus, lymphoma, Chagas' disease, and neurodegenerative disease. The loss of inhibitor neurons that produce nitric oxide and vasoactive intestinal peptide leads to uninhibited cholinergic neurons and failure of the lower esophageal sphincter to relax or generate coordinated peristaltic waves.
■ What are the symptoms associated with this condition?	Achalasia has equal incidence in men and women. Frequent symptoms include weight loss, cough, dysphagia, and diffuse chest pain. Dysphagia to solids and liquids is suggestive of motility disorders (i.e., achalasia and diffuse esophageal spasm [DES]), whereas dysphagia to only solids suggests mechanical obstruction (i.e., tumor or Schatzki's rings).
■ How is this condition diagnosed?	Achalasia is diagnosed by barium swallow study and manometry. A barium swallow demonstrating a dilated esophagus with a sharp tapering "bird's beak" is characteristic of achalasia, whereas a "corkscrew pattern" is suggestive of DES. Manometry reveals normal to elevated pressures in the distal esophagus.
■ What is the most appropriate treatment for this condition?	Treatments for achalasia include agents that dilate the distal esophagus (nitroglycerin, anticholinergic agents, calcium channel blockers, opioids), local botulinum toxin injections, balloon dilatation, and sphincter myotomy.

► CASE 4

A 42-year-old woman presents to her primary care physician with a chief complaint of flushing. These episodes arise suddenly and spontaneously, without any trigger she can identify. These episodes usually last about a minute. However, she describes one episode that continued for about 15 minutes. During these episodes, the skin on her chest and face becomes very red, with a mild burning feeling. Over the past few weeks, she has also had increasing problems with diarrhea and has had up to 20 watery, nonbloody stools per day, accompanied by intense abdominal cramping. She denies any health problems prior to these complaints, which began a few months ago. On physical examination, she appears comfortable with normal vital signs. Faint wheezes are heard on her lung exam. She has mildly hyperactive bowel sounds, but her abdomen is soft and nontender. A 24-hour urine collection is obtained and found to contain 274 mg of 5-hydroxyindoleacetic acid (5-HIAA; normal 2–8 mg/day).

■ What is the most likely diagnosis?	Carcinoid syndrome. Carcinoid syndrome is characterized by flushing episodes, diarrhea, wheezing, and right-sided cardiac valvular lesions , and is due to hormone production by the enterochromaffin cells in a carcinoid tumor. Symptoms may follow exertion, excitement, or eating but often have no known trigger. Carcinoid tumors are typically located in the small intestine, and the hormones produced are then cleared by the liver. The presence of carcinoid syndrome signifies hepatic metastasis or primary bronchial location of the carcinoid tumor.
■ What is the pathogenesis of this condition?	Carcinoid tumors are composed of enterochromaffin cells, which synthesize and secrete a variety of humoral factors, most commonly serotonin, histamine, and prostaglandins. Serotonin stimulates intestinal motility and secretion and thus is thought to be responsible for the diarrhea. It may also stimulate cardiac valve fibrosis. Excess serotonin levels can be measured by the excretion of its metabolite, 5-HIAA, in the urine. Histamine, produced by primary gastric carcinoid tumor, is thought to cause the flushing seen in carcinoid syndrome.
■ What tests and/or imaging tools could be used to confirm the diagnosis?	In any patient with unexplained flushing and diarrhea, the urine should be tested for 5-HIAA excretion, which is very sensitive and specific test for carcinoid syndrome. Unfortunately, the test is frequently complicated by the ingestion of certain foods and drugs. If results are equivocal, whole blood serotonin concentration can be determined. The carcinoid tumor itself can be localized by chest and abdominal CT scans.
■ What is the most appropriate treatment for this condition?	Octreotide is a somatostatin analogue that neutralizes serotonin and therefore improves symptoms. The ideal treatment of a carcinoid tumor involves complete surgical resection; this will result in resolution of all symptoms. In the case of hepatic metastases, surgical debulking will improve symptoms. Chemotherapy, typically with 5-fluorouracil and doxorubicin, may also be used.
■ What is the prognosis for patients with this condition?	Patients with localized tumors are estimated to have a 95% 5-year survival rate, which drops to 80% for those with hepatic metastases. Average survival time on octreotide therapy is approximately 12 years.

► **CASE 5**

A 76-year-old man presents to his primary care physician with 2 months of abdominal pain. He reports bloating, diarrhea, fatigue, and an unintentional weight loss of 6.8 kg (15 lb). Vital signs include a temperature of 37.0°C (98.6°F), pulse of 75/min, and blood pressure of 118/74 mm Hg. Relevant laboratory findings include a hemoglobin level of 8.4 g/dL, a WBC count of 10.0/mm³, and a positive fecal occult blood test.

-
- **What is the most likely diagnosis?** Colon cancer. Colorectal cancer is the second leading cause of cancer deaths in the United States. The incidence is similar in men and women and increases with age, peaking at 70–80 years of age. The diagnosis should be suspected in elderly patients with iron deficiency anemia.

 - **What risk factors are associated with an increased incidence of this condition?** Risk factors include age, family or personal history of colorectal cancer, inflammatory bowel disease, adenomatous polyps, and a high-fat, low-fiber diet. Rare hereditary syndromes such as familial adenomatous polyposis (APC), Gardner’s disease, and hereditary nonpolyposis colon cancer (HNPCC) carry a particularly high risk. Ulcerative colitis carries a higher risk than does Crohn’s disease. Villous, sessile colon polyps progress to cancer more frequently than tubular, pedunculated polyps.

 - **What are the signs and symptoms of this condition?** Change in bowel habits, with or without abdominal pain, is the most common presenting symptom. Signs and symptoms of anemia and the presence of blood in the stool are also common. Most colorectal cancers are asymptomatic, but symptoms, if present, vary with the location of the lesion. Right-sided lesions present with anemia from chronic occult blood, while left-sided lesions present with constipation and blood-streaked stools. Rectal lesions present with pain, hematochezia, and tenesmus.

 - **What tests and/or imaging tools could be used to confirm the diagnosis?** Colonoscopy is the gold standard for diagnosis. Air-contrast barium enema (as shown in Figure 6-2) is performed if colonoscopy is incomplete. Complete blood count may demonstrate microcytic anemia, and stool occult blood is positive.

 - **What is the most appropriate treatment for this condition?** Cancer should be staged with contrast CT of the abdomen and colonoscopy with or without endoscopic ultrasound for low rectal tumors. Surgical resection is standard treatment, and adjuvant chemotherapy is used with lymph node involvement. Carcinoembryonic antigen (CEA) levels are not diagnostic but are useful for tracking response to treatment and disease progression and should be measured preoperatively. Recurrence or new tumors can be identified with serial CEA levels, colonoscopy, and abdominal imaging.
-

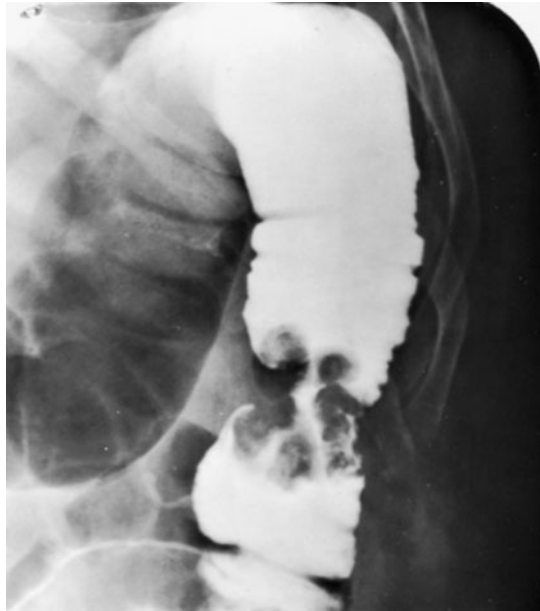

FIGURE 6-2. Barium enema roentgenogram of an encircling carcinoma of the descending colon presenting an “apple core” appearance. (Reproduced, with permission, from Doherty GM, Way LW. *Current Surgical Diagnosis & Treatment*, 12th ed. New York: McGraw-Hill, 2006: Fig. 30-9.)

► **CASE 6**

A 14-year-old girl presents to her pediatrician with abdominal bloating and pain, watery diarrhea, and a blistering rash that has persisted for the past week. The rash is distributed across her elbows and knees. She also notes that over the past week she has unintentionally lost 2.3 kg (5 lb) and seems to bruise easily. She denies any fever, chills, recent camping trips, travel, or change in diet. Physical exam is notable for short stature and delayed puberty. She is at the 40th percentile for height and Tanner Stage I for breast development, and she has not had her first menstrual period. Her abdomen is slightly distended and diffusely tender to palpation. Peritoneal signs are absent. On her lower right leg is a golf ball–size hematoma. Labs are negative for fecal leukocytes and blood.

■ What is the most likely diagnosis?	Celiac disease. Celiac disease is a gluten-induced enteropathy that affects the small intestine and leads to malabsorption. Glutens are a class of high-molecular-weight proteins that are found in wheat, rye, and barley. Celiac disease affects women more often than men (3:2) and is associated with the haplotypes HLA-DR3 and HLA-DQw2.
■ What conditions should be included in the differential diagnosis?	The differential includes tropical sprue, Whipple’s disease, and lactase deficiency. Tropical sprue can be differentiated from celiac disease by the infiltration of monocytes. In Whipple’s disease, periodic acid-Schiff (PAS)–positive macrophages infiltrate the bowel wall. Whipple’s disease can also be diagnosed by PCR of peripheral blood for <i>Tropheryma whippelii</i> . Lactase deficiency symptoms are commonly seen acutely after consumption of dairy products.
■ What are the symptoms associated with this condition?	Patients present with diarrhea (50%), bloating, abdominal pain, steatorrhea, and weight loss. Iron deficiency anemia and evidence of a deficiency of fat-soluble vitamins (osteoporosis, coagulopathy) are common presentations. In children and adolescents, celiac disease can lead to stunted growth. Dermatitis herpetiformis is a pruritic rash that is also associated with celiac sprue.
■ Why does the patient have easy bruising and a hematoma?	Malabsorption leading to vitamin deficiencies, in this case vitamin K. Anemia may also be present due to poor absorption of iron.
■ How is this condition diagnosed?	The disease is diagnosed by small bowel biopsy, which demonstrates characteristic findings of flattened intestinal villi, lymphocyte infiltration, and hyperplasia and lengthening of intestinal crypts.
■ What is the most appropriate treatment for this condition?	Avoidance of gluten products will lead to resolution of symptoms within a few weeks. For severe cases, glucocorticoids can be administered.

► CASE 7

An 83-year-old woman presents to the emergency department for abdominal pain. She was in her usual state of health until approximately 8 hours ago, when she began experiencing a crampy pain in the left lower quadrant of her abdomen. Since the onset of her symptoms, she has vomited twice and has not had a bowel movement. Physical examination reveals a temperature of 38.3°C (100.9°F), pulse of 109/min, and blood pressure of 122/70 mm Hg. Abdominal examination is significant for left lower quadrant tenderness with guarding. Rectal examination is notable for rectal tenderness. A complete blood count reveals a WBC count of 14.1/mm³, hemoglobin level of 13.1 g/dL, and platelet count of 200/mm³.

- | | |
|--|---|
| <ul style="list-style-type: none"> ■ What is the most likely diagnosis? | <p>Diverticulitis. Diverticular disease is most common in the sigmoid colon and is caused by outpouchings of mucosa and submucosa that herniate through the colonic muscle layers. These outpouchings are considered to be false diverticula because they do not comprise all layers of the bowel wall. Diverticulosis refers to the presence of diverticula without inflammation. Diverticulitis refers to perforation of the diverticulum with resulting extraluminal pericolic infection and inflammation. Diverticulitis is estimated to occur in 10–25% of people with diverticulosis. Risk factors for diverticular disease include a low-fiber diet, connective tissue disorders, and advanced age. Approximately 50% of people over age 90 have diverticular disease. In contrast, it is uncommon for diverticular disease to present before age 40, and other diagnoses should be entertained.</p> |
| <ul style="list-style-type: none"> ■ What are the signs and symptoms of this condition? | <p>Diverticulitis is classically associated with lower abdominal pain that is gradual in onset and is localized to the left lower quadrant. A history of diverticulosis may be present. Low-grade fever, accompanied by tachycardia, may also be present. Other findings may include abdominal and/or rectal tenderness, a palpable abdominal mass, nausea, vomiting, and bowel habit changes. By contrast, diverticulosis is asymptomatic or presents with painless rectal bleeding and symptoms of anemia.</p> |
| <ul style="list-style-type: none"> ■ What tests and/or imaging tools could be used to confirm the diagnosis? | <p>Patients with diverticulitis frequently demonstrate an increased WBC count, with a prevalence of polymorphonuclear leukocytes. Abdominal films can show evidence of free air, ileus, or mass. CT of the abdomen and pelvis best confirms the diagnosis of diverticulitis; common findings include a thickened colonic wall or an abscess. Invasive techniques such as barium enema or colonoscopy should be avoided in early diverticulitis due to increased risk of perforation and translocation of colonic bacteria.</p> |
| <ul style="list-style-type: none"> ■ What is the most appropriate treatment for this condition? | <p>Diverticulitis is treated with bowel rest, intravenous fluids, and intravenous broad-spectrum antibiotics. A nasogastric tube is not needed unless there is significant ileus or obstruction. Invasive studies, such as colonoscopy, should be delayed 4–6 weeks due to risk of perforation. Surgical resection of the affected bowel is not recommended after the first episode of diverticulitis because of the low recurrence rate of 20–30%. Surgery may be considered after subsequent episodes. Diverticular bleeding usually resolves spontaneously but should be treated with transfusions and hydration, as needed. If the patient has a perforated diverticulum, immediate surgical resection is required. Patients with asymptomatic diverticular disease should be followed clinically and encouraged to adhere to a high-fiber diet.</p> |
-

► **CASE 8**

A 66-year-old man presents to his primary care physician for difficulty swallowing. Approximately 8 months ago, he began exclusively eating soft foods because of the sensation of solid foods becoming “stuck” in his chest. He reports some anorexia and an unintentional weight loss of 11.3 kg (25 lb) over the past several months. He admits to smoking one pack of cigarettes daily for the past 35 years and drinking two beers a day since he was 18 years old. Physical examination reveals a temperature of 37.0°C (98.6°F), pulse of 86/min, and blood pressure of 136/86 mm Hg. He appears cachectic.

- **What is the most likely diagnosis?** Esophageal carcinoma, likely squamous. Squamous cell carcinoma accounts for the majority of esophageal carcinomas worldwide, although the incidence varies geographically. The incidence in the United States is approximately 20 per 100,000. In Western societies, smoking and alcohol consumption are strongly linked with squamous cell carcinoma. Adenocarcinoma of the esophagus, once an unusual malignancy, now accounts for over 50% of esophageal cancer in Western countries. The increased incidence of adenocarcinoma is the result of the well-established association between gastroesophageal reflux, Barrett’s esophagus, and esophageal adenocarcinoma.

 - **What are the signs and symptoms of this condition?** Esophageal cancer is usually advanced once symptoms are present. Earlier on, esophageal cancer presents with weight loss and anorexia. Dysphagia appears late in the disease. Esophageal cancer usually extends locally. Extension of the primary tumor into the tracheobronchial tree can present as stridor. Other complications of local invasion include tracheoesophageal fistula, which can present as coughing, choking, aspiration pneumonia, and vocal cord compression, resulting in vocal changes. Distant metastases can cause jaundice or bone pain.

 - **What tests and/or imaging tools could be used to confirm the diagnosis?** Routine contrast radiographs can identify large, symptomatic esophageal lesions. Esophageal carcinomas characteristically cause ragged, ulcerating changes in the mucosa. Smaller, potentially resectable tumors are often poorly visualized despite adequate esophagograms. As a result, esophagoscopy should be performed to visualize the tumor and obtain tissue biopsies when there is a high suspicion of cancer. Esophagoscopy should be performed prior to barium studies to maximize visualization of the tumor. Gastrografin is contraindicated if there is concern for a fistula. The extent of tumor spread to lymph nodes should also be assessed with chest and abdominal CT and endoscopic ultrasound. Positron-emission tomography scanning may be useful in assessing resectability.

 - **What is the most appropriate treatment for this condition?** Fewer than 5% of patients with esophageal carcinoma are alive 5 years after diagnosis. Treatment therefore focuses on symptom control. Approaches to palliation include endoscopic dilatation of the esophagus, gastrostomy or jejunostomy placement for nutrition, and stent placement to bypass the tumor. Total resection of the tumor by esophagectomy is feasible in only 45% of cases; esophagectomy has a postoperative mortality rate of 5–10%, and residual tumor cells are frequently present at the resection margins. Radiation therapy and/or chemotherapy are beneficial in some cases, but their use remains controversial.
-

► **CASE 9**

A 45-year-old man presents to his primary care physician for recurrent, burning chest pain after meals. His pain worsens when he reclines and improves with over-the-counter antacid tablets. He also reports a sour taste in his mouth and a persistent cough for the past 6 months. He has smoked two packs of cigarettes daily for the past 20 years. His temperature is 37.0°C (98.6°F), pulse is 91/min, and blood pressure is 142/90 mm Hg. He is 175 cm (69 in) tall and weighs 135 kg (298 lb). His physical examination is unremarkable.

- | | |
|--|---|
| ■ What is the most likely diagnosis? | Gastroesophageal reflux disease (GERD). GERD is the symptomatic reflux of gastric contents into the esophagus due to incompetent barriers at the gastroesophageal junction. Studies suggest that 15% of individuals have symptoms of GERD weekly, and 7% have symptoms daily. |
| ■ What is the pathogenesis of this condition? | Reflux occurs when the gradient of pressure between the lower esophageal sphincter and the stomach is lost. This can be caused by an incompetent lower esophageal sphincter, gastroparesis, or hiatal hernia. Other causes include scleroderma, alcohol, caffeine, nicotine, fatty foods, or increased intra-abdominal pressure due to obesity or pregnancy. |
| ■ What are the signs and symptoms of this condition? | The classic symptoms of GERD include heartburn and a sour taste in the mouth (“water brash”). Reflux of gastric contents into the pharynx, larynx, and tracheobronchial tree can cause chronic cough, bronchoconstriction, pharyngitis, laryngitis, bronchitis, or pneumonia. Chest pain occurs in some patients due to esophageal spasm. |
| ■ What other symptoms can this patient expect to develop over time? | <ul style="list-style-type: none"> ■ Ten percent of patients undergoing endoscopy for GERD are diagnosed with Barrett’s esophagus, a squamocolumnar metaplasia of the esophageal epithelium that carries an increased risk (approximately 0.5% per year) of adenocarcinoma. ■ Patients with chronic reflux are at increased risk for developing peptic strictures, which commonly presents as dysphagia. ■ Upper gastrointestinal bleeding can occur due to mucosal erosions or Barrett’s ulcer. |
| ■ What tests and/or imaging tools could be used to confirm the diagnosis? | GERD is usually diagnosed by clinical history. A successful therapeutic trial with a proton pump inhibitor supports the diagnosis. Diagnostic studies are indicated in patients with persistent symptoms after 6-8 weeks of medical therapy. Mucosal damage can be documented by barium swallow study, esophagoscopy, and mucosal biopsy. Reflux can be assessed with ambulatory 24-hour esophageal pH recording. Esophageal motility studies may be useful in evaluating the competence of the lower esophageal sphincter and esophageal motor function. |
| ■ What is the most appropriate treatment for this condition? | Mild cases of GERD may be treated with lifestyle changes and over-the-counter medications. Lifestyle modifications, including weight reduction, elevation of the head of the bed, and avoidance of tobacco, fatty foods, and alcohol, should be encouraged for all patients. Current recommendations are to add treatment with proton pump inhibitors (PPIs) for symptom relief in moderate to severe cases, with plans to “step down” to H ₂ -receptor blocking agents after several months of PPI therapy. Laparoscopic fundoplication, in which the gastric fundus is wrapped around the esophagus, increases the lower esophageal sphincter pressure and should be considered for patients who require long-term medical therapy or who fail more conservative measures. |

► **CASE 10**

A 52-year-old man presents to his primary care physician for loss of libido that has persisted over the past 6 months. He was diagnosed with diabetes 1 year ago, and he has recently developed painful arthritis in his hands and fingers. Physical examination reveals a temperature of 37.0°C (98.6°F), pulse of 83/min, and blood pressure of 132/90 mm Hg. An abdominal examination reveals splenomegaly, and a genital examination suggests testicular atrophy. Spider nevi are noted on his thorax. A cardiac examination is unremarkable. His complexion is an odd grayish-brown hue. He denies any alcohol consumption. Relevant lab findings are as follows:

Fe: 400 µg/dL
TIBC: 600 µg/dL
Serum ferritin: 500 ng/mL

-
- | | |
|---|--|
| <p>■ What is the most likely diagnosis?</p> | <p>Hemochromatosis. Hemochromatosis is an autosomal recessive iron storage disorder in which increased intestinal iron absorption causes excessive iron deposition in the liver, adrenals, pancreas, testes, and skin. The tissue damage caused by iron deposition results in the classic symptoms of cirrhosis, diabetes mellitus, and hypogonadism. Patients typically become symptomatic between 40 and 60 years of age. Men are 10 times more likely to be affected, particularly those of northern European descent.</p> |
| <p>■ What are the signs and symptoms of this condition?</p> | <p>Early symptoms of hemochromatosis include weakness, abdominal pain, loss of libido, and symptoms of diabetes mellitus. The liver is usually the first organ to be affected, and hepatomegaly is present in > 95% of symptomatic patients. Excessive skin pigmentation is common at the time of diagnosis and results from increased iron deposits in the dermis. Arthropathy develops in 25–50% of patients, with the joints of the hands being the first involved (second and third metacarpophalangeal joints are most commonly affected). Testicular atrophy is seen due to the impairment of hypothalamic-pituitary function by iron deposition and, later, because of end-stage liver disease. Cardiac arrhythmias and congestive heart failure may be present in advanced disease.</p> |
| <p>■ What tests and/or imaging tools could be used to confirm the diagnosis?</p> | <p>Laboratory diagnosis includes an elevated serum iron concentration, an increased serum ferritin, and a transferrin saturation > 45%. Although liver biopsy with hepatic iron index determination was previously required, genetic testing for the C282Y mutation is now sufficient for diagnosis in the correct clinical setting. Liver biopsy may be important in assessing the presence of cirrhosis or when the patient is not homozygous for the C282Y mutation.</p> |
| <p>■ What is the most appropriate treatment for this condition?</p> | <p>Treating hemochromatosis requires removal of excess body iron and supportive treatment of damaged organs. Iron removal is achieved by weekly phlebotomy. After the transferrin saturation and ferritin level normalize, maintenance therapy can be initiated using periodic phlebotomy or chelating agents such as deferoxamine. All first-degree relatives should be screened with a transferrin saturation and ferritin level.</p> |
-

■ **What is the prognosis for patients with this condition?**

Removing excessive iron stores and maintaining them at near-normal levels improves the 5-year survival rate from 33% to 89%. With repeated phlebotomy, hepatomegaly improves, pigmentation of the skin decreases, and cardiac failure may be reversed. Diabetes improves in about 40% of affected patients, but removal of excess iron has little effect on hypogonadism or arthropathies. Hepatic fibrosis may decrease, but cirrhosis is irreversible; end-stage liver disease can be treated with orthotopic liver transplantation. Patients who are cirrhotic at presentation should also be screened for hepatocellular carcinoma.

► **CASE 11**

A 58-year-old man presents to his primary care physician for an employment physical examination. His physical examination reveals a temperature of 37.0°C (98.6°F), pulse of 85/min, and blood pressure of 138/94 mm Hg. Abdominal and chest examinations are unremarkable. An x-ray of the chest required for his employment physical is shown in Figure 6-3.

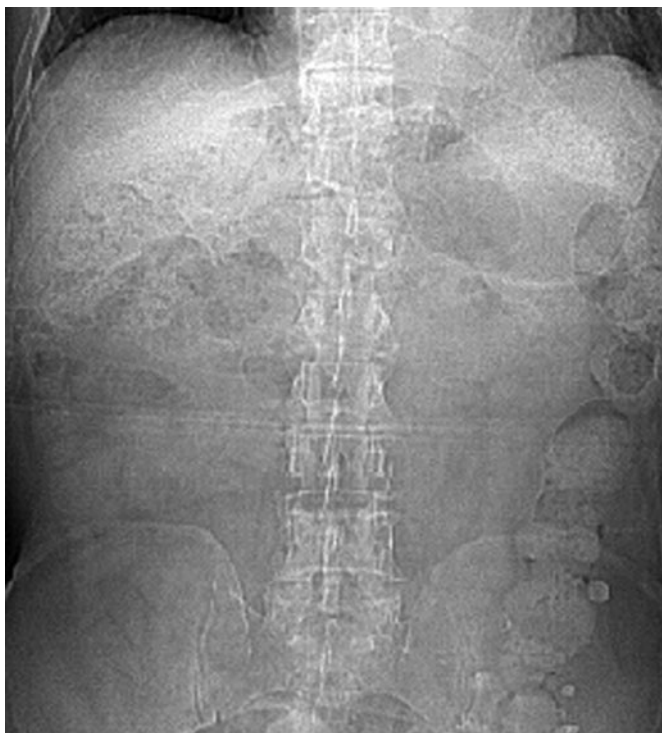


FIGURE 6-3. (Reproduced, with permission, from the Pathology Education Instructional Resource Digital Library (<http://peir.net>) at the University of Alabama, Birmingham.)

-
- **What is the most likely diagnosis?** Hiatal hernia. A hiatal hernia is a herniation of part of the stomach into the thoracic cavity through the esophageal hiatus of the diaphragm. The incidence of hiatal hernias increases with age. The prevalence of hiatal hernia is approximately 60% in the sixth decade of life.

 - **How is this condition classified?** There are two types of hiatal hernias: sliding and paraesophageal. A sliding hiatal hernia is characterized by the upward movement of the gastroesophageal junction and the fundus into the mediastinum. In contrast, a paraesophageal hiatal hernia, which is less common, occurs when the gastroesophageal junction remains below the diaphragm, but a portion of the fundus herniates into the mediastinum.
-

■ **What are the signs and symptoms of this condition?**

Many patients with hiatal hernias are asymptomatic. Sliding hiatal hernias can be associated with gastroesophageal reflux disease. In contrast, a paraesophageal hiatal hernia can present with symptoms of dysphagia and postprandial fullness. Many patients with paraesophageal hiatal hernias are anemic due to chronic bleeding from ulcerated gastric mucosa (Cameron's lesions). Most significantly, paraesophageal hiatal hernias may become incarcerated, requiring immediate surgery.

■ **What tests and/or imaging tools could be used to confirm the diagnosis?**

Asymptomatic hiatal hernias are frequently diagnosed as incidental findings on upright chest x-rays (see Figure 6-3). This appears as an air-fluid level behind the cardiac shadow. Barium studies or esophagoscopy can also confirm the diagnosis.

■ **What is the most appropriate treatment for this condition?**

Sliding hiatal hernias are commonly treated with medical therapies and lifestyle modifications that decrease the symptoms of gastroesophageal reflux disease. In these cases, the hernia itself is not treated. Paraesophageal hiatal hernias are typically repaired with surgical gastropexy, a procedure that attaches the stomach to the rectus sheath and closes the hiatus. This procedure prevents gastric incarceration.

► **CASE 12**

A 25-year-old woman presents to her primary care physician for recurrent abdominal pain. She describes having daily episodes of crampy, lower abdominal pain and diarrhea for the past 6 months. Her diarrhea has occasionally been bloody, and she has experienced an unintentional weight loss of 4.5 kg (10 lb) over the past 3 months. She adds that she had a subjective fever several nights last week. Physical examination reveals a temperature of 37.8°C (100.1°F), pulse of 96/min, and blood pressure of 108/66 mm Hg. She appears thin but is in no acute distress. An abdominal examination reveals diffuse tenderness, and a rectal examination is significant for frank blood.

- **What is the most likely diagnosis?** Inflammatory bowel disease, likely ulcerative colitis (UC). Inflammatory bowel disease is an idiopathic, chronic inflammation of the intestines. Crohn's disease (CD) and UC are the two major types of inflammatory bowel disease. UC is a mucosal disease that usually involves the rectum and extends proximally to involve all or part of the colon. It most commonly presents at 20–25 years of age and is more common in Caucasians, especially Ashkenazi Jews. CD is a transmural process that can affect any segment of the gastrointestinal tract from the mouth to the anus. It has a bimodal age distribution, with the first peak occurring between 15 and 30 years and a second peak occurring between the ages of 60 and 80. Women are affected slightly more often than men, and it is most common in Caucasians and Ashkenazi Jews. Smoking increases the risk of CD, whereas smoking decreases the risk of UC.

 - **What are the signs and symptoms of this condition?** Patients with CD often experience abdominal pain, low-grade fever, weight loss, and watery diarrhea. Rectal involvement (e.g., perianal fissures, fistulas) and upper gastrointestinal symptoms are also common. In contrast, UC is characterized by diarrhea (often bloody), tenesmus, and crampy abdominal pain. Extraintestinal manifestations of IBD occur in nearly 10% of affected patients and include arthritis, episcleritis, uveitis, erythema nodosum (more common with CD) and pyoderma gangrenosum (more common with UC).

 - **What tests and/or imaging tools could be used to confirm the diagnosis?** Patients suspected of having inflammatory bowel disease should have a complete blood count, abdominal plain films, and a stool examination for bacteria, *Clostridium difficile* toxin, and ova and parasites (which should be negative). Colonoscopy or sigmoidoscopy can be useful, but definitive diagnosis is made by biopsy. Colonoscopy in CD may show aphthoid, linear, or stellate ulcers, strictures, cobblestoning, and skip lesions. Colonoscopy in UC may show diffuse and continuous rectal involvement with friable mucosa, edema, and pseudopolyps. Single-contrast barium enema can also show the early radiologic changes of inflammatory bowel disease. Evidence of terminal ileal involvement can be detected with peroral pneumocolon or small bowel follow through.
-

■ **What is the most appropriate treatment for this condition?**

The mainstay of therapy for mild to moderate UC and CD is sulfasalazine and mesalamine (5-ASA) with the exact formulation depending on the target site of action. Corticosteroids and immunosuppressants are used to treat refractory disease and to induce remission in moderate to severe disease. Total colectomy is curative for long-standing UC or toxic megacolon. Surgical resection is not curative for CD, as the disease may recur anywhere in the gastrointestinal tract. However, surgery may be required to treat local complications of the disease.

■ **What is the prognosis for patients with this condition?**

Patients with long-standing diagnoses of UC carry an increased risk of colorectal cancer. As such, after 8 years of disease, patients should undergo frequent monitoring with fecal occult blood screening and colonoscopy. The incidence of secondary malignancy is significantly lower in CD.

► **CASE 13**

A 46-year-old man presents to the emergency department for having three episodes of hematemesis during the past 3 hours. He admits to many years of alcohol and heroin abuse. Physical examination reveals a temperature of 37.8°C (100.1°F). He has a pulse of 102/min and blood pressure of 116/70 mm Hg while supine, and a pulse of 115/min and blood pressure of 90/56 mm Hg while upright. Abdominal examination reveals a distended abdomen with splenomegaly, caput medusae, and a fluid wave. He is anicteric, and spider angiomas are present on his thorax. Neurological examination is unremarkable. Relevant labs are as follows:

Albumin: 2.0 g/d
Bilirubin: 3.0 mg/d
PT: 25 seconds
LAST: 200 U/L
LALT: 250 U/L

-
- | | |
|--|--|
| ■ What is the most likely diagnosis? | Liver cirrhosis. Cirrhosis of the liver is caused by hepatocellular injury, which leads to fibrosis with nodular regeneration and loss of lobular architecture. Clinical features result from liver dysfunction, portosystemic shunting, and portal hypertension. The most common causes of cirrhosis are alcohol and chronic viral hepatitis. Other causes include nonalcoholic steatohepatitis, hemochromatosis, Wilson's disease, α_1 -antitrypsin deficiency, primary biliary cirrhosis, and congestive heart failure. |
| <hr/> | |
| ■ What are the signs and symptoms of this condition? | Weakness, muscle cramps, and weight loss are common symptoms. Advanced cirrhosis may cause anorexia, nausea, vomiting, amenorrhea, impotence, and gynecomastia. Presenting symptoms include hematemesis in 15–25% of cases and fever in up to 35% of cases. Splenomegaly is seen in 35–50% of cases, while hepatomegaly is rare; cirrhosis typically results in a small, shrunken liver. Skin manifestations include spider angiomas, palmar erythema, and Dupuytren's contractures. Caput medusae or hemorrhoids may appear as superficial veins dilate secondary due to intrahepatic obstruction of portal blood flow. The main clinical manifestations of cirrhosis are encephalopathy and ascites, which are late findings. Other late findings include pleural effusions, peripheral edema, ecchymotic lesions, and jaundice. |
| <hr/> | |
| ■ What tests and/or imaging tools could be used to confirm the diagnosis? | Blood chemistries reflect liver dysfunction, with modest elevations of aspartate aminotransferase, alkaline phosphatase, and bilirubin. Prothrombin time prolongation may result from impaired synthesis of clotting factors. Hypoalbuminemia may also be present. Liver biopsy confirms the presence of cirrhosis. Ultrasound, CT, or MRI may assess liver size, identify ascites, and characterize hepatic disease. |
-

- **What is the most appropriate treatment for this condition?**

Variceal bleeds are treated with inpatient intravenous resuscitation, blood transfusion, esophagoscopy with or without banding, and prophylactic antibiotics for spontaneous bacterial peritonitis. Treatment for chronic liver disease includes sobriety, vitamin supplements, and a tailored diet. Salt and protein restriction minimizes fluid retention and encephalopathy, respectively. However, once encephalopathy is controlled, a moderate protein diet will best fulfill the increased protein requirements of cirrhosis. Ascites is treated with diuretics or paracentesis, for those unresponsive to or intolerant of diuretics. Transjugular intrahepatic portosystemic shunt (TIPS) can be used to treat variceal bleeding refractory to standard therapy or intractable ascites with preserved synthetic function; it is used as a bridge to transplantation. Notably, TIPS improves the symptoms of cirrhosis but not the mortality rate. Liver transplantation is primarily indicated in cases of decompensated cirrhosis or hepatocellular carcinoma.

-
- **What is the prognosis for patients with this condition?**

Fifty percent of patients with severe cirrhosis survive 6 months. Patients are also at risk for developing hepatocellular carcinoma, with rates of 3–5% per year. Liver transplantation markedly improves prognosis.

► CASE 14

A 29-year-old woman presents to her primary care physician for repeated episodes of abdominal pain. She reports that, although she has had these episodes since college, the pains have become significantly worse since her divorce 1 year ago. Her abdominal pain is usually focused around her umbilicus, and she describes it as “crampy.” She reports that the episodes of pain are exacerbated by eating and are relieved only by a bowel movement. She also frequently feels bloated. Her recent bowel movements have been loose and watery, with intervening episodes of constipation. She adds that although the abdominal pain is not present at night, she is also having difficulty sleeping. She denies any fevers or weight loss. Physical examination reveals a temperature of 37.0°C (98.6°F), pulse of 69/min, and blood pressure of 118/76 mm Hg. An abdominal examination is remarkable only for diffuse mild abdominal tenderness.

- **What is the most likely diagnosis?** Irritable bowel syndrome. Irritable bowel syndrome is a disorder characterized by abdominal pain and changes in bowel habits in the absence of identifiable gastrointestinal structural abnormalities. Women are diagnosed with irritable bowel syndrome two to three times more often than men. The majority of patients present prior to age 45. Of note, 50% of patients diagnosed with irritable bowel syndrome have comorbid psychiatric disorders.

 - **What are the signs and symptoms of this condition?** By definition, all patients diagnosed with irritable bowel syndrome experience abdominal pain or discomfort. The abdominal pain is highly variable in intensity and location but is usually diffuse and more often in the mid-lower abdomen. It rarely awakens a patient from sleep. Pain is often exacerbated by eating or emotional stress and is relieved by passage of flatus or stool. Patients may also experience constipation alternating with diarrhea, usually with one of these symptoms predominating. Stool may also be accompanied by passage of large amounts of mucus. Bleeding and malabsorption are not features of irritable bowel syndrome, and weight loss does not typically occur. If these symptoms exist, alternative diagnoses should be sought.

 - **What tests and/or imaging tools could be used to confirm diagnosis?** Irritable bowel syndrome is a diagnosis of exclusion based on the clinical presentation. Tests should be used to rule out other possible diagnoses. These tests could include a complete blood count, thyroid-stimulating hormone, electrolytes, stool cultures, fecal occult blood, abdominal films, and barium contrast studies to rule out structural abnormalities. No diagnostic markers exist for irritable bowel syndrome.

 - **What is the most appropriate treatment for this condition?** Patients need reassurance from their physicians about the nature of their symptoms and may also benefit from stress management education. They should be encouraged to eliminate any foods that produce or exacerbate their symptoms. High-fiber diets, bulking agents, and fiber supplements such as psyllium are frequent recommendations. Clinicians have found that antispasmodics, particularly anticholinergic drugs, may provide temporary relief from painful cramps related to intestinal spasm. Antidiarrheal agents like loperamide may be helpful in patients with diarrhea-predominant disease, and tegaserod, a serotonin receptor agonist, may provide relief in patients with significant constipation, but there are some concerns about an increased risk of cardiovascular disease from this medication. Tricyclic antidepressants are often prescribed for both their mood-elevating effects and their physiologic actions.
-

► **CASE 15**

A 33-year-old lawyer presents to his primary care physician with burning epigastric pain that worsens when he is hungry and is relieved by food. He reports that the pain awakens him at night. Over the past month he has gained 6.8 kg (15 lb). He has smoked 2 packs of cigarettes per day for the past 10 years. Due to work-related stress, he often gets severe headaches for which he takes up to seven aspirin tablets per day. Aside from epigastric tenderness on palpation, his physical exam is unremarkable. Vital signs include a temperature of 37°C (98.6°F), pulse of 75/min, and blood pressure of 118/74 mm Hg.

-
- **What is the most likely diagnosis?** Peptic ulcer disease (PUD). PUD encompasses duodenal ulcer (DU) disease and gastric ulcer (GU) disease. PUD is twice as common in men as in women and occurs more frequently in smokers. Other risk factors include infection with *Helicobacter pylori* and use of nonsteroidal anti-inflammatory drugs (NSAIDs) or steroids. The gastric pain in DU is alleviated by food, while that associated with GU is typically exacerbated by food. Zollinger-Ellison (ZE), a gastrin-secreting tumor, often presents with PUD due to gastric acid hypersecretion. To rule out ZE, a secretin stimulation test and a gastrin level should be performed.

 - **What are the symptoms associated with this condition?** Epigastric pain is the most common presenting symptom of PUD. The pain is often characterized as a gnawing or burning sensation that occurs 2–3 hours after a meal. Patients often report being woken up at night by the pain. Pain radiating to the back is concerning for a perforated ulcer. Other symptoms include nausea, vomiting, chest discomfort, melena, or hematochezia.

 - **How is this condition diagnosed?** Endoscopy is the gold standard for diagnosing PUD and for detecting infection with *H. pylori*. Alarming features that warrant endoscopy include the new onset of symptoms in patients > 50 years old, dysphagia, gross or occult GI bleeding, unexplained anemia, unintentional weight loss, anorexia, and significant emesis. *H. pylori* serology (enzyme-linked immunosorbent assay [ELISA]) is the initial recommended screening test for infection in a case of new-onset dyspepsia. A urease breath test can differentiate active infection from residual antibodies, which persist for months after eradication of *H. pylori*.

 - **What are the complications associated with this condition?** Complications of PUD include bleeding (20%), perforation (7%), and gastric outlet syndrome caused by scarring and edema.

 - **What is the most appropriate treatment for this condition?** Patients are encouraged to discontinue smoking and of use NSAIDs. For patients infected with *H. pylori*, a triple regimen including a proton pump inhibitor (PPI), amoxicillin, and clarithromycin, is initiated. H₂ blockers and PPIs are mainstay treatments of PUD. Surgery is indicated only for ulcers refractory to 12 weeks of medical treatment or in cases of perforation, obstruction, or hemorrhage.
-

► **CASE 16**

A 29-year-old man presents to his gastroenterologist with jaundice, fever, pruritus, and abdominal pain. He also notes pale-colored stools. His past medical history is significant for ulcerative colitis. He denies any fever, rashes, or recent illness but has been feeling fatigued for the past 3 weeks. He has been in a monogamous relationship with his wife for the past four years and has no history of sexually transmitted diseases. He works at a fast-food chain and tested negative for hepatitis A, B, and C at the company's last annual screening. Physical exam is notable for splenomegaly, hepatomegaly, and upper right quadrant tenderness. The patient has no rashes. His lungs are clear, and his heart has a regular rate and normal rhythm. Relevant laboratory findings are as follows:

GGT: 80 U/L
Alkaline phosphatase: 300 U/L
Bilirubin: 7 mg/dl
Albumin: 1.0 g/dl
PT: 18 seconds
+ p-ANCA

Magnetic resonance cholangiography shows multifocal stricturing and beading involving both the intrahepatic and extrahepatic biliary tree. Abdominal ultrasound is negative for stones.

■ What is the most likely diagnosis?	Primary sclerosing cholangitis (PSC). PSC is a chronic progressive disease characterized by inflammation and fibrosis of medium- and large-diameter intrahepatic and extrahepatic ducts of the biliary tree. The resulting stricture leads to biliary cirrhosis, portal hypertension, and liver failure. The cause of PSC is unknown, but it has a strong association with ulcerative colitis. Other diseases that can present similarly include ascending cholangitis and cholecystitis; these are unlikely given the lack of stones on ultrasound.
■ How do patients with this condition typically present?	Patients commonly present with fatigue, pruritus, steatorrhea, and deficiencies of fat-soluble vitamins. Fatigue can be profound and pruritus may be debilitating. Up to 80% of patients with PSC have inflammatory bowel disease (most often ulcerative colitis [UC]). However, < 5% of patients with UC develop PSC.
■ What tests and/or imaging tools could be used to confirm the diagnosis?	Cholangiography is the gold standard for diagnosing PSC. Characteristic findings are irregularly distributed areas of fibrosis interrupted by areas of saccular dilatation, resulting in the characteristic beaded appearance. Ultrasound may also show ductal dilatation, splenomegaly, ascites, and increased heterogeneity and echogenicity of the liver due to cirrhosis.
■ What are the typical laboratory findings in this condition?	Laboratory findings in PSC are consistent with a cholestatic liver enzyme picture. Abnormalities include an elevation in γ -glutamyl transpeptidase and alkaline phosphatase (ALP) in addition to mild elevations in aminotransferases (ALT and AST). Once cirrhosis has developed, bilirubin will also be increased. In addition, perinuclear neutrophil cytoplasmic antibody (P-ANCA) is positive in 70% of patients with PSC.
■ What is the most appropriate treatment for this condition?	Short-term palliative treatments include balloon dilatation and stent placement in the obstructed biliary tree. Liver transplantation is the only definitive cure.

► **CASE 17**

A 63-year-old woman who was recently hospitalized 3 weeks for pyelonephritis is brought to the emergency department by her daughter for new-onset diarrhea and fever. The woman appears weak and dehydrated. The daughter reports that her mother has been having continuous episodes of up to 6 loose watery stools for the past 3 days. Her medical history is significant for Parkinson's disease and hypothyroidism, which is well-controlled with levothyroxine. She is otherwise healthy. On physical exam, her temperature is 38.3°C (101°F), pulse is 125/min, blood pressure is 80/40 mm Hg, and respiratory rate is 22/min with 93% oxygen saturation on room air. On examination, she is lethargic but arousable, her neck veins are flat, and her lungs are clear to auscultation. She is tachycardic, but no gallops, murmurs, or clicks are heard. Her abdominal exam is notable for diffuse tenderness, guarding, and rebound tenderness. Lab findings include WBC count of 18,000/mm³ and a positive fecal leukocyte test.

■ What should be the first course of action?	Assess vital signs, secure IV access, order saline, type and cross blood, and call for help. The patient most likely has a perforated colon and will require surgical intervention.
■ What is the most likely diagnosis?	Pseudomembranous colitis. Pseudomembranous colitis is a colonic infection caused by <i>Clostridium difficile</i> , a spore-forming anaerobe normally found in the GI tract. Long-term treatment with antibiotics, especially clindamycin, leads to eradication of the normal gut flora and allows <i>C. difficile</i> to grow unimpeded. <i>C. difficile</i> releases enterotoxins that damage the mucosa of the colon, resulting in a friable mixture of inflammatory cells, fibrin, and bacteria.
■ What other symptoms are common in patients with this condition?	The classical presentation is cramping, diffuse abdominal pain, fever, and watery (occasionally bloody), malodorous stool. Most patients will give a history of antibiotic use and/or recent hospitalization.
■ What are the complications associated with this condition?	A life-threatening complication of pseudomembranous colitis is toxic megacolon. Toxic megacolon, which develops when the infection penetrates all layers of the colon wall, carries the risk of perforation.
■ What tests and/or imaging tools could be used to confirm the diagnosis?	Assays for <i>C. difficile</i> toxin (usually toxin A) are used to diagnose <i>C. difficile</i> colitis. Cultures are not used since <i>C. difficile</i> are among the normal colonic flora. The presence of fecal leukocytes supports the diagnosis. In situations requiring rapid diagnosis or in patients with ileus, sigmoidoscopy can be performed. Yellowish membranous plaque visible on the colonic mucosa is pathognomonic for <i>C. difficile</i> infection. Toxic megacolon is characterized radiographically by dilation of the transverse colon to a diameter > 6 cm and “thumbprinting” (bowel wall edema).
■ What is the most appropriate treatment for this condition?	Stabilize the patient (i.e., fluid resuscitation, blood transfusion, surgical intervention), then stop the offending antibiotic and start the patient on oral metronidazole or vancomycin.

► **CASE 18**

A 47-year-old man presents to the emergency department with colicky abdominal pain that has lasted 5 hours. He reports two episodes of feculent vomiting and a bowel movement 10 hours ago. Physical examination reveals a temperature of 37.0°C (98.6°F), pulse of 92/min, and blood pressure of 134/90 mm Hg. Abdominal examination reveals a mildly distended abdomen with well-healed surgical scars and diffuse tenderness. High-pitched, hyperactive bowel sounds are noted. No hernias are appreciated, and rectal examination is unremarkable. An abdominal film is shown in Figure 6-4.

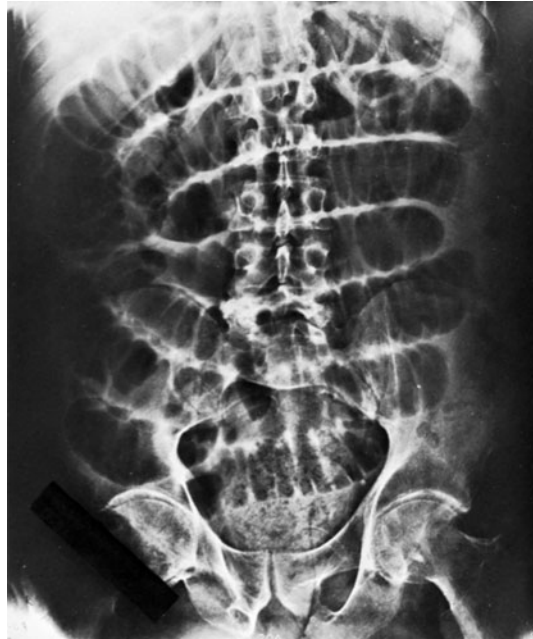

FIGURE 6-4. (Reproduced, with permission, from Doherty GM, Way LW. *Current Surgical Diagnosis and Treatment*, 12th ed. New York: McGraw-Hill, 2006; Fig. 29-6.)

-
- **What is the most likely diagnosis?** Small bowel obstruction. Small bowel obstruction is defined as the blocked passage of bowel contents through the small bowel; the obstruction can be complete or partial. Bowel strangulation from vascular compromise may result in bowel ischemia or infarction. In adults, the majority of small bowel obstructions arise from adhesions from prior abdominal surgery (60% of cases), hernias (10–20%), or neoplasm (10–20%). By contrast, the leading cause of small bowel obstruction in children is hernias.
 - **What are the signs and symptoms of this condition?** Symptoms include colicky abdominal pain, nausea, vomiting, and obstipation. Continued passage of flatus and/or stool 6–12 hours after symptom onset is characteristic of partial rather than complete obstruction. Bowel sounds are described as high-pitched tinkles and peristaltic rushes. Fever, hypotension, rebound tenderness, and tachycardia suggest a surgical emergency. The relative predominance of vomiting and distention depends on the site of obstruction; higher obstruction results in more vomiting and less distention.
-

■ What tests and/or imaging tools could be used to confirm the diagnosis?	Abdominal films (erect and supine; see Figure 6-4) show dilated small bowel loops, air-fluid levels, and a paucity of colonic gas. CT of the abdomen may confirm the diagnosis. Mild leukocytosis is common, particularly with strangulation of bowel.
■ What is the most appropriate treatment for this condition?	Partial obstruction can be managed with supportive care, including nasogastric suction, intravenous hydration, elimination of both solid and liquid oral intake, and electrolyte repletion. Surgery is required in cases of complete obstruction with vascular compromise or symptoms lasting > 3 days. Broad-spectrum antibiotics are commonly administered as prophylaxis against bacterial translocation across the bowel wall.

► **CASE 19**

A 47-year-old man presents to the emergency department with mild abdominal pain that he has had for the past 24 hours. He has noticed an increase in his abdominal girth and has been feeling intermittently confused. He adds that last year another physician told him that his “liver was bad.” Physical examination reveals a temperature of 38.2°C (100.8°F), pulse of 104/min, and blood pressure of 136/74 mm Hg. He is alert and oriented to person and place. He is unable to provide the correct date. An abdominal examination reveals a distended, nontender abdomen with shifting dullness. Neurological examination reveals asterixis.

■ What is the most likely diagnosis?	Spontaneous bacterial peritonitis (SBP). Spontaneous bacterial infection of ascitic fluid is seen in patients with cirrhosis and is likely caused by translocation of enteric bacteria across the gut wall or by mesenteric lymphatics seeding the ascitic fluid. Twenty to thirty percent of cirrhotic patients with ascites develop spontaneous peritonitis. However, the incidence is > 40% in patients with ascitic fluid total protein < 1 g/dL, due to decreased bacterial opsonization and phagocytosis.
■ What is the etiology of this condition?	Nearly all cases of SBP are caused by a single pathogen. Common causative pathogens include enteric gram-negative bacteria (<i>Escherichia coli</i> , <i>Klebsiella pneumoniae</i> , <i>Enterococcus</i> species) or gram-positive bacteria (<i>Streptococcus pneumoniae</i> , viridans streptococci). Anaerobic bacteria are not associated with SBP. Multiple pathogens should raise the possibility of secondary bacterial peritonitis, a surgical emergency.
■ What signs and symptoms are associated with this condition?	Eighty to 90% of patients with SBP are symptomatic, but symptoms are typically mild and nonspecific. Worsening encephalopathy is the most common presenting symptom and may be accompanied by worsening ascites, fever, and abdominal pain secondary to abdominal distention.
■ What tests and/or imaging tools could be used to confirm the diagnosis?	All patients suspected of having SBP should undergo abdominal paracentesis. Ascitic fluid should be sent for cell count, and blood culture bottles should be inoculated at the bedside. Ascitic fluid with a count of > 250 neutrophils/mL is presumptive evidence of SBP. Patients with < 1 g/dL of protein in their ascitic fluid are at high risk of developing SBP.
■ What is the most appropriate treatment for this condition?	Patients with ascitic fluid consistent with SBP are presumed to be infected and should be started on intravenous antibiotics, regardless of symptoms. Cefotaxime is the antibiotic of choice, but ceftriaxone or a quinolone and metronidazole are good alternatives. Supplemental administration of intravenous albumin may reduce mortality by decreasing the incidence of hepatorenal syndrome. Response to therapy can be documented by a 50% decrease in the polymorphonuclear neutrophil count on repeat paracentesis 48 hours after the initiation of therapy.
■ What is the prognosis for patients with this condition?	The mortality rate of SBP is up to 30% during hospitalization and up to 70% by 1 year due to progressive liver disease. Patients who develop SBP should be maintained on long-term antibiotic prophylaxis (e.g., weekly norfloxacin) and evaluated for liver transplantation. The patient’s ascites should also be optimally controlled.

► CASE 20

A 50-year-old surgeon presents to his primary care physician with a 2–3-week history of fatigue and right upper quadrant discomfort. During the past week, he has noticed yellowing of his eyes. He was previously healthy and has no chronic medical problems. Several months ago, while supervising a new intern on a trauma case he was accidentally stuck with a needle. He did not seek medical care at that time due to the patient's critical condition but thinks that the patient may have been a drug user. His physical exam is notable for jaundice, hepatomegaly, and right upper quadrant tenderness. His labs include:

Bilirubin: 8.9 mg/dl
 AST: 1398 U/L
 ALT: 2200 U/L
 Alkaline phosphatase: 290 U/L
 INR: 1.2
 HbsAg, HBeAg, HBV DNA: positive
 Anti-HBs, anti-HBe: negative

-
- | | |
|--|---|
| ■ What is the most likely diagnosis? | Viral hepatitis. Acute viral hepatitis presents with transaminase levels in the 100–5000 range; higher transaminase levels are typically associated with acute toxic injury. Etiologies of viral hepatitis include hepatitis A, B, C, D, and E viruses; Epstein-Barr virus (EBV), cytomegalovirus (CMV), herpes simplex virus (HSV), and coxsackievirus. |
| ■ What are the signs and symptoms associated with this condition? | The prodromal symptoms of viral hepatitis are systemic and variable. Constitutional signs include nausea and vomiting, fatigue, malaise, and low grade fever. During acute infection, the liver becomes enlarged and tender and may be associated with right upper quadrant pain and discomfort. In rare cases, patients can present with a cholestatic picture (elevations predominantly in alkaline phosphatase). Patients with acute Hepatitis C are usually asymptomatic for years. |
| ■ What laboratory tests could be used to confirm the diagnosis? | Disease is diagnosed with serological tests (see Tables 6-2 and 6-3). |
-

TABLE 6 - 2. Clinical and Laboratory Features of Viral Hepatitis

FEATURE	HAV	HBV	HCV	HDV	HEV
Incubation (days)	15–45	30–180	15–160	30–180	14–60
Onset	Acute	Insidious or acute	Insidious	Insidious or acute	Acute
Transmission	Fecal-oral	IV drug use, needle stick, maternal-fetal transmission, sexually transmitted	IV drug use, needle stick	IV drug use, needle stick	Fecal-oral
Clinical severity	Mild	Occasionally severe	Moderate	Occasionally severe	Mild
Serology	Diagnosis: IgM anti-HAV Previous infection: IgG anti-HAV	Acute diagnosis: HBsAg, IgM anti-HBc Chronic diagnosis: IgG anti-HBc, HBsAg Markers of replication: HBeAg, HBV DNA	Acute and chronic infection: anti-HCV, HCV RNA (PCR)	Diagnosis: anti-HDV, HDV RNA HBV/HDV coinfection: IgM anti-HBc and anti-HDV HDV superinfection: IgG anti-HBc and anti-HDV	Diagnosis: IgM/IgG anti-HEV (assays being developed); virus in stool
Progression to chronicity	None	Occasional (1–10%) (90% of neonates)	Common (85%)	Common	None
Cancer	None	+	+	±	None
Prognosis	Excellent	Worse with age, debility	Moderate	Acute, good Chronic, poor	Good, except in pregnant women
Prophylaxis	IG Inactivated vaccine	HBIG Recombinant vaccine	None	HBV vaccine (none for HBV carriers)	Vaccine
Therapy	None	Pegylated interferon, Lamivudine, Adefovir	Pegylated interferon plus ribavirin	Interferon ±	None

Modified, with permission, from Fauci AS, Braunwald E, Kasper DL, Hauser SL, Longo DL, Jameson JL, Loscalzo J (Eds.), *Harrison's Principles of Internal Medicine*, 17th ed. New York: McGraw-Hill, 2008: Table 298-2.

TABLE 6-3. Common Serologic Patterns in Hepatitis B

DIAGNOSIS	HbsAg	ANTI-HBs	ANTI-HBc	HBeAg	ANTI-HBe
Acute hepatitis B	+	-	IgM	+	-
Infectious chronic Hepatitis B	+	-	IgG	+	-
Noninfectious chronic Hepatitis B (low viral load)	+	-	IgG	-	+
Vaccination (immunity)	-	+	-	-	-

Modified, with permission, from Fauci AS, Braunwald E, Kasper DL, Hauser SL, Longo DL, Jameson JL, Loscalzo J (Eds.), *Harrison's Principles of Internal Medicine*, 17th ed. New York: McGraw-Hill, 2008: Table 298-3.

► **CASE 21**

A 19-year-old woman presents to her primary care physician for recent changes in her mood. Over the past 6 months she has felt increasingly depressed and anxious. She believes that her symptoms have affected her extracurricular activities, as she feels uncoordinated on the soccer field. Physical examination reveals a temperature of 37.0°C (98.6°F), pulse of 74/min, and blood pressure of 118/82 mm Hg. An abdominal examination reveals hepatomegaly without signs of jaundice. Neurological examination shows a subtle resting tremor and increased tonicus. An ophthalmologic examination is significant for green-brown deposits in the cornea bilaterally.

- **What is the most likely diagnosis?** Wilson's disease. Wilson's disease, or hepatolenticular degeneration, is an autosomal recessive disorder caused by a defect in copper transportation, resulting in excessive deposition of copper in the liver, brain, and other tissues. The prevalence of the disease is approximately 1 in 30,000, with most patients presenting between the ages of 5 and 40. Clinical manifestations are caused by copper toxicity and include a multitude of signs and symptoms related to hepatic, neurologic, hematologic, and renal impairment.

 - **What is the pathogenesis of this condition?** Wilson's disease is caused by excessive absorption of copper in the small intestine and decreased copper excretion by the liver. In early stages of the disease, the excess copper is stored in the liver. As the disease progresses, the excess copper damages the hepatocytes and eventually leaks into the circulation and deposits in the brain, eyes, and other organs.

 - **What are the signs and symptoms associated with this condition?** The clinical presentation of Wilson's disease is variable. Approximately 40% of patients present with signs and symptoms of chronic hepatocellular disease, either chronic hepatitis or cirrhosis. Others may present with asymptomatic liver function abnormalities. Patients whose disease progresses beyond hepatic dysfunction may present with neuropsychiatric symptoms such as tremors, rigidity, clumsiness of gait, slurring of speech, uncontrollable grinning (risus sardonicus), and drooling. Patients may also present with acute or fulminant liver failure complicated by hemolytic anemia and renal failure. Wilson's disease is classically associated with Kayser-Fleischer rings, green-brown deposits of copper in Descemet's membrane, one of the deeper layers of the cornea.

 - **What tests and/or imaging tools could be used to confirm the diagnosis?** Serum aminotransferases are moderately elevated in patients with Wilson's disease. The aspartate aminotransferase concentration most commonly exceeds that of alanine aminotransferase because of low-grade hemolysis. Serum ceruloplasmin levels are classically diminished; however, this does not establish or exclude the diagnosis. Patients with Wilson's disease also typically have increased urinary copper excretion. Slit-lamp examination for Kayser-Fleischer rings or liver biopsy with stains for copper and quantitative copper determination confirm the diagnosis. A rising bilirubin and a falling alkaline phosphatase should raise the suspicion for Wilson's disease in patients with fulminant liver disease.
-

- **What is the most appropriate treatment for this condition?**

Copper removal is achieved by the administration of D-penicillamine, a potent copper chelator. Copper reaccumulation is prevented with lower doses of chelators or oral zinc. Patients should restrict their dietary copper intake by avoiding copper-rich foods like liver, shellfish, and legumes. Anticopper therapy must be lifelong. Although resolution of symptoms may be incomplete, with treatment, liver function may partially recover within a year, and neurologic and psychiatric symptoms may improve between 6 and 24 months.

► **CASE 22**

A 40-year-old man presents to his primary care physician for recurrent abdominal pain. He reports that, despite strict adherence to his peptic ulcer disease medication regimen, he has frequent episodes of burning abdominal pain. He also reports diarrhea and an unintentional weight loss of 4.5 kg (10 lb) over the past 6 months. He adds that he is very concerned about his symptoms because of a strong family history of tumors. His brother was recently diagnosed with a pituitary tumor, and his father had “some sort of tumor in his pancreas” at age 46. Physical examination reveals a temperature of 37.0°C (98.6°F), pulse of 83/min, and blood pressure of 130/70 mm Hg. His physical examination is otherwise unremarkable.

- **What is the most likely diagnosis?** Zollinger-Ellison syndrome. Zollinger-Ellison syndrome is caused by gastrin-secreting neuroendocrine tumors (gastrinomas), which result in hypergastrinemia and acid hypersecretion. The incidence of Zollinger-Ellison syndrome varies from 0.1–1% in individuals presenting with peptic ulcer disease. Males are more commonly affected than females, with most patients diagnosed between ages 30 and 50. Primary gastrinomas arise in the pancreas (25%), duodenal wall (45%), or lymph nodes (5–15%). One-third of gastrinomas have already metastasized to the liver at the initial presentation and > two-thirds are malignant. Twenty-five to fifty percent of gastrinomas are associated with multiple endocrine neoplasia type 1 (MEN1) syndrome.

 - **What are the signs and symptoms associated with this condition?** Over 90% of patients with Zollinger-Ellison syndrome develop peptic ulcers. Gastrinoma should be suspected in patients with ulcers in unusual locations (second part of the duodenum and beyond), ulcers refractory to medical therapy, ulcer recurrence after acid-reducing surgery, ulcers presenting with frank complications, or ulcers in the absence of *Helicobacter pylori* or NSAID ingestion. Other symptoms of Zollinger-Ellison syndrome include recurrent abdominal pain, nausea, vomiting, GERD, diarrhea, steatorrhea, and weight loss. In most cases, the symptoms of Zollinger-Ellison syndrome are indistinguishable from other causes of peptic ulcer disease and therefore may go undiagnosed.

 - **What tests and/or imaging tools could be used to confirm the diagnosis?** A fasting serum gastrin concentration > 150 pg/mL is the most sensitive and specific method of diagnosing Zollinger-Ellison syndrome. Patients should be instructed to stop taking H₂-receptor antagonists for 24 hours or proton pump inhibitors for 6 days prior to obtaining a fasting gastrin concentration. A secretin stimulation test should also be performed to distinguish Zollinger-Ellison syndrome from other causes of hypergastrinemia. MEN1 syndrome should be excluded in all patients by obtaining serum parathyroid hormone (PTH), prolactin, luteinizing hormone–follicle-stimulating hormone (LH-FSH), and growth hormone (GH) levels. Multiple imaging modalities are often required to identify the location of the gastrinoma and can include CT, MRI, octreotide scanning, and endoscopic ultrasound.

 - **What is the most appropriate treatment for this condition?** Zollinger-Ellison syndrome can be cured by surgical resection in up to 30% of patients. However, cure can be achieved only if the gastrinoma is resected before metastatic spread has occurred. Regardless of resectability, high-dose proton pump inhibitors are the treatment of choice and are recommended to decrease acid production and provide symptomatic relief.

 - **What is the prognosis for patients with this condition?** The 15-year survival of patients without liver metastases at initial presentation is > 95%. Thirty percent of patients with hepatic metastases have a survival of 10 years.
-

Hematology/Oncology

Case 1	164
Case 2	166
Case 3	167
Case 4	168
Case 5	170
Case 6	171
Case 7	172
Case 8	174
Case 9	175
Case 10	176
Case 11	178
Case 12	180
Case 13	182
Case 14	183
Case 15	184
Case 16	186
Case 17	188
Case 18	190
Case 19	191
Case 20	192
Case 21	193
Case 22	194

► **CASE 1**

A 57-year-old man is referred to a hematologist for a detailed workup of severe anemia. His hemoglobin level is 8.2 mg/dL, but testing reveals no evidence of occult bleeding. For the past several weeks, he has noticed blood on his toothbrush nearly every day and complains that he bruises more easily than before. He has become increasingly fatigued and has cut back on his hours at the waste management company he owns because he often becomes short of breath with mild exertion. In addition, he complains that “I always have a cold; I can’t get rid of it.” In addition to the low hemoglobin, relevant laboratory results include a WBC count of 3200/mm³, reticulocyte count of 0.8%, and platelet count of 30,000/mm³. His peripheral smear shows myeloblasts and markedly decreased granulocytes.

-
- **What is the most likely diagnosis?** Acute myelogenous leukemia (AML). While often idiopathic, AML may be caused by radiation therapy, chemical exposure such as excessive benzene exposure, and alkylating chemotherapeutic agents. AML is a clonal malignancy. It may present de novo or arise out of myelodysplasia or another hematologic malignancy. It is characterized by an increase in blast cells in the bone marrow (> 20%), as well as impaired production of normal RBCs, platelets, and neutrophils. Patients often present with pallor, fatigue, weakness, palpitations, dyspnea on exertion, and other symptoms of anemia. They may also have gingival bleeding, easy bruising, and conjunctival hemorrhages, which indicate thrombocytopenia. In addition, minor infections of the skin are common. Major infections (pneumonia, meningitis, etc.) are less likely because severe neutropenia may not occur until chemotherapy is instituted.

 - **What is the pathogenesis of this condition?** AML is associated with characteristic somatic mutations or translocations in hematopoietic stem cells. These mutant progenitors do not produce normal red cells, granulocytes, or platelets and have a survival and proliferative advantage over normal cells. Since the growth of normal cell lines is suppressed relative to the mutant cells, patients develop anemia, thrombocytopenia, and neutropenia.

 - **What tests could be used to confirm the diagnosis?** A CBC and bone marrow biopsy both aid in the diagnosis of AML. Patients are typically anemic due to their inability to produce normal RBCs, as reflected by reticulocyte counts in the range of 0.5–2.0%. The platelet count will be low, often < 50,000/μL. The WBC count will generally be < 5000/mm³, while the total neutrophil count will be < 1000/mm³. On a peripheral smear (see Figure 7-1), the major abnormality is seen in the white cells. Some patients will have Auer rods (elliptical cytoplasmic inclusions; Figure 7-2) in their blast cells, although this is more common in acute promyelocytic leukemia. A bone marrow biopsy will contain > 20% blast cells.

 - **What is the most appropriate treatment for this condition?** The goal of treatment is to induce remission. Induction therapy typically combines an anthracycline antibiotic with cytarabine. Complications include hyperleukocytosis and pancytopenia. Red cell transfusions are needed to maintain the hematocrit during treatment. In order to induce sustained remission, either consolidation chemotherapy or allogenic bone marrow transplantation is necessary.
-

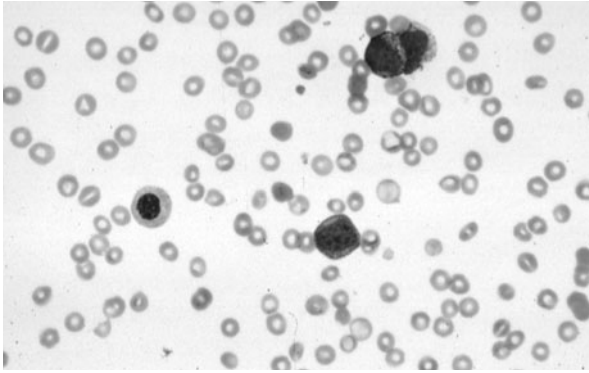


FIGURE 7-1. Peripheral blood smear shows few platelets and myeloblasts with what appears to be basophilic and eosinophilic metamyelocytes. (Reproduced, with permission, from the Pathology Education Instructional Resource Digital Library [<http://peir.net>] at the University of Alabama, Birmingham.)

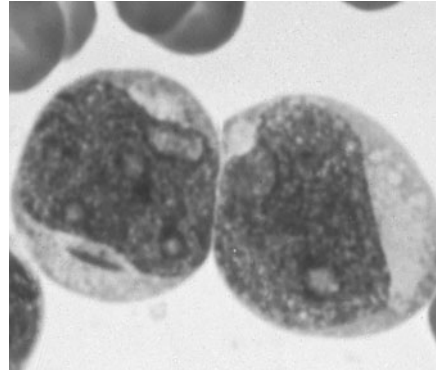


FIGURE 7-2. Leukemic myeloblasts with an Auer rod. Note two to four large, prominent nucleoli in each cell. (Reproduced, with permission, from Lichtman MA, Beutler E, Kipps TJ, Seligsohn U, Kaushansky K, Prchal JT. *Williams Hematology*, 7th ed. New York: McGraw-Hill, 2006: Color Plate XVI-2.)

► **CASE 2**

A 4-year-old girl presents to her pediatrician with a 2-week history of cough, nasal congestion, and fatigue. Her mother has brought her in three times in the past month for unremitting cold symptoms; each time, the child has been diagnosed with a viral upper respiratory infection and advised on symptomatic care. She has been sleeping more than usual for the past few days, and she awoke this morning with a new rash. On physical examination, she has a temperature of 37.2° C (99.0° F) and pulse of 140/min. She appears pale, with scattered petechiae across her lower legs, hepatosplenomegaly, and cervical lymphadenopathy.

■ How should the workup proceed for this patient's condition?	This child presents with symptoms suggesting multiple cytopenias; therefore, the first test should be a complete blood count (CBC) with peripheral blood smear. In this patient, the CBC will show neutropenia, anemia, and thrombocytopenia with lymphoblasts on peripheral smear.
■ What is the most likely diagnosis?	Acute lymphoblastic leukemia (ALL). ALL is the most common malignancy of childhood. While suggested by the presence of lymphoblasts on peripheral smear, a diagnosis of ALL must be confirmed by bone marrow aspirate and/or biopsy showing > 25% lymphoblasts.
■ What conditions should be included in the differential diagnosis?	<ul style="list-style-type: none">■ Chronic viral infection (Epstein-Barr virus [EBV], cytomegalovirus [CMV]).■ Immune thrombocytopenic purpura (ITP).■ Aplastic anemia.■ Autoimmune hemolytic anemia.■ Juvenile rheumatoid arthritis.
■ What are the stages of treatment, and what chemotherapies are commonly used?	Induction is the first month of therapy and commonly involves oral prednisone or dexamethasone, intramuscular asparaginase, intravenous vincristine, and intrathecal methotrexate; over 95% of patients have minimal residual disease on repeat bone marrow examination after this stage. Consolidation involves continued systemic therapy with intrathecal and cranial radiation therapy to eradicate CNS "sanctuaries" of disease. A brief intensification of therapy following consolidation has been shown to improve survival in pediatric patients. Finally, maintenance chemotherapy is continued for several years to ensure remission. Hematopoietic stem cell transplantation may be used to treat relapsed patients.
■ What patient or disease characteristics indicate a negative prognosis?	<ul style="list-style-type: none">■ Patient age >10 years.■ WBC count at diagnosis >50,000/mm³.■ CNS or testicular involvement.■ Residual disease following induction therapy.■ Chromosomal translocations t(9;22) or t(4;11).
■ The patient begins induction chemotherapy but develops acute renal failure with a uric acid level of 16 mg/dL. What is the problem, and what is the most appropriate treatment?	Tumor lysis syndrome typically occurs early in the treatment of patients with a high tumor burden due to the lysis of tumor cells. Laboratory hallmarks include hyperkalemia, hyperphosphatemia, hypocalcemia, and hyperuricemia. Aggressive hydration, alkalinization of urine, and administration of allopurinol (which inhibits uric acid production) are important components of treatment. Hemodialysis may be necessary if renal failure is severe.

► CASE 3

A 67-year-old man presents to his primary care physician with one episode of syncope, fatigue, and weight loss for several months. He fainted earlier that morning and felt palpitations prior to passing out. He also complains of alternating constipation and diarrhea, tingling in his right hand, and difficulty forming words. On physical examination, his vital signs include a temperature of 37.2° C (99.0°F) and respiratory rate of 12/min. His seated blood pressure is 110/75 mm Hg with pulse of 75/min; after standing, blood pressure is 95/60 mm Hg with pulse of 104/min. Hepatomegaly, 1+ peripheral edema, and macroglossia are noted. An electrocardiogram demonstrates multiple premature ventricular contractions. Urinalysis reveals proteinuria, and urine protein electrophoresis reveals monoclonal kappa light chains.

-
- | | |
|---|---|
| <ul style="list-style-type: none"> ■ What is the most likely diagnosis? | <p>Systemic amyloidosis. This collection of diseases involves the extracellular deposition of fibrillar proteins in multiple organ systems. They are classified by the type of protein in the deposit; there are 24 known proteins, but the most common types are light-chain amyloidosis (AL), transthyretin amyloidosis (ATTR), and amyloidosis A (AA). Macroglossia is typically a feature of AL.</p> |
| <ul style="list-style-type: none"> ■ What tests and/or procedures could be used to confirm the diagnosis? | <p>Confirmation of amyloidosis requires tissue biopsy; fat aspiration or rectal biopsy is usually performed. Tissues are stained with Congo red and examined under polarized light. Amyloid proteins exhibit a characteristic apple-green birefringence.</p> |
| <ul style="list-style-type: none"> ■ What are the characteristics of the different types of this disease? | <p>Immunohistochemistry of a biopsy sample is the gold standard for identifying the type of amyloidosis. AL is associated with monoclonal plasma cell disorders, in which excess production of light-chain immunoglobulin leads to fibrillar deposition in tissues. A clonal spike of immunoglobulin can be seen on electrophoresis of urine or serum; bone marrow examination can also demonstrate plasma cell proliferation. In ATTR, the transthyretin protein forms the amyloid deposits; there are senile and familial forms. AA is seen in patients with chronic inflammatory diseases, which can be infectious, autoimmune, neoplastic, or inherited. Serum amyloid A (SAA) is an acute-phase reactant; only certain alleles encode for the amyloidogenic form of SAA.</p> |
| <ul style="list-style-type: none"> ■ What is the most appropriate treatment for this condition? | <p>Given the resemblance of AL to myeloma, chemotherapy is the first-line treatment. Regimens typically include melphalan and prednisone. A doxorubicin analog, 4'-iodo-4'-deoxydoxorubicin (IDOX), has shown potential in breaking down existing amyloid fibrils. Supportive therapy, including hemodialysis for renal failure and diuretics and antiarrhythmics for heart failure, may also be indicated depending on the degree of organ dysfunction.</p> |
-

► **CASE 4**

A 60-year-old white man presents to his family physician for a full physical examination. His last doctor's visit was 2 years ago when he had the flu. He explains that his health has been "relatively okay" and that he has had many colds but no ongoing medical problems. Upon further probing, he admits that he has been increasingly tired for the past 6 months and that he has lost about 9 kg (20 lb) over the past 2 years. He insists that he is healthy and needed to lose the weight, but he denies any exercise regimen or specific dietary restrictions. His vital signs are within normal limits, and he appears comfortable. Upon examination, he has palpable lymph nodes in his neck and axillae. He denies any pain on palpation; the nodes range from 1.0 cm to 3.0 cm in diameter. His abdominal examination is significant for hepatosplenomegaly. His chemistry test values are within normal limits; his WBC count is 25,200/mm³ with 90% lymphocytes.

- **What is the most likely diagnosis?** Chronic lymphocytic leukemia (CLL). CLL is a B-cell malignancy that occurs in older patients; the median age at presentation is 65 years. The proliferating B cells cannot effectively recognize antigen, so patients are often immunocompromised and may have coexistent hypogammaglobulinemia. Some patients present with fatigue or lymphadenopathy, while the majority are asymptomatic. Eventually, some patients will develop hepatomegaly or splenomegaly. The disease progresses very slowly in most cases; rarely, patients will develop an aggressive large cell lymphoma (Richter's syndrome). Staging for the nonzero stages of CLL (more than just lymphocytosis) follows the Rai system, which can be remembered using the mnemonic **LOATH**:

I—Lymphocytosis + Lymphadenopathy
II—Organomegaly (splenomegaly or hepatomegaly)
III—Anemia
IV—Thrombocytopenia
 - **What is the pathogenesis of this condition?** CLL is a monoclonal proliferation of mature lymphocytes. Despite their morphological maturity, these B cells are unable to produce functional antibodies. This renders patients more susceptible to infection, but patients may be asymptomatic for prolonged periods, given the slow progression of the disease.
 - **What tests could be used to confirm the diagnosis?** A CBC and peripheral blood smear demonstrating isolated lymphocytosis are virtually diagnostic for CLL. The WBC count will usually be > 20,000/mm³, with a total lymphocyte number of > 6,000/mm³. The cells will be small, mature, and structurally indistinguishable from immunocompetent lymphocytes (Figure 7-3). They express both the CD19 surface marker commonly found on B cells, as well as the CD5 marker usually attributed to T cells; this finding in combination with the lymphocytosis is diagnostic for CLL. Cyclin D should be evaluated to rule out mantle cell lymphoma, a common mimic.
-

- **What is the most appropriate treatment for this condition?**

In the case of indolent CLL, no treatment is required. If patients are symptomatic—fatigued, anemic, thrombocytopenic, or presenting with lymphadenopathy—chemotherapy, often with purine analog-based therapy (i.e., fludarabine) is warranted. If patients have autoimmune hemolytic anemia, they should receive prednisone or a splenectomy; fludarabine may exacerbate warm autoimmune hemolysis. In patients with severe, refractory disease, allogenic bone marrow transplantation or antibody (anti-CD52) may be beneficial; however, the role of allogenic transplantation is limited by the fact that the average patient is over the age of 60.

- **What is the prognosis for patients with this condition?**

The median survival for CLL patients depends on the stage of disease at diagnosis. Patients with stage 0 or stage I disease have a median survival of 10–15 years and may live a normal life for many years. Patients with stage III or stage IV disease have a median survival of at least 2 years; this will hopefully improve as new therapies are developed. Newer cellular markers, such as the presence of somatic mutations in the immunoglobulin domains, ZAP-70, cytogenetics, and CD38 may allow identification of different prognostic categories for this disease.

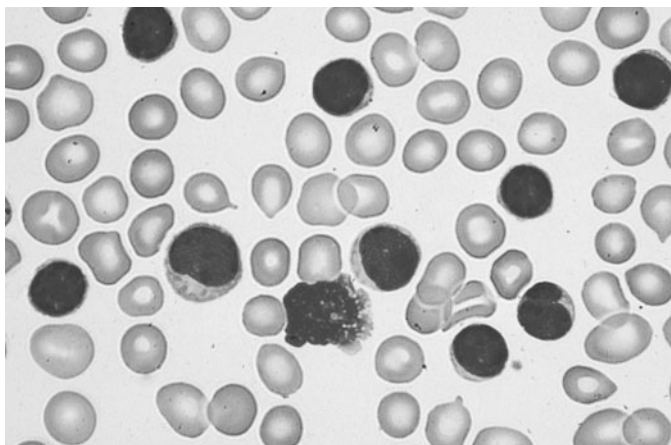


FIGURE 7-3. Peripheral blood smear showing an excess number of mature lymphocytes. (Reproduced, with permission, from Lichtman MA, Beutler E, Kipps TJ, Seligsohn U, Kaushansky K, Prchal JT. *Williams Hematology*, 7th ed. New York: McGraw-Hill, 2006: Color Plate XX-4.)

► **CASE 5**

A 21-year-old woman presents to her primary care physician with pain and swelling of her right lower leg. The pain began the night before following a 12-hour plane flight and did not improve with resting overnight. She denies fevers or trauma to the leg. Her only medication is an oral contraceptive. When questioned, she notes that multiple family members have suffered similar symptoms and that her maternal grandmother died from a pulmonary embolism. On physical examination, she is afebrile with normal vital signs. Her lateral right lower leg is erythematous without a palpable cord, and she reports increased pain with passive dorsiflexion of the right foot.

-
- **What is the most likely diagnosis?** Deep venous thrombosis due to a hypercoagulable state, likely factor V Leiden mutation. This is the most common of the genetic hypercoagulable states. While less severe than mutations in protein C or protein S, patients with factor V Leiden frequently develop superficial and deep vein thromboses, especially in the presence of other risk factors (smoking, oral contraceptives, immobilization).
-
- **What is the pathogenesis of this condition?** Patients with factor V Leiden are resistant to activated protein C (APC), an anticoagulant that deactivates factor Va in the clotting cascade. The mutation results in an Arg506Gln substitution in factor Va, which renders it much less susceptible to deactivation by APC. Although APC can act at a second site in factor Va, degradation occurs more slowly than at Arg506. The second deactivation site explains the partial resistance to APC and the relatively mild clinical phenotype of factor V Leiden compared to other hereditary prothrombotic states.
-
- **What tests could be used to confirm the diagnosis?** Coagulation studies are performed as a screening test on both patient and control plasma. The addition of APC will result in a prolonged activated partial thromboplastin time (aPTT) in the control plasma, but less prolongation in the patient plasma. Repeating this test using factor V-deficient plasma allows the physician to test for lupus anticoagulant and other prothrombotic disorders. The diagnosis is confirmed by DNA testing using polymerase chain reaction (PCR) to isolate the specific mutation; this will also determine heterozygosity versus homozygosity for the mutation.
-
- **What is the most appropriate treatment for this condition?** A standard heparin and warfarin regimen should be initiated in any patient with known venous thromboembolism. Thrombophilic patients should receive prophylactic doses of low-molecular-weight heparin prior to surgery or air travel lasting > 4 hours, during pregnancy until 6 weeks after delivery, or for long periods of immobilization.
-
- **The patient mentions that she is hoping to become pregnant within the next few years. How does this condition affect pregnancy?** Hereditary thrombophilias have been associated with many complications of pregnancy, including venous thromboembolism, stillbirth, placental abruption, and severe preeclampsia. Women with factor V Leiden heterozygosity have a significantly increased incidence of recurrent fetal loss.
-

► CASE 6

A 6-year-old girl is brought to the pediatrician by her parents 1 week after her adoption. She has had a progressively severe cold for the past week and developed a cough productive of yellow sputum yesterday. She was seen at the community clinic 3 days ago (when she had a fever of 37.7° C [99.8° F]) and was given antibiotics. Today, her fever is 39.4° C (102.9° F). She is tachycardic at 125/min, respiratory rate is 16/min, and blood pressure is 100/58 mm Hg. She is curled up on the examination table and appears pale and lethargic. During his examination, the pediatrician notes that the patient's thumbs are proportionately smaller than her other fingers and that she has a number of hyperpigmented lesions on her skin that are 4–8 cm in diameter. He suspects that the patient has an inherited disorder.

- **What is the most likely diagnosis?** Fanconi's anemia (FA). This is an autosomal recessive disorder characterized by defective DNA repair due to a variety of mutations. Thrombocytopenia and pancytopenia are common presentations of the disease, so care must be taken to distinguish FA from other causes of decreased platelets, such as idiopathic thrombocytopenic purpura (ITP), and pancytopenic conditions, including aplastic anemia or acute leukemias. Patients with FA have varying degrees of hematologic abnormalities, including purpura, petechiae or bleeding, and weakness or fatigue. In addition, some may have congenital abnormalities such as unusual skin pigmentation (e.g., café-au-lait spots), short stature, missing or malformed thumbs and radii, horseshoe kidneys, and microcephaly.

- **What is the pathogenesis of this condition?** There are at least 11 known genes associated with Fanconi's anemia. The proteins produced from these genes form a complex that ubiquitinates the D2 protein thought to be involved in the response to DNA damage. Failure to effectively inactivate D2 is hypothesized to result in FA.

- **What tests can be used to confirm the diagnosis?** A CBC can reveal many properties that are helpful in diagnosing FA. Patients will typically present with a low platelet count and leukopenia. Cells will be macrocytic and anisocytic, and fetal hemoglobin will be elevated. In addition, bone marrow will be hypoplastic or aplastic. Because this is a disorder of DNA repair, induction of chromosome breaks and rearrangements using diepoxybutane can confirm the diagnosis. This bone marrow or skin test is highly sensitive, even in children who are not yet symptomatic. Other disorders such as Diamond-Blackfan anemia, aplastic anemia, and dyskeratosis congenita should also be considered in the differential diagnosis.

- **What is the most appropriate treatment for this condition?** Patients with Fanconi's anemia are at greater risk of infection and bleeding, especially during adolescence and early adulthood. Neutropenic patients must be treated with broad-spectrum antibiotics. Transfusions should be considered carefully but not performed too frequently. A successful bone marrow transplant can cure aplastic anemia, particularly in children with an HLA-identical sibling donor who does not show signs of chromosome breakage. Reduced-intensity cytotoxic therapies are used, as Fanconi's patients are unusually sensitive to chemotherapy. Prognosis in these patients is typically complicated by the development of malignancies, particularly head and neck cancers and other solid tumors.

► **CASE 7**

A 43-year-old African-American man is brought to the emergency department after losing consciousness during a barbecue. Earlier that morning when getting out of bed, he felt dizzy and had to steady himself against the doorframe of the bathroom. He is generally healthy, although he recently had a bad sinus infection for which he received trimethoprim-sulfamethoxazole 4 days ago from his primary physician. Upon examination, he is tachycardic and tachypneic. His sclerae are icteric, but the rest of his examination is unremarkable. He has never been anemic in the past, but at this time laboratory studies reveal a hemoglobin of 9.1 mg/dL, a normal white count, white cell differential and platelet count. The reticulocyte count is elevated. The bilirubin is elevated, and fractionation reveals that the bilirubin is predominantly indirect.

- **What is the most likely diagnosis?** Glucose-6-phosphate dehydrogenase (G6PD) deficiency. This is an X-linked recessive disorder in which the ability of erythrocytes to defend themselves against oxidative stresses is reduced. It primarily affects African-American males; female carriers are rarely affected. A Mediterranean variant (favism) has also been described. Remember the three oxidant drug groups that induce this hemolytic anemia as **AAA**:
 - Antibiotics (e.g., sulfamethoxazole).
 - Antimalarials (e.g., primaquine).
 - Antipyretics (e.g., acetanilid, but not aspirin or acetaminophen).

 - **What is the pathogenesis of this condition?** G6PD is an enzyme that protects RBCs from hemolysis. It is the first enzyme in the hexose-monophosphate pathway (HMP) shunt. The pathway produces reduced glutathione, which protects RBCs from oxidative stresses by disposing of hydrogen peroxide; NADPH, produced in the G6PD step, is a cofactor for glutathione reductase. Without reduced glutathione, hemoglobin can be oxidized by hydrogen peroxide. Oxidized hemoglobin aggregates into clumps called Heinz bodies, which damage RBC membranes and make them susceptible to disposal by the spleen. Increased splenic destruction is responsible for the hemolytic anemia seen in G6PD deficiency.

 - **What tests could be used to confirm the diagnosis?** A peripheral blood smear, though not diagnostic for G6PD deficiency, is most sensitive during hemolytic episodes. Hemoglobin aggregates, or Heinz bodies, can be visualized in the periphery of red blood cells (see Figure 7-4). Damage to mature RBCs leads to reticulocytosis, with an elevation of serum LDH, low serum haptoglobin, and elevated indirect bilirubin. In addition, portions of the red cells are missing, giving them the appearance of having a “bite” taken out of them. These indentations occur at locations where hemoglobin aggregates have been removed by the spleen. Enzymatic assays for G6PD may return low levels during nonhemolytic episodes but may be paradoxically normal during hemolysis, as the defective cells have been eliminated.
-

- **What is the most appropriate treatment for this condition?**

There is no specific treatment for G6PD deficiency. However, patients must be advised to avoid substances that will precipitate a hemolytic episode. These include malaria medications such as quinine, antibiotics such as sulfonamides and nitrofurantoin, and foods such as fava beans.

- **What is the prognosis for patients with this condition?**

The prognosis in these patients is good, since hemolytic episodes are precipitated by specific medications and foods that can be avoided.

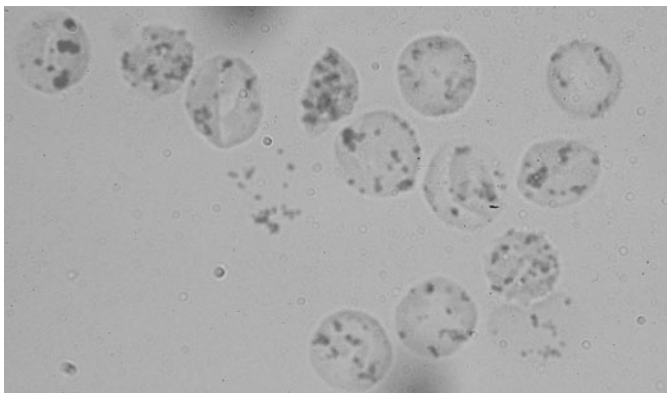


FIGURE 7-4. Blood mixed with hypotonic solution of crystal violet reveals precipitates of denatured hemoglobin (Heinz bodies) within the cells.

(Reproduced, with permission, from Lichtman MA, Beutler E, Kipps TJ, Seligsohn U, Kaushansky K, Prchal JT. *Williams Hematology*, 7th ed. New York: McGraw-Hill, 2006: Color Plate IV-4.)

► **CASE 8**

A 53-year-old man presents to his primary care physician complaining of weight loss and difficulty eating as much as he used to. He denies difficulty swallowing but reports that he feels full after much less food than previously. When questioned, he describes several months of fatigue that he attributed to the frequent colds he has had. He has no past medical history except hypertension, which is well-controlled on hydrochlorothiazide. On physical examination, he appears pale with multiple bruises over both legs. There is a palpable, nontender mass in his left upper quadrant on abdominal examination. The physician orders a complete blood count with peripheral smear, which is shown in Figure 7-5. The abnormal cells stain positive for tartrate-resistant acid phosphatase (TRAP).

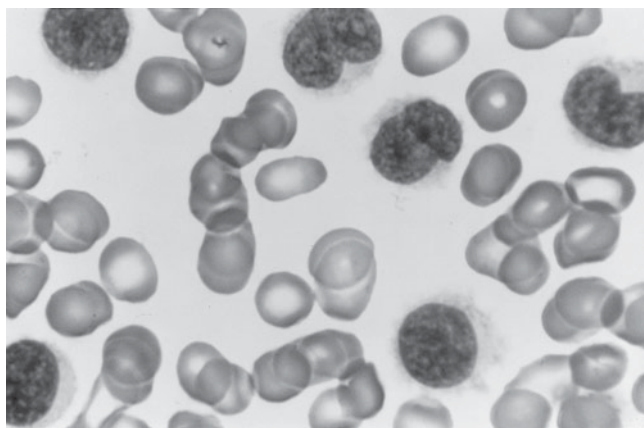


FIGURE 7-5. Peripheral blood smear demonstrating abnormal circulating lymphocytes.

(Reproduced, with permission, from Lichtman MA, Beutler E, Kipps TJ, Seligsohn U, Kaushansky K, Prchal JT. *Williams Hematology*, 7th ed. New York: McGraw-Hill, 2006: Fig. 93-1.)

■ What is the most likely diagnosis?	Hairy cell leukemia. This is an uncommon lymphoproliferative disorder distinguished by circulating B lymphocytes with characteristic “hairy” cytoplasmic projections. It accounts for an estimated 2–3% of adult leukemias in the United States. Massive splenomegaly and pancytopenia are the most frequent presenting symptoms.
■ What tests could be used to confirm the diagnosis?	TRAP staining of peripheral blood smears is positive in 90% of cases. Additionally, the hairy cells have a unique immunophenotype with expression of CD103 and can be identified by immunohistochemistry using an anti-CD103 antibody.
■ What is the most appropriate treatment for this condition?	Given his symptomatic splenomegaly and pancytopenia, this patient requires immediate treatment; 90% of patients require treatment at some point during the disease. Cladribine, a purine nucleoside analog, is the treatment of choice. A single 7-day course of continuous IV cladribine induces prolonged remission in a majority of patients and can be used again to treat patients who relapse. Fever and immunosuppression are the principal adverse effects. Newer therapies include rituximab and interferon. Splenectomy can rapidly reverse peripheral cytopenias in patients with severe disease.
■ What is the prognosis for patients with this condition?	Prognosis is very good. Patients initially treated with cladribine can expect a 5-year event-free survival rate > 90%.

► CASE 9

A 7-year-old boy is brought to the emergency department (ED) after falling on the playground and hurting his knee. He collided with a classmate while running across the schoolyard and fell on the pavement. No medical history is available; a teacher's aide accompanies the patient to the ED. She became concerned when his knee became terribly swollen and she was unable to stop the bleeding. Upon examination, the patient is extremely uncomfortable, his knee is warm and tender, and there is a large hematoma on the anterior aspect of the knee. The patient also has cuts on both elbows that continue to bleed, as well as a number of contusions elsewhere on his arms and legs. The rest of the examination is unremarkable, laboratory studies reveal a normal CBC, including a normal platelet count, a normal prothrombin time, and a markedly elevated partial thromboplastin time. X-rays of the leg are negative for fractures in the femur, tibia, and fibula.

-
- | | |
|--|--|
| <p>■ What is the most likely diagnosis?</p> | <p>Hemophilia. This is a disorder of coagulation that leads to increased bleeding as a result of deficiency in one of two clotting factors. Hemophilia A, which is much more common, is a deficiency of factor VIII, while hemophilia B is associated with factor IX. Both are X-linked recessive diseases and cannot be distinguished based on clinical presentation and symptoms. Women are generally unaffected carriers unless extreme mosaicism is present. Patients bruise easily and bleed into joints and muscles. More severe bleeding can occur in the abdomen, retroperitoneum, or central nervous system. Furthermore, trauma or surgical interventions can lead to severe bleeding.</p> |
| <p>■ What is the pathogenesis of this condition?</p> | <p>Factor VIII is a critical component of the clotting cascade. It increases the rate of cleavage of factor X by activated factor IX. In plasma, factor VIII travels in a complex with von Willebrand factor (vWF). In the absence of factors VIII or IX, clotting is impaired, and patients bleed longer.</p> |
| <p>■ What tests could be used to confirm the diagnosis?</p> | <p>Prothrombin time (PT) and activated partial thromboplastin time (aPTT) are not always helpful, since they can be normal in patients with mild disease. In more severe disease, the PT will still be normal, but the aPTT will be prolonged. The diagnosis can be confirmed only by assays for the specific clotting factors.</p> |
| <p>■ What is the most appropriate treatment for this condition?</p> | <p>Factor replacement—either recombinant or plasma-derived/purified—is the most effective method to control bleeding in hemophilia patients. The recombinant factors are more pure but also significantly more expensive. Plasma-derived factors are effective but disadvantageous because of the risk of transmission of blood-borne viruses (e.g., hepatitis B or C); additionally, plasma-derived concentrates of factor IX can contain other clotting factors that lead to paradoxical clotting. With repeated treatments, patients may develop antibodies to clotting factors, which complicates management and necessitates pathway-bypassing products (i.e., factor VIIa).</p> |
| <p>■ What is the prognosis for patients with this condition?</p> | <p>Management of patients with hemophilia is complicated, particularly when the bleeding is within or above the neck or in the retroperitoneum, or if compartment syndrome is suspected. Determining the proper dose of factor replacement necessary for acute bleeding is also challenging; patients who require repeated treatments must be hospitalized.</p> |
-

► **CASE 10**

A 23-year-old man visits his primary physician after 1 month of night sweats. He says that for the past 6 weeks he has had general malaise, which he attributes to the stress of his new job as an investment banker and his crumbling relationship with his girlfriend. He has lost about 4.5 kg (10 lb) during this time. He has been healthy in the past and is conscientious about eating a balanced diet and exercising daily. His family history is unremarkable. He does not smoke, drinks one to two beers per week, and denies intravenous drug use. He denies international travel and says he had a negative purified protein derivative (PPD) test before starting his new job. On examination, his temperature is 38.1° C (100.5° F), blood pressure is 120/65 mm Hg, heart rate is 80/min, and respiratory rate is 16/min. His examination is within normal limits, with the exception of a palpable cervical lymph node, which is firm, painless, and approximately 2 cm in diameter. Results of excisional biopsy are shown in Figure 7-6.

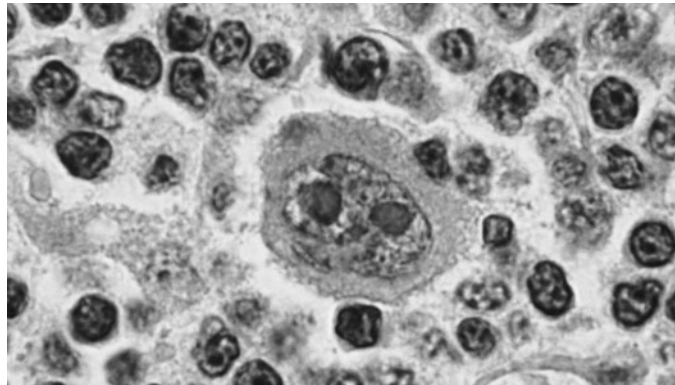


FIGURE 7-6. (Reproduced, with permission, from Lichtman MA, Beutler E, Kipps TJ, Seligsohn U, Kaushansky K, Prchal JT. *Williams Hematology*, 7th ed. New York: McGraw-Hill, 2006: Color Plate XXII-32.)

-
- **What is the most likely diagnosis?** Hodgkin's lymphoma. This is a painless lymphadenopathy that can only be conclusively diagnosed by excisional lymph node biopsy (not fine needle aspiration). Many patients present with a painless neck mass, while a minority have constitutional symptoms such as fever, night sweats, and weight loss. The age of onset has a bimodal distribution, with peaks in the 20s and the 50s. There are multiple types of Hodgkin's disease, which are classified by the types of cells that proliferate: nodular sclerosing, mixed cellularity, lymphocyte predominant, and lymphocyte depleted. The differential includes other malignant lymphomas as well as causes of reactive lymph nodes (mononucleosis, autoimmune disorders, drug reactions, and *Bartonella henselae* infection or cat-scratch disease).
-
- **What is the pathogenesis of this condition?** Hodgkin's disease is a collection of cancers in which Reed-Sternberg cells (giant, multinucleated macrophages seen in Figure 7-6) appear in a background of reactive cellularity. These specialized cells have an "owl's eye" appearance. The exact etiology of the disease is unknown, but there is some evidence suggesting a role for Epstein-Barr virus (EBV). Remember the Hodgkin's lymphoma classifications that accompany tumor staging:
A: Asymptomatic
B: Bad
-

■ **What tests could be used to confirm the diagnosis?**

Hodgkin's lymphoma can only be diagnosed conclusively by lymph node biopsy with careful histologic examination for the presence of Reed-Sternberg cells. Fine needle aspirate of lymph nodes often provides inadequate tissue sample for diagnosis.

■ **What is the most appropriate treatment for this condition?**

Treatment is dictated by staging, which is based on the number of involved lymph node areas. In the past, patients with low-risk disease (stages I and II) were primarily treated with radiation therapy; however, long-term follow-up has shown an unacceptable late incidence of radiation-related malignancies. As a result, lower-stage patients are generally treated with chemotherapy with or without radiotherapy. Patients with higher stages of disease (stages III and IV) respond well to combination chemotherapy, often with agents such as doxorubicin, bleomycin, dacarbazine, and vincristine.

■ **What is the prognosis for patients with this condition?**

Patients with low-stage disease who respond well to radiation or chemotherapy have an excellent prognosis, with 10-year survival rates > 80%. Those with disseminated disease have 5-year survival rates of about 60%. Prognosis worsens with increasing age and tumor bulk, as well as for patients who have lymphocyte depletion or mixed cellularity. Relapses are best addressed with high-dose chemotherapy and autologous stem cell transplantation; a cure in these cases is possible in 35–50% of cases if the tumor is still sensitive to chemotherapeutic agents.

► CASE 11

A 21-year-old woman presents to her gynecologist after 1 year of dysmenorrhea and menorrhagia. She recalls having seven or eight periods over the past 12 months, all of which were heavier than normal. She previously went to the gym five times per week but is now unable to exercise because she feels she “cannot keep up.” In addition, she has been feeling tired for the past 3 months and has trouble waking up each morning because she feels exhausted instead of refreshed. She is not taking any medications and denies smoking, alcohol consumption, and illicit drug use. She eats a well-balanced diet, and coagulation studies are normal. Her vital signs include a heart rate of 92/min, blood pressure of 135/80 mm Hg, and respiratory rate of 20/min. Her examination is otherwise unremarkable. Relevant laboratory results are as follows:

WBC count: 5600/mm³

Hemoglobin: 9.2 g/dL

Platelet count: 225,000/mL

Mean corpuscular hemoglobin: 21 pg

Mean corpuscular hemoglobin concentration: 29%

Mean corpuscular volume: 72 fL

-
- | | |
|---|--|
| ■ What is the most likely diagnosis? | Iron-deficiency anemia. The most common cause of anemia, this is particularly common in women with heavy, irregular menses. Iron-deficiency anemia is microcytic and hypochromic and can easily be detected on a peripheral blood smear (Figure 7-7). Cells exhibit central pallor and are smaller than expected. |
| ■ What is the pathogenesis of this condition? | More than half of the body’s iron is stored within red blood cells. Therefore, iron deficiency most often results from an imbalance between iron intake and loss of RBCs from the body through bleeding. It is rarely due to internal destruction of RBCs, as the body is able to recycle iron released by hemolysis. The source of the bleeding is often the gastrointestinal tract; however, menorrhagia should also be considered in menstruating women. |
| ■ What other screening might be necessary for this patient? | Though the history points toward iron deficiency as the most likely cause in this patient, other causes of microcytic anemia exist. If laboratory studies such as iron and iron binding capacity confirm iron deficiency, additional causes need not be considered. If iron deficiency is not confirmed, other causes such as thalassemias, a group of inherited blood disorders, must be considered. For some of these patients, genetic screening may be desirable. Hemoglobin electrophoresis (hemoglobin A ₂) is necessary to diagnose thalassemia trait. |
| ■ What tests could be used to confirm the diagnosis? | A CBC is helpful because the decreased hemoglobin indicates anemia, while the low values of MCV, MCH, and MCHC suggest a microcytic process. To confirm the presence of an iron-deficiency anemia, it is best to directly examine iron stores. Serum iron levels < 60 µg/dL are suggestive. An iron to iron binding capacity ratio of less than 10% is strongly suggestive of iron deficiency. Serum ferritin levels < 20–30 ng/dL indicate that stored iron is depleted in the absence of inflammation (< 50–100 if iron deficiency and chronic inflammation are both present). The gold standard for identifying iron-deficiency anemia is a bone marrow examination with Prussian blue staining, which will reveal depleted iron stores; however, the diagnosis is usually made when oral iron supplementation produces marked reticulocytosis, and marrow examination is rarely necessary. |
-

- **What is the most appropriate treatment for this condition?**

Dietary modification to include sources of iron such as red meats, fish and leafy green vegetables would be helpful in a patient who does not follow a balanced diet. In this case, the patient would probably benefit from iron supplementation. Supplementation is typically oral, but can be intramuscular or intravenous in patients who do not tolerate the gastrointestinal side effects of oral iron. Vitamin C increases the bioavailability of oral iron and may be beneficial.

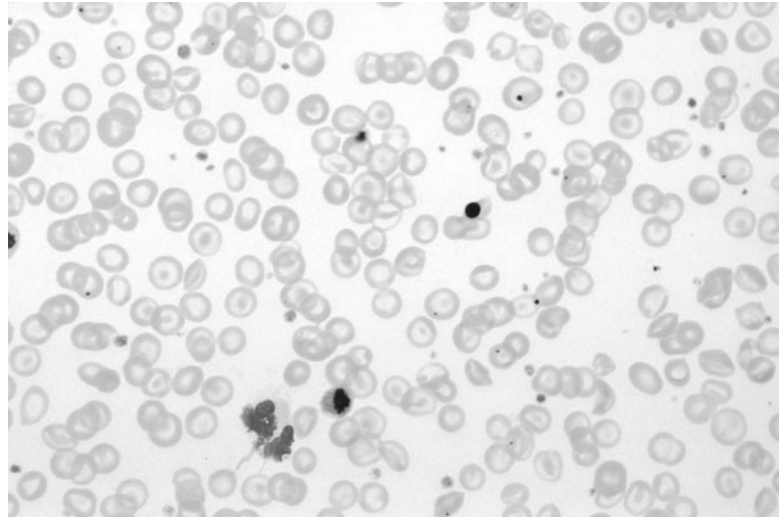


FIGURE 7-7. Peripheral blood smear shows microcytic hypochromic normoblasts. (Reproduced, with permission, from the Pathology Education Instructional Resource Digital Library [<http://peir.net>] at the University of Alabama, Birmingham.)

► **CASE 12**

A 69-year-old man presents to the community clinic complaining of pain in his right thigh for the past 2 months. He also reports fatigue for the past few weeks. The pain is constant and knifelike and is always midway between his hip and his knee; it does not radiate. He rates the pain 9/10 and says that he feels like it is deep in his bones. He denies any trauma to the area; femoral x-rays are negative for fracture. He says that sometimes he feels a similar pain in his ribs; x-ray of the chest is negative for rib fractures. About 3 months earlier, he suffered a severe bout of pneumonia and was successfully treated. His past medical history is significant only for essential hypertension, for which he is taking hydrochlorothiazide. He quit smoking 20 years ago but enjoys a glass of brandy after dinner every night. He denies any intravenous drug use. Relevant laboratory results are as follows:

Hemoglobin: 9.1 mg/dL
Mean corpuscular volume: 72 fL
Glucose (nonfasting): 135 mg/dL
Serum Na⁺: 142 mEq/dL
Serum K⁺: 3.4 mEq/dL
Serum Ca²⁺: 17 mg/dL

-
- **What is the most likely diagnosis?** Multiple myeloma. One of the plasma cell dyscrasias, multiple myeloma is characterized by excessive bone marrow replacement, bone destruction, and excess release of paraproteins (abnormal proteins) by malignant plasma cells. Patients present with anemia and can progress to bone marrow failure. Some have complications associated with plasmacytomas, tumors that may compress the spinal cord. Often, patients have bone pain, osteoporosis, pathologic fractures, and hypercalcemia as a result of the increased insult to the bone and the release of stored calcium into the bloodstream. Excess light chains can deposit in the kidneys and lead to renal failure. Patients are also more susceptible to infection, particularly with encapsulated organisms such as *Streptococcus pneumoniae* and *Haemophilus influenzae*.
-
- **What is the pathogenesis of this condition?** Multiple myeloma is a form of plasma cell tumor (Figure 7-8); it is not a malignancy of the bone. Many patients will present with a preceding MGUS (monoclonal gammopathy of undetermined significance), which is present in 1–3% of the population. Proliferation of plasma cells can interfere with the proper function of the bone marrow and lead to anemia, and, much less commonly, leukopenia and thrombocytopenia. Abnormal plasma cells also stimulate osteoclasts, leading to osteoporosis and an increase in fractures.
-
- **What tests could be used to confirm the diagnosis?** Multiple myeloma patients are almost universally anemic. Their red blood cells may appear structurally normal on peripheral blood smears (Figure 7-9) but will often be seen in rouleau formation due to the presence of abnormal, negatively charged γ -globulins. Rarely, a plasma cell will be visible in the smear. Serum protein electrophoresis can be used to detect paraproteins. Radiography is important to identify lytic lesions in the bone or unexpected osteoporosis. Since myeloma is a malignancy, the diagnosis depends on obtaining tissue, in this case, through a bone marrow aspirate and biopsy.
-

- What is the most appropriate treatment for this condition?

Patients who present with multiple myeloma require treatment of their malignancy as well as their symptoms (e.g., bone pain, hypercalcemia, fractures). No curative therapies exist. Thalidomide and dexamethasone have replaced VAD chemotherapy (vincristine, doxorubicin [Adriamycin], and dexamethasone) as standard induction therapy; however, this regimen is associated with an increased risk of deep venous thrombosis. Once initial treatments are implemented (induction therapy), autologous stem cell transplantation can be considered, particularly in patients < 70 years of age. Lenalidomide, a thalidomide analog, and bortezomib have improved survival in this disease as well. Allogenic transplantation is also possible but carries a 40–50% mortality rate in these patients.

- What is the prognosis for patients with this condition?

The Durie-Salmon or International Stage of the patient is often used to determine prognosis. Prognosis depends on the degree of end-organ damage (anemia, low albumin, lytic lesions, renal failure) and proliferative rate (β_2 microglobulin) of the plasma cells. Cytogenetic findings may also be important. Patients with milder forms have a median survival of 5–6 years, while those with severe disease may only live 1–2 years without autologous transplantation.

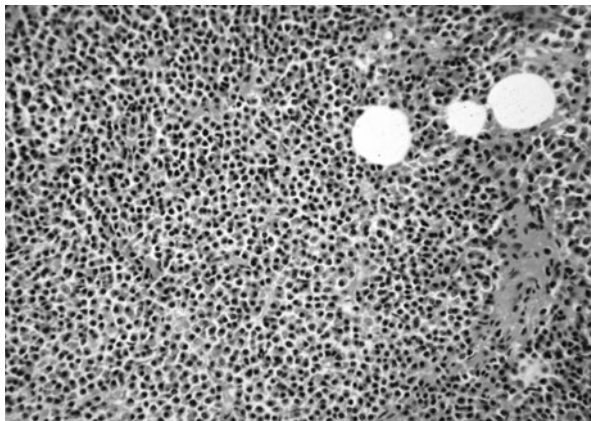


FIGURE 7-8. High magnification H&E stain shows plasma cells. (Reproduced, with permission, from the Pathology Education Instructional Resource Digital Library [<http://peir.net>] at the University of Alabama, Birmingham.)

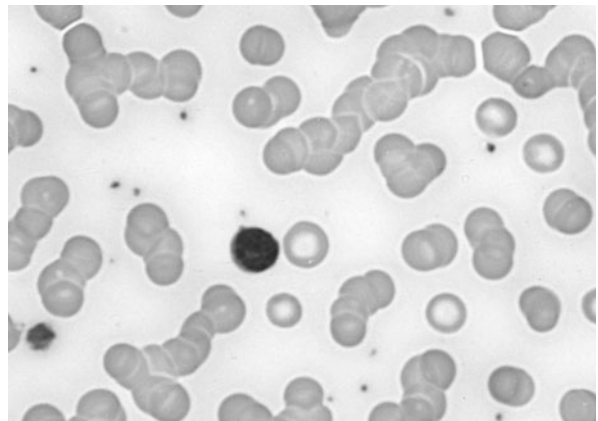


FIGURE 7-9. RBCs in a rouleaux formation. (Reproduced, with permission, from Lichtman MA, Beutler E, Kipps TJ, Seligsohn U, Kaushansky K, Prchal JT. *Williams Hematology*, 7th ed. New York: McGraw-Hill, 2006: Color Plate 1–8.)

► **CASE 13**

A 26-year-old woman loses consciousness in her front yard and is rushed to the emergency department (ED) by her husband. He is concerned that she hit her head on the driveway when she fell, but she is conscious, alert, and oriented soon after arrival in the ED. Her neurological examination is normal, and imaging studies are negative for intracranial hemorrhage. While in the evaluation room, she says she may have cut her mouth when she fell. Upon closer inspection, the blood in her mouth is discovered to be gingival in origin, and she is also noted to have epistaxis and nonpalpable purpura on her arms and legs. When asked about other abnormal bleeding, the patient notes that her menses have been heavier than normal for the past 4 months and that she had noticed the purpura on her limbs approximately 1 month ago but thought it was “winter skin.” Relevant laboratory results include a hemoglobin of 12.8 mg/dL, hematocrit of 37%, WBC count of 6600/mm³, and platelet count of 7300/mm³.

- | | |
|--|--|
| ■ What is the most likely diagnosis? | Idiopathic thrombocytopenic purpura (ITP). In childhood, isolated episodes of ITP can follow a viral infection. The adult form, however, is chronic, rarely associated with a prodromal illness, and commonly occurs between the ages of 20 and 50 years. It is twice as common in female patients as in males. Patients typically present with bleeding: epistaxis, gingival bleeding, menorrhagia, purpura, and petechiae. The spleen is characteristically of normal size in ITP. |
| ■ What is the pathogenesis of this condition? | An autoimmune disease of the platelets, ITP is associated with overproduction of IgG that targets platelets for destruction by the spleen. The specific platelet antigen is not known, but the Fc receptors on splenic macrophages bind antibody-coated platelets. |
| ■ What conditions should be included in the differential diagnosis? | Isolated thrombocytopenia is ITP in over 99% of cases. Drug-induced thrombocytopenia is also possible, and a patient history that includes sulfonamides, quinine, thiazides, cimetidine, gold, or heparin may be suggestive; heparin is the most common inpatient cause. Myelodysplasia and other diseases of bone marrow failure can be ruled out by examining the bone marrow, which will be normal in ITP except for an increased number of megakaryocytes. Other causes of peripheral thrombocytopenia include disseminated intravascular coagulation, thrombotic thrombocytopenic purpura, hemolytic-uremic syndrome, hypersplenism, and sepsis. However, in patients with isolated thrombocytopenia in the absence of systemic signs and symptoms, an immune origin must be suspected. |
| ■ What tests could be used to confirm the diagnosis? | The hallmark of ITP is thrombocytopenia. Other blood cell lines are normal, although the bleeding can lead to mild anemia. The peripheral blood smear will show a significant absence of mature platelets and some enlarged (immature) platelets (megathrombocytes). |
| ■ What is the most appropriate treatment for this condition? | ITP in adults does not typically undergo spontaneous remission as it does in children, so the first line of treatment is corticosteroids (methylprednisolone, prednisone, or dexamethasone). Steroid treatment will increase vascular stability even before resolving the thrombocytopenia. Prednisone may be curative, but in many patients, stopping treatment can lead to a recurrence of the disease. Splenectomy is often employed as second-line therapy, but it too is associated with relapses in up to a third of patients. Intravenous immunoglobulin or Rho(D) immune globulin (in Rh-positive patients) are often used to increase the duration of response. In patients with refractory disease, danazol or immunosuppressive agents such as vincristine, rituximab, or cyclosporine can be successful. |
-

► CASE 14

A 12-year-old girl is admitted to the hospital for chemotherapy for refractory leukemia. With the exception of common side effects such as nausea, vomiting, loss of appetite, and malaise, her treatment course over the past year has been uneventful. Routine laboratory tests are ordered, and the medications are prepared. As she changes into a hospital gown, the patient notes that she is sweating, and a nurse determines that her temperature is 38.9° C (102.1° F). Her blood pressure is 90/55 mm Hg, pulse is 100/min, and respiratory rate is 17/min. An intravenous line is started with normal saline and broad-spectrum antibiotics plus antifungal coverage instead of her chemotherapeutic agents. Relevant laboratory results include a WBC count of 900/mm³.

-
- **What is the most likely diagnosis?** Neutropenic fever. Defined as a neutrophil count below 2000/mm³, neutropenia renders patients increasingly susceptible to bacterial and fungal infections, particularly *Candida* and *Aspergillus*. Patients can be asymptomatic or may present with varying degrees of infection or sepsis, depending on their level of neutropenia. Some patients live comfortably at chronically low neutrophil levels without serious infectious consequences. Common infections include septicemia, stomatitis, cellulitis, and pneumonia.
 - **What is the pathogenesis of this condition?** Neutropenia has many causes, including bone marrow hypoplasia, ineffective neutropoiesis (resulting from exaggerated apoptosis of late precursors), and increased removal or utilization of circulating neutrophils. If isolated, it is typically drug-induced by agents such as sulfonamides, penicillin, chlorpromazine, and chemotherapeutic drugs, or related to autoimmune disorders (i.e., lupus). Cancer or infection, such as sepsis or HIV, can lead to invasion of the bone marrow with subsequent neutropenia. Furthermore, folate or vitamin B₁₂ deficiencies can lead to arrest in the maturation of neutrophils. Lastly, destruction of neutrophils, as in hypersplenism, can also lead to neutropenia. In this case, marrow replacement by the leukemia or marrow suppression by prior chemotherapy is the obvious cause.
 - **What tests could be used to confirm the diagnosis?** A decreased absolute neutrophil count is diagnostic for neutropenia. A bone marrow biopsy can establish a specific diagnosis if one has not previously been made. Peripheral blood flow cytometry may assist in the diagnosis of large granular lymphocyte syndrome.
 - **What is the most appropriate treatment for this condition?** Treatment for neutropenia should address the underlying cause of neutrophil suppression. Causative pharmacologic agents should be discontinued. Infections should be covered with broad-spectrum antibiotics, with particular coverage of enteric gram-negative bacteria. The physician should also have a low threshold for adding antifungal coverage. In-hospital therapy is typically recommended for febrile patients with neutropenia, especially those with symptoms, prolonged neutropenia, or an underlying hematologic malignancy. Exogenous growth factor support and prophylactic antibiotics may reduce the hospital stay but have not been shown to impact mortality or risk of severe infections in chemotherapy-induced neutropenia. Idiopathic or cyclic cases often respond to granulocyte colony-stimulating factor.
 - **What is the prognosis for patients with this condition?** The prognosis depends on the cause and duration of the neutropenia, the degree of bone marrow suppression, and the severity of infection.

► **CASE 15**

A 58-year-old man presents to the emergency department complaining, “I can’t stop itching all over, and my eyes are blurry.” He successfully installed a new showerhead in his bathroom this weekend and took a long, hot shower to test it. A few minutes after the shower, his hands began to itch, and the sensation soon spread to his trunk and his limbs. He used the same soap he has used for the past few years and has lived in his current house for nearly three decades. He regularly completes small home improvement projects around the home but has never experienced these symptoms in the past; he denies any allergies. Upon examination, he is fidgeting and uncomfortable. He repeatedly scratches his arms, legs, and abdomen, and tries to reach his back. His face is very red and warm to the touch. His temperature is 38.3° C (101° F), blood pressure is 140/80 mm Hg, heart rate is 92/min, and respiratory rate is 16/min. He complains of a dull, throbbing headache that he rates 5/10 on the pain scale. His examination is remarkable for a palpable spleen and excoriated skin on his arms, legs, and abdomen. Relevant laboratory results include a hemoglobin of 20.5 mg/dL, a hematocrit of 62%, and an erythrocyte sedimentation rate of 2 mm/hr.

■ **What is the most likely diagnosis?**

Polycythemia vera. This is defined as a condition in which the hematocrit exceeds 50%. There are two causes: relative, in which plasma volume has decreased but red cell mass is preserved; or absolute, in which red cell mass is increased regardless of plasma volume. Absolute polycythemia may be reactive, as in heavy smokers, or may indicate a myeloproliferative disorder, polycythemia rubra vera. These patients typically present with malaise, fever, ruddy complexion (plethora), and pruritus after a warm shower. Some will also have cardiovascular symptoms (stroke, MI, claudication, headache) as a result of vascular congestion. Splenomegaly is a common finding in these patients. Primary polycythemia is idiopathic and is commonly referred to as polycythemia vera. Remember the symptoms with the mnemonic **Polycythemia Rubra Vera (PRV):** Plethora/Pruritus, Ringing in ears, and Visual blurring. Secondary polycythemia is associated with oxygen deprivation, as in the setting of COPD or other lung diseases, high altitudes, erythropoietin-producing tumors, or smoking (an increase in carboxyhemoglobin).

■ **What is the pathogenesis of this condition?**

Polycythemia is an excess in either the size or number of red blood cells. It can be primary, secondary (related to elevated levels of erythropoietin), or spurious (resulting from a decrease in plasma volume). It may be apparent or inapparent (masked by iron deficiency or another cause of anemia). A rare familial form also exists and is associated with hyperresponsive erythropoietin receptors. In the nonfamilial secondary forms, erythropoietin can be elevated due to environmental causes, such as hypoxia from lung disease or higher elevations. Alternatively, abnormal causes such as ectopic production or renal artery stenosis can lead to elevations in erythropoietin.

- **What tests could be used to confirm the diagnosis?**

A CBC with differential is useful in the diagnosis of polycythemia. Hemoglobin will often be > 16 mg/dL in women and 18 mg/dL in men, and the RBC mass (tagged RBC scan) will be increased. In primary disease, erythropoietin levels are low; in secondary disease, they are high. However, overlap in erythropoietin levels and decrease in erythropoietin levels as the hematocrit rises limits the value of erythropoietin levels as a diagnostic test. WBC levels and platelet counts are typically normal, but it is possible to see patients present with an elevation in both the RBC and WBC lines, including basophils and eosinophils. JAK2 mutations are commonly found (> 90%) and may contribute to the erythropoietin-independent colony growth seen in polycythemia vera. This test has become the cornerstone of diagnosis.

-
- **What is the most appropriate treatment for this condition?**

The most effective treatment for polycythemia is serial phlebotomy. It reduces blood volume and lowers the risk of cardiovascular events. Aspirin is helpful in reducing stroke risk, and hydroxyurea can be used to suppress hyperactive bone marrow, if necessary, although there is a risk for secondary leukemia with this agent.

-
- **What is the prognosis for patients with this condition?**

Primary polycythemia (polycythemia vera) increases the risk of conversion to myelofibrosis or acute myelogenous leukemia. This risk is associated with the duration of the disease and exposure to chemotherapeutic agents and radioactive phosphorus.

► **CASE 16**

A 15-month-old African-American boy is brought to the emergency department by his parents because they have been unable to get him to stop crying. The child has been in distress for the past hour, ever since the family returned from a day hike. The parents deny any trauma, and he was healthy and happy earlier that morning. His mother notes that her pregnancy and delivery were both uneventful and that her son has been relatively healthy, with the exception of occasional colds. Upon examination, he appears uncomfortable and is crying inconsolably. He is tachycardic and tachypneic, and his lips are slightly cyanotic. His right knee appears swollen, and when the physician tries to examine it, the crying worsens and the child pulls away. His oxygen saturation on room air is 85%. Relevant laboratory results are as follows:

WBC count: 10,500/mm ³	Mean corpuscular hemoglobin: 27 pg
Hemoglobin: 8.6 mg/dL	Mean corpuscular hemoglobin concentration: 31%
Hematocrit: 25%	Platelet count: 500,000/mm ³
Mean corpuscular volume: 78 fL	

■ **What is the most likely diagnosis?**

Sickle cell anemia. An autosomal recessive disorder associated with a point mutation in the hemoglobin gene, sickle cell anemia typically presents during the first year of life and primarily affects children of African-American descent. There is usually a strong family history for sickle cell anemia, and prenatal testing is now available. Patients have a chronic hemolytic anemia that predisposes them to a number of additional complications. Acutely painful sickle cell “crises” may occur as a result of infection, hypoxia, or dehydration. During a crisis, the microvasculature of an affected organ or body part becomes clogged with abnormal red blood cells that impair circulation. The occlusion can last from hours to days and may be accompanied by a fever. Common sites include the back, limbs, and chest. Remember the complications of sickle cell disease using the mnemonic **SICKLE**:

Strokes/Swelling of hands and feet/Splenic sequestration
Infections (ulcers, osteomyelitis)/Infarctions
Crises (painful, sequestration, aplastic)/Cholelithiasis/Chest syndrome/
Chronic hemolysis/Cardiac problems
Kidney disease
Liver disease/Lung problems
Erection (priapism)/Eye problems (retinopathy)

■ **What is the pathogenesis of this condition?**

A point mutation in the sixth position of the hemoglobin gene results in the insertion of valine instead of glutamate into the polypeptide chain. As a result of this substitution, an abnormal hemoglobin tetramer (HbS) forms ($\alpha_2\beta_2^s$) that assumes a concave shape when deoxygenated; this shape change, known as sickling, results in injury to the red blood cells. The sickling is reversible if oxygen is returned to the environment, but repeated sickling can permanently injure a cell and render it suitable for elimination by the spleen. Symptoms typically present as the transition from fetal to adult hemoglobin begins, and production converts from γ -globin chains to defective β -globin chains.

- What tests and/or imaging tools could be used to confirm the diagnosis?

A CBC is helpful in the diagnosis of sickle cell anemia. Patients have chronic anemia, with hematocrit levels around 20–30%. Patients may also have thrombocytosis, increased WBCs, and elevated indirect bilirubin levels. A peripheral blood smear showing abnormally shaped cells (Figure 7-10) is diagnostic; crescent-shaped (sickled) cells, target cells, and Howell-Jolly bodies (DNA inclusions) are often present. Hemoglobin electrophoresis can confirm any diagnostic suspicions; > 85% of the hemoglobin will be the HbS form, and there will be no HbA (normal adult form) present. In addition, HbF (fetal form) will be elevated, since it enables these patients to compensate for their poor oxygenation states. Sickle cell carriers will typically have 60% HbA and 40% Hb S unless coexistent thalassemia is present.

- What is the most appropriate treatment for this condition?

Patients with sickle cell disease primarily receive treatment for their symptoms as opposed to their disease. Folate supplements are given, and patients are instructed to avoid factors that precipitate acute crises. Patients benefit greatly from substances that increase the amount of fetal hemoglobin in the body, such as hydroxyurea, which can reduce the frequency of painful, acute crises. The long-term risk of leukemia with this agent in this population is minimal compared to the risk and morbidity of recurrent acute crises. In serious cases, transfusions must be considered.

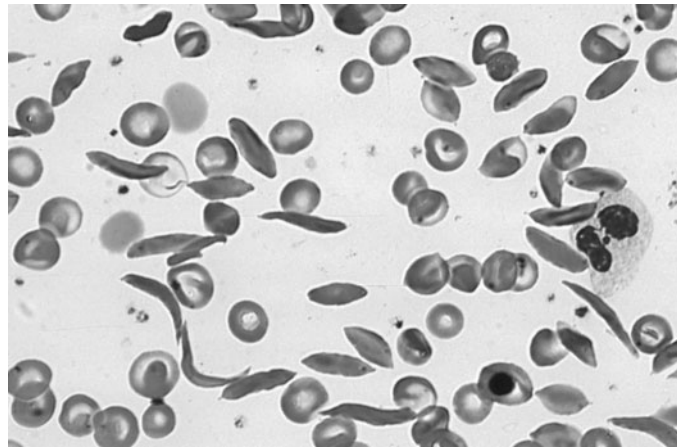


FIGURE 7-10. Peripheral blood smear demonstrating abnormal RBCs. (Reproduced, with permission, from Lichtman MA, Beutler E, Kipps TJ, Seligsohn U, Kaushansky K, Prchal JT. *Williams Hematology*, 7th ed. New York: McGraw-Hill, 2006: Color Plate III-5.)

► **CASE 17**

A 3-year-old girl is brought to the emergency department after being found unconscious in her bed. She is cyanotic, her respiratory rate is 4/min, and her pulse is faint and thready. Her mother is frantic and unable to provide a history. She does state that her daughter has “a bad blood disease,” which has necessitated numerous transfusions, particularly after a round of antibiotic treatment. Despite heroic measures, the child does not survive. A peripheral smear shows severe microcytic, hypochromic anemia with target cells and poikilocytosis. Emergency laboratory results revealed the following:

WBC count: 8500/mm³
Hemoglobin: 6 g/dL
Hematocrit: 23%
Mean corpuscular volume: 55 fL
Reticulocyte count: 6%

-
- **What is the most likely diagnosis?** α -Thalassemia (hemoglobin H disease). Thalassemias are disorders in which one or more of the α - or β -globin chains are deficient. The deficiencies result in a decrease in hemoglobin and ultimately lead to a microcytic, hypochromic anemia. Seen primarily in patients from Southeast Asia and China, the severity of α -thalassemia depends on how many of the four α -globin genes are missing. With three intact genes, patients are said to be silent carriers and are hematologically normal. Individuals with two functional genes have thalassemia trait. They have an asymptomatic microcytic anemia. With only a single functional α -globin gene, as in this patient, individuals have hemoglobin H disease. They are chronically anemic to varying degrees and will generally have splenomegaly and appear pale. Some may require transfusions after infection or stress to resolve exacerbations of the anemia. When all four α -globin genes are absent, hydrops fetalis occurs; this condition is not compatible with life, and stillbirth usually results.

 - **What is the pathogenesis of this condition?** Thalassemias result from the deficiency of genes required to construct normal forms of hemoglobin. Hemoglobin A, which is the normal adult form, consists of four chains arranged as $\alpha_2\beta_2$. The α -globin chains are required in hemoglobin, while the β -globin chains can be substituted by δ or γ chains to produce other forms: hemoglobin A₂ ($\alpha_2\delta_2$) and hemoglobin F ($\alpha_2\gamma_2$). In more severe forms of α -thalassemia, some tetramers made exclusively of β -globin chains can form; these β_4 forms are referred to as hemoglobin H.

 - **What tests could be used to confirm the diagnosis?** Patients with hemoglobin H disease are anemic and often have microcytosis that is out of proportion to the anemia. A low hematocrit level (22–32%) with significantly lower MCV (60–70 fL) is suggestive of hemoglobin H disease. A peripheral blood smear is more indicative and will reveal microcytosis, hypochromia, target cells, reticulocytosis, and poikilocytosis (RBCs of abnormal shape; Figure 7-11). Furthermore, hemoglobin electrophoresis will demonstrate the presence of a fast-migrating hemoglobin (HbH), which will be no more than 40% of the total sample.

 - **What is the most appropriate treatment for this condition?** Patients with hemoglobin H disease should take folate and avoid causes of oxidative stress, such as sulfonamides, which might worsen their chronic anemia. Splenectomy should be considered if too many transfusions are required. Iron chelation therapy is necessary for iron-overload states.
-

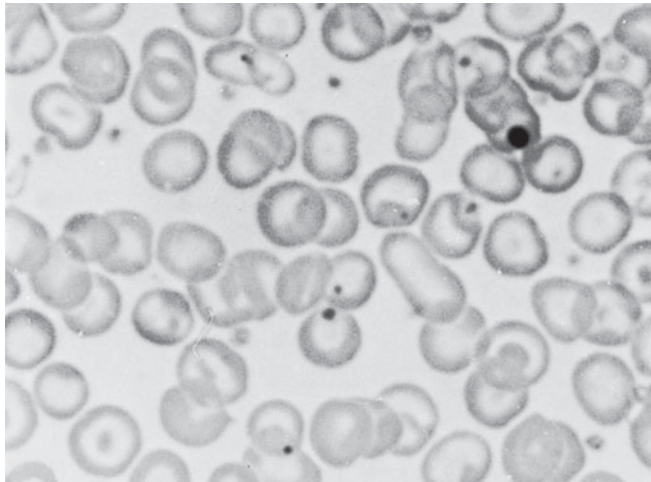


FIGURE 7-11. Peripheral blood smear in hemoglobin H disease. (Reproduced, with permission, from Lichtman MA, Beutler E, Kipps TJ, Seligsohn U, Kaushansky K, Prchal JT. *Williams Hematology*, 7th ed. New York: McGraw-Hill, 2006: Fig. 46-18.)

► **CASE 18**

A 60-year-old man presents to the emergency department complaining of a persistent nosebleed. His nose began bleeding spontaneously about 3 hours ago, and he has not been able to get it to stop despite direct pressure and ice packs. He denies trauma, blood disorders, cancer, or a family history of hematologic or oncologic problems. He has gastroesophageal reflux disease (GERD), for which he recently increased his dose of cimetidine, and atrial fibrillation, for which he takes metoprolol and warfarin. His temperature is 37.0° C (98.6° F), blood pressure is 120/80 mm Hg, heart rate is 90/min, and respiratory rate is 10/min. Physical examination is notable for crusted blood around his left nasal ala and slowly oozing bright red blood from his left nostril. He also has small conjunctival hemorrhages and a large bruise on his knee. The remainder of his physical examination is unremarkable, including a regular heart rate and rhythm and normal chest, abdominal, and neurologic examinations. Laboratory tests show:

WBC count: 6000/mm³
Hemoglobin: 13.5 g/dL
Hematocrit: 40%
Platelet count: 350,000/mm³
International Normalized Ratio: 12.5

-
- **What is the most likely diagnosis?** Supratherapeutic warfarin levels. This patient has clinically significant, persistent bleeding (epistaxis and other hemorrhagic phenomena) in the context of an International Normalized Ratio (INR) of 12.5 while receiving warfarin therapy. His entire clinical presentation can be explained by his medications. Cimetidine inhibits the cytochrome P450 (CYP450) system of drug metabolism (a hepatic enzymatic system that metabolizes drugs for excretion), and warfarin is metabolized by this system. Thus, a recent increase in cimetidine dosage in a patient who takes warfarin could easily lead to dangerously high warfarin levels, evidenced in this patient by severe bleeding and a high INR.

 - **What risk factors are associated with an increased incidence of this condition?** Medications and other compounds that induce the CYP450 system include alcohol, barbiturates, carbamazepine, dexamethasone, griseofulvin, phenytoin, quinidine, and rifampin.

Medications and other compounds that inhibit the CYP450 system include cimetidine, clarithromycin, erythromycin, grapefruit juice, isoniazid, ketoconazole, and ritonavir.

 - **What is the most appropriate treatment for this condition?** With an INR > 10 and bleeding, not only must the warfarin be stopped but low-dose vitamin K₁ should be given. Larger doses will interfere with reanticoagulation. If bleeding is felt to be life threatening, fresh frozen plasma must be given, as vitamin K works by synthesis of clotting factors and will take over 24 hours to correct the situation. Stopping the drug responsible for the prolonged INR is also crucial. This patient should receive nasal packing and be admitted for observation and serial neurologic exams (monitoring for intracranial hemorrhage), INR assessments, and hemoglobin levels. Finally, this patient should be counseled to use a different histamine blocker for his GERD, such as ranitidine, to avoid this complication in the future.
-

► **CASE 19**

A 12-year-old African-American girl is brought to the emergency department (ED) by her parents for confusion, fevers, and a new rash over her legs. They report that she had a “stomach bug” two weeks previously but had been getting better except for occasional headaches. This morning, they had difficulty waking her, and she remained confused on the way to the ED. On physical examination, her temperature is 40.1° C (104.1° F), pulse is 106/min, blood pressure is 95/70 mm Hg, and respirations are 16/min. She is oriented only to person and seems lethargic. Her sclerae are icteric, and there is a pinpoint, nonblanching, macular rash over her lower legs. Initial laboratory findings include normal white blood cell count and differential, hemoglobin of 8.3 mg/dL, hematocrit of 28%, platelets of 13,000/mm³, blood urea nitrogen of 41 mg/dL, and creatinine of 1.6 mg/dL.

-
- | | |
|---|---|
| ■ What is the most likely diagnosis? | Thrombotic thrombocytopenic purpura with hemolytic uremic syndrome (TTP-HUS). TTP is one of the thrombotic microangiopathies, characterized by a microangiopathic hemolytic anemia (causing her icterus) and thrombocytopenia (suggested by her petechiae). Her additional neurologic abnormalities, renal dysfunction, and fever fulfill the classic pentad for TTP-HUS. |
|---|---|
-
- | | |
|--|---|
| ■ What is the epidemiology of this condition? | Peak incidence occurs in the third decade, but cases have been reported in all ages. In childhood, the disease often follows gastroenteritis, especially due to <i>Escherichia coli</i> or <i>Shigella</i> . In adults, cases are often related to pregnancy, HIV infection, post-transplant immunosuppression, or collagen vascular diseases such as systemic lupus erythematosus (SLE). |
|--|---|
-
- | | |
|---------------------------------------|--|
| ■ What is the pathophysiology? | The underlying etiology of TTP is unknown but causes systemic endothelial cell damage. This results in platelet agglutination and the formation of hyaline thrombi in terminal arterioles and capillaries, which shear passing RBCs and cause the hemolytic anemia. Despite their thrombocytopenia, patients with TTP do not exhibit the coagulation anomalies seen in patients with disseminated intravascular coagulation (DIC). |
|---------------------------------------|--|
-
- | | |
|---|--|
| ■ What are the appropriate next steps in management? | TTP is a hematologic emergency, and many patients will require ICU admission. Early initiation of plasma exchange, with a goal of exchanging 150% of the plasma volume daily, has been shown to improve survival. This is continued for several days after remission (demonstrated by normalized platelet count, LDH level, and RBC appearance on peripheral smear). The average duration of plasma exchange is 5–14 days. |
|---|--|
-
- | | |
|---|--|
| ■ What are the major risks of plasma exchange? | <ul style="list-style-type: none"> ■ Air embolus. ■ Citrate toxicity: causes hypocalcemia and metabolic alkalosis. ■ Pulmonary edema. ■ Transfusion reactions. |
|---|--|
-
- | | |
|--|---|
| ■ What is the prognosis for patients with this condition? | Mortality has improved with the widespread use of plasma exchange; current survival rates are reported around 70%. Surprisingly, the degree of renal involvement does not predict mortality from TTP-HUS. |
|--|---|
-

► **CASE 20**

A 20-year-old college student is brought to the emergency department by her boyfriend following a seizure. The patient is still confused, but her boyfriend states that she was complaining of abdominal pain when she woke up. They had attended a party the night before, and the boyfriend believes she took some sort of pills in addition to drinking. He also reports that she has been on a diet and that her eating has been very erratic. On physical examination, she is confused but responsive. Vital signs include a temperature of 37.8° C (100.1° F), heart rate of 115/min, and blood pressure of 110/75 mm Hg. Her abdomen is soft, but she groans on palpation. Neurologic exam is normal except for global areflexia. A Foley catheter is inserted and returns 200 cc of dark reddish-brown urine. Her urinary excretion of aminolevulinic acid (ALA) and porphobilinogen (PBG) is markedly elevated.

- **What is the most likely diagnosis?** Acute intermittent porphyria (AIP). This is an autosomal dominant condition that, like all the porphyrias, involves a defect in heme production leading to an accumulation of porphyrins, specifically ALA and PBG in AIP.

 - **What are the two broad categories of symptoms in these conditions?**

Photocutaneous porphyrias: Acute attacks are precipitated by UV light; primary exam findings include skin blisters and photosensitivity.

Neurovisceral porphyrias: Presents with visceral complaints, primarily a colicky abdominal pain, and neurologic abnormalities such as seizures.

 - **What tests could be used to confirm the diagnosis?** Elevated porphyrin levels can be detected in blood, urine, and stool samples; the specific porphyrins present depends on the type of porphyria. Enzyme assays to identify specific diseases can be helpful. For AIP, the activity of erythrocyte PBG deaminase will be reduced compared to normal controls.

 - **What is the most appropriate treatment for this condition?** She is suffering an acute attack of a neurovisceral porphyria, likely triggered by her poor eating and use of alcohol and barbiturates. She should be treated with high doses of IV glucose or IV hematin; both of these inhibit the production of the toxic intermediates of the heme pathway responsible for her symptoms. In general, patients with a neurovisceral attack must immediately stop all medications or other substances that may have precipitated the attack and must receive treatment for possible infections or illnesses. Patients should also receive analgesia and/or sedation as needed.

 - **What is the most appropriate treatment for photocutaneous porphyria?** The focus in these diseases is on prevention through liberal use of sunscreen and protective clothing. When therapy is needed for an attack, oral activated charcoal or cholestyramine can absorb porphyrins and increase excretion in the stool; similarly, chloroquine forms a water-soluble complex with uroporphyrin to increase its urinary excretion. Phlebotomy to reduce body iron stores can also induce clinical remission.
-

► CASE 21

A 58-year-old man presents to his primary physician with complaints of back pain and problems urinating. His past medical history is significant for a cadaveric kidney transplant 2 months ago. The surgery was successful, and he did not experience any immediate postoperative complications. For the past week, he has been having right lower back pain and malaise. He has noticed a significant decrease in his need to urinate as well as the volume of urine he can produce. He denies any burning on urination. On further questioning, he admits he has not been taking his medications regularly; he estimates he remembers to take his medications three to four times per week. Upon examination, he has a temperature of 38.3° C (101.0° F), blood pressure of 160/98 mm Hg, heart rate of 83/min, and respiratory rate of 18/min. His back is very tender, particularly over the right lumbar paraspinal region. When asked to provide a urine sample, the patient returns with only 20 mL of urine. Relevant laboratory results are as follows:

WBC count: 20,000/mm³
 Serum Na⁺: 135 mEq/L
 Serum K⁺: 3.2 mEq/L
 Blood urea nitrogen: 47 mg/dL
 Serum creatinine: 3.4 mg/dL
 Serum glucose: 115 mg/dL

■ What is the most likely diagnosis?	Acute transplant rejection. Acute rejection typically occurs between 5 days and 3 months after the transplant. Patients can present with fever, pain, lethargy, and organ dysfunction, as demonstrated by the serum chemistries of the patient above.
■ What is the pathogenesis of this condition?	The mechanism of acute rejection is based on the action of cytotoxic T cells against foreign major histocompatibility complexes (MHCs). The primary function of MHCs is to present antigens to cytotoxic and helper T cells. However, they are also potent markers of “self” within the body and must be matched as effectively as possible when a transplant organ is selected.
■ How could this condition be avoided more effectively?	The use of a living donor tends to reduce the risk of acute rejection. Improved compliance with the immunosuppressive regimen could also have prevented this complication. Patient noncompliance may be due to an inability to tolerate the side effects of the immunosuppressive agents; choosing medications that better suit a patient’s lifestyle helps ensure greater compliance and more successful maintenance.
■ What tests and/or imaging studies could be used to confirm the diagnosis?	Tests of organ function can be suggestive of the diagnosis; in this patient, his renal function is clearly compromised, as seen by his elevated BUN and creatinine levels. A biopsy of the transplanted organ typically will reveal T cell and antibody-induced reactions with graft tissue injury. A renal ultrasound will likely demonstrate enlargement of the organ, as well as focal swelling and hypogenicity of the medullary pyramids. Ruling out other causes of acute renal failure in this population, such as calcineurin toxicity, BK virus infection, volume depletion, and ureteric obstruction is important.
■ What is the most appropriate treatment for this condition?	Patients gain relief from acute rejection symptoms via treatment with steroids and antilymphocyte antibodies. However, for long-term management, it is important that the patient adhere carefully to his regimen of immunosuppressive medications.

► **CASE 22**

An 18-year-old African-American woman presents to a gynecologist for her first visit. She is in generally good health but complains of menorrhagia since menarche. She notes that she bleeds profusely from cuts but that she can stop the bleeding with prolonged pressure. Her mother has the same problem, but her two brothers and her father seem to clot more quickly. Her maternal uncle died in a car accident as a teenager and was rumored to be a hemophiliac; two of her maternal aunts also have menorrhagia, but neither they nor her mother have had problems getting pregnant or any complications during pregnancy and delivery. The patient's prothrombin time is 13 seconds, and her partial thromboplastin time is 62 seconds.

- **What is the most likely diagnosis?** von Willebrand's disease. This is the most common inherited coagulopathy and consists of a variety of disorders that produce abnormal forms of von Willebrand factor (vWF). There are many versions of dysfunctional vWF, but they can be classified into three groups with increasing disease severity. The classical form (type I, a quantitative defect) is autosomal dominant; more severe forms (type III) undergo autosomal recessive transmission. Type II vWD is composed of many different qualitative functional defects in the vWF protein. Patients typically present with easy bruising, gingival bleeding, epistaxis (bleeding from the nose and nasopharynx), menorrhagia in women, and bleeding out of proportion to trauma. Von Willebrand's disease must be distinguished from other coagulopathies, but particularly from hemophilia (i.e., type II Normandy); deficiency of factor VIII with normal vWF levels indicates the latter.

- **What is the pathogenesis of this condition?** vWF is synthesized by endothelial cells and megakaryocytes. It is a cofactor for platelet adhesion as well as the carrier for clotting factor VIII. Factor VIII, which is deficient in hemophilia A, is a critical component of the clotting cascade. Deficiencies in vWF limit the body's ability to carry factor VIII and therefore lead to prolonged bleeding and excessive bleeding secondary to minor trauma.

- **What tests could be used to confirm the diagnosis?** Patients with von Willebrand's disease generally have prolonged partial thromboplastin times (PTTs), low to normal vWF antigen, and decreased vWF activity. Factor VIII levels and prothrombin times (PTs) may not be abnormal, which is why the disease often resembles mild hemophilia A. Ristocetin cofactor assay activity (which stimulates platelets through vWF) is typically low. von Willebrand multimer electrophoresis may help differentiate the type of vWD. Patients with type O blood often have vWF levels that are one-third lower than patients with other blood types. Platelet counts may be low in type II vWD (Ha).

- **What is the most appropriate treatment for this condition?** Desmopressin temporarily increases vWF levels by stimulating its release from endothelial cells and concomitantly stabilizes vascular endothelium. However, it can only be given for 2–3 days before endothelial depletion occurs and the therapeutic effect is lost. Patients with severe forms of the disease may benefit from plasma factor VIII replacement, which contains vWF.

- **What is the prognosis for patients with this condition?** This bleeding disorder is much milder than hemophilia. Even for more serious forms of von Willebrand's disease, factor replacement is often highly effective. Overall, the prognosis for these patients is good.

Infectious Disease

Case 1	196
Case 2	197
Case 3	198
Case 4	200
Case 5	201
Case 6	202
Case 7	204
Case 8	206
Case 9	208
Case 10	209
Case 11	210
Case 12	212
Case 13	214
Case 14	215
Case 15	216
Case 16	217
Case 17	218

► **CASE 1**

A 22-year-old HIV-positive woman who emigrated from Botswana 2 months ago presents to the emergency department complaining of worsening shortness of breath and fatigue. She contracted HIV 5 years ago and was started on highly active antiretroviral therapy (HAART) 3 weeks before leaving Botswana. She states that she has been very adherent with her HAART regimen of zidovudine (AZT), lamivudine (3TC), and abacavir and has not missed even one dose. Her CD4 count prior to initiating treatment was 250/mm³. On physical examination, the patient has a temperature of 36.6° C (98.5° F), heart rate of 116/min, blood pressure of 110/68 mm Hg, respiratory rate of 26/min, and percutaneous oxygen saturation level of 97% on room air. Her conjunctivae are noticeably pale, and her capillary refill time is delayed.

- **What is the most likely diagnosis?** AZT-induced anemia. AZT can cause bone marrow suppression and subsequent anemia, usually within several weeks of initiating therapy. Given this patient's history of HIV with a low CD4 count, her anemia could certainly be secondary to HIV-related bone marrow suppression or to an opportunistic infection within the bone marrow. As AZT is the most likely culprit and the easiest to treat, it is prudent to discontinue the AZT and start this patient on a new regimen. If the patient does not improve, further investigation is necessary.

- **What is the mechanism of action of zidovudine?** Zidovudine is a synthetic thymidine analog that is part of the larger class of nucleotide reverse transcriptase inhibitors. Reverse transcriptase is an RNA-dependent DNA polymerase that converts viral RNA into proviral DNA that is then incorporated into the host cell chromosome. Like all available antiretrovirals, nucleoside and nucleotide reverse transcriptase inhibitors prevent infection of susceptible cells but have no impact on cells already harboring HIV. Nucleoside and nucleotide analogs act as substrates for the reverse transcriptase enzyme, thus blocking its ability to bind viral RNA and generate proviral DNA.

- **What are other common adverse effects of zidovudine?** Patients initiating AZT treatment often complain of fatigue, malaise, myalgia, nausea, anorexia, headache, and insomnia. These symptoms usually resolve within the first few weeks of treatment and are generally not cause for a change in drug regimen. More severe adverse effects include peripheral neuropathy, hyperuricemia, neutropenia, myositis, and liver toxicity. Lactic acidosis, with or without hepatomegaly and hepatic steatosis, may also be seen with AZT.

- **What is the pathogenesis of this condition?** AZT causes anemia and often granulocytopenia through bone marrow suppression. This adverse effect most often occurs within the first 4 weeks of treatment in individuals with advanced HIV and low CD4 counts. It is more common when given in higher doses and is often the dose-limiting adverse effect. The anemia can be exacerbated by other drugs that also cause bone marrow suppression, such as ganciclovir.

- **What is the most appropriate treatment for this condition?** In the immediate setting, patients with hemoglobin levels < 7 g/dL should receive transfusion with packed RBCs; two or more units may be required. Long-term management would include switching to an alternative HAART regimen.

► **CASE 2**

A 10-day-old infant is brought by his mother to the pediatrician's office due to purulent discharge from the infant's right eye. The infant was born via spontaneous vaginal delivery without complications 30 minutes after the mother's arrival at the hospital. He had Apgar scores of 8 and 9 at 1 and 5 minutes, respectively. The mother received no prenatal care during her pregnancy. On physical examination, the patient has a temperature of 38.3° C (100.9° F). His right eye is notably erythematous and draining purulent material. The left eye is currently unaffected.

-
- **What is the most likely diagnosis?** Ophthalmia neonatorum (conjunctivitis occurring within the first month of life), most likely caused by *Chlamydia trachomatis*. Occurring within 5–12 days postdelivery, this is the most common cause of infectious conjunctivitis in the neonate and is a common cause of preventable blindness in developing countries. In actively infected mothers, there is a 30–50% vertical transmission rate during vaginal delivery. *Neisseria gonorrhoeae* causes a more rapidly destructive form of infectious conjunctivitis, usually presenting 3–5 days postpartum. It can progress to ulceration or perforation in 24 hours if untreated.

 - **What are other conditions caused by this pathogen?** In addition to urethritis/pelvic inflammatory disease, *C. trachomatis* is an infrequent cause of endocarditis, peritonitis, pleuritis, and possibly periappendicitis and may occasionally cause respiratory infections in older children and adults.

 - **What are the other species of this pathogen and what infections do they typically cause?** *Chlamydophila psittaci* (formerly *Chlamydia psittaci*) causes genital, conjunctival, intestinal, or respiratory infections in many mammalian and avian species. Although mammalian strains of *C. psittaci* are not known to infect humans, avian strains can cross-infect and cause pneumonia and the systemic illness known as **psittacosis**. *Chlamydophila pneumoniae* (formerly *Chlamydia pneumoniae*) is a common cause of upper respiratory tract infections and pneumonia, primarily affecting children, young adults, and the elderly or immunocompromised. Some studies have also linked *C. pneumoniae* infection to atherosclerotic cardiovascular disease and possibly to some asthmas and sarcoidosis as well.

 - **What is the reproductive cycle of this pathogen?** All *Chlamydia* species have a complex reproductive cycle involving the extracellular elementary body and the intracellular reticulate body. Adapted for extracellular survival, the elementary body is the infective form that is transmitted between hosts. Elementary bodies attach to target cells (usually columnar or transitional epithelial cells) and enter the cells via a phagosome. The elementary bodies reorganize into reticulate bodies, which replicate via binary fission within the membrane-bound “inclusion body.” These inclusions resist lysosomal fusion, protecting them from host cell defenses. Within a day, the reticulate bodies condense into elementary bodies, which are then released when the inclusion body ruptures.

 - **What antibiotics are effective against this pathogen?** Chlamydial species are obligate intracellular bacteria that possess both DNA and RNA and have a cell wall and ribosomes similar to those of gram-negative bacteria. Tetracyclines (targeting the 30S ribosome) and macrolides (targeting the 50S ribosome) are effective in treating chlamydial infections.
-

► **CASE 3**

A 21-year-old woman presents to the emergency department because of progressively worsening left wrist pain and malaise over the past 36 hours. The night before admission she developed a fever and loss of appetite. She also developed pain in her palms bilaterally. She denies any history of trauma or unusual physical activity. She does not have any nausea, vomiting, diarrhea, or hematochezia. On examination, she has a temperature of 38.7° C (101.7° F), heart rate of 85/min, respiratory rate of 16/min, and blood pressure of 110/80 mm Hg. The examination is notable for swelling, warmth, and erythema of her left wrist. The wrist joint is extremely tender to palpation. Skin examination is notable for several tender bilateral palmar violaceous pustular eruptions. She is a college student and lives in a sorority house on campus. She drinks and smokes socially and is sexually active with more than one partner.

■ What should be included in the differential diagnosis of monarticular arthritis?	The three main diagnoses to consider in a patient who presents with acute monarticular symptoms are trauma, infection, and crystalline disease (gout and pseudogout). Tick-borne arthropathies and certain systemic disorders, such as systemic lupus erythematosus (SLE), seronegative spondyloarthropathies, and rheumatoid arthritis, are also commonly considered in the differential diagnosis.
■ What is the most likely diagnosis?	Disseminated gonococcal infection (DGI) is the most common cause of acute nontraumatic monoarthritis or oligoarthritis in young adults. Patients with DGI typically present with one of two syndromes: <ul data-bbox="659 838 1308 929" style="list-style-type: none">■ A triad of tenosynovitis, vesiculopustular skin lesions, and polyarthralgias without purulent arthritis.■ Purulent arthritis without associated skin lesions.
■ What risk factors are associated with an increased incidence of this condition?	DGI occurs in 1–3% of patients infected with <i>Neisseria gonorrhoeae</i> . Both host and microbial factors play important roles in the potential for gonorrhea to disseminate. Host factors include female gender (three times more than males), pregnancy, menstrual period, complement deficiencies, and SLE.
■ What laboratory tests could be used to confirm the diagnosis?	<ul data-bbox="659 1135 1442 1453" style="list-style-type: none">■ Synovial fluid analysis.■ At least two sets of blood cultures.■ Synovial, skin, urethral or cervical cultures, throat, and rectal cultures submitted on Thayer-Martin medium. If associated urethritis is simultaneously present, a Gram stain of the urethral exudate should be obtained and examined for the presence of the gram-negative diplococci characteristic of <i>N. gonorrhoeae</i> infection.■ Test for HIV infection, <i>Chlamydia trachomatis</i>, and syphilis serology since coexistent infection with other sexually transmitted diseases is common. In women, a pregnancy test should also be performed.
■ What is the most appropriate treatment for this condition?	The initial therapy of choice is ceftriaxone (1 g either IV or IM) every 24 hours. Centers for Disease Control and Prevention guidelines suggest a minimum treatment course of 7 days for DGI with a switch to oral therapy 24–48 hours after improvement is noted. For a nondisseminated case, a single dose of 125 mg ceftriaxone IM is sufficient. Patients with purulent arthritis require joint drainage. Patients should be empirically treated for chlamydial coinfection, since these two infections often coexist. Common regimens for chlamydial infection include azithromycin and doxycycline.

- **The patient is treated and sent home. She continues to have unprotected sex. Three months later she returns complaining of lower abdominal pain, fever, foul-smelling vaginal discharge, and pain during intercourse and urination. What is the most likely diagnosis?**
-

Her symptoms are most likely a result of pelvic inflammatory disease (PID) caused by *N. gonorrhoeae* or *C. trachomatis* infection. PID is an acute infection of the upper genital tract structures in women, involving any or all of the uterus, oviducts, and ovaries. Untreated PID can lead to serious consequences including infertility, ectopic pregnancy, abscess formation, and chronic pelvic pain.

► **CASE 4**

A 45-year-old woman from Cincinnati presents to her physician complaining of cough, dyspnea, fevers, and weight loss. She has been HIV positive for 20 years and has been using highly active antiretroviral therapy for the past decade. While previously adherent to her regimen, she has lost her health insurance and hasn't seen her regular physician. Her temperature is 39° C (102.2° F), heart rate is 90/min, and respiratory rate is 20/min. Physical exam is significant for diffuse rales, hepatosplenomegaly, and lymphadenopathy. X-ray of the chest reveals reticulonodular infiltrates with a few calcified granulomas. Laboratory studies are as follows:

CBC: Hemoglobin: 10.0 g/dL
WBC count: 4000/mm³
Platelet count: 50,000/mm³
CD4 count: 100/mm³

-
- | | |
|--|---|
| ■ What is the most likely diagnosis? | Disseminated endemic fungal infection, likely histoplasmosis. The endemic fungi are soil-based fungi seen in particular geographic areas and include histoplasmosis and blastomycosis (Ohio and Mississippi River valleys), coccidioidomycosis (southwestern United States), and paracoccidioidomycosis (Latin America). In endemic areas, these fungi commonly cause asymptomatic infection in healthy patients. In patients with a large inoculum, an acute pulmonary infection is seen. Patients with underlying lung disease can develop chronic cavitary disease, which resembles tuberculosis. In immunocompromised patients, especially those with AIDS, disseminated disease can be life threatening. |
| ■ What conditions should be included in the differential diagnosis? | The differential diagnosis of a febrile respiratory illness with lymphadenopathy in a patient with AIDS includes <i>Pneumocystis pneumonia</i> , the <i>Mycobacterium avium</i> complex, disseminated cytomegalovirus, disseminated cryptococcus, lymphoma, or miliary tuberculosis. In acute pulmonary cases in patients without AIDS, the differential list also includes sarcoidosis, which can have a very similar clinical presentation. |
| ■ What is the pathogenesis of this condition? | The endemic mycoses are dimorphic fungi that live in the soil. When the spores are aerosolized and inhaled, they revert to fungal forms and incite a T-cell response that usually clears the infection within 2 weeks. Immunocompromised patients can either develop disseminated disease immediately or as a reactivation of latent infection. Disseminated disease can demonstrate gastrointestinal involvement with ulcerations, polyp development, or obstruction, skin lesions, adrenal involvement, and central nervous system disease. |
| ■ What tests could be used to confirm the diagnosis? | Rapid antigen detection tests can identify the <i>Histoplasma</i> polysaccharide antigen in urine, blood, cerebrospinal fluid, or bronchoalveolar lavage fluid. Direct visualization and culture of the fungus can be done with blood or tissue samples, although culture may take weeks. |
| ■ What is the most appropriate treatment for this condition? | The current recommendation for disseminated histoplasmosis in patients with AIDS is liposomal amphotericin B, followed by itraconazole suppressive therapy for life. The majority of acute pulmonary histoplasmosis infections in immunocompetent patients do not require treatment. |
-

► **CASE 5**

A 17-year-old girl presents to her pediatrician with fatigue and a sore throat of several weeks' duration. She says that she is still able to attend classes at her high school but falls asleep as soon as she gets home. She has never had anything like this before but notes that several of her good friends have missed school recently. On physical examination, her vital signs include a temperature of 39.1° C (102.4° F), heart rate of 76/min, blood pressure of 110/75 mm Hg, and respiratory rate of 12/min. Her throat is markedly erythematous with occasional exudates on the tonsils. She has tender posterior cervical lymphadenopathy bilaterally and mild hepatosplenomegaly. The remainder of her exam is within normal limits. A peripheral blood smear reveals atypical lymphocytosis.

■ What is the most likely diagnosis?	Infectious mononucleosis (mono). This is an acute infection with Epstein-Barr virus (EBV) typically seen in teenagers and young adults. Patients present with the triad of fever, sore throat, and lymphadenopathy. Fatigue frequently accompanies the initial illness and may persist for 3–6 months.
■ What is the pathogenesis of this condition?	EBV is transmitted in bodily fluids, including saliva, and replicates in oropharyngeal epithelial cells before infecting B cells, which disseminate systemically through the lymphoreticular system. While B cells are infected in mono, the atypical lymphocytes seen on peripheral smear are actually T lymphocytes, which help control the infection.
■ What tests could be used to confirm the diagnosis?	The Monospot, or heterophile antibody test, is the first test ordered in a patient with suspected mono. EBV-infected B cells produce antibodies that agglutinate horse and sheep blood samples; however, these antibodies may not be produced until the patient has been symptomatic for a few weeks. If the monospot is negative but clinical suspicion is high, antibody tests against viral capsid antigen or EBV nuclear antigen should be ordered. Clinical disease with negative monospot and antibody tests is likely due to cytomegalovirus (CMV) infection or acute HIV seroconversion syndrome (primary HIV disease).
■ What is the most appropriate treatment for this condition?	There is no effective antiviral therapy for mono, so treatment is mainly supportive. Steroids are indicated in case of tonsillar enlargement that threatens the patient's airway, severe autoimmune hemolytic anemia, or significant thrombocytopenia.
■ What are the potential complications of this condition?	<ul style="list-style-type: none"> ■ CNS infection ■ Splenic rupture ■ Upper airway obstruction ■ Bacterial superinfection ■ Fulminant hepatic necrosis ■ Autoimmune hemolytic anemia
■ The patient is misdiagnosed with streptococcal pharyngitis and treated with ampicillin. What adverse event is associated with this treatment?	Patients with mono who receive β -lactam antibiotics frequently develop a prolonged, pruritic drug rash. The rash resolves with discontinuation of the drug and does not indicate future sensitivity or allergy to the class of antibiotics.

► **CASE 6**

A 42-year-old woman presents to her physician with an erythematous annular patch with central clearing on her left forearm. The patient states that the rash began as a small red papule about 5 days ago and has grown progressively larger. She also complains of fatigue, headache, myalgias, and intermittent arthralgias that have lasted 2 weeks. She has remained afebrile, and her vital signs are stable. Physical examination is significant for a 9 × 9-cm erythematous patch on her left forearm that has concentric rings of redness and a clearing center. She also has cervical and axillary lymphadenopathy. The remainder of the examination is unremarkable. She has no recent travel history, no sick contacts, and keeps several dogs for hunting in the woods near her Connecticut home.

■ What is the most likely cause of her rash?	The most likely cause of an erythematous annular rash with red expanding borders and central clearing is erythema migrans, caused by the spirochete <i>Borrelia burgdorferi</i> . The tick must be imbedded for 2–3 days for infection to be transmitted because borrelia replication begins only after the tick has started to feed. Lyme disease is most often seen in the northeastern United States.
■ What else should be considered in the differential diagnosis?	In the southern United States, a similar syndrome called STARI (southern tick-associated rashlike illness) has been described, though the causative organism has not been isolated. Other causes to consider include tinea, erysipelas, cellulitis, nummular eczema, and insect bites.
■ What is the most likely diagnosis?	Lyme disease, a multisystem inflammatory disease caused by spirochetes, must be considered in a patient from an endemic area with a classic “bull’s-eye” rash of erythema migrans in combination with constitutional symptoms.
■ What is the most appropriate immediate treatment for this condition?	Doxycycline, amoxicillin, and cefuroxime axetil, given for approximately 2–3 weeks, are all effective for the treatment of early Lyme disease. When given in a timely fashion, these oral antibiotics prevent progression to later features of disease, although treatment may not decrease the duration or severity of the symptoms of early disease.
■ How can the diagnosis of this condition be confirmed?	The diagnosis of early Lyme disease is clinical because the sensitivity of serologic testing is approximately 50% in early disease (and increases to over 90% by the later stages). The fact that the patient lives near a wooded area in an endemic area, and the history that the rash expanded over several days and surpassed 5 cm in diameter, are useful clues. Diagnosis of Lyme disease is aided by serologic testing in later disease, which should include antibody testing by enzyme-linked immunosorbent assay (ELISA). If positive, follow-up with Western blot testing for both immunoglobulin G and M antibodies is required to determine a definitive diagnosis. By weeks 6–8 of infection, most patients will have an appropriate antibody response.

- **The patient's husband presents to the physician 6 months later complaining of left-sided facial palsy. What is the most likely diagnosis and what is the most appropriate treatment?**

This patient has Bell's palsy, most likely caused by disseminated *B. burgdorferi*. Presentation of disseminated disease can occur days to months after the tick bite. Symptoms include carditis, migratory arthralgias, CNS involvement including meningitis and cranial nerve palsies. IV antibiotic therapy is indicated for early neurologic disease with one exception: isolated facial palsy (of cranial nerve VII) can be treated with oral antibiotics if the CSF reveals no inflammatory changes and there are no other objective neurologic findings.

- **What other symptoms could this patient expect to develop over time if the condition is not treated?**

Late Lyme disease occurs months to years after initial infection. Arthralgias are most common, but neurologic manifestations (encephalopathy, neurocognitive dysfunction, peripheral neuropathy) and nonspecific symptoms (headache, fatigue) also occur.

► **CASE 7**

A 6-year-old boy presents to his pediatrician with high fevers, chills, and sweats that he has experienced since returning from a family trip to India. His parents say he has had no energy since their return, has complained of stomach and muscle aches, and has been unable to tolerate any food. He did not receive any prophylactic medications during their trip. On physical examination, he is clinging to his mother and appears uncomfortable. Vital signs include a temperature of 40.1° C (104.1° F), heart rate of 157/min, blood pressure of 88/65 mm Hg, and respiratory rate of 16/min. His abdomen is soft with marked splenomegaly. There is no lymphadenopathy, nuchal rigidity, or rash.

■ **What conditions should be included in the differential diagnosis?**

- Malaria
 - Typhoid fever
 - Viral gastroenteritis
 - Dengue fever
 - Influenza
-

■ **What is the most likely diagnosis, and how can it be confirmed?**

Malaria. This is a hematologic infection with one of four species of *Plasmodium* (*P. falciparum*, *P. vivax*, *P. ovale*, or *P. malariae*). Characteristic symptoms include a cyclic fever with chills and diaphoresis lasting 4–6 hours and recurring every 2–3 days, depending on the species; early in infection, however, fevers are generally continuous. Thick and thin blood films should be obtained at intervals to identify the strain of *Plasmodium*. More sensitive tests, including fluorescent antibody methods and polymerase chain reaction, are also available.

■ **What is the epidemiology of this condition?**

There are 300–500 million cases of malaria annually worldwide, causing up to 2.7 million deaths, especially in children. *Plasmodium* is endemic in Oceania, sub-Saharan Africa, Southeast Asia, and South America; infection should be suspected in patients from those areas.

■ **What is the pathogenesis of this condition?**

Malaria is transmitted primarily via the bite of a female *Anopheles* mosquito. Sporozoites travel through the blood stream to the liver, where they infect hepatocytes and replicate, forming a liver schizont. The liver schizont ruptures and releases thousands of merozoites, which infect red blood cells; in *P. vivax* and *P. ovale* infections, some parasites remain dormant in the liver and can reactivate to cause late relapses months to years later. Parasite development completes in the red blood cell, forming a red cell schizont. Rupture of the red blood cells causes the characteristic fever spike after 48–72 hours. Parasite metabolism within the red blood cell can cause anemia, hypoglycemia, and lactic acidosis.

■ **What is the most appropriate treatment for this condition?**

Uncomplicated malaria infections can be treated with oral medications. Knowledge of the area of travel and medication resistance patterns is necessary to choose the appropriate regimen. Chloroquine has been the standard treatment but has increasingly been replaced with alternative medicines like quinine, atovaquone, and mefloquine or combinations such as proguanil/atovaquone (Malarone). Severe infections should be treated with parenteral medications administered in the hospital setting.

■ **What is the appropriate prophylaxis for this condition?**

Those with plans to travel to endemic areas should take appropriate precautions. Preventing mosquito bites through the use of DEET insect repellent, insecticide-treated bednets, window screens, and light-colored clothing is prudent. In addition, an antimalarial drug should be prescribed immediately prior to and during the trip to prevent infection.

■ **What are potential complications of this infection?**

- Cerebral malaria
 - Severe hemolytic anemia
 - Acute tubular necrosis with renal failure
 - Noncardiogenic pulmonary edema
-

► **CASE 8**

A 4-year-old girl presents to her pediatrician with pain and swelling of her right thigh. Her parents note that she has been playing outside frequently and suffered a questionable spider bite several days ago. The child has had increasing pain and discomfort since that time and now is not as active as usual. Over the last day, she has not been eating well, has had a fever up to 38.6° C (101.4° F), and is fussy and irritable. Her past medical history is significant only for a prior soft tissue infection at 2 years of age. Her mother thinks some of the other children at daycare may have had similar skin infections. On physical examination, her temperature is 38.9° C (102.1° F), blood pressure is 95/69 mm Hg, and heart rate is 115/min. The patient also has a 4 × 5-cm fluctuant mass on her medial right thigh with overlying erythema, which is obviously painful to touch.

- **What is the most likely diagnosis?** Given the history of a prior skin infection, contacts with similar infections, and the prevalence of community-acquired methicillin-resistant *Staphylococcus aureus* (MRSA), one has to assume this is an MRSA abscess and treat it accordingly.

 - **What is the most appropriate treatment for this condition?** The standard treatment for a fluctuant mass (i.e., abscess) is incision and drainage (I&D) with subsequent culture, plus or minus additional antibiotic therapy. For an abscess smaller than 5 cm, an I&D alone should effectively treat the infection. While it is possible to perform the procedure under local anesthesia with or without sedation, many practitioners would consult general surgery to drain the abscess under general anesthesia. In this case, the patient also has systemic signs of infection (fever, tachycardia), so determining if a bloodstream infection is present by obtaining blood cultures should occur along with systemic anti-MRSA treatment. As an inpatient, the patient will receive IV vancomycin, followed by 7–10 days of clindamycin or trimethoprim-sulfamethoxazole for outpatient therapy. While less effective, a long-acting tetracycline (such as doxycycline) may be a reasonable choice for adults. It should be avoided in children because of deposition in bones and teeth. It should also be noted that clindamycin resistance is inducible in certain strains of MRSA that are erythromycin resistant, so knowledge of local susceptibility patterns is important prior to choosing antibiotic therapy.

 - **How may future infections be prevented?** Recurrence rate is thought to be greater than 10%. Decolonization techniques are becoming popular with pediatricians, though the efficacy is unclear to date. Chlorhexidine or bleach baths as well as intranasal mupirocin have been offered as potential decolonization strategies. The CDC recommends several measures to limit the spread of community-acquired MRSA including covering draining wounds with clean bandages, washing hands and clothes after contact with contaminated wound, avoidance of shared towels/clothes/athletic equipment that may become contaminated, and cleaning sports equipment with a disinfectant effective against staphylococci.
-

■ What is the epidemiology of this infection?

Methicillin-resistant *Staphylococcus aureus* refers to strains of staphylococcus resistant to all β -lactams. Initially only a pathogen in health care settings, new strains of MRSA (community associated MRSA or CA-MRSA) have become a significant source of disease burden in the community at large over the last decade. In most communities, a predominant strain of CA-MRSA called USA300 has emerged, which usually expresses an exotoxin (Panton-Valentine leukocidin) associated with necrotizing pneumonia, abscess formation, and skin necrosis. A recent study found almost 10% of children to be asymptotically colonized with MRSA.

► **CASE 9**

A 58-year-old diabetic man presents to his primary care physician complaining of low-grade fever and severe right leg pain. He had sustained a small laceration to his calf while playing tennis with friends the day before. His pain began several hours after his injury, with localized redness and swelling. The pain worsened to the point where he had difficulty walking. On physical examination, he is ill-appearing and diaphoretic. His temperature is 38.9°C (102.1°F), heart rate is 115/min, blood pressure is 98/60 mm Hg, and respiratory rate is 29/min. On physical examination, his right leg is erythematous with a bluish hue, cold, swollen, and very painful to palpation.

-
- **What is the most likely diagnosis?** Necrotizing fasciitis is an infection of the deep fascia. Infection initially begins in the epidermis but quickly spreads to the dermis, causing extensive thrombosis and subsequent necrosis of blood vessels in the dermal papillae. From there, it extends to the deep fascia, where it rapidly spreads along fascial planes through venous channels and lymphatics. Patients often appear toxic and may quickly progress to shock and multiorgan failure.

 - **What are the most common causative pathogens of this condition?** Necrotizing fasciitis is most commonly associated with group A streptococci. The infection may also be polymicrobial and include aerobic and anaerobic bacteria. The presence of gas gangrene may suggest infection caused by *Clostridium perfringens*.

 - **What is the pathogenesis of this condition?** Infection usually begins after trauma (most often a seemingly minor event) that results in a break in the skin (even unnoticed). The epidermal defect allows organisms access to the deeper structures, where proliferation results in rapid progression.

 - **What risk factors are associated with an increased incidence of this condition?** Risk factors include conditions that compromise systemic blood flow and wound healing, such as peripheral vascular disease and diabetes mellitus. Conditions that cause a breach in skin, such as recent surgery or instrumentation or a penetrating injury, also predispose a patient to necrotizing fasciitis.

 - **What is the most appropriate treatment for this condition?** All patients with suspected necrotizing fasciitis should receive empiric antibiotic coverage for aerobic and anaerobic bacteria immediately after obtaining blood cultures to isolate the offending organism. While many different antibiotic combinations are possible, penicillin combined with clindamycin is most effective for group A streptococcus. Other regimens include ampicillin/sulbactam, piperacillin/tazobactam, or imipenem/cilastatin all combined with clindamycin. The recent increase in recognized necrotizing fasciitis due to MRSA suggests that therapy targeted against this organisms should also be a component of the empirical regimen. To reduce morbidity and mortality, however, treatment with antibiotics must be paired with early and aggressive surgical exploration. Surgical intervention is necessary to visualize the deep tissue structures, remove necrotic tissue, reduce compartment pressure, and obtain suitable material for Gram's staining and for aerobic and anaerobic cultures.

 - **What laboratory value may be used to mark response to treatment?** Serum creatine phosphokinase (CPK) levels may be used to track response to treatment. Initial values are markedly elevated due to severe tissue and muscle injury. While initial levels of serum CPK may not correlate with the degree of initial infection, a rise or fall from the initial value can be used to track an inappropriate or appropriate response to treatment, respectively.
-

► **CASE 10**

A 70-year-old woman who recently started chemotherapy for acute myeloid leukemia presents to the emergency department with fever of 1 day's duration. She is otherwise asymptomatic. She has a temperature of 38.7° C (102° F), heart rate of 88/min, respiratory rate of 12/min, and blood pressure of 110/80 mm Hg. Physical examination is unremarkable. Her indwelling vascular catheter site is without erythema or tenderness. A chest radiograph is normal. Relevant laboratory findings include a WBC count of 1.2/mm³, hemoglobin of 11.4 g/dL, platelet count of 150,000/mm³, and an absolute neutrophil count of 290/mL. RBC levels are within normal limits.

<p>■ What is the most appropriate next step in management of this patient?</p>	<p>Fever in a neutropenic patient must be treated as a medical emergency, and empiric therapy with antibiotics should be instituted immediately after obtaining cultures of the blood, urine, and sputum. The empiric antibiotics must be effective against gram-negative bacteria, particularly <i>Pseudomonas aeruginosa</i>. Common regimens include monotherapy with imipenem, meropenem, or a combination of a β lactam and an aminoglycoside (a synergistic combination).</p>
<p>■ What laboratory tests should be included in the diagnosis of febrile neutropenic patients?</p>	<ul style="list-style-type: none"> ■ CBC with differential. ■ Electrolytes. ■ Liver function tests. ■ Cultures of blood, urine, stool, and wound (if present). ■ Radiograph of the chest. ■ CT scan to rule out an abscess.
<p>■ Blood cultures grow gram-positive cocci in clusters. What is the appropriate next step?</p>	<p>The blood culture result suggests infection with staphylococci. An antibiotic directed at gram-positive cocci should be started, even without further identification of the organism. Vancomycin is usually the drug of choice for gram-positive infections in neutropenic patients.</p>
<p>■ When should the patient's indwelling catheter be removed?</p>	<p>Catheter removal is recommended for patients with catheter-related candidemia or bacteremia in which one of the following organisms is implicated: <i>Staphylococcus aureus</i>, <i>Pseudomonas</i> species, rapid-growing atypical mycobacteria, <i>Stenotrophomonas</i> species, <i>Bacillus</i> species, or <i>Corynebacterium jeikeium</i>.</p>
<p>■ Despite appropriate management, the fever persists for the next 5 days. The patient remains stable, and further cultures are negative. What is the appropriate next step?</p>	<p>The incidence of fungal infection (especially <i>Candida</i> species or <i>Aspergillus</i> species) rises after patients have experienced > 7 days of persistent fever and neutropenia. Antifungal therapy is routinely added after 5–7 days of persistent fever in a neutropenic patient when reassessment does not yield a cause. Amphotericin B is most commonly used, but less toxic drugs such as voriconazole, caspofungin, and itraconazole are gaining popularity.</p>
<p>■ What other therapy should be considered for this patient?</p>	<p>In acute myeloid leukemia, primary administration of a colony-stimulating factor is recommended after completion of induction chemotherapy to shorten the duration of neutropenia. Several prospective randomized controlled trials have evaluated the efficacy of hematopoietic colony-stimulating factors as treatment for neutropenic fever. While some provided evidence of minor clinical benefit, including shorter duration of neutropenia (ANC < 500/μL) and hospitalization, decreased mortality rates have not consistently been seen.</p>

► **CASE 11**

A 9-year-old boy presents to his pediatrician with right leg pain and intermittent fever of 5 days' duration. He complains of pain in his right leg that has gotten progressively worse, and he has been having an increasingly difficult time walking over the past 2 days. He fell off of his skateboard 7 days ago but has no other history of trauma. He has no previous medical problems. He denies recent weight loss, cough, diarrhea, or dysuria. On examination, his temperature is 39.4° C (102.9° F), heart rate is 110/min, respiratory rate is 16/min, and blood pressure is 95/50 mm Hg. He is alert and well appearing. Physical examination is significant for edema, warmth, and tenderness over his right proximal tibia. The remainder of his examination is unremarkable.

■ What conditions should be included in the differential diagnosis?	The differential diagnosis of a child who presents with fever, bone pain, and tenderness includes bone infarction due to sickle cell disease, cellulitis, Ewing's sarcoma, leukemia, neuroblastoma, osteomyelitis, osteosarcoma, rheumatic fever, septic arthritis, thrombophlebitis, toxic synovitis.
■ What laboratory tests should be ordered for this patient?	The most useful laboratory values are the acute phase reactants, erythrocyte sedimentation rate (ESR) and C-reactive protein (CRP), which can identify acute inflammatory processes. The value for ESR usually starts to increase about 48–72 hours into an infectious process. The CRP rises earlier than the ESR, about 6–10 hours after the onset of inflammation. A complete blood count can be useful in detecting an elevated WBC or signs of leukemia. Blood cultures can identify the causative organism in 30–50% of cases.
■ A radiograph of the right tibia is normal. MRI shows a hyperintense signal in the marrow with a small fluid-filled pocket elevating the periosteum, as well as soft tissue swelling of the right proximal tibia. What is the most likely diagnosis?	Acute osteomyelitis. MRI is now the most sensitive modality for detecting changes in bone consistent with acute osteomyelitis. Bone marrow edema is seen as low signal intensity (dark) on T1-weighted images and high signal intensity (bright) on T2-weighted images. These changes are not specific, so findings must be interpreted within the clinical context.
■ What is the pathogenesis of this condition?	Acute bacterial osteomyelitis occurs either by hematogenous seeding or direct spread from a soft tissue infection. Acute hematogenous osteomyelitis is the most common presentation in children. Acute hematogenous osteomyelitis has a predilection for long bones, as the cancellous framework in the metaphysis facilitates spread of the infection. This patient most likely developed his infection by hematogenous seeding.
■ What are the most likely pathogens involved in this condition?	In both infants and children, <i>Staphylococcus aureus</i> is the most common organism recovered. Other frequent pathogens include group B streptococci and <i>Escherichia coli</i> in neonates, and group A streptococci in children with varicella infection. <i>Streptococcus pneumoniae</i> is an uncommon cause of osteomyelitis but occurs in children under 24 months of age. <i>Kingella kingae</i> (a member of the HACEK group) is an important organism to consider in children < 5 years of age. In patients with sickle cell disease, osteomyelitis is often caused by <i>Salmonella</i> , because impaired splenic function predisposes to infection with encapsulated organisms.

- **What is the most appropriate treatment for this condition?**

Initial intravenous antimicrobial therapy should be directed against *S. aureus* and group A streptococci.

Surgical intervention is indicated if the patient has not responded to antimicrobial therapy; there is evidence of a persistent soft tissue abscess or subperiosteal collection; or joint infection is suspected or diagnosed.

► **CASE 12**

A 31-year-old woman with no known past medical history presents to the emergency department in respiratory distress. She recently emigrated with her family from India and is unable to speak English. Through a translator, she describes increasing shortness of breath over the past 2 weeks with a nonproductive cough. On physical examination, she is a thin and ill-appearing woman in respiratory distress. She is notably using her accessory muscles to breathe. Vital signs include a temperature of 38.3° C (101.8° F), heart rate of 122/min, blood pressure of 122/66 mm Hg, respiratory rate of 34/min, and oxygen saturation of 84%. Auscultation of the lungs reveals bibasilar crackles with relatively clear middle and upper lung fields. Her oral cavity reveals a white film on her tongue and buccal mucosa.

-
- **What is the most likely diagnosis?** Pneumocystosis. Pneumocystosis is a pneumonia caused by the opportunistic fungal pathogen *Pneumocystis jiroveci* (formerly *P. carinii*). Occurring primarily in the immunocompromised host, infection with *P. jiroveci* causes an indolent course of worsening dyspnea, fever, and nonproductive cough. The key physical examination clue is the presence of tachypnea, tachycardia, and cyanosis in the context of a relatively normal lung examination. Diagnosis thus relies on a high index of clinical suspicion and a thorough history. Pneumocystosis is the most common presenting infection in newly diagnosed AIDS.

 - **What are the classic radiographic findings for patients with this condition?** The classic findings on chest radiography consist of diffuse, bilateral infiltrates without evidence of distinct hilar adenopathy. They are often described as having a “ground-glass” appearance (see Figure 8-1).

 - **Below what CD4 count is this condition common?** The incidence of *Pneumocystis* pneumonia increases in direct proportion to the fall in a patient’s CD4 count, with most cases occurring in patients with CD4 counts < 200/mm³. Up to 80% of AIDS patients not receiving prophylaxis will contract *P. jiroveci* pneumonia (PCP), making it a major cause of AIDS-related death, especially in the developing world.

 - **What prophylactic treatment is generally administered in such patients?** Primary prophylaxis for *Pneumocystis* pneumonia should be given to any patient with a CD4 count < 200/mm³, a CD4 percentage below 14%, or weight loss or oral candidiasis. Secondary prophylaxis is indicated for both HIV-infected and non-HIV-infected patients with prior PCP infection. Primary and secondary prophylaxis should not be discontinued in patients with HIV until CD4⁺ counts have been > 200/mm³ for at least 3 months. The first-line antimicrobial agent for prophylaxis is trimethoprim-sulfamethoxazole. Alternative agents for patients with sulfa allergies include dapsone, pentamidine, and atovaquone-proguanil.

 - **What risk factors are associated with an increased incidence of this condition?** Serologic evidence indicates that asymptomatic infections with *P. jiroveci* occur in most people by a young age. Symptomatic disease, however, tends to occur only in those with abnormal or altered cellular immune systems (i.e., patients with AIDS, severe malnutrition, cancer, etc.).
-

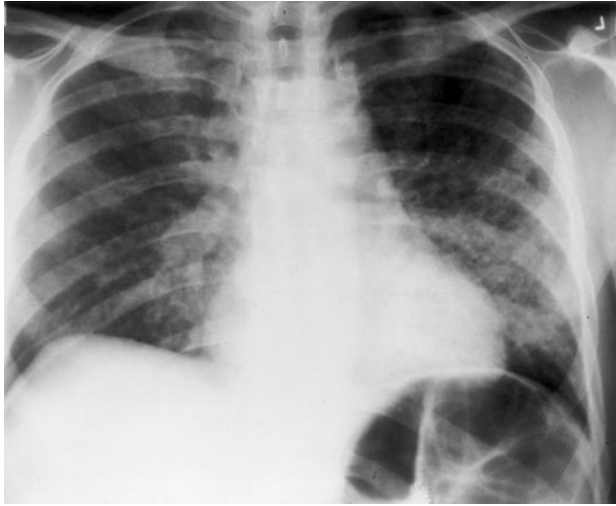

FIGURE 8-1. Ground-glass appearance on chest radiography in *P. jirovecii* pneumonia. (Reproduced, with permission, from Kasper DL, Braunwald E, Fauci AS, Hauser SL, Longo DL, Jameson JL, Isselbacher J, et al. *Harrison's Principles of Internal Medicine*, 16th ed. New York: McGraw-Hill, 2005: Fig. 191-1.)

► CASE 13

A 22-year-old woman presents to her physician with complaints of fatigue, shortness of breath, and loss of appetite. Her symptoms started 2 weeks ago and have progressively worsened. She has had a fever for the past 3 days and has been having night sweats. Her past medical history is unremarkable except for a wisdom tooth extraction approximately 2 months before she came to the clinic. She denies any recent travel, and she has no pets or sick contacts. On physical examination, she has a temperature of 38.6° C (101.4° F), heart rate of 112/min, respiratory rate of 18/min, and blood pressure of 110/85 mm Hg. She has a 4/6 holosystolic murmur that radiates to the left axilla. Skin examination reveals scattered petechiae on her extremities; nonblanching, linear, reddish-brown lesions under her nail beds; and nonpainful erythematous, macular, blanching lesions on her palms and soles.

- | | |
|--|---|
| ■ What is the most likely diagnosis? | The patient's symptoms, combined with a heart murmur and associated skin lesions, are most suggestive of subacute infective endocarditis following bacteremia from her dental procedure. The lesions under her nails are most likely splinter hemorrhages, and the macular lesions are probably Janeway lesions. |
| ■ What are common clinical findings on physical exam that are associated with this condition? | <ul style="list-style-type: none">■ Janeway lesions (macular, blanching, nonpainful, erythematous lesions on the palms and soles).■ Roth's spots (exudative, edematous hemorrhagic lesions of the retina).■ Nail-bed (splinter) hemorrhages.■ Osler's nodes (painful violaceous nodules found in the pulp of fingers and toes).■ Fever.■ Anemia.■ New or changed heart murmur. |
| ■ What risk factors are associated with an increased incidence of this condition? | <ul style="list-style-type: none">■ Rheumatic, congenital, or valvular heart disease.■ Prosthetic heart valves.■ IV drug abuse.■ Immunosuppression. |
| ■ What are the most common pathogens associated with this condition in patients without prosthetic heart valves? | <ul style="list-style-type: none">■ Streptococci (particularly <i>Streptococcus viridans</i>), 50%.<ul style="list-style-type: none">■ <i>Staphylococcus aureus</i>, 20%.■ Enterococci, 10%.■ HACEK organisms (<i>Haemophilus aphrophilus</i> [recently renamed <i>Aggregatibacter aphrophilus</i>], <i>Actinobacillus actinomycetemcomitans</i>, <i>Cardiobacterium hominis</i>, <i>Eikenella corrodens</i>, and <i>Kingella kingae</i>), 5%.<ul style="list-style-type: none">■ Culture negative, 5%. |
| ■ What are the most appropriate next steps in the management of this patient? | Three separate sets of blood cultures, each from a separate venipuncture, obtained over 24 hours, are recommended to evaluate suspected endocarditis. Transesophageal echocardiogram is preferred over a transthoracic echocardiogram to evaluate for valvular vegetations. A complete blood count is performed to look for anemia. A basic metabolic panel and urinalysis are performed to evaluate renal function (immune complex glomerulonephritis often occurs in endocarditis). |
| ■ What are some possible complications of this condition? | <ul style="list-style-type: none">■ Cardiac: valvular damage, heart failure, abscesses, pericarditis.■ Neurologic: meningitis/encephalitis, embolic stroke, cerebral hemorrhage, brain abscess or cerebritis, seizures.■ Renal: renal infarction, glomerulonephritis.■ Musculoskeletal: osteomyelitis. |
-

► **CASE 14**

A 6-year-old girl presents to the emergency department (ED) with a 6-day history of fever, malaise, irritability, diffuse myalgias, abdominal pain, nausea, and vomiting. She had been seen in the ED 4 days prior to admission for fever, abdominal pain, nausea, and vomiting and was diagnosed with viral gastroenteritis. In the past 4 days, she has developed a rash that started on her wrists and ankles and spread toward her trunk. She has a temperature of 39.3° C (102.7° F), heart rate of 130/min, respiratory rate of 16/min, and blood pressure of 87/45 mm Hg. Physical examination is significant for hepatosplenomegaly and an erythematous papular rash with scattered petechiae on the trunk, arms, legs, palms, and soles. The patient lives with her parents, two siblings, and three dogs. The family had recently traveled to North Carolina and gone bird watching in the woods. Relevant laboratory findings are as follows:

CBC: WBC 11.4/mm³, Platelets 90/mm³

AST: 279 U/L

ALT: 77 U/L

■ What conditions should be included in the differential diagnosis?	<ul style="list-style-type: none"> ■ Ehrlichiosis ■ Infectious mononucleosis ■ Leptospirosis ■ Meningococemia ■ Rocky Mountain spotted fever ■ Viral exanthem, especially measles ■ Viral hepatitis
■ What is the most likely diagnosis?	<p>The patient's symptoms are most suggestive of Rocky Mountain spotted fever (RMSF), a tick-borne illness caused by <i>Rickettsia rickettsii</i>. All species of rickettsia generally cause a small-vessel vasculitis, manifested by fever, headache, and rash. Clues to this diagnosis include the petechial rash that began on her wrists and ankles and spread centrally, thrombocytopenia, hyponatremia, and elevated liver enzyme levels. Additionally, the patient recently visited an area with a high incidence of RMSF.</p>
■ What is the epidemiology of this condition?	<p>In the United States, RMSF is most prevalent in the southeastern and south central states. Most cases of RMSF occur in the spring and early summer. Two-thirds of cases occur in children under the age of 15 years, with the peak incidence occurring between the ages of 5 and 9 years. Individuals with frequent exposure to dogs and who reside near wooded areas may also be at increased risk for infection.</p>
■ What is the typical rash seen in this condition?	<p>Most patients with RMSF develop a rash between 3 and 5 days after infection, and it is often not present or is very subtle at initial presentation. The typical rash of RMSF begins on the ankles and wrists and spreads both centrally and to the palms and soles. It often begins as a macular or maculopapular eruption and then usually becomes petechial. Urticaria and pruritus are not characteristic of RMSF, and their presence make the diagnosis highly unlikely. Since mortality increases dramatically after about 5 days, RMSF is an important diagnosis to suspect even before the rash appears.</p>
■ What tests could be used to confirm the diagnosis?	<p>Biopsy of a skin lesion can establish the diagnosis of RMSF using direct immunofluorescence or immunoenzyme methods. Diagnosing RMSF is best confirmed using the indirect fluorescent antibody test.</p>
■ What is the most appropriate treatment for this condition?	<p>RMSF titers can take days to determine, so antibiotic treatment should be initiated <i>immediately</i> when there is a suspicion of RMSF. Doxycycline is the drug of choice for patients with RMSF, even in children.</p>

► **CASE 15**

A 67-year-old woman with a past medical history significant for rheumatoid arthritis for 15 years presents to the emergency department complaining of a painful, swollen left knee that has been worsening over the past 3 days. She denies any recent trauma to the affected joint and states that she has been compliantly taking methotrexate for her rheumatoid arthritis for the past 5 years. She further denies any recent sexual activity other than with her husband of 41 years. On physical examination, her temperature is 38.5° C (101.3° F), heart rate is 90/min, and blood pressure is 110/74 mm Hg. Her knee is markedly warm, erythematous, swollen, and painful. A mild effusion is noted.

-
- **What is the most likely diagnosis?** Septic arthritis, characterized by the sudden onset of acute arthritis, usually monarticular, most often in large weight-bearing joints or the wrists. Common signs and symptoms include fever, chills, malaise, and joint pain, swelling, and effusion. Other possible diagnoses to consider include gout, pseudogout, and acute rheumatic fever. Gout and pseudogout require visualization of crystals on synovial fluid analysis. Acute rheumatic fever commonly manifests as migratory arthritis and involves many joints rather than a single joint.

 - **What are the most common causative pathogens?** Septic arthritis can be divided into two general categories, gonococcal (caused by *Neisseria gonorrhoeae*) and nongonococcal. *Staphylococcus aureus* is the most common cause of nongonococcal septic arthritis, followed by group A and group B streptococci. In patients with recent arthroscopy or prosthetic joint surgery, *S. epidermidis* is a common pathogen. Infection with gram-negative bacteria is becoming increasingly more common, especially in injection drug users and immunocompromised hosts. *Escherichia coli* and *Pseudomonas aeruginosa* are the most common gram-negative offenders in adults.

 - **What risk factors are associated with an increased incidence of this condition?** Nongonococcal acute bacterial arthritis is usually associated with persistent bacteremia, as with chronic injection drug users or patients with endocarditis, or a damaged or prosthetic joint.

 - **What is the most important laboratory test in establishing the diagnosis?** In all patients with a swollen or erythematous joint, the joint must be aspirated for analysis of the synovial fluid. A leukocyte count < 50,000/μL suggests an inflammatory condition, such as gout, pseudogout, or rheumatoid arthritis. A leukocyte count > 50,000/μL is consistent with septic arthritis. The differential will usually demonstrate > 90% neutrophils. Values are lower but less well defined for prosthetic joints. Additionally, synovial fluid glucose is usually low, and a Gram stain is positive in 75% of staphylococcal infections and in 50% of gram-negative infections.

 - **What are the typical radiographic findings in this condition?** Early in the disease, radiographs are usually normal, as joint destruction is rare with prompt treatment. Within a few days, however, demineralization of the bone may become evident. Bony erosions and narrowing of the joint space with subsequent osteomyelitis and periostitis may be seen within 2 weeks if treatment is inadequate.

 - **What are the pathologic sequelae of this condition?** Pathologic changes are fairly consistent regardless of the affected joint. Pathologic changes include varying degrees of acute inflammation, with synovitis, intra-articular effusion, and possible abscess formation in synovial or subchondral tissues. Ultimately, articular destruction occurs if treatment is not adequate.
-

► **CASE 16**

A 61-year-old man with a past medical history significant for coronary artery disease underwent an open abdominal aortic aneurysm repair 2 days ago. The patient has been doing well, with systolic blood pressures ranging between 100 and 120 mm Hg and no evidence of cardiac ischemia detected by telemetry monitoring. He says he is feeling well except for his recent right thigh and knee pain. On physical examination, the right leg is swollen and slightly pale. It is painful to palpation and to full extension.

-
- **What is the most likely diagnosis?** Thrombophlebitis due to a deep vein thrombosis (DVT). Unlike superficial phlebitis, which is an inflammatory thrombosis of a superficial *normal* vein due to infection or trauma from needles and catheters, or of a *varicose* vein secondary to chronic venous insufficiency, DVT is due to thrombotic obstruction of a larger vein with or without an inflammatory response. DVT risk is thought to increase with certain risk factors known as “Virchow’s triad” (mnemonic: **SHE**): **S**low blood flow, **H**ypercoagulability, and **E**ndothelial damage.

 - **What other conditions should be included in the differential diagnosis?** Included in the differential diagnosis for DVT are: lymphedema, cellulitis, erysipelas, superficial phlebitis, and lymphangitis. Rupture of the plantar muscle, although uncommon, produces pain, swelling, and ecchymotic areas in the dependent ankle area and should be considered in the appropriate clinical setting.

 - **What are possible complications of this condition?** The most dreaded complication of DVT is pulmonary embolism, whereby the free-floating tail of the venous thrombus breaks off and lodges in the pulmonary vasculature, occluding pulmonary blood flow and thus preventing gas exchange. Another complication, post-thrombotic syndrome, occurs as a result of the thrombus damaging the endothelium and venous valves. Increased venous pressure due to occlusion of the vein by the thrombus may become greater than the arterial pressure, compromising blood flow in the affected limb. Long-term valvular dysfunction can cause chronic extremity edema.

 - **What is the most appropriate treatment for this condition?** The treatment of DVT is anticoagulation. IV heparin or low-molecular-weight heparin should be initiated and titrated so that the prothrombin time is 1.5–2 times normal. Warfarin can be started at the same time, but should be bridged with heparin since it takes up to 5 days to reach therapeutic anticoagulation. Of note, there is a brief period of hypercoagulability when beginning warfarin therapy; this is due to the inhibition of anticoagulants protein C and S, which occurs relatively fast compared to inhibition of other vitamin K–dependent coagulation factors. Patients should receive at least 3 months of therapeutic anticoagulation. Additionally, all patients should wear elastic stockings and compression devices for at least 3 months and should begin to ambulate as soon as pain symptoms subside.
-

► **CASE 17**

A 59-year-old man with known benign prostatic hyperplasia (BPH) and a history of nephrolithiasis presents to the emergency department with a 3-day history of fever and flank pain. He always has trouble emptying his bladder but notes that he has had more than his usual urgency and frequency over the past several days. Two days ago he began to have nausea, and he has not been able to keep anything down for the last 24 hours. He takes prazosin and some blood pressure medication, but cannot recall the name of the medication. On physical examination, he has a temperature of 38.5° C (101.3° F), heart rate of 89/min, and respiratory rate of 14/min. Chest exam is unremarkable. His abdomen is soft and nondistended, though he has some discomfort with suprapubic palpation. When his right flank is percussed, he almost jumps off the bed in pain. A CT scan is performed and is shown in Figure 8-2.

CBC: WBC 11,000/mm³, hemoglobin 13 g/dL, platelets 330,000/mm³

UA: nitrites (+), large leukocyte esterase, and moderate blood

BMP: Na⁺ 140, K⁺ 3.7, Cl⁻ 102, CO₂ 24, BUN 25, Cr 1.1

■ What is the most likely diagnosis?	A urinary tract infection is evident by history and on urinalysis. More specifically, he has elements of cystitis (frequency, urgency, suprapubic tenderness) and pyelonephritis (fever, flank tenderness, nausea/vomiting).
■ Why does the urinalysis (UA) detect nitrites and large leukocyte esterase?	Gram negative organisms metabolize the nitrates found in urine to nitrites, which are detected on the UA. Since the most frequent causative organism is <i>Escherichia coli</i> (80%), nitrites are often detected on UA. Leukocyte esterase is, as the name implies, an enzyme produced by neutrophils and is detected in both gram-negative and gram-positive infections as well as any other process that breaks down leukocytes.
■ What are the common radiographic findings in this condition?	If obstruction is involved (severe BPH or nephrolithiasis), hydronephrosis can be seen. Otherwise, parenchymal striations or perinephric stranding are often seen. Given the history of nephrolithiasis in this patient, ruling out the presence of an infected stone is important.
■ What is the most appropriate treatment for this condition?	Optimal treatment involves both immediately treating his infection and then subsequent therapy to decrease the likelihood of recurrence. This patient has evidence of dehydration but not of overt renal failure and should be admitted for IV antibiotics and fluids. Antibiotic coverage must include <i>E. coli</i> and coagulase-negative staphylococci, so a fluoroquinolone would be a good first choice, since it reaches high concentrations in the urinary system and penetrates well into prostatic tissue. Coverage can be altered as cultures and susceptibilities are determined. Isolation of <i>Staphylococcus aureus</i> would be suggestive of a hematogenous source. Recurrence of pyelonephritis can result in permanent damage and scarring to the kidneys, so steps should be taken to minimize that risk. Once the infection clears, this patient would be a candidate for transurethral resection of the prostate or more rigorous medical management. Referral to a urologist should be considered at this point.

Musculoskeletal and Connective Tissue

Case 1	220
Case 2	222
Case 3	223
Case 4	224
Case 5	225
Case 6	226
Case 7	228
Case 8	229
Case 9	230
Case 10	231
Case 11	232
Case 12	234
Case 13	236
Case 14	238
Case 15	240
Case 16	242
Case 17	244
Case 18	245
Case 19	246
Case 20	247

► **CASE 1**

A 27-year-old man presents to an orthopedic surgeon complaining of back pain and stiffness that has progressively worsened over the past 3 years. Initially, the pain was mild and intermittent, but currently it is 6/10 even at rest. The patient is occasionally awakened from sleep by the pain. The stiffness is worst in the morning and improves somewhat with exercise. On examination, the patient has a marked loss of lateral flexion of the lumbar spine and point tenderness over the sacroiliac joints. Radiographs of the patient's lumbar spine are significant for mild erosion and sclerosis of the subchondral bone within the sacroiliac joint. An x-ray of the patient's spine is shown in Figure 9-1. Relevant laboratory findings are a WBC count of $7200/\text{mm}^3$ and erythrocyte sedimentation rate of 113 mm/hr; results for rheumatoid factor are negative, but results for HLA-B27 are positive.

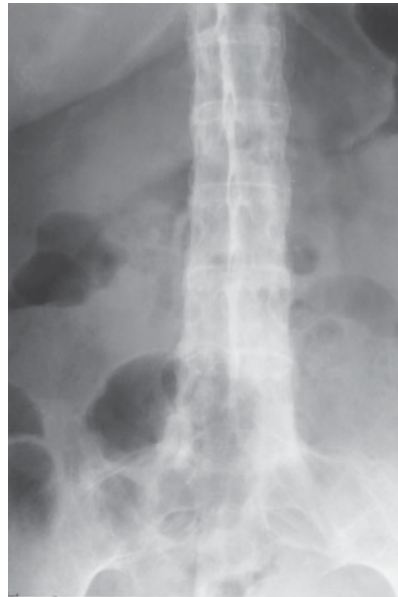


FIGURE 9-1. (Reproduced, with permission, from Chen MYM, Pope TL, Ott DJ. *Basic Radiology*. New York: McGraw-Hill, 2004: Fig. 7-45).

■ **What is the most likely diagnosis?**

Ankylosing spondylitis (AS). AS is a chronic inflammatory disease of the axial skeleton manifested by back pain and progressive stiffness of the spine. It characteristically affects young adults, with a peak age of onset between 20 and 30 years. Although classically thought of as a spinal disease, transient acute arthritis of peripheral joints (hips, shoulders, knees) occurs in up to 50% of patients, and chronic changes occur in 25%. AS affects men four times as often as women. Ninety to 95% of patients with AS have the tissue antigen human leukocyte antigen-B27 (HLA-B27), as compared to 7% of the general population.

- **What is the pathogenesis of this condition?**

AS begins with inflammation centered at entheses, or the bony attachments of tendons, ligaments, and joint capsules. This inflammatory process eventually leads to calcification and ossification at the entheses. Inflammation with cellular infiltration by lymphocytes, plasma cells, and polymorphonuclear leukocytes is associated with erosion and eburnation of the subligamentous bone. This process always involves the sacroiliac joints. In the paravertebral tissues, the lesion manifests as formation of new bone within the outer layers of the annulus fibrosus of the intervertebral disk. The margins of the disk are invaded by hyperemic granulation tissue arising from the subchondral bone. This tissue replaces the disk fibers with new bone, leading to the characteristic “bamboo spine” typically associated with this disease process and clearly seen in Figure 9-1.

- **What conditions should be included in the differential diagnosis?**

- Diffuse idiopathic skeletal hyperostosis (DISH)—while the hyperostotic process in DISH is similar to that in AS, the sacroiliac joints are typically spared. Furthermore, DISH is characterized by nonmarginal syndesmophytes, while AS is characterized by marginal syndesmophytes.
 - Reiter’s syndrome and psoriatic arthritis-like AS—these distinct processes behave or share articular features with AS when associated with HLA-B27. Because of this, the presence of extra-articular manifestations, like uveitis in Reiter’s and rash in psoriatic arthritis, are important in differentiating these disorders from AS.
 - Rheumatoid arthritis—generally easy to differentiate, as it typically affects small joints of the hands initially. There is no association with HLA-B27 in this condition.
 - Spondyloarthropathy associated with inflammatory bowel disease—this may be part of the disease spectrum associated with AS. Many patients do not develop clinical signs or symptoms of inflammatory bowel disease until many years after the onset of the arthropathy.
-

► **CASE 2**

A 50-year-old seamstress presents to her primary care physician with numbness and pain in the thumb, index, and middle finger of her right hand. She reports occasionally being awakened from sleep by the pain, which is relieved by moving her fingers. She notes that the pain comes on when she is holding a piece of cloth for a prolonged period while sewing. She also notes that recently she has had difficulty unscrewing jar tops and holding onto a glass or tea cup after a long day at work. She denies any trauma to her right hand, pain in other joints, fevers, or chills. On physical exam, the paresthesia is reproducible by having her hold her wrist flexed at 90 degrees for 30 seconds. Tapping on her right wrist reproduces the pain.

- | | |
|--|--|
| ■ What is the most likely diagnosis? | Carpal tunnel syndrome (CTS). CTS is caused by compression of the median nerve as it passes through the carpal tunnel. Most common causes are activities requiring repetitive motion of the wrist, trauma to the carpal bones, and flexor tenosynovitis. CTS can also be secondary to systemic illnesses such as rheumatoid arthritis, sarcoidosis, amyloidosis, acromegaly, hypothyroidism, and diabetes. |
| ■ What other symptoms are common in patients with this condition? | Patients with CTS have paresthesias in the median nerve distribution of the hand. Pain in the affected hand is worse at night than during the day and may awaken the patients from sleep. Classically, CTS is not associated with pain or paresthesia on the dorsal aspect of the hand. |
| ■ What tests could be used to confirm the diagnosis? | The Phalen maneuver, Tinel sign, and wrist compression tests are used to establish the diagnosis. A positive Phalen sign is the presence of paresthesias along the median nerve after wrist flexion at 90 degrees for 30 seconds. A positive Tinel sign is pain radiating to the thumb, index, middle, or ring finger when the skin over the median nerve is percussed. The wrist compression test is the reproduction of symptoms after applying pressure over the median nerve proximal to the wrist for 30 seconds. |
| ■ What is the most appropriate treatment for this condition? | Conservative treatments include prescribed rest with a wrist splint and elevation of the hand to reduce swelling and pressure on the median nerve. For temporary relief, steroids can be injected into the carpal tunnel. Patients unresponsive to conservative treatment can undergo surgical division of the flexor retinaculum following confirmatory median nerve conduction testing. |
-

► CASE 3

A 25-year-old man involved in a motor vehicle accident is brought by ambulance to the nearest emergency department for evaluation of multiple cuts, bruises, and a swollen and extremely painful leg. On physical examination, his left leg is slightly cool and is swollen and tense relative to his right leg. He describes feeling “pins and needles” in his toes; he also has extreme difficulty dorsiflexing his left ankle. Dorsalis pedis and posterior tibial pulses are weak. Relevant findings include a temperature of 37° C (99.7° F), a blood pressure of 140/90 mm Hg, and a lateral compartment pressure of 60 mm Hg on compartment manometry of his left leg.

- | | |
|--|--|
| ■ What is the most likely diagnosis? | Compartment syndrome. Given a swollen leg with tense compartments, extreme pain, paresthesias (numbness and tingling), poor pulses, and, most importantly, high compartment pressure, compartment syndrome becomes a likely diagnosis that must be considered, since compartment syndrome is one of the few true orthopedic emergencies. This patient has a crush injury, which places the leg at risk for the development of compartment syndrome. Compartment syndrome should also be suspected when pain is out of proportion to the injury. |
| ■ What are the causes of this condition? | Compartment syndrome occurs when the tissue pressure rises above the perfusion pressure inside a closed anatomic space. Compartment syndrome tends to occur most commonly in the forearm or in the leg. The two most common causes are an externally applied compressive force or an expanding internal force (such as an arterial bleed, overexertion, or a fracture). Regardless of the mechanism, the common end point is ischemia and subsequent reperfusion injury (particularly in cases of vascular injury) to the muscles in the affected compartment. Within 6–10 hours, muscle infarction and necrosis, as well as nerve damage, ensues. |
| ■ What are the signs and symptoms associated with this condition? | Classically, compartment syndrome presents with the “6 P’s”: P ain, P allor, P oikilothermia, P ulselessness, P aresthesia, and P aralysis; however, the best clinical test is pain with passive stretching of the great toe. Though unnecessary for treatment (with high suspicion, patients should undergo immediate surgical intervention), manometry is often used to diagnose compartment syndrome. Normal compartment pressure is about 0 mm Hg. A compartment pressure > 30 mm Hg or a difference of < 30 mm Hg between compartment and diastolic pressures portends ischemic injury. As muscle infarction and necrosis occur, the serum creatine kinase may be elevated in the 1000–5000 U/mL range. |
| ■ What is the most appropriate treatment for this condition? | Emergent fasciotomy is the only proven treatment for acute compartment syndrome. This procedure, in which the fascia enclosing the compartment is opened, allows for relief of the building tissue pressure. In cases in which compartment syndrome is diagnosed very late (3–5 days after symptom onset), the benefit of surgical intervention must be balanced against the increased risk of complications, as deep infection will occur with greater frequency in necrotic muscle. As a general rule, if there is little to no muscular or neurologic function, most surgeons would not perform a fasciotomy in the 3–5-day range. |
-

► **CASE 4**

A 54-year-old woman presents to her primary care physician with muscle weakness and a crusty, scaly rash on her knuckles and over her eyelids. For the past couple of months, she has had difficulty getting out of a chair but attributed it to aging. The rash developed 2 weeks after visiting a self-tanning salon and is extremely pruritic. She has tried taking antihistamines and applying moisturizer to the area but reports no relief. The itching is so severe that it often wakens her at night. She denies fevers, chills, or changes in detergents or creams. She is taking no medication except the antihistamine. On examination, she is afebrile with a heart rate of 70/min, blood pressure of 110/80 mm Hg, and a respiratory rate of 13/min. Notable findings include prominent violaceous papules over the metacarpophalangeal joints of her hands and over her upper eyelids and a rash with a shawl-like distribution over her anterior neck, upper chest, and back. Relevant labs are as follows:

Erythrocyte sedimentation rate: 60 mm/hr

Antinuclear antibody: 1:320

Creatine phosphokinase level: 510 U/L

-
- | | |
|--|---|
| <p>■ What is the most likely diagnosis?</p> | <p>Dermatomyositis (DM). DM is a systemic connective tissue disease leading to proximal muscle weakness with cutaneous findings. The proximal muscle weakness and characteristic distribution of the rash are pathognomonic for DM. Other causes of proximal muscle weakness include motor neuron diseases, muscular dystrophies, rheumatoid arthritis, and polymyositis. However, the characteristic distribution of the rash makes these diseases less likely.</p> |
| <p>■ How do patients with this condition typically present?</p> | <p>DM is a progressive autoimmune connective tissue disease of unknown etiology. Infectious agents such as coxsackie and influenza virus have been suggested as possible triggers of the disease. DM tends to affect individuals > 60 years old, and women are twice as likely as men to be affected. Patients often present with symmetric, progressive proximal muscle weakness leading to difficulty squatting, kneeling, rising from a chair, or climbing stairs. Other characteristic findings are the heliotrope rash (violaceous periorbital rash), a purple-red papular/scaly photosensitive rash distributed in a “v” or “shawl” over the neck and chest, and Gottron’s papules (papules located on the dorsum of the hands and over bony prominences).</p> |
| <p>■ How is this condition diagnosed?</p> | <p>A number of features suggest the diagnosis:</p> <ul style="list-style-type: none">■ Muscle weakness.■ Rash involving dorsal hands, periorbital and neck areas.■ Increased creatine phosphokinase (CPK)/aldolase.■ Muscle biopsy showing T-cell infiltrate with myonecrosis.■ Electromyogram showing muscle irritation with increased spike amplitude.■ MRI, especially of the thigh, showing muscle edema. <p>Positive ANA and elevated levels of serum creatine/aldolase and CPK are usually present. In 50% of patients, ESR will be elevated and in 30% of patients myositis-specific antibodies (anti-jo, anti-mi2, and anti-pm1) will be positive.</p> |
| <p>■ What is the most appropriate treatment for this condition?</p> | <p>High-dose glucocorticoids will increase muscle strength in 4–6 weeks and can be tapered to a lower dose for maintenance therapy. Skin manifestations are difficult to treat and patients are encouraged to avoid sunlight exposure and liberally apply sunscreen. Patients have an increased risk for malignancy and should be closely monitored.</p> |
-

► **CASE 5**

A 4-year-old boy is brought to his pediatrician because he has been having difficulty in preschool with both learning and play activity. In the first 2 years of life, the patient successfully reached many developmental milestones including holding his head up, rolling over, sitting, and standing at the appropriate ages. However, he did not begin to walk until 16 months. By age 2, he was walking with a lordotic posture. The patient had been doing fairly well prior to beginning preschool, but over the past 5 months both the patient's parents and teacher have noticed that he seems to be regressing. In particular, he does not seem to be able to run around with the other kids in his class and has difficulty rising from a seated position. His physical exam is notable for 3/5 strength in the proximal muscles of both the upper and lower extremities. The patient's gastrocnemius muscles appear disproportionately large bilaterally. When lying prone and asked to raise himself to a standing position, the patient has great difficulty and needs to push off with his arms, and then push against his knees and thighs in order to stand. Laboratory examination is significant for an elevated serum creatine kinase level of 27,000 IU/L.

-
- | | |
|---|---|
| ■ What is the most likely diagnosis? | Duchenne's muscular dystrophy (DMD). DMD is the most common childhood-onset muscular dystrophy, with an incidence of 1 in 3500 live male births. Because this disease follows an X-linked pattern of inheritance, it almost exclusively affects males. One-third of these cases are due to spontaneous mutations, while the rest are inherited in an X-linked dominant manner. Gonadal mosaicism accounts for approximately 20% of new DMD cases. |
| ■ What common musculoskeletal signs and symptoms are associated with this condition? | Patients typically present with progressive weakness, most often starting with the muscles of the axial skeleton and the proximal lower extremity. Because of this pattern of involvement, affected children tend to have difficulty with activities such as running, jumping, and walking up steps. When arising from the floor, affected boys use their hands to push themselves to an upright position, a maneuver termed Gower's sign . In addition to these symptoms, patients often exhibit a waddling gait, lordotic curvature of the spine, and pseudohypertrophy of the gastrocnemius muscles. Patients also develop scoliosis secondary to unequal weakening of the paravertebral muscles. Most affected boys present with their first symptoms between the ages of 3 and 7 and are wheelchair bound by the age of 12. |
| ■ What is the pathogenesis of this condition? | DMD results from a deficiency of dystrophin, a protein important to the structural stability of the myofiber. In the absence of dystrophin, proteins responsible for protecting the integrity of the sarcolemma (the muscle cell membrane) are digested by proteases. This change renders the sarcolemma susceptible to breaks and tears during muscle contraction and eventually leads to the progressive weakness experienced by the patient. |
| ■ What other symptoms are common in patients with this condition? | Dystrophin is also found in the heart and the brain, so cardiac fibrosis and/or cardiomyopathy are commonly found. Some patients suffer from varying levels of mental retardation. |
| ■ What are the main causes of mortality in this condition? | Death usually occurs secondary to pulmonary infections and respiratory failure. Fewer than 25% of affected individuals live past the age of 25. |
| ■ What is the most appropriate treatment for this condition? | Supportive care for the patient and his family to help maintain function and optimal quality of life. Corticosteroid therapy has been tried but its benefits may not outweigh the side effects of growth retardation and weight gain. |
-

► **CASE 6**

A 35-year-old man is referred to an orthopedic surgeon for severe back pain radiating to his left leg. He has not been able to play in his weekly basketball game since the pain began 5 weeks ago. During the past 2 weeks, he says the pain has increased in severity and he can only sit for 20 minutes before the shooting pain becomes intolerable. The patient claims that he has had back pain before, but it has never been this severe and has always been well controlled with over-the-counter nonsteroidal anti-inflammatory medications (NSAIDs). Currently, he reports getting no relief from NSAIDs. The pain has begun to affect his ability to sleep, as he wakes up in pain every 1–2 hours. He denies any recent back injury, infection, weight loss, or changes in appetite. The patient appears to have an athletic build and stands throughout the office visit. On physical exam, raising the patient's left leg 30 degrees above the horizontal plane reproduces the pain; this does not occur with his right leg. The patient has no focal lower extremity weakness, but he does have an absent Achilles tendon reflex on the left. An MRI of the lower spine is shown in Figure 9-2.

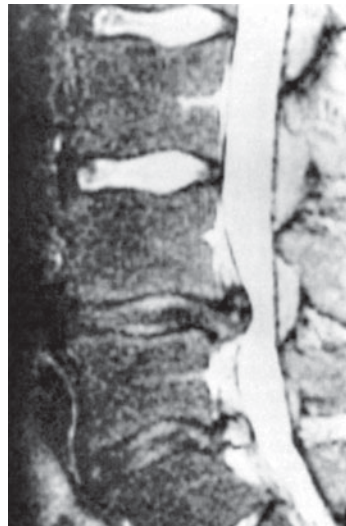

FIGURE 9-2. (Reproduced, with permission, from Skinner HB. *Current Diagnosis & Treatment in Orthopedics*, 3rd ed. New York: McGraw-Hill, 2003: Fig. 5-10.)

■ **What is the pathophysiology of this condition?**

The term *herniated disk* refers to a protrusion of the nucleus pulposus through a weakened area of the surrounding annulus fibrosus of an intervertebral disk. In Figure 9-2, the MRI shows a large posterolateral disk herniation at L5–S1, with compression of the S1 nerve root. In an acute disk herniation, there is often a period of mild back pain that precedes the typical presenting symptoms; this is commonly due to the initial tear in the annulus fibrosus. Because this back pain is mild, most patients do not associate an acute event with their presenting pain. In the weeks following this initial event, the extrusion of the nucleus pulposus can eventually compress the nerve root and produce symptoms such as those seen in this patient.

- | | |
|--|--|
| ■ What other symptoms are common in patients with this condition? | Often, this extrusion will place direct mechanical pressure on an affected spinal nerve root, causing symptoms of radiculopathy, weakness, and sensory deficits. Patients will usually present with back or buttock pain. In addition, most will also have pain radiating down their thigh to their calf. The straight leg raise test, flexion of the thigh with the knee extended, on the affected side, causes stretching of the sciatic nerve which will often exacerbate and/or reproduce the patient's symptoms. |
| ■ What imaging tools could be used to confirm the diagnosis? | The ideal imaging diagnostic modality must be able to detect extrusion of the nucleus pulposus, which is a soft tissue, and visualize the spinal canal and spinal roots. As such, a plain radiograph of the spine is of little use. The historical gold standard was a myelogram, which was later replaced by the development of the CT myelogram of the lumbar spine. The current practice is a spine MRI, which has a high sensitivity and specificity. |
| ■ What is the most appropriate treatment for this condition? | Treatment should start with conservative management, namely bed rest and medications directed at alleviating pain and reducing muscle spasm. NSAIDs, including COX-2 inhibitors, are often successful in relieving pain. In addition, most patients will benefit from sleeping with a pillow under the knees. In patients who fail this initial management after a trial period of 4–6 weeks, epidural injection of steroids can be given to relieve the radicular pain and inflammation. This is often utilized as a temporizing measure to provide the patient with relief in the short to medium term. In general, if these conservative treatments do not relieve pain after 6 weeks, surgical intervention can be pursued. Surgical options include injection therapy, percutaneous discectomy, microsurgical discectomy, and traditional hemilaminectomy with disk excision. |

► **CASE 7**

A 45-year-old man presents to the emergency department complaining of pain and swelling of his great left toe. He reports being awoken from sleep by the pain, which is 9/10 in severity. In addition, his proximal medial foot is swollen and erythematous. The patient denies any history of trauma, recent illness, or intravenous drug abuse. The patient admits that he drinks alcohol heavily on occasion and had 10 or 15 beers 2 days ago while at a party. He is married and has been in a monogamous relationship with his wife for the past 20 years. His past medical history is significant only for mild hypertension, which is well controlled with hydrochlorothiazide. On examination, the patient is clearly in significant distress due to the pain. The patient's metatarsophalangeal joint appears warm, erythematous, edematous, and tender to palpation. The patient's temperature is 38.7° C (101.7° F), and his heart rate is 92/min. Joint fluid analysis reveals a WBC count of 80,000/mm³; results of culture are pending. A Gram stain of joint fluid is negative, but microscopic analysis reveals negatively birefringent needle-shaped crystals.

-
- **What is the most likely diagnosis?** Gouty arthritis. This is a peripheral arthritis that results from the deposition of sodium urate crystals in one or more joints. Podagra, or pain in the first metatarsophalangeal joint, is the classic initial presentation of gout. Gout tends to occur in males more than females, beginning between the ages of 30 and 50. Pseudogout is a similar arthritic crystallopathy marked by **positively** birefringent crystals and should be included in the differential.

 - **What risk factors are associated with an increased incidence of this condition?** Common risk factors for gout include family history of gout, heavy alcohol consumption, lead toxicity, male gender, obesity, older age, renal insufficiency, use of thiazide diuretics

 - **What is the pathogenesis of this condition?** Gout results from hyperuricemia (supersaturation of blood with urate), although only 5% of those with hyperuricemia will develop gout. Primary gout may be due to an inborn error of metabolism (rare) or from defects in renal handling of uric acid. Common causes of secondary gout include renal disease and conditions with increased nucleic acid turnover.

 - **What is the most appropriate treatment for this condition?** The goal of treatment in acute gouty arthritis is prompt alleviation of pain and disability. High-dose nonsteroidal anti-inflammatory drugs (NSAIDs) are the first-line therapy in this setting. Indomethacin is particularly effective. A second option for acute gout is intra-articular or systemic corticosteroids. Candidates for systemic steroids are patients with polyarticular disease who cannot tolerate NSAIDs due to GI, renal, or congestive heart diseases. High-dose colchicine can be used orally for acute gout flares, but its utility is limited by predictable distressing GI side effects. The best use of colchicine is in low daily dosage as prophylaxis against acute gout flares during the first 3–6 months of urate-lowering therapy. Long-term goals for the patient would be cure by reduction and maintenance of urate levels below 6 mg/dL. Urate levels can be lowered by 1–2 mg/dL by diet modification and avoidance of thiazide diuretics, but uricosuric (probenecid) or allopurinol therapy is usually needed to achieve target urate levels in persons with gout.
-

► CASE 8

A 68-year-old woman with a history of depression, anxiety, and irritable bowel syndrome presents to her primary care physician with muscle aches and weakness, joint pain, and fatigue. She reports continued fatigue despite sleeping 10 hours each night. The muscle ache is described as a tight, burning stiffness that spreads across the upper part of her back. The pain is worse in the morning but gradually improves throughout the day. She also reports occasional back pain that radiates down her buttocks to her legs. On examination, her blood pressure is 132/70 mm Hg, pulse is 73/min, and respiratory rate is 12/min. Motor examination of the lower and upper extremities reveals no weakness or decreased range of motion. Her joints are not warm or edematous. Her neurological exam is normal.

-
- | | |
|--|---|
| <ul style="list-style-type: none"> ■ What is the most likely diagnosis? | <p>Fibromyalgia. Fibromyalgia is a connective tissue disorder defined by multiple specific trigger points (≥ 11 of 18) that, when palpated, reproduce the pain. Fibromyalgia is a diagnosis of exclusion, so other diseases such as lumbar degenerative disk disease, hypothyroidism, cervical disk disease, rheumatoid arthritis, and systemic lupus erythematosus (SLE) must be ruled out. Lumbar degenerative disk disease, rheumatoid arthritis, and cervical disk disease can be ruled out with imaging studies such as an MRI. SLE is an autoimmune disease defined by specific criteria and the presence of autoantibodies (ANA, anti-Smith, anti-dsDNA, anti-cardiolipin, and lupus anticoagulant).</p> |
| <ul style="list-style-type: none"> ■ What other symptoms are common in patients with this condition? | <p>Fibromyalgia is characterized by myalgia, weakness, and fatigability in the absence of inflammation. It is associated with conditions such as depression, anxiety, and irritable bowel syndrome and is commonly seen in women > 50 years of age. Patients often describe the pain as widespread or global and shifting in intensity and location. The average patient has seen an average of 15 physicians and endured 5 years of fibromyalgia before receiving the correct diagnosis. Therefore, many patients are frustrated and skeptical.</p> |
| <ul style="list-style-type: none"> ■ What are the criteria required to diagnose this condition? | <p>The diagnostic criteria require the presence of pain in all four quadrants of the body for at least 3 months and at least 11 of 18 anatomically specific tender points. Because fibromyalgia is a diagnosis of exclusion other diseases, as described above, must be ruled out.</p> |
| <ul style="list-style-type: none"> ■ What is the most appropriate treatment for this condition? | <p>Treatment is based on supportive measures such as stretching, other therapeutic exercises, massages, and simple analgesics. Reassurance of the benign nature of the disease, patient education, stress reduction, psychotherapy, and low dose antidepressants can also help in the alleviation of symptoms.</p> |
-

► **CASE 9**

A 4-year-old girl is brought to her pediatrician by her parents because they are concerned about her right knee. For the past several months, the patient's right knee has been swollen and she often limps. Her parents note that sometimes she does not want to walk in the morning, but seems fine later in the day. The patient's past medical history is unremarkable. On physical examine, there appears to be a large effusion of the right knee but no erythema, increased warmth, or tenderness to palpation or range of motion testing. The right knee has a passive range of motion of 15–120 degrees. Relevant laboratory findings are as follows:

WBC count: 8.6/mm³ (45% polymorphonuclear cells, 47% lymphocytes, 8% monocytes)

RBC count: 12,000/mm³

Erythrocyte sedimentation rate: 20 mm/hr

Urinalysis: normal

Rheumatoid factor: negative

Antinuclear antibody titer: 1:640

■ What is the most likely diagnosis?	Juvenile rheumatoid arthritis (JRA). JRA is a disease or group of diseases characterized by chronic joint inflammation. JRA affects approximately 10–20 per 100,000 children. Whereas both sexes are affected equally in systemic JRA, females are affected more frequently in pauciarticular JRA. Most children develop symptoms in early childhood, and approximately 95% of cases resolve by puberty. Because JRA is a diagnosis of exclusion, it is important to rule out infection and malignancy.
■ What is the pathogenesis of this condition?	The etiology of JRA is unknown. It is thought that the chronic inflammation of the joint is caused by B lymphocytic infiltration and expansion and increased cytokine release by macrophages and T cells.
■ What tests and/or imaging tools could be used to confirm the diagnosis?	There is no specific diagnostic test for JRA. Rheumatoid factor and antinuclear antibody can occasionally be positive in JRA. A positive ANA or HLA-B27 increases the risk of uveitis. Synovial biopsy may be helpful in demonstrating synovial infiltration with plasma cells, mature B lymphocytes, and T lymphocytes, with areas of synovial thickening and fibrosis.
■ What is the most appropriate treatment for this condition?	Nonsteroidal anti-inflammatory drugs (NSAIDs) are the first-line therapy in the treatment of JRA. While NSAIDs are effective in the treatment of pauciarticular JRA, NSAIDs alone are rarely effective in the treatment of polyarticular or systemic JRA. In patients in whom NSAIDs are ineffective, glucocorticoids can be given either orally or intravenously. In cases refractory to steroids, immunosuppressive agents such as methotrexate or TNF- α -receptor antagonists are sometimes effective. In addition, patients can benefit from a rigorous physical therapy regimen focused on strength training and maintaining or improving the range of motion of affected joints.

► CASE 10

A 9-year-old boy is referred to a pediatric sports medicine physician due to a history of intermittent pain in his right hip. The pain began during a soccer game 6 months ago and has increased in severity over this time. Although he has tried activity restriction and crutches, the right hip continues to bother him, especially with any activity. He had an uncomplicated birth and a past medical history negative for trauma or significant illness. He has no family history of similar complaints or disability. On physical examination, the patient is a healthy well-nourished boy who is at the 50th percentile for both height and weight for his age. He is afebrile and has stable vital signs. He walks with an antalgic gait. There are no obvious deformities of either lower extremity. However, he has marked discomfort to palpation over the entire right hip region, and internal rotation and hip abduction cause significant pain. When compared with the opposite side, the right hip has decreased range of motion noted in abduction, internal rotation, and flexion. A full laboratory workup was within normal limits. An x-ray of the affected right hip demonstrates a “moth-eaten” radiolucency suggestive of osteopenia of the femoral epiphysis and neck with a shortened femoral epiphysis. A bone scan of the lower extremities demonstrates evidence of avascularity of the right femoral epiphysis.

-
- | | |
|--|--|
| <ul style="list-style-type: none"> ■ What conditions should be considered in the differential diagnosis? | <p>The differential diagnosis of limp in the pediatric population is substantial and includes Legg-Calvé-Perthes disease (LCPD), toxic synovitis, rheumatoid arthritis, and septic (including tuberculous) arthritis. The x-ray findings of epiphyseal abnormalities seen in LCPD can also be seen in Gaucher’s disease, and hypothyroidism. Avascular necrosis seen in LCPD can also be secondary to sickle cell anemia, trauma, or chronic corticosteroid use.</p> |
| <ul style="list-style-type: none"> ■ What is the most likely diagnosis? | <p>LCPD. The combination of history, physical examination and radiological testing makes LCPD the most likely diagnosis. LCPD is a relatively uncommon hip condition affecting 1 in 2000 children. Boys are affected five times as often as girls, and the disease presents most often between 4–10 years of age. The hallmark of this disease is avascular necrosis of the capital femoral epiphysis, which often leads to abnormal hip joint development and/or permanent deformity of the femoral head.</p> |
| <ul style="list-style-type: none"> ■ What is the prognosis for patients with this condition? | <p>Fifty percent of cases do well with conservative (nonoperative treatment). Age is the key to the prognosis:</p> <ul style="list-style-type: none"> ■ < 6 years old: outcome is almost always good regardless of treatment. ■ 6–8 years old: many do well with bracing, some require surgical treatment. ■ > 9 years old and those with severe deformity: most will benefit from surgical treatment such as femoral osteotomy. |
-

► **CASE 11**

A 13-year-old boy presents to the orthopedic surgeon with progressively worsening right leg pain of 6 weeks' duration. The patient says the pain began after being tackled in a football game 6 weeks ago. Since then, the pain has not improved despite ample rest, ice therapy, and ibuprofen. The pain also increases with activity. In addition, he noted a lump behind his knee after the game that has not resolved. On physical examination, there is a small but palpable mass in the popliteal region of the patient's right leg. In addition, there is a slight decrease in passive range of motion in the patient's right knee when compared to the left. The patient has full strength in all extremities and exhibits no neurological deficits. Plain anteroposterior and lateral radiographs of the patient's right knee reveal a large lesion with osteoblastic and osteolytic changes. On the posterior aspect of the supracondylar region of the femur, there is a prominent elevation of the periosteum.

-
- | | |
|---|--|
| <p>■ What is the most likely diagnosis?</p> | <p>Osteosarcoma, a primary malignant tumor of bone in which the malignant cells produce osteoid or immature bone. Osteosarcoma is the third most common cancer in adolescence, behind lymphomas and brain tumors. This condition is more common in boys than in girls and has a higher incidence in African Americans. Most cases are diagnosed in children between the ages of 5 and 20 years old, but this disease has a bimodal distribution, with a second peak after 65 years of age. Osteosarcoma can arise from any bone but has a predilection for the long bones of the extremities near the metaphyseal growth plates.</p> |
| <p>■ What risk factors are associated with an increased incidence of this condition?</p> | <p>Risk factors include rapid bone growth (most cases occur during adolescence at peak linear growth) and radiation exposure. There are a number of genetic syndromes, including Li-Fraumeni syndrome (germline <i>TP53</i> mutation) and Rothmund-Thomson syndrome, that predispose patients to osteosarcoma. In addition, there are bone conditions such as Paget's disease, fibrous dysplasia, enchondromatosis, and hereditary multiple exostoses, which increase a patient's risk of developing osteosarcoma.</p> |
| <p>■ What are the typical radiographic findings in this condition?</p> | <p>Classical findings on plain film are a destructive lesion with a moth-eaten appearance, a spiculated periosteal reaction (sunburst pattern), and elevation of the periosteum due to new bone formation (Codman's triangle) (see Figure 9-3). Thirty-five percent of plain radiographs show a purely osteolytic lesion, 45% show a purely osteoblastic lesion, and 20% show a mixed lesion. The entire bone and adjacent joint should be imaged for skip lesions and joint involvement. A bone biopsy is necessary for diagnosis.</p> |
| <p>■ What is the most appropriate treatment for this condition?</p> | <p>Surgical resection of the primary lesion is the only definitive treatment. Preoperative (neoadjuvant) chemotherapy can be used to shrink the tumor and improve the success of resecting the tumor. Limb amputation is typically the procedure of choice but a less radical resection is possible if the surgical margins are determined to be tumor free by frozen section analysis.</p> |
-

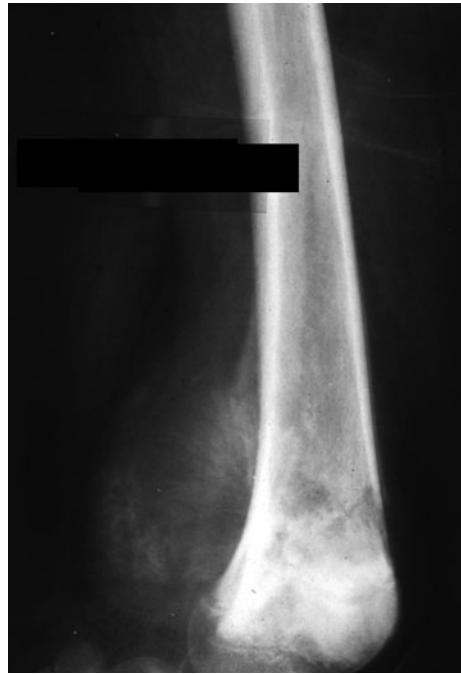

FIGURE 9-3. Prominent Codman's triangle and sunburst appearance.
(Reproduced, with permission, from the Pathology Education Instructional Resource Digital Library [<http://peir.net>] at the University of Alabama, Birmingham.)

► **CASE 12**

A 35-year-old woman presents to her primary care physician with a 6-week history of hand stiffness, swelling, and pain. The stiffness is worst in the morning, taking up to an hour to become “more manageable.” Upon further questioning, the patient admits that she has been having some pain in her knees as well over the past 6 months but thought that it was related to inactivity. The patient denies any fevers, rashes, or recent illness. She is currently in a stable relationship, and both she and her partner were recently tested and found to be negative for sexually transmitted diseases. She denies any decreased sensation or color changes in her fingers during exposure to the cold. The patient notes that her grandmother had “arthritis” but does not recall the details. Her physical examination is significant for mild swelling and tenderness over the metacarpophalangeal (MCP) joints of both hands. Her knees also have slight warmth and small effusions bilaterally but no point tenderness or loss of range of motion. The patient has no rashes or mouth ulcers. Her lungs are clear, and her heart has a regular rate and rhythm. Relevant laboratory findings are as follows:

WBC count: 8200/mm³

Erythrocyte sedimentation rate: 50 mm/hr

C-reactive protein: 2 mg/L

Antinuclear antibody: negative

Rheumatoid factor (RF): highly positive

Radiographs of the wrist reveal soft tissue swelling and slight osteopenia. Radiographs of the knees are normal. An MRI of the wrists shows erosions of the MCP joints bilaterally.

■ What is the most likely diagnosis?	Rheumatoid arthritis (RA). Her relatively young age, gender (females are affected most often), family history, symmetrical nature of her symptoms, and the related negative findings make RA most likely. While this patient’s presenting symptoms and signs do not rule out other systemic autoimmune processes such as systemic lupus erythematosus (SLE), the lack of classic SLE findings (e.g., malar rash, oral ulcers, and pleuritis) point to RA.
■ What are the defining features of this condition?	A patient must have four of the following seven signs and symptoms to be diagnosed with RA. The first four criteria must be present for at least 6 weeks and the last three must be observed by a physician. <ul style="list-style-type: none">■ Erosions and/or periarticular osteopenia seen on radiographs in hand or wrist joints.■ Morning stiffness (at least 1 hour).■ Serum rheumatoid factor.■ Subcutaneous nodules.■ Swelling of hand joints (proximal interphalangeal [PIP], MCP, or wrist).■ Swelling of three or more joints.■ Symmetrical soft tissue swelling about the joints.
■ What is the mechanism of arthritic degeneration in this condition?	RA is caused by an autoimmune-mediated inflammatory response in which T cells and macrophages invade the synovial lining of the joints. The release of inflammatory cytokines leads to the formation of a pannus, which invades and destroys adjacent bone and cartilage. The MCP and PIP joints are most often involved. Common findings include ulnar deviation of the wrist, swan-neck deformities (hyperextension of the PIP joint), and/or boutonnière deformities (hyperflexion of the PIPs) of the fingers (see Figure 9-4).

- **What is the most appropriate treatment for this condition?**

The goal of treatment is halting the progression of the disease and symptom management and should be started as early as possible. Most patients are treated with a combination of NSAIDs, corticosteroids, and a disease-modifying antirheumatic drug (DMARD). Examples of common DMARDs include methotrexate, TNF- α antagonists, and interleukin-1 antagonists.



FIGURE 9-4. Deformities including marked ulnar deviation, swan-neck deformity, active synovitis, and nodules. (Reproduced, with permission, from Brunickardi FC, Andersen DK, Billiar TR, Dunn DL, Hunter JG, Matthews JB, Pollock RE, Schwartz SI. *Schwartz's Principles of Surgery*, 8th ed. New York: McGraw-Hill, 2005: Fig. 43-115.)

► **CASE 13**

A 50-year-old woman presents to her primary care physician with cold and painful fingers. In addition to the pain, she has a lump on the dorsal aspect of her proximal carpophalangeal joint. Since her teenage years, she has always had difficulty keeping her hands warm and was diagnosed with Raynaud's phenomenon 5 years ago. Her past medical history is significant for acid reflux, dysphagia, and stomach ulcers. She also has a long history of joint pains, and was previously given a diagnosis of fibromyalgia. The appearance of the patient's hands is shown in Figure 9-5. Radiographs of the hands reveal no arthritic changes but demonstrate a large calcium deposit that corresponds to the lump felt by the patient. Relevant laboratory findings are as follows:

WBC count: 11,000/mm³
Hemoglobin: 10 g/dL
Antinuclear antibody titer: 1:320
Anti-Scl 70 antibody: 27.01 U/mL

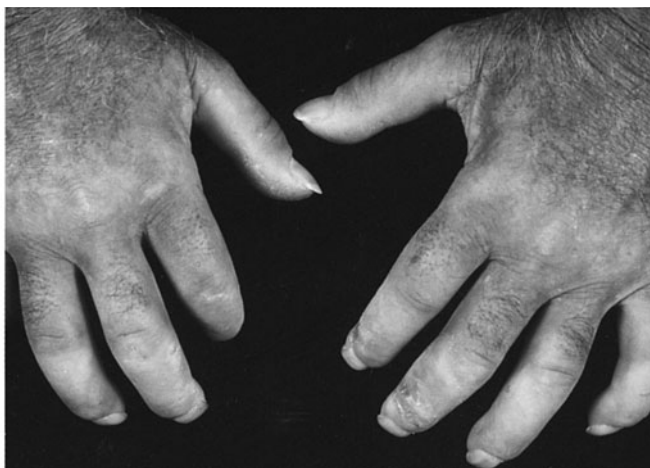

FIGURE 9-5. (Reproduced, with permission, from Kasper DL, Braunwald E, Fauci AS, Hauser SL, Longo DL, Jameson JL, Isselbacher J, et al. *Harrison's Principles of Internal Medicine*, 16th ed. New York: McGraw-Hill, 2005: Fig. 49-7).

-
- **What is the most likely diagnosis?** Scleroderma. This disease most commonly affects women ages 30–50 years and has a prevalence of 240 cases per million. Both physical findings and laboratory tests are used to diagnose scleroderma. In scleroderma patients, antinuclear antibody (ANA) is positive in > 95% of patients. Anticentromere antibodies are positive in 20–40% of patients and are associated with the CREST variation. Antitopoisomerase I (anti-scl-70) is found in 20–40% of patients and is associated with diffuse disease.
-
- **What is the pathogenesis of this condition?** Scleroderma is caused by excessive production and deposition of type I and type III collagen by fibroblasts, leading to tissue fibrosis and occlusion of the microvasculature. While the etiology of scleroderma is unknown, studies point to a combination of environmental risk factors (e.g., viruses or toxin exposure) and genetic factors (MHC haplotypes DQ7 and DR2) as predisposing risk factors.
-

■ **How is this condition classified?**

Major criterion:

- Sclerodactyly and skin changes (as seen in Figure 9-5) that may affect the entire extremity, face, neck, and trunk.
- Minor criteria:
 - Sclerodactyly limited to the fingers
 - Digital pitting scars
 - Bibasilar pulmonary fibrosis

Scleroderma is further classified based on the extent of involvement: Localized scleroderma is a cutaneous disease, while systemic sclerosis requires the involvement of internal organs. The most common limited type is **CREST syndrome**, which consists of **C**alcinosis, **R**aynaud's phenomenon, **E**sophageal dysmotility, **S**clerodactyly, and **T**elangiectasias.

■ **What is the most appropriate treatment for this condition?**

- Arthralgias: acetaminophen or NSAIDs.
 - Myositis: glucocorticoids (first choice), methotrexate, and azathioprine.
 - Pruritus: moisturizers, histamine₁ (H₁)- and histamine₂ (H₂)-blockers, tricyclic antidepressants.
 - Pulmonary fibrosis: cyclophosphamide.
 - Raynaud's phenomenon: calcium channel blockers, prazosin, reserpine, or topical nitrates; cervical sympathectomy is reserved for severe cases.
 - Renal hypertension: angiotensin-converting enzyme inhibitors.
 - Skin changes: D-penicillamine or methotrexate.
-

► **CASE 14**

A 72-year-old man presents to his primary care physician complaining of progressively worsening exercise intolerance. He states that he has always been active, but over the past 3 years he has been having more and more pain while walking. On walking four or five blocks, he begins to experience discomfort in his lower back as well as numbness and tingling that radiates down the back of his thighs and calves. The patient states that these symptoms persist until he sits down and rests for awhile. Past medical history is significant for hypertension for which he takes losartan. On examination, his blood pressure is 132/70 mm Hg, pulse is 73/min, and respiratory rate is 12/min. Motor examination of the lower extremities reveals no weakness, but the patient has decreased sensation to light touch in the S1 distribution, and his Achilles reflexes are diminished bilaterally. Posterior tibial and dorsalis pedis pulses are 2+, and a straight leg raise test (Lasègue's sign) is negative bilaterally.

- **What conditions should be considered in the differential diagnosis?**

This patient is exhibiting signs and symptoms of claudication, which can be vasculogenic or neurogenic. Most patients develop vasculogenic claudication secondary to atherosclerosis and peripheral artery disease. Neurogenic claudication is typically caused by degenerative spinal stenosis. Other causes include vasculitis, popliteal entrapment syndrome, and radiation fibrosis.

- **What is the most likely diagnosis?**

Neurogenic claudication due to degenerative spinal stenosis. Because peripheral vascular disease and spinal stenosis are both common in this age group, it is important that any patient presenting with claudication be worked up for both conditions. With normal peripheral pulses, this patient is unlikely to have peripheral vascular disease significant enough to cause his presenting symptoms. While most cases of spinal stenosis are due to degenerative disease, other serious processes such as a bone or nerve tumor, infection, or vertebral fracture must be considered. Diagnostic imaging can help to establish the diagnosis.

- **How is this condition distinguished clinically from other conditions with a similar presentation?**

Neurogenic claudication must be differentiated from vascular claudication, as both are common and present similarly. Vascular claudication is associated with peripheral vascular disease and, unlike neurogenic claudication, is marked by decreased or absent peripheral pulses, arterial bruits, foot pallor, and cyanosis. Vascular claudication is typically experienced after ambulating a certain distance and is relieved by rest, even in the upright position. Other symptoms such as impotence and dystrophic skin changes are often seen. In contrast, neurogenic claudication is associated with nerve impingement that occurs with prolonged upright posture. As in vascular claudication, ambulation can exacerbate these symptoms, but the key difference is that relief occurs with squatting, bending forward, or sitting rather than by simply resting.

- **What is the most appropriate treatment for this condition?**

X-ray of the lumbar spine will exhibit signs of degenerative disease. MRI and/or CT scan of the lumbar spine can demonstrate the stenotic spinal canal. Treatment should always begin with a trial of conservative therapy, including analgesics and physical therapy. Long-term use of NSAIDs is relatively contraindicated in those > 65 years of age. If symptoms do not improve, epidural corticosteroid injections will often help to provide symptomatic relief. Surgical therapy is reserved for patients with refractory symptoms or with signs of rapidly progressing disease. Cauda equina syndrome (loss of bowel/bladder function, saddle anesthesia, present Babinski's sign) is an emergency requiring immediate surgical intervention.

► **CASE 15**

A 23-year-old woman presents to her primary care physician with complaints of malaise, fever of 10 days' duration, and swelling in her ankles and knees. She also has been having chest pain, which is particularly painful on inspiration and expiration. On questioning, the young woman states that she has always been healthy. She has not had any recent sick contacts and has been in a monogamous relationship for the past 3 years. Of note, her mother has Raynaud's disease. On examination, the patient is found to have no skin lesions or muscle tenderness. Her temperature is 38.1° C (100.6° F). She has a pleural friction rub and significant effusions around her ankles, knees, and hands bilaterally. She also has palpable cervical and inguinal lymph nodes. Radiography of her knees shows significant soft tissue swelling. Relevant laboratory findings are as follows:

WBC count: 11,000/mm³

Hemoglobin: 9.8 g/dL

Erythrocyte sedimentation rate: 80 mm/hr

Rheumatoid factor: negative

Antinuclear antibody: positive (titer 1:160)

Anti-dsDNA antibody: positive (titer 1:320)

Anti-Sm antibody: negative

VDRL test: positive

Urinalysis: positive white cells, red cells, red cell casts; 4+ proteinuria

-
- | | |
|--|---|
| ■ What is the most likely diagnosis? | Systemic lupus erythematosus (SLE). SLE is a chronic, multisystem autoimmune inflammatory disease of unknown etiology that typically affects the skin, joints, kidneys, lungs, nervous system, serous membranes, and/or other organs of the body. The clinical course of SLE is variable and may be characterized by periods of remissions and chronic or acute relapses. Ninety percent of cases occur in women, especially young African-American women in their 20s and 30s. |
| <hr/> | |
| ■ What other symptoms are common in patients with this condition? | Patients often present with nonspecific constitutional symptoms such as headache, fever, and anorexia. Joint pain and swelling occur early and are typically bilateral. The pain is commonly out of proportion to the physical findings. Other typical presenting signs and symptoms include a photosensitive malar butterfly rash over the cheeks and nose and ulcers of the mouth. |
-

■ **What are the signs and symptoms of this condition?**

Patients who meet at least four of these criteria are likely to have SLE (recall the mnemonic **DOPAMINE RASH**):

Discoid rash.

Oral ulcers.

Photosensitivity.

Arthritis.

Malar rash.

Immunologic (anti-DNA, -Smith, or -phospholipid antibodies; false-positive VDRL).

Neurologic symptoms (lupus cerebritis, seizures, headache).

Elevated erythrocyte sedimentation rate (ESR; not part of the American College of Rheumatology criteria for lupus).

Renal disease.

ANA positive.

Serositis.

Hematologic abnormalities.

Serologic testing plays an important role in diagnosing SLE. The antinuclear antibody (ANA) test is the best diagnostic test for SLE and is positive (titer of $\geq 1:160$) in almost all SLE patients. However, a positive ANA has a low specificity and positive predictive value because it may be positive in many other diseases. Other important autoantibodies associated with SLE are anti-double-stranded DNA (dsDNA) and anti-Smith antibodies, which have a lower sensitivity than ANA (66–90%) but have a high specificity (80–100%) and positive predictive value (89–100%).

■ **What is the most appropriate treatment for this condition?**

- Antimalarials are useful for skin manifestations and for musculoskeletal complaints that do not adequately respond to NSAIDs. They may also protect against organ involvement and are now advised for most, if not all, patients with lupus.
- Immunosuppressive drugs are used in combination with glucocorticoids for treatment of advanced lupus with significant systemic involvement, as in this patient with glomerulonephritis.
- NSAIDs are the treatment of choice for mild musculoskeletal complaints and mild serositis.
- Systemic corticosteroids are reserved for acute exacerbations and for patients with significant organ system involvement, particularly renal and central nervous system disease.

► **CASE 16**

A 13-year-old boy presents to the orthopedic surgeon's office because of right knee pain of 8 months' duration. The pain is deep and achy and is concentrated on the medial side of the knee. Occasionally, the knee buckles while the patient is walking. Until recently, the patient was able to engage in physical activity, but the pain is too severe now. He has no history of trauma or injury and denies numbness, paresthesias, or weakness in his right leg. He also denies fevers, chills, or recent illnesses. On physical examination, he is an obese, young African-American boy in no apparent distress. The patient's right knee appears atraumatic on inspection, with no obvious inflammation or effusion. The right knee is nontender to palpation. Examination of the hips revealed no tenderness but is significant for increased passive external rotation and decreased passive internal rotation of the right hip compared to the left. Anteroposterior and lateral radiographs of the patient's right knee are normal. Lateral radiographs of the patient's right hip is shown in Figure 9-6.

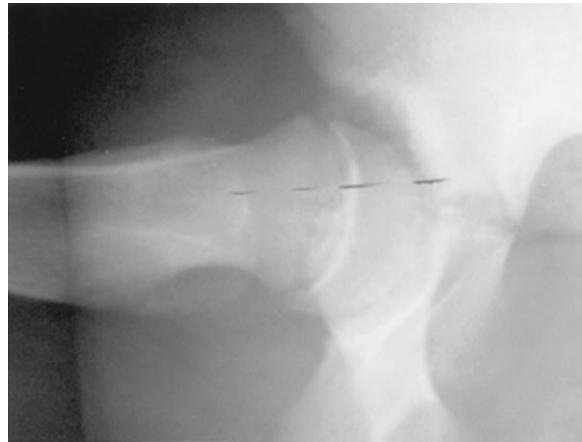


FIGURE 9-6. (Reproduced, with permission, from Brunnicardi FC, Andersen DK, Billiar TR, Dunn DL, Hunter JG, Matthews JB, Pollock RE, Schwartz SI. *Schwartz's Principles of Surgery*, 8th ed. New York: McGraw-Hill, 2005: Fig. 42-82.)

-
- **What is the most likely diagnosis?** Slipped capital femoral epiphysis (SCFE). SCFE is caused by the displacement of the capital femoral epiphysis from the femoral neck through the growth plate. It is one of the most common hip disorders of adolescence and tends to occur during the time of peak linear growth. Males are more affected than females with a ratio of 1.5:1. Obesity is the most significant risk factor, with 60% of all those affected measuring in the 90th percentile for weight (adjusted for age and sex). Other risk factors include African-American ethnicity, hypothyroidism, growth hormone deficiency, and Down syndrome. Approximately 15% of patients present with isolated thigh or knee pain, so physicians must have a high degree of suspicion to prevent a delay in diagnosis, which can worsen the prognosis.
-

- | | |
|--|---|
| ■ What symptoms are common in patients with this condition? | The two most common presenting features of SCFE are pain and antalgic gait. Pain is typically localized to the groin, hip, thigh, and/or knee and is described as dull, deep, and difficult to localize by palpation. The pain is often exacerbated by activity. There is usually no preceding history of trauma. In patients who present with knee or thigh pain, examination of these anatomical areas is typically unremarkable, as pain experienced by the patient is usually referred from the affected hip. |
| ■ What tests and/or imaging tools could be used to confirm the diagnosis? | Most cases of SCFE can be diagnosed using plain radiographs of the hip. At a minimum, anteroposterior (AP) and lateral views of the hips should be taken. Bilateral views are preferable because (1) SCFE often affects both hips, and (2) the contralateral hip serves as a point of comparison. Findings associated with SCFE on the AP view include widening, lucency, and irregularity of the growth plate. In the normal AP view, a line drawn along the superior femoral neck (Klein's line; as in Figure 9-6) intersects the lateral portion of the femoral head. In a patient with SCFE, the line passes outside of the epiphysis or just at its superior edge. |
| ■ What is the most appropriate treatment for this condition? | Patients with acute SCFE should be hospitalized and put on bed rest prior to definitive treatment. Treatment is focused on stabilization of the epiphysis to prevent further slippage. The gold standard treatment is pinning of the epiphysis to the femoral neck. |

► **CASE 17**

A 65-year-old woman is referred to an orthopedic surgeon by her primary care physician for evaluation of right knee pain. Just 10 years ago, she was a competitive marathon runner, but over the past 5 years the aches and pains in her joints have gradually begun to limit her physical activity. The patient reports that she can walk only “about a half mile” before the pain in her knee forces her to stop and rest. On examination, her right knee has a moderate effusion but is not warm or erythematous. She has decreased range of motion in her right knee relative to her left. Radiographs of the right knee show osteophyte formation, subchondral bone cysts, and narrowing of the joint space. The patient’s leukocyte count is 6000/mm³ and erythrocyte sedimentation rate is 8 mm/hr.

- **What is the most likely diagnosis?** Osteoarthritis (OA). OA is a chronic, noninflammatory, degenerative process that affects the articular cartilage surfaces of the affected joint(s). Because it is a mechanical wear and tear process, osteoarthritis tends to affect the weight-bearing surfaces, especially the hips, knees, and spine. This patient has classical findings of advanced age, slow onset of symptoms, pain worse with exertion, and decreased range of motion of the affected joint. Osteoarthritis also tends to be an asymmetric process, affecting one joint more than its counterpart, while rheumatoid arthritis tends to affect joints symmetrically. Primary osteoarthritis is the most common cause of arthritis, with up to 80% of people exhibiting some evidence of osteoarthritic changes by age 65.

 - **What are the typical radiographic findings in this condition?** Radiographs of the knees tend to show changes related to mechanical degeneration at the surface of the affected joint. Common findings include joint space loss or narrowing, subchondral body sclerosis (a reaction of the bone to increased bone-on-bone pressure caused by loss of cartilage), and bone cyst formation. Bony osteophytes or bony outgrowths on the margins of the joint surface are often seen as the degenerative process continues. In the knee, the medial side tends to bear more weight than the lateral side; thus, more degeneration is typically seen medially.

 - **What is the most appropriate treatment for this condition?** Conservative treatment should be the first intervention and should focus on pain management and slowing the progression of the disease. Such treatment includes the use of acetaminophen or NSAIDs for analgesia, activity modification (i.e., limiting activities that aggravate symptoms the most), and the use of braces. Intra-articular steroid injections are of little benefit as this is not a condition marked or caused by inflammation. In general, definitive intervention is surgical and is attempted only after conservative treatment has failed. In such cases, joint arthroplasty is often successful at both alleviating the pain associated with this disease and restoring function lost due to deterioration of the affected joint surfaces.
-

► CASE 18

A 23-year-old Asian-American woman presents to her primary care physician with cold hands and increasingly frequent episodes of headaches and lightheadedness. She reports that the coldness in her hands is associated with numbness, tingling, and loss of sensation in her arms. Two days ago, while reading a book at her desk, she reported seeing flashing lights followed by a loss of vision that lasted for about 15 seconds. She denies head trauma, fever, night sweats, chills, or weight loss. She is not taking any medications except for an occasional acetaminophen for her headaches. On physical exam, her temperature is 39° C (100.5° F), pulse is 65/min, blood pressure is 140/90 mm Hg, and respiratory rate is 12/min. She has carotid bruits and faint pulses in her arms bilaterally. Her hands are cold, with cyanotic nail beds. Her lungs are clear, and her heart has a regular rate and rhythm. Abdominal examination is unremarkable.

- | | |
|--|---|
| ■ What is the most likely diagnosis? | Takayasu's arteritis (TA). TA is a chronic inflammatory disease of medium and large arteries that usually affects the aorta and its branches. It is found commonly in young women of Asian descent. Other diseases to consider include carotid artery disease, Buerger's disease, and fibromuscular dysplasia. Buerger's disease is found almost exclusively in smokers and males less than 40 years of age. Fibromuscular dysplasia is a hyperplastic arterial disease that affects medium and small arteries, generally the renal or carotid arteries, and can present similarly to TA. |
| ■ What other symptoms are common in patients with this condition? | Patients generally present with arm claudication, Raynaud's phenomenon, and constitutional symptoms (fever, arthralgias, weight loss). Clinical suspicion for TA should be high in a young woman with carotid or clavicular bruits, asymmetric upper-extremity blood pressure measurements, hypertension, and faint or absent peripheral pulses. |
| ■ What tests and/or imaging tools could be used to confirm the diagnosis? | TA is confirmed by arteriography showing irregular vessel walls and narrowing or occlusion of the aorta. MR arteriography can also be helpful in delineating the degree and distribution of arterial disease and is less invasive. |
| ■ What is the most appropriate treatment for this condition? | High-dose steroids are the first-line therapy used to suppress the inflammatory process of TA, and aggressive treatment is needed to prevent strokes. Disease refractory to glucocorticoid therapy can be treated with methotrexate or cyclophosphamide. |
-

► CASE 19

A 65-year-old woman presents to her primary care physician with a severe headache that has persisted for 2 weeks despite therapy with ibuprofen. The headache is localized over the right temporal region. She is particularly worried since she rarely suffers from headaches. The patient also notes that she has been experiencing discomfort while attempting to eat over the past few days. She reports no history of trauma and denies fever, night sweats, or chills; weight loss; photophobia; and visual disturbances. She is taking no medication except for ibuprofen, which she has been taking for 1 year to treat what she describes as arthritis of the neck, shoulders, and elbows. The patient's temperature is 38° C (100.4° F), pulse is 90/min, blood pressure is 120/75 mm Hg, and respiratory rate is 12/min. On palpation of the patient's right temporal region, there is noticeable throbbing and tenderness but no signs of trauma to the head. Ophthalmologic examination reveals equally round and reactive pupils and no papilledema. Her chest is clear, and her heart has a normal rate and regular rhythm. Abdominal examination is unremarkable. Relevant labs include the following:

ESR: 100 mm/hr
CRP: 3.0 mg/dL
MCV: 85 fl
Hemoglobin: 9.0 g/dL
Platelet count: 500,000/L

-
- | | |
|--|---|
| ■ What is the most likely diagnosis? | Temporal arteritis (TA), also known as giant cell arteritis. The onset of a new and severe headache in an older adult requires immediate evaluation for TA, because untreated TA can lead to permanent vision loss stemming from occlusion of the ophthalmic artery. Other secondary causes of unilateral headaches are migranes, cluster headaches, trauma, and infection. |
| ■ What is the pathophysiology of this condition? | Temporal arteritis is an inflammatory vasculitis that affects the medium-sized arteries. It tends to occur in individuals > 60 years old, and affects females more often than males. TA can be associated with: <ul style="list-style-type: none">■ Cherry red spot due to central retinal infarction (late finding).■ Decreased visual acuity.■ Elevated liver function tests.■ Orbital or frontotemporal head pain.■ Pain in the jaw or tongue while chewing.■ Pale and/or swollen optic disks (late finding).■ Retinal splinter hemorrhage (late finding). |
| ■ What tests and/or imaging tools could be used to confirm the diagnosis? | The gold standard for diagnosis is a temporal artery biopsy. However, 20–30% of biopsies will be falsely negative due to the segmental nature of the disease. In patients in whom there is a high index of suspicion, treatment should not be delayed for biopsy results. An elevated erythrocyte sedimentation rate (ESR) and C-reactive protein (CRP) and abnormal blood count can help support the diagnosis. Up to half of all patients will have a normocytic, normochromic anemia and a thrombocytosis. In addition, 33% of patients will have an elevated alkaline phosphatase on liver function tests. |
| ■ What is the most appropriate treatment for this condition? | TA is highly responsive to high-dose corticosteroids (60–80 mg prednisone per day). Typically, steroids given for 2–3 weeks will produce a dramatic improvement in symptoms, and improvements can be seen within the first few days of treatment. For patients with evidence of advanced TA (fixed visual loss and cherry red spot), intravenous steroids should be given for the first 3 days before switching to oral steroids. |
-

► **CASE 20**

A 66-year-old woman presents to the rheumatologist's office complaining of muscle aching, weakness in her upper arms and thighs, and severe fatigue. She also notes an unintentional weight loss of 2.3 kg (5 lb) over the past 6 months. The patient's symptoms are most severe in the morning and so debilitating that she can barely get dressed. The patient denies any history of trauma or arthritis. She also denies fevers, headache, and jaw claudication. On physical examination, the patient is tender to palpation along her shoulder girdle bilaterally as well as her trunk. The patient has a normal neuromuscular examination and no obvious signs of inflammation in any of her joints. Relevant laboratory findings are as follows:

WBC count: $7.2/\text{mm}^3$

RBC count $10,300/\text{mm}^3$

Erythrocyte sedimentation rate: 85 mm/hr

C-reactive protein: 10.1 mg/L

Rheumatoid factor: negative

Antinuclear antibody: negative

CPK: normal

-
- **What is the most likely diagnosis?** Polymyalgia rheumatica (PMR). PMR is a clinical syndrome characterized by severe aching and stiffness in the neck, shoulder girdle, and pelvic girdle. This condition has a prevalence of 1% and rarely affects patients < 50 years old. It is more commonly seen in whites. Fifteen percent of patients with PMR will also have temporal arteritis (TA), and 50% of patients with TA will have PMR.

 - **What other symptoms are common in patients with this condition?** The classical presentation of PMR is proximal muscle pain and weakness. Patients will typically complain of subacute or chronic symmetric aching and morning stiffness in the shoulders, hips, neck, and torso. In addition, they usually have difficulties with daily life activities such as dressing in the morning (e.g., pulling a sweater over their head or putting on stockings) and brushing their hair. In a patient with PMR, headaches or high spiking fevers should alert the physician to the possibility of TA.

 - **What are the typical laboratory and radiographic findings in this condition?** As with TA, PMR is associated with an elevated erythrocyte sedimentation rate (ESR) and C-reactive protein. Typically, the ESR is between 60 and 100 mm/hr, but values below 40 mm/hr can still be consistent with PMR. Plain radiographs of affected areas will rarely reveal any abnormalities. However, MRI of such areas will confirm the inflammation of extra-articular structures that is associated with this condition.

 - **What is the most appropriate treatment for this condition?** PMR is remarkably responsive to low-dose corticosteroids. Note that high-dose corticosteroids will be required if TA is also present.
-

Neurology

Case 1	250
Case 2	252
Case 3	254
Case 4	256
Case 5	258
Case 6	260
Case 7	262
Case 8	264
Case 9	266
Case 10	267
Case 11	268
Case 12	269
Case 13	270
Case 14	272
Case 15	275
Case 16	276
Case 17	278
Case 18	281
Case 19	282
Case 20	284
Case 21	286
Case 22	288
Case 23	290

► **CASE 1**

A 50-year-old left-hand-dominant man presents to his primary care physician with complaints of right hand weakness. He says 6 months ago he began dropping things with his right hand. In the subsequent months, his grip strength has weakened further and his handwriting has deteriorated. He has also noticed frequent twitching in the muscles of his right hand, forearm, and shoulder, and he has developed painful muscle cramps in his neck and back. He also reports occasional problems swallowing his food and says his speech seems “thicker.” The patient reports no other significant past medical history and denies any lower extremity disturbances or sensory deficits. Vital signs are within normal limits. The patient’s cranial nerve examination is significant for atrophy of the tongue, which also demonstrates fasciculations upon protrusion. On motor exam, the patient has significant thenar atrophy of the right hand, but not on the left. Right hand strength is 3/5, and left hand strength is 4/5. Triceps and biceps are 4+/5 bilaterally and deltoids are 5/5 bilaterally. Neuromuscular examination of the lower extremities is normal. Reflexes are 3+ in the upper extremities bilaterally and he also has a brisk jaw jerk reflex. Sensory examination is normal. The patient’s gait is normal, and he exhibits no ataxia.

■ **What is the most likely diagnosis?**

Amyotrophic lateral sclerosis (ALS). ALS is a neurodegenerative disorder that causes progressive muscle weakness and disability. ALS follows a relentless course and eventually leads to death, with dysphagia and respiratory muscle weakness causing recurrent aspiration pneumonias and culminating in overt respiratory failure. This disease typically affects patients between 40 and 60 years old. Men are affected more often than women. Most cases of ALS are idiopathic, but 5–10% of cases are familial and follow an autosomal dominant inheritance pattern.

■ **What causes this condition?**

The etiology of the neurodegeneration in ALS is currently unknown. Signs and symptoms result from the death of motor neurons in the spinal cord (anterior horn cells) and brain stem, the descending corticospinal tracts, and motor regions of the frontal cortex. Because ALS damages both the corticospinal tracts and the motor neurons, patients exhibit a combination of upper motor neuron (UMN) and lower motor neuron (LMN) signs:

- UMN signs:
 - Weakness; affects groups of muscles.
 - Hyperreflexia and hypertonia.
 - Spasticity; predominant in the antigravity musculature (i.e., flexors in the upper extremities and extensors in the lower extremities).
 - Extensor plantar responses (Babinski’s sign).
 - LMN signs:
 - Weakness; affects single muscle fibers.
 - Atrophy.
 - Fasciculations.
 - Hyporeflexia or areflexia.
-

- **What is the typical presentation of this condition?**

Early in the disease, ALS can be difficult to diagnose as symptoms can be very subtle. Patients with early ALS usually present with focal motor weakness, often in an arm. This weakness can be accompanied by a combination of both UMN and LMN signs, but atrophy of intrinsic hand muscles and fasciculations may be the only early signs. As the disease progresses, hyperreflexia and spasticity of the limb often develops, and eventually the disease involves other limbs, the neck, tongue, and pharyngeal and laryngeal muscles. About 25% of patients present initially with bulbar symptoms such as slurred speech and difficulty swallowing. Notably, sensory deficits are not part of this disease. The diagnosis of ALS requires electromyography (EMG), which demonstrates widespread denervation in at least three limbs. EMG findings of denervation include giant motor unit potentials, polyphasic motor unit potentials, and fibrillations.

-
- **What other condition may have a similar presentation?**

There is a significant overlap between ALS and frontotemporal dementia (FTD). As many as 15% of patients with FTD meet definite criteria for ALS. These patients develop cognitive deficits resulting from the loss of frontal and temporal cortical neurons. This leads to impairment of executive functioning, behavior, and memory.

► **CASE 2**

An 80-year-old woman is brought to her physician by her daughter for a medication check. During the visit, the patient has trouble answering questions about events that took place in the past month, and at one point stops to ask her daughter where she is. Her daughter comments that she has recently been disoriented in familiar environments, that she has trouble coming up with the names of people and objects, and that she recently forgot to turn off the stove at home, setting off the fire alarm. Her temperature is 36.5°C (97.7°F), with a heart rate of 90/min and a blood pressure of 130/80 mm Hg. Neurologic examination reveals no focal deficits, but she scores a 22/30 on the Mini-Mental State Examination, losing points because she is not oriented to the date or day of the week, is unable to recall words that she has been asked to remember after a brief delay, and is unable to copy a simple figure.

- | | |
|--|--|
| ■ What is the most likely diagnosis? | Dementia. Dementia is defined as a chronic progressive decline in multiple areas of cognitive functioning that impairs activities of daily living. Memory is most commonly affected, but there are also language, problem-solving, mood, and neuropsychiatric deficits. This patient's prominent deficits in memory, naming, and visuospatial processing are most consistent with a diagnosis of dementia of the Alzheimer type. |
| ■ What are the most common causes of this condition? | Dementia may be due to a primary neurodegenerative process (primary dementia) or due to other medical conditions (secondary dementia), the latter of which may be reversible if the medical condition can be treated early enough (e.g., vitamin B ₁₂ deficiency). The most common cause of primary dementia in the United States is Alzheimer's disease (AD); vascular demetia is the next most common, followed by dementia with Lewy bodies and frontotemporal lobar degeneration. |
| ■ What are the most common potentially reversible causes of this condition? | <ul style="list-style-type: none">■ D: Drug toxicity (sedatives, analgesics, polypharmacy).■ E: Ethanol.■ M: Metabolic (hypothyroidism, hepatic or renal disease).■ E: Environmental (chronic heavy metal poisoning, sensory deprivation due to hearing or vision loss).■ N: Nutritional (thiamine, vitamin B₁₂ deficiency).■ N: Normal pressure hydrocephalus.■ T: Tumor (especially in the frontotemporal lobe).■ T: Trauma (dementia pugilistica, chronic subdural hematoma).■ I: Infection (HIV, syphilis).■ A: Affective disorders (depression, schizophrenia). |
| ■ What diagnostic tests should be performed? | The diagnostic workup should try to identify any reversible causes based on presenting symptoms and history. Screening should be performed for common disorders like depression and alcoholism. Routine laboratory tests such as a complete blood count, electrolyte panel, thyroid and liver function tests, and vitamin B ₁₂ levels should also be pursued when a new patient presents with dementia. If not documented, screening for syphilis and HIV may be appropriate. Imaging with CT or MRI is recommended, particularly if the exam reveals focal neurological deficits. |
-

- **What management options are available for this patient and her daughter?**

Available medical treatments include acetylcholinesterase inhibitors (e.g., donepezil) and NMDA-receptor antagonists (e.g., memantine), both of which have been shown to slow progression in mild to moderate cases of dementia. Depression can often exacerbate cognitive symptoms and should be treated to improve both mentation and quality of life. Efforts should also be made to reduce caretaker “burnout.”

► **CASE 3**

An 18-year-old man is brought to the emergency department (ED) by his mother for “increasing sleepiness.” His mother relates that he has been having fevers over the past week up to 38.6°C (101.4°F), which were reduced with acetaminophen. The last two days he has had headaches, and this morning began experiencing significant nausea and vomiting. She attributed his symptoms to gastroenteritis until he began having trouble using his left arm and became progressively more somnolent. He has no sick contacts but did have an upper respiratory tract infection about 5 weeks ago. His past medical history is significant for mild asthma and frequent sinusitis. His sinusitis usually resolves with oxymetazoline and saline nasal sprays. Several times over the past few years he has required antibiotics for chronic sinusitis. On physical examination, the patient is able to answer some basic questions but has difficulty keeping his eyes open. His neck is supple. His neurologic exam demonstrates bilateral papilledema and 2/5 strength in his left arm and leg. Computed tomography (CT) scan of the head with contrast reveals a ring-enhancing lesion adjacent to the superior aspect of the right frontal and temporal bones, without evidence of a bony defect. Laboratory findings are as follows:

White blood cells: 18,900/mm³
Red blood cells: 41,100/mm³
Platelets: 302,000/mm³

■ What are the next immediate steps in this patient’s workup?	His symptoms of headache, nausea, vomiting, and focal neurologic deficits in combination with signs of infection are concerning for intracranial pyogenic infection, which in this case turned out to be an epidural abscess. With a mass lesion identified, a neurosurgery consult is the next best step. Immediate administration of antibiotics and surgical management of the intracranial abscess are imperative for a positive outcome in this case.
■ What factors contributed to this patient’s presentation?	His history of sinusitis is the most likely contributing factor to his disease. Four pairs of air-filled sinuses are present in the adult. The ethmoid and maxillary sinuses are present and clinically significant at birth, while the sphenoid and frontal sinuses develop as the child grows. Obstruction of the ostia draining the frontal, maxillary, and anterior sphenoid sinuses, which commonly occurs during upper respiratory tract infections, can facilitate overgrowth of native bacterial flora manifesting as acute sinusitis. The peak incidence of epidural abscesses secondary to sinusitis occurs in adolescence and is more common in males.
■ What organisms are probably responsible for this patient’s disease?	Microorganisms responsible for acute sinusitis are primarily native nasopharyngeal flora: <i>Streptococcus pneumoniae</i> , <i>Moraxella</i> , and nontypable <i>Haemophilus influenzae</i> . Anaerobes can be seen in chronic sinusitis, so appropriate antibiotic coverage for this patient would be broad until susceptibilities are available.
■ How would his infection have reached the epidural space?	Spread of infection usually occurs via progressive thrombophlebitis through the diploic veins (valveless veins draining through the cranial bone). One explanation for the prevalence of this disease in adolescent males is the increased vascularity of the diploe in that age group. Other mechanisms include direct passage through a bony defect caused by osteomyelitis, trauma, or surgery.

■ **What other complications related to paranasal sinusitis can occur?**

Ophthalmological complications, most commonly arising from infection in the ethmoid sinuses, present with chemosis and periorbital edema. Orbital cellulitis and subperiosteal abscess of the orbit are distinguished from preseptal cellulitis (infection of structures anterior to orbit) by decreased vision, range of extraocular movement, and proptosis. Other intracranial complications include cavernous venous thrombosis, brain abscess, and osteomyelitis of the frontal bone (Pott's puffy tumor).

► **CASE 4**

An 18-year-old woman is brought to the emergency department by ambulance after a motor vehicle accident. The patient was alert when the paramedics arrived at the scene, but her level of consciousness declined en route to the hospital. The patient told the paramedics she was unrestrained and had hit her windshield during the collision. On presentation the patient is drowsy but responsive to verbal commands. She complains of back and neck pain and a headache. There is a contusion and abrasion over her right temporal region; the remainder of her head, ear, eye, nose, and throat examination is normal. Neurological examination reveals no focal deficits, and cranial nerves II–XII are intact. Vital signs, a complete blood count, and blood chemistry test results are within normal limits. A lateral x-ray of the cervical spine reveals no abnormalities. Noncontrast CT scan of the head shows a small skull fracture in the temporal region and an underlying extra-axial lenticular hyperdensity.

- | | |
|---|--|
| ■ What is the most likely diagnosis? | Epidural hematoma (EDH). EDH is an accumulation of blood between the inner table of the skull and the dural membrane. In a patient with a history of blunt head trauma, radiographic evidence of a temporal bone fracture, and an underlying lens-shaped collection of blood, EDH is the most likely diagnosis. Because the underlying brain has usually been spared from injury, prognosis is excellent if treated quickly and aggressively. |
| ■ What are the typical clinical findings associated with this condition? | Trauma that causes an EDH sometimes results in a transient episode of altered consciousness immediately following the initial impact, followed by a lucid interval prior to a subsequent decline in consciousness (from the enlarging hematoma). Patients may progress to coma by the time they receive medical attention. Other common presenting signs and symptoms include headache, seizure, and nausea/vomiting. |
| ■ What other symptoms are common in patients with this condition? | As with all expanding space-occupying lesions, increasing intracranial pressure can lead to brain herniation and possible death. Signs of increasing intracranial pressure and herniation include the following: <ul style="list-style-type: none">■ A triad of hypertension, bradycardia, and respiratory irregularities, (Cushing's triad).■ Cranial nerve III and/or VI palsy.■ Dilated, sluggish, or fixed pupils.■ Papilledema secondary to impaired axonal transport and congestion of the optic nerve.■ Periorbital bruising. |
| ■ What risk factors are associated with a worse prognosis? | The mortality rate for EDH is 5–40%, with increased mortality associated with the presence of the following: <ul style="list-style-type: none">■ Advanced age.■ Increased hematoma volume.■ Increased intracranial pressure.■ Intradural lesions.■ Lower Glasgow Coma Scale rating.■ Pupillary abnormalities.■ Rapid clinical progression.■ Temporal location. |
-

- **What is the most appropriate treatment for this condition?**

Initial management focuses on hemodynamic and respiratory stabilization. Definitive surgery (craniotomy and excavation of the underlying hematoma) may be required; burr hole placement at bedside in rare cases may be necessary in setting of imminent death from herniation.

► **CASE 5**

A 70-year-old Asian woman presents to the emergency department complaining of extreme pain in her right eye and blurred vision. The pain began suddenly that morning and got progressively worse during her drive to the hospital; she vomited once and reports continued nausea. The blurred vision began with the pain and is in only her right eye. She is a retired radiologist with no significant past medical history. On physical examination, she is in severe discomfort, with her hand over her right eye. Her eye is hard and red; the pupil is 6 mm dilated and reacts poorly to light. Visual acuity is 20/200 in the right eye and 20/30 in the left. The remainder of her exam, including that of the left eye, is unremarkable.

- | | |
|---|---|
| ■ What is the most likely diagnosis? | Closed-angle glaucoma. This is an optic neuropathy due to narrowing or closure of the anterior chamber angle that prevents adequate drainage of the aqueous humor from the eye and leads to elevated intraocular pressure (typically over 30 mm Hg, normal 8–21 mm Hg). This is a medical emergency that must be addressed within 24 hours to prevent blindness. |
| ■ How can the diagnosis be confirmed? | She will need an immediate ophthalmology consult for evaluation and treatment. Her exam will include the following components: <ul style="list-style-type: none">■ Gonioscopy: gold-standard for the diagnosis of angle closure; involves use of a special lens with a slit lamp.■ Slit lamp exam of anterior segments: can be used to estimate anterior chamber depth; not as reliable as gonioscopy.■ Measurement of intraocular pressure. |
| ■ What is the epidemiology of this condition? | Closed-angle glaucoma is the leading cause of glaucoma blindness worldwide; in the United States, it constitutes ~10% of cases of glaucoma. Patients have an anatomic predisposition to the condition; risk factors include: <ul style="list-style-type: none">■ Family history of angle closure.■ Advanced age.■ Female > male.■ Asian or Inuit ethnicity.■ Pupillary dilation (prolonged time in the dark, stress, medications).■ Anterior uveitis.■ Lens dislocation. |
| ■ What is the most appropriate treatment for this patient? | Treatment involves rapidly decreasing the intraocular pressure and reversal of angle closure. Systemic acetazolamide is given, followed by topical pilocarpine or timolol eye drops. This will typically reduce the intraocular pressure and improve the patient's symptoms. Definitive treatment involves laser iridotomy, which creates a hole in the iris and allows drainage of the aqueous humor. The fellow eye should also be examined, as prophylaxis may be needed to prevent angle closure. |
-

- **What is the other common form of this condition, and how does it present?**

Open-angle glaucoma. This is the most common type of glaucoma in the United States. Patients are typically older blacks with diabetes and myopia who present with peripheral visual field loss progressing to central field loss. Intraocular pressure is typically elevated, and the optic disc shows characteristic “cupping” on fundoscopic exam. Symptoms are usually minor, and at-risk patients should be screened carefully to avoid missing the diagnosis.

-
- **What is the most appropriate treatment for this condition?**

Prevention is key for open-angle glaucoma, as visual field loss cannot be reversed. Topical medications such as timolol and pilocarpine can decrease intraocular pressure. Laser trabeculoplasty can open the diseased trabecular network and allow aqueous drainage.

► **CASE 6**

A 45-year-old man is brought to the emergency department following a generalized convulsive episode witnessed by strangers. He was subsequently observed to be in a confused state, having lost continence of bowel and bladder. When the paramedics bring him to the hospital, he is more lucid but his language ability seems impaired. He states that he has noticed progressive difficulty comprehending conversations, and that he sometimes mispronounces words or uses the wrong words. He says he has also been suffering from general malaise and a dull headache. In the past several weeks he has had several episodes of “lost time” in which he loses awareness, followed by a transient disorientation; he has no memory of what occurs during these episodes. The patient denies any fever, chills, night sweats, or recent illness and has no relevant past medical history. He smokes half a pack of cigarettes per day and drinks socially on occasion. On examination, the patient is well appearing and in no acute distress. His vital signs are stable and his CBC and blood chemistry studies are unremarkable. HEENT, cranial nerve, and neurological examinations reveal no abnormalities or focal deficits. Results of T2- (Figure 10-1A) and enhanced T1-weighted (Figure 10-1B) MRI are shown.

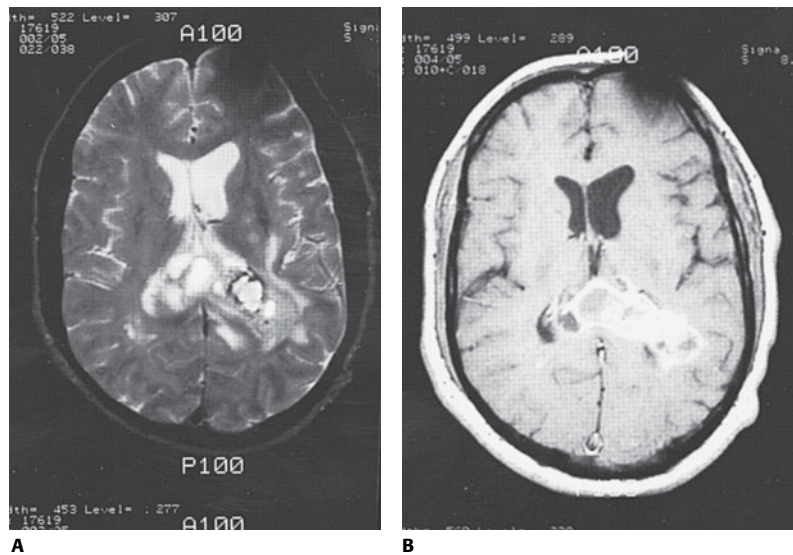


FIGURE 10-1 A & B. (Reproduced, with permission, from Ropper AH, Brown RH. *Adams and Victor's Principles of Neurology*, 8th ed. New York: McGraw-Hill, 2005: Fig. 31-2.)

■ **What is the most likely diagnosis?**

Glioblastoma multiforme (GBM). GBM is the most common primary brain tumor in adults. It is also the most malignant of the primary tumors and has a mean survival of 3 months without therapy and 1 year with optimum therapy. In younger patients (< 45 years old), GBM tends to occur because of malignant degeneration of a lower-grade astrocytoma. In older patients, GBM arises de novo as a primary tumor. GBM is the most undifferentiated of the astrocytic subset of glial brain tumors.

■ **What conditions should be included in the differential diagnosis?**

- Other tumors:
 - Brain metastases
 - CNS lymphoma
 - Anaplastic astrocytoma
 - Oligodendroglioma
- Infection:
 - Brain abscess
 - Encephalitis
- Vascular lesions:
 - Intracerebral hemorrhage
 - Arteriovenous malformation

■ **What is the typical presentation of this condition?**

GBM most commonly presents with a progressive neurological deficit related to the area of brain where the tumor is located. As seen in Figure 10-1, this patient has a large tumor deep within the left cerebral hemisphere and extending through the corpus callosum, and presented with aphasia. Other common presenting signs and symptoms include headache (worse in the morning), seizure, and changes in mental status or personality. GBM is an aggressive tumor that grows quickly; most patients are diagnosed with GBM within 6 months of symptom onset.

■ **How is this condition diagnosed histologically?**

GBM typically consists of poorly differentiated, pleomorphic astrocytic cells with marked nuclear atypia and brisk mitotic activity. Necrosis is also an essential diagnostic criterion for GBM. Immunostaining is positive for glial fibrillary acidic protein, vimentin, and fibronectin.

■ **What is the most appropriate treatment for this condition?**

Treatment of GBM is difficult since no current therapy is considered curative. At this point, treatment of GBM is palliative and utilizes a combination of radiation, chemotherapy, and surgery.

► **CASE 7**

An 18-year-old woman presents to the emergency department complaining of leg weakness. One week ago the patient was ill with fever, nausea, and diarrhea, but the symptoms resolved 2 days prior to admission. The patient first noticed that something was wrong upon waking up this morning, when she nearly fell over after getting out of bed. She says she cannot walk without support and that as the day has progressed, her arms have also begun to feel weak. She has also developed pain in the lower back and legs as well as a bothersome tingling sensation in the feet. The patient denies any headache, blurred vision, tinnitus, or vertigo, but has had mild weakness in the face and has noticed that her speech is becoming more slurred. She is not experiencing any bowel or bladder incontinence. On presentation, the patient is a well-nourished teenager who appears nervous. Vital signs include a temperature of 37.0°C (98.6°F), a heart rate of 72/min, a respiratory rate of 22/min, and a blood pressure of 100/64 mm Hg. HEENT, heart, lung, and abdomen examinations are normal. Her cranial nerve examination demonstrates mild facial diplegia and dysarthria. She has 3/5 strength in the lower extremities bilaterally and 4/5 strength in the upper extremities. Deep tendon reflexes are absent throughout. Brachial, posterior tibial, and dorsalis pedis pulses are 2+ bilaterally. CBC, electrolytes, blood urea nitrogen, creatinine, glucose, calcium, and liver function tests are normal. Urine toxicology screen is negative. A lumbar puncture is performed; opening pressure is normal. CSF analysis shows a protein level of 146 mg/dL, glucose of 70 mg/dL, and no WBCs or RBCs. Gram stain demonstrates no WBCs and no organisms.

■ **What conditions should be considered in the differential diagnosis?**

The differential for an individual presenting with rapidly progressing flaccid quadriplegia includes:

- Acute HIV seroconversion
 - Acute myelopathy
 - Botulism
 - Collagen vascular disease
 - Diphtheria
 - Guillain-Barré syndrome
 - Heavy metal intoxication
 - Hexane inhalation
 - Hypophosphatemia and hypomagnesemia
 - Lyme disease
 - Myasthenia gravis
 - Poliomyelitis
 - Porphyria
 - Tick paralysis
-

■ **What is the most likely diagnosis?**

Guillain-Barré syndrome (GBS) is an acute inflammatory demyelinating polyneuropathy of the peripheral nervous system characterized by progressive flaccid weakness. Weakness typically first develops in the lower extremities and may eventually spread proximally to involve the trunk, upper extremities, and, in severe cases, respiratory and bulbar muscles. This pattern of ascending paralysis is fairly symmetric and develops over a period of days or weeks. There is a slight male predominance of 1.5:1 and the disease occurs in 1 of every 100,000 people every year.

■ **What criteria are used to diagnose this condition?**

Typical history findings include the following:

- Ophthalmoplegia, associated with the Miller Fisher variant, may manifest as a complaint of double vision.
- Pain is often the initial complaint in young children.
- Weakness or ataxia, often within 2–4 weeks of a viral illness.

Typical physical findings include the following:

- Areflexia is a hallmark of GBS. Proximal reflexes are sometimes present early in the presentation of the disease.
- Areflexia, ophthalmoplegia, and ataxia are a triad of symptoms associated with the Miller Fisher variant.
- Ascending motor weakness.
- Autonomic dysfunction manifests as orthostatic hypotension, pupillary dysfunction, sweating abnormalities, and sinus tachycardia.
- Cranial nerve findings, particularly facial weakness and dysarthria, may be observed.

Typical laboratory findings include the following:

- Abnormal nerve conduction study findings (including prolonged distal motor latencies, F waves, and conduction block).
- Albuminocytologic dissociation on CSF evaluation (high protein count with a low cell count) is highly suggestive of GBS.
- GBS-associated antibodies such as GQ1B (for the Miller Fisher variant) and GM1 (for *Campylobacter jejuni*-associated GBS).
- Stool culture positive for *C. jejuni* (approximately 1/1000 *C. jejuni* infections results in GBS).

■ **What is the most appropriate treatment for this condition?**

The mainstay of therapy is immunomodulation by administering either intravenous immunoglobulins or plasmapheresis. Both therapies are proven to slow or halt the progression of the disease and hasten the recovery of lost motor function. The patients most likely to benefit are those who present with moderate or severe progressive weakness and those who are unable to walk, have a rapidly progressive course, or have bulbar paralysis and impending respiratory distress. More severe cases of GBS (30%) may require mechanical ventilation in addition to immunomodulation. Patients with mild symptoms or patients who present weeks after symptom onset are less likely to benefit. For such patients, supportive care including nursing and respiratory care, physical therapy, and adequate nutrition are usually sufficient. Overall, children have a better prognosis than adults.

► **CASE 8**

A 27-year-old woman presents to her primary care physician complaining of recurrent headaches that started in puberty, but have recently become more frequent, now occurring approximately three times a month. She describes the pain as throbbing, focused over the left temple, and accompanied by nausea, occasional vomiting, and sensitivity to bright lights and loud noises. Upon further questioning, she admits to seeing flashing lights in her right lower visual field approximately 1 hour before the headache begins. Physical examination reveals a temperature of 37°C (98.6°F), a heart rate of 80/min, a respiratory rate of 12/min, and a blood pressure of 120/80 mm Hg. A neurologic examination shows no focal deficits.

■ **What is the most likely diagnosis?**

Migraine with aura (old term: classic migraine). This patient most likely has a primary headache disorder due to the chronic presentation and lack of focal neurologic findings. She fulfills the diagnostic criteria for migraine, and the presence of an aura rules out the more prevalent disorder of migraine without aura (old term: common migraine). Peak onset occurs in adolescence.

■ **What conditions should be included in the differential diagnosis?**

Two other primary headache disorders include tension and cluster headaches. Tension headaches are bilateral, of mild to moderate intensity, and unaffected by physical activity. Patients associate them with a feeling of pressure or tightness. Cluster headaches are unilateral, severe, and occur in groups ranging from every other day to up to eight times a day. They are associated with autonomic phenomena such as conjunctival injection, lacrimation, and nasal congestion. They are more common in men than women.

There are many secondary causes of headache, including subarachnoid hemorrhage, temporal arteritis, tumor, malignant hypertension, narrow-angle glaucoma, meningitis, and analgesic rebound (or medication overuse) headache.

■ **What are the diagnostic criteria?**

To make the diagnosis of migraine, a patient must have recurrent headaches lasting hours to days with at least two of the following characteristics:

- Aggravated by physical activity
- Moderate to severe intensity
- Pulsating quality
- Unilateral location

AND at least one of the following:

- Nausea and/or vomiting
- Photophobia or phonophobia

As in this patient, the aura is most commonly a visual disturbance. It precedes the headache by an interval of ≤ 60 minutes, develops gradually, and is fully reversible.

- **What is the most appropriate treatment for this condition?**

Initiate abortive therapy at the first sign of pain. High-dose nonsteroidal anti-inflammatory drug (NSAID) therapy can be successful, especially if paired with an antiemetic or promotility agent such as phenergan or metoclopramide. The most specific (and expensive) relief for migraine comes from the triptans (e.g., sumatriptan), a family of selective agonists for the serotonin 1D receptor. In the emergency department setting, alternative abortive agents include IV steroids, antiepileptics (e.g., divalproex) and ergots (dihydroergotamine).

- **What are the prevention options for this patient?**

Prophylactic therapy can decrease migraine frequency and severity. Options include antihypertensives (particularly β -blockers and calcium channel blockers), antidepressants (e.g., tricyclic antidepressants), and antiepileptics (e.g., valproic acid and topiramate). In addition, patients should avoid potential triggers; common triggers include dietary (red wine, sharp cheeses), hormonal (estrogens or menses), and environmental (perfumes, lack of sleep, letdown period after high stress).

► **CASE 9**

A woman brings her 50-year-old father to a neurologist after being referred by his psychiatrist. He is belligerent, making inappropriate comments, and occasionally experiencing auditory hallucinations. His behavioral problems developed a few years ago and were initially attributed to a substance abuse problem. However, a recent examination by his psychiatrist showed rhythmic, repetitive grimacing and blinking, with occasional rapid, jerky, dancelike movements of his right arm. The daughter says that she remembers her grandfather having similar symptoms and that he committed suicide when she was a child. Physical examination reveals a temperature of 37°C (98.6°F), a heart rate of 80/min, and a blood pressure of 145/90 mm Hg.

- | | |
|---|--|
| ■ What is the most likely diagnosis? | Huntington's disease (HD). HD is an autosomal dominant neurodegenerative disorder with prominent psychiatric components, including personality changes and substance abuse. The hallmark of the disease, however, is the choreiform movements that start in the face and progress to include the entire body, making purposeful movement impossible. The later stage of the disease is marked by parkinsonism and dementia. After the appearance of symptoms, life expectancy is approximately 20 years. |
| ■ What are the typical gross and microscopic pathology findings in this condition? | The HD brain is characterized by widespread atrophy, most markedly in the caudate nucleus. On electron microscopy, inclusion bodies containing mutant huntingtin protein are seen in the nucleus and cytoplasm of neurons. |
| ■ What are the genetics of this condition? | Huntington's disease is a triplet repeat disorder caused by an instability on chromosome 4 characterized by CAG repeats, a gain-of-function mutation in the protein huntingtin. Wild-type huntingtin has 4–29 repeated sequences; > 36 repeats can cause the disease. As the diseased allele is passed on to the next generation, the number of CAG repeats increases, causing the clinical phenomenon of anticipation, in which subsequent generations experience progressively more severe symptoms and at earlier ages. |
| ■ What test could be used to confirm the diagnosis? | When HD is suspected clinically, there is a genetic test available to confirm the diagnosis. For affected patients, genetic counseling should be considered, particularly if they have asymptomatic offspring. |
| ■ What is the most appropriate treatment for this condition? | Treatment is for symptomatic relief only, and does not significantly alter the natural history of the disease. Dopamine antagonists (e.g., haloperidol) can help control unwanted movement and psychotic symptoms, but can also contribute to parkinsonism and dystonia. Atypical antipsychotics have fewer side effects. Depression and anxiety are managed with selective serotonin reuptake inhibitors and benzodiazepines. The dopamine-depleting drug reserpine has been used to control unwanted movement. |
-

► CASE 10

A 4-month-old boy is brought to the emergency department (ED) by his parents following a seizure. He was lying in his crib when his head, trunk, arms, and legs began symmetrically jerking; his parents estimate that the seizure lasted 2 minutes. He began seizing again in the car on the way to the ED. He has been healthy since birth and has met all his developmental milestones. On physical examination, the baby appears postictal. There are no obvious neurologic findings. An interictal electroencephalogram (EEG) displays hypsarrhythmia.

- | | |
|---|---|
| ■ What is the most likely diagnosis? | Infantile spasms, or West syndrome. This is a rare but very serious form of generalized epilepsy in infants. It presents between 3 and 12 months of age, usually around age 5 months, and affects males more than females. Infants cease psychomotor development at the age of seizure onset, so the prognosis for these patients is very poor. |
| ■ What is the etiology of this condition? | <p>Many cases of infantile spasms are considered idiopathic; however, in some patients, organic brain disease is found, such as the following:</p> <ul style="list-style-type: none"> ■ Phenylketonuria (PKU) ■ Perinatal infections ■ Hypoxic-ischemic injury ■ Tuberous sclerosis ■ Microcephaly or cerebral atrophy <p>This patient likely has idiopathic West syndrome, given his previously normal development.</p> |
| ■ What are the typical EEG findings in this condition? | Infantile spasms can be diagnosed by the characteristic interictal finding on EEG of hypsarrhythmia . This is a very chaotic and disorganized reading, with no recognizable pattern. It is often said that the EEG looks the same when flipped upside down. |
| ■ What is the most appropriate treatment for this condition? | First-line therapy includes adrenocorticotropic hormone and prednisone. Antiepileptics are used to control the seizures but commonly do not affect the patient's long-term outcome. There is some evidence that a ketogenic diet may also reduce seizure activity. |
-

► **CASE 11**

A 30-year-old man presents to the ophthalmology clinic with “double vision.” He states that when he gazes to the right, he sees two images side by side. This does not occur when he looks to the left. Past medical history is significant for depression, for which he takes amitriptyline. He denies ocular pain, recent viral illness, or tick bites. He does not smoke, drink alcohol, or use intravenous drugs. Visual field testing reveals an adduction deficit in the left eye. Extreme right lateral gaze causes horizontal nystagmus in the abducting right eye and recreates the painless horizontal diplopia the patient has been experiencing. Conjugate eye movements are observed in all other directions. Accommodation and convergence are normal.

■ **What is the most likely diagnosis?** Internuclear ophthalmoplegia (INO). INO results from lesions of the medial longitudinal fasciculus (MLF), a fiber pathway that connects the abducens nucleus (cranial nerve VI) in the dorsal pons to the contralateral oculomotor nucleus (cranial nerve III) in the midbrain. Without coordination of these two nuclei, the medial rectus of the adducting eye cannot coordinate with the lateral rectus of the abducting eye. This leads to the characteristic disconjugate lateral gaze of INO. In addition, the abducting eye also has end-gaze nystagmus. INO can either be unilateral (as in this patient) or bilateral, in which lateral gaze in either direction will produce diplopia.

■ **What conditions should be considered in the differential diagnosis?** INO can easily be confused with a medial rectus palsy since the affected eye appears to have lost its ability to adduct. However, most patients with INO retain the ability to converge, as this ocular movement pattern (bilateral ocular adduction in response to focusing on an object moving closer to the eyes) does not require an intact MLF.

The presence of INO suggests a brain stem lesion involving the MLF. INO can result from a small-vessel brain stem stroke and may be the presenting sign of multiple sclerosis (MS). Most patients (92%) who develop INO because of demyelination will progress to full-blown MS. Such patients require close follow-up so that the diagnosis of MS can be made at an earlier stage. Another important consideration is myasthenia gravis (MG), which can also initially mimic the findings of INO. Half of patients with MG present initially with extraocular muscle weakness. As such, patients in whom there is any question of the diagnosis should undergo testing for anti-acetylcholine receptor antibodies.

Many other diseases can create such a lesion, they include brain stem and fourth ventricular tumor; drug intoxication (e.g., phenothiazines, tricyclic antidepressants, toluene, tacrolimus); Lyme disease; trauma; subdural hematoma; syphilis; and viral infection.

In this patient, a history of tricyclic antidepressant use may explain his symptoms, as this toxicity of this medication has been known to cause INO.

■ **What test(s) should be used to determine the etiology of this condition?** Imaging with MRI (with and without contrast) is the initial test of choice to help identify the etiology. If MS is suspected, cerebrospinal fluid evaluation (e.g., for oligoclonal bands) is warranted. Other recommended tests include a toxin screen, FTA-Abs/VDRL (for syphilis), Lyme titer, fasting blood glucose, CBC with differential, and blood pressure measurement.

■ **What is the most appropriate treatment for this condition?** Treatment is focused on the etiology of the brain stem lesion associated with INO.

► **CASE 12**

A 53-year-old woman presents to her primary care physician complaining of severe nausea and “dizziness.” The patient’s symptoms began upon arising from bed. She states that “it feels like the world is spinning” around her and that she feels nauseous. Sitting still for a moment will cause the symptoms to abate, but upon moving the symptoms begin again. The patient has no significant past medical history and is an avid runner. She denies any history of smoking or alcohol use, and any recent illness or sick contacts. On examination, bringing the patient from a seated to a supine position and turning her head 45 degrees to the side reproduces her symptoms and causes upbeat torsional nystagmus 20 seconds after head movement. Vital signs are stable, and results of laboratory tests are within normal limits.

-
- **What is the most likely diagnosis?** Benign positional paroxysmal vertigo (BPPV). BPPV is the most common cause of peripheral vertigo, accounting for approximately 50% of cases. There does not seem to be any age or sex predilection. BPPV is likely caused by the dislodgement of otoconia (calcium carbonate crystals) from the otolithic membrane of the utricle, which then travel into the semicircular canal ducts; this is known as canalithiasis. The debris in the canal is thought to cause inappropriate endolymph movement and, thus, the sensation of rotational movement that is out of sync with actual movement.

 - **What conditions should be considered in the differential diagnosis?** Vertigo (a symptom of vestibular dysfunction characterized by an illusion of motion or spinning) must be distinguished from other forms of dizziness such as presyncope or disequilibrium. Vertigo is classified as either central vertigo or peripheral vertigo. Central vertigo results from lesions involving the vestibular nuclei or their central pathways; peripheral vertigo results from lesions involving the semicircular canals or the vestibular nerve. Of patients with true vertigo, approximately 80% have peripheral vestibular dysfunction, while the remainder have central vestibular dysfunction. The common causes of peripheral vertigo include BPPV (~50%), vestibular neuritis or labyrinthitis (~25%), and Ménière’s disease (the triad of sensorineural hearing loss, ear fullness, and tinnitus). BPPV is distinguished from the latter by the transient, positional nature of the vertigo.

 - **What are the typical clinical findings associated with this condition?** Patients complain of acute episodes of vertigo, typically lasting < 1 minute. They tend to occur sporadically and are triggered by sudden head movements. Some patients experience nausea and vomiting. Nystagmus is transient (note that nystagmus due to central lesions is usually static, in that the nystagmus persists as long as the head is kept in the provoking position).

 - **What clinical test(s) are most effective in the diagnosis of this condition?** The **Dix-Hallpike maneuver** is the test of choice for diagnosing BPPV. The test is conducted by quickly taking a seated patient into a supine position while turning the patient’s head 45 degrees and observing for nystagmus. While a positive test is pathognomonic, a negative test does not rule out BPPV. Nystagmus usually occurs after a few seconds and stops after about 30 seconds.

 - **What is the most appropriate treatment for this condition?** Repositioning exercises facilitate the migration of the deposits out of the semicircular canal ducts; these include the Brandt-Daroff exercises, the Epley maneuver, and the Semont maneuver.
-

► **CASE 13**

A 20-year-old college student presents to the clinic with fever and headache 2 days after returning from spring break in Mexico. The headache began the night before and has significantly disrupted her routine. She describes it as a 10/10, nonpulsating headache, exacerbated by moving her neck. She also notes that loud noises and bright lights seem to bother her much more than usual. On physical examination, her temperature is 39.1°C (102.4°F), pulse is 112/min, and the respiratory rate is 14/min. She is unable to touch her chin to her chest, and she experiences significant pain upon flexion of her thigh with extension of her leg. There is a macular purple rash over both shins, which she had not noticed before. Her funduscopic exam is normal, and she has no focal neurologic deficits. A lumbar puncture (LP) reveals cloudy fluid and the following results:

Protein: 75 g/dL
Glucose: 23 g/dL
WBCs: 678/mm³, 98% neutrophils
RBCs: 5/mm³
Bacteria: none visualized

-
- **What is the most likely diagnosis?** Bacterial meningitis. This is a classic presentation with severe headache, fever, nuchal rigidity, and a positive Kernig's sign. Bacterial infection is probable given the cerebrospinal fluid findings of elevated WBC count, increased protein, and decreased glucose. The rash is characteristic of meningitis due to *Neisseria meningitidis*, although a viral exanthem is also a possibility.
-
- **Should this patient have undergone CT scan prior to LP?** No. She has no evidence of increased intracranial pressure (i.e., papilledema) and no focal deficits, either of which would be concerning for tumor or intracranial bleed and could place her at risk of herniation during the LP.
-
- **When should patients receive steroids or antibiotics?** Current guidelines state that antibiotics should be started within 30 minutes from the suspected diagnosis of bacterial meningitis. However, antibiotic administration prior to lumbar puncture can decrease the likelihood of identifying the microorganism. Generally, the LP is performed first, with antibiotics immediately following. The problem arises when a patient requires CT scanning prior to LP, in which case empiric coverage is started immediately, often with cefotaxime or ceftriaxone. Steroids are often administered to decrease the risk of long-term complications, either prior to or with the first dose of antibiotics. Steroids have proven benefit in pneumococcal meningitis, but many clinicians will give them in any case of suspected bacterial meningitis and will continue administration for the full 4 days regardless of the results of bacterial culture.
-
- **What is the rate of post-meningitis complications?** Meningitis caused by *Streptococcus pneumoniae* is associated with an incidence of mortality as high as 19–37% and of complications (e.g., sensorineural hearing loss) as high as 30%. Meningococcal meningitis has lower mortality rates (3–13%) and complication rates of 3–7%. Negative prognostic indicators include *S. pneumoniae* infection, low WBC in the CSF, altered mental status, and systemic involvement.
-

■ **Is there an effective way to prevent bacterial meningitis?**

Vaccines are an important tool in combating the microbes causing meningitis. The *Haemophilus influenzae* type B vaccine has dramatically reduced the incidence of pediatric meningitis. A meningococcal vaccine targeting serotypes A, C, Y, and W135 is often offered to high-risk populations like military recruits and college freshmen. Pneumovax is a 23-valent vaccine recommended for older patients and patients with risk factors for *S. pneumoniae* infection, such as sickle cell disease, diabetes, or chronic obstructive pulmonary disease.

► **CASE 14**

A 31-year-old woman is referred to a neurologist for evaluation of multiple neurologic complaints. She recalls a specific episode 3 years ago of mild weakness in her right leg, which seemed to resolve over time. Last month, she developed incoordination of her left leg and left hand, although these too seem to be improving. She feels that she has also become less steady on her feet over time. Though she always considered herself to be an energetic person, over the past year or two she has been constantly fatigued. She has also been having problems focusing her attention and feels that her thinking has slowed down in general. She has noticed that many of her symptoms sometimes get worse after a hot bath or after she has been to the gym. The patient recently was sick with the flu and is now suffering from a particularly bad flare of her symptoms. Although her flu symptoms have subsided, she is concerned by the fact that 2 days following the onset of her flu she developed blurry vision in the right eye and pain in the eye associated with eye movements. On examination the patient is found to be afebrile and has normal vital signs. Her visual acuity in the right eye is 20/80 compared to 20/20 in the left eye. WBC count, erythrocyte sedimentation rate, and C-reactive protein are all normal. Cerebrospinal fluid analysis reveals slightly elevated protein, with elevated immunoglobulin G and oligoclonal bands on further analysis. MRI of the brain is shown in Figure 10-2.

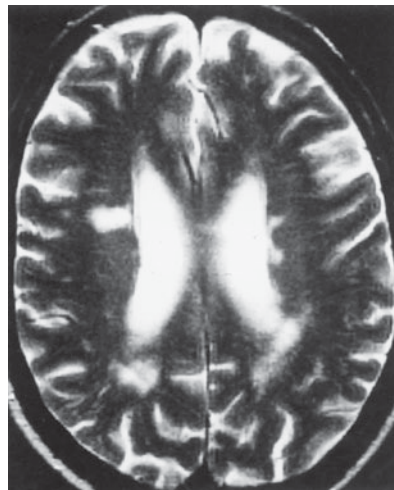


FIGURE 10-2. (Reproduced, with permission, from Ropper AH, Brown RH. *Adams and Victor's Principles of Neurology*, 8th ed. New York: McGraw-Hill, 2005: Fig. 36-1.)

■ **What is the most likely diagnosis?**

Multiple sclerosis (MS). MS is an idiopathic inflammatory demyelinating disease of the central nervous system. This disease more frequently affects women of northern European descent who are of childbearing age. As seen in Figure 10-2, MS is characterized pathologically by multifocal areas of demyelination (often periventricular) with relative preservation of axons, loss of oligodendrocytes, and astroglial scarring. MS has a highly variable presentation and remains a clinical diagnosis made by the combination of history and physical and laboratory and radiological examinations. MS is an autoimmune disease of unclear etiology (it is thought that stimulation of the immune system by a viral infection may trigger the disease). Typical presenting features include optic neuritis, internuclear ophthalmoplegia, Lhermitte's phenomenon (electric shock-like sensations radiating down the spine or into the limbs with flexion of the neck), nystagmus, and pain. Psychiatric symptoms are not uncommon.

■ **What conditions should be included in the differential diagnosis?**

The differential diagnosis is limited in a young patient who presents with a history of two or more clinically distinct episodes of CNS dysfunction with at least partial resolution. This diagnosis becomes difficult when a patient presents with atypical symptoms. In general, the differential includes inflammatory diseases (acute disseminated encephalomyelitis, polyarteritis nodosa, lupus), infectious diseases (HIV, neurosyphilis, Lyme disease), granulomatous disease (sarcoidosis, Wegener's granulomatosis), other primary myelin diseases (e.g., adrenoleukodystrophy), and others such as Arnold-Chiari malformation, vitamin B₁₂ deficiency, and arteriovenous malformation.

■ **What criteria are used to diagnose this condition?**

The McDonald criteria are now the most commonly used for diagnosing MS (see Table 10-1) and are based on both clinical and MRI findings.

■ **What is the most appropriate treatment for this condition?**

IV steroids have been shown to reduce the duration and severity of an acute flare, but probably do not change overall disease progression. Specific immunomodulatory agents used to treat MS include: interferon β_{1a} (Avonex and Rebif), interferon β_{1b} (Betaseron), glatiramer acetate (Copaxone), and mitoxantrone (Novantrone). Since the course is typically progressive, symptomatic therapy for depression, spasticity, urinary incontinence/retention is imperative.

TABLE 10-1. McDonald Criteria for Diagnosing Multiple Sclerosis

CLINICAL SIGNS AND SYMPTOMS	ADDITIONAL DATA NEEDED TO DIAGNOSE MULTIPLE SCLEROSIS
≥ 2 attacks plus objective evidence of ≥ 2 lesions	None, although MRI of the brain is recommended to exclude other etiologies.
≥ 2 attacks plus objective evidence of 1 lesion	Evidence of dissemination in space as shown by any one of the following: <ul style="list-style-type: none"> ■ MRI ■ ≥ 2 lesions detected on MRI that are consistent with MS plus positive CSF findings* ■ Observation until another clinical attack implicates a different lesion
1 attack plus objective clinical evidence of ≥ 2 lesions	Evidence of dissemination in time as shown by any one of the following: <ul style="list-style-type: none"> ■ MRI ■ Second clinical attack
1 attack plus objective clinical evidence of 1 lesion (clinically isolated syndrome)	Evidence of dissemination in time as shown by any one of the following: <ul style="list-style-type: none"> ■ MRI ■ Second clinical attack AND Evidence of dissemination in space as shown by any one of the following: <ul style="list-style-type: none"> ■ MRI ■ ≥ 2 lesions detected on MRI that are consistent with MS plus positive CSF findings*
Insidious neurologic progression suggestive of MS	One year of disease progression (determined either retrospectively or prospectively) AND Any two of the following: <ul style="list-style-type: none"> ■ Positive MRI of the brain (≥ 9 T2 lesions or ≥ 4 T2 lesions with positive visual evoked potentials) ■ Positive MRI of the spinal cord (≥ 2 focal T2 lesions) ■ Positive CSF findings*

*Positive cerebrospinal fluid (CSF) findings include oligoclonal bands different from those in serum, or a raised IgG index.

► CASE 15

A 30-year-old woman presents to her primary care physician complaining of double vision and fatigue. Her symptoms are absent in the morning but become progressively worse by the end of the day. Physical examination reveals a heart rate of 90/min and a blood pressure of 115/75 mm Hg. Ophthalmologic examination is remarkable for symmetric ptosis and intact pupillary responses bilaterally. Weakness of the muscles of the hand is evident bilaterally, but only after multiple contractions. Sensory exam is completely normal and deep tendon reflexes are intact.

-
- **What is the most likely diagnosis?** Myasthenia gravis (MG). Hallmarks include progressive weakness and fatigability of striated muscles; proximal muscles are most often affected, and weakness in ocular muscles results in ptosis and diplopia. MG can occur at any age, but is most commonly seen in women during the third and fourth decades and in middle-aged men. It is associated with other autoimmune disorders and hyperthyroidism. The differential diagnosis includes Lambert-Eaton myasthenic syndrome (LEMS), an autoimmune disorder that is often a paraneoplastic condition in which antibodies are produced against presynaptic voltage-gated calcium channels; this results in less calcium entry into the presynaptic terminal and thus less release of acetylcholine (ACh) into the neuromuscular junction. Associated symptoms include depressed or absent reflexes and increasing amplitude of responses on repetitive nerve stimulation.

 - **What is the pathophysiology of this disorder?** MG is a disorder of the neuromuscular junction (NMJ) in which autoantibodies to the ACh receptor effectively blunt the depolarization of the muscle endplate. The phenomenon of “myasthenic fatigue” is due to the fact that on repeated activation of the NMJ and release of ACh, there are fewer available ACh molecules released and fewer receptors for the ACh molecules to bind. The sensory nerves are unaffected, and deep tendon and pupillary reflexes are preserved.

 - **What tests and/or imaging tools could be used to confirm the diagnosis?** A rapid diagnosis can be made with the edrophonium test. This fast-acting acetylcholinesterase inhibitor will cause a transient resolution of symptoms in the myasthenic patient as more ACh is available in the cleft. Repetitive nerve stimulation tests will demonstrate a characteristic decrement of evoked compound muscle action potential (CMAP) amplitude. Antibody tests can confirm the diagnosis and are used to follow treatment response. Eighty percent of patients with general myasthenia have ACh receptor antibodies, and 5% have antibodies to muscle-specific kinase (anti-MuSK). A CT of the chest is recommended, since 15% of MG patients also have an associated thymoma.

 - **What is the most appropriate treatment for this condition?** Acetylcholinesterase inhibitors (pyridostigmine) are first-line treatment; these medications inhibit the enzyme that degrades ACh (acetylcholinesterase) and allow ACh to build up in the neuromuscular junction. In patients with associated thymoma, thymectomy may be curative. If symptoms persist, immunosuppressive therapy is initiated, primarily with corticosteroids and immunosuppressants.

 - **What is a potential complication of this condition and how is it managed?** Myasthenic crisis is a serious complication characterized by severe weakness and respiratory and pharyngeal muscle paresis leading to respiratory failure. It may occur spontaneously or after physiologic stress (infection/surgery). Management consists of early elective intubation, withdrawal of anticholinergic medication, and plasmapheresis or intravenous immunoglobulin.
-

► **CASE 16**

A 9-year-old boy is brought to the pediatrician's office because his parents have become concerned about his unusual behavior over the past 2 days. The patient's mother states that over the past 2 days her son has had several episodes of sudden alteration in behavior. He first complains of a rising feeling in his stomach and becomes fearful. He begins to have difficulty speaking, and then begins to stare and seems to lose awareness of what he is doing. He starts making strange lip-smacking movements, and assumes awkward postures with his right hand and arm. These episodes last about 30 seconds to 1 minute. As soon as an episode is over, the patient becomes tired and confused for a few minutes and does not seem to recall the event afterward. The patient is in good health, and all of his developmental milestones were normal. Obstetric history is unremarkable. He did, however, suffer from a prolonged episode of convulsions as a child in the setting of a febrile illness. On examination, the patient is well appearing. Height, weight, and head circumference are appropriate for his age. Physical examination reveals no rashes or other skin lesions. The patient is afebrile, and all vital signs are stable. Neurologic examination is normal, as is an MRI of the head. Electroencephalography (EEG) demonstrates left temporal slowing with occasional spikes and sharp waves.

-
- | | |
|--|--|
| <p>■ What is the most likely diagnosis?</p> | <p>Partial complex seizures. Seizures are the clinical expression of excessive, abnormal, synchronous discharges of neurons residing primarily in the cerebral cortex. Partial seizures are those in which clinical presentation suggests origin in a specific brain region. In this patient, the symptoms of an epigastric rising sensation and fearfulness, followed by staring, oral automatisms, and dystonic posturing all strongly suggest partial seizures with a temporal lobe focus. This diagnosis is further supported by his EEG findings. Complex partial seizures are those in which the patient has impaired awareness during the episode. This is demonstrated by the patient's lack of memory for the seizure events. Simple partial seizures are those that do not impair consciousness.</p> |
| <p>■ What are the typical clinical findings associated with this condition?</p> | <p>Partial seizures can present in a variety of ways, depending on the brain region in which they originate. Motor symptoms (e.g., rhythmic movements or tonic contracture of a limb or the face), sensory symptoms (paresthesias; vertigo; and gustatory, olfactory, auditory, and visual sensations), and autonomic symptoms (sweating, piloerection, pupillary changes) can all occur.</p> |
| <p>■ What is the etiology of this condition?</p> | <p>There are many causes of seizures; careful history is required to determine the underlying cause. Some seizures are idiopathic with no specific cause. Secondary seizures are either cryptogenic if the cause is unknown or symptomatic if the cause is known. Causes include metabolic (e.g., hypocalcemia, hyponatremia, hypoglycemia), cortical injury (e.g., head trauma, ischemia), infection (sepsis, meningitis, encephalitis, fever from any source), bleeding (intraparenchymal or subarachnoid hemorrhage), or chronic disturbance of neurologic function (perinatal asphyxia, in-utero stroke, genetic syndrome, tumor).</p> |
-

- **What tests and/or imaging tools could be used to confirm the diagnosis?**

MRI is the imaging study with the greatest sensitivity to detect focal brain lesions associated with the seizure focus. Single photon emission computed tomography (SPECT) is an emerging approach used in conjunction with EEG that can often demonstrate areas of increased perfusion during an EEG documented seizure episode. An EEG should be performed in every patient in whom there is suspicion of seizure; the EEG is abnormal about 50% of the time within 24 hours of last seizure activity. In patients with a strong suspicion of seizure and a negative EEG, a sleep-deprived EEG may demonstrate epileptiform abnormalities.

-
- **What is the most appropriate treatment for this condition?**

Anticonvulsant therapy is indicated in all patients who have more than one unprovoked seizure. Criteria for withdrawal of anticonvulsant therapy include being seizure free for 2 years while on medication, having a single type of partial or general seizure, and a normal neurologic examination and EEG. Because there are many side effects of anticonvulsant therapy, patient education is of special importance, and periodic monitoring of pertinent laboratory parameters (e.g., liver function tests with Depakote) may be warranted prior to and/or during the course of treatment.

► **CASE 17**

A 62-year-old woman is brought to the emergency department (ED) by ambulance because she is experiencing weakness and language disturbances. She and her husband were having dinner when she suddenly stopped speaking, slumped to her right side, and slid to the floor. She was unable to get off of the floor because she could not move her right side. He also noted that that she neither spoke nor seemed to understand what he was saying. Approximately 45 minutes passed from the onset of symptoms to the time the patient was evaluated in the ED. Past medical history is significant for poorly controlled hypertension and stable angina. Her husband recalled that she had not taken her antihypertensive medication for several days. The patient smokes two packs of cigarettes per day. Family history is significant for hypertension and coronary artery disease. The patient's father died at age 58 of a heart attack. On physical examination, the patient is afebrile, has a blood pressure of 168/94 mm Hg, a heart rate of 70/min, and a respiratory rate of 18/min. Medications include a baby aspirin and atenolol. A mental status examination reveals the patient to be globally aphasic. She cannot produce fluent speech, follow commands, repeat phrases, or name objects. Her gaze is deviated to the left. She does not blink to visual threat on the right side, and cranial nerve examination reveals a right-sided central pattern of facial weakness. Strength is 0/5 in the right upper extremity and 5/5 on the left. Strength is 0/5 in the right lower extremity and 5/5 on the left. In response to noxious sensory stimulation, she does not move her right side, but readily moves her left side with good strength. Laboratory examination including complete blood count and blood chemistries are within normal limits.

-
- **What is the most likely diagnosis?** Acute ischemic stroke. While some other processes such as seizures, syncope, migraine, and hypoglycemia can at times mimic brain ischemia, this patient's constellation of signs and symptoms in addition to her history make acute ischemic stroke the overwhelming likely diagnosis. In this patient presenting with global aphasia, a left-deviated gaze, and right-sided motor and sensory losses, an ischemic stroke involving the left middle cerebral artery is the most likely cause of the patient's symptoms. Stroke is characterized by the sudden loss of circulation to an area of the brain, resulting in a corresponding loss of neurologic function. Strokes are either ischemic (80%) or hemorrhagic (20%), and the same risk factors can lead to either type. There are an estimated 750,000 new strokes every year. Stroke is the third leading cause of death in the United States and the leading cause of disability. Strokes can occur at any age but are much more common in the elderly, with the death rate doubling every 10 years between the ages of 55 and 85.
-
- **What risk factors are associated with an increased incidence of this condition?** Key risk factors include family history, a previous stroke, hypertension, dyslipidemia, atrial fibrillation, diabetes, heart disease, carotid stenosis, cocaine use, and smoking. Age, race (blacks are at higher risk), and gender (males are at higher risk than females) are also important.
-

■ **What are the typical radiographic findings associated with this condition?**

In the acute setting, noncontrast CT scan of the head is typically used to differentiate a hemorrhagic from an ischemic stroke. Typical early signs of brain ischemia seen on CT include hypoattenuation of ischemic brain tissue, obscuration of the lentiform nucleus, focal parenchymal attenuation, and loss of gray-white differentiation in the basal ganglia. In particular, the earliest indication of infarction is the “insular ribbon sign” (see Figure 10-3), which is caused by edema within the left insular cortex and basal ganglia. Brain MRI can also be used very effectively to identify and differentiate acute ischemic and hemorrhagic stroke. In particular, diffusion-weighted imaging is a particularly sensitive sequence for detecting evidence of acute or subacute ischemic strokes, while the gradient echo sequence identifies hemorrhagic stroke.

■ **What is the most appropriate treatment for this condition?**

Management of acute stroke begins with stabilization of the patient and minimizing risk of further damage. Maintaining adequate ventilation, fluid resuscitation, and cerebral perfusion is essential for helping to minimize ischemic injury to damaged and at-risk areas of the brain. For patients who qualify, intravenous thrombolytic therapy (IV tPA) offers the best chance of restoration of blood flow and recovery of ischemic brain tissue in patients with acute ischemic stroke. Eligibility criteria include clinical diagnosis of ischemic stroke, symptom onset < 3 hours, and those with a measurable neurologic deficit. Interventional (i.e., intra-arterial) therapies with thrombolytics and the use of mechanical clot removal devices may be employed in certain patients who have an identified large-vessel occlusion and are beyond the window for IV tPA or in whom IV tPA has failed. Aspirin should be started within 24–48 hours after symptom onset (although must wait 24 hours in patients who received IV tPA). Workup usually includes ECG, echocardiogram, and carotid imaging. Stroke risk factors must be managed to decrease risk of future events.

■ **What are the contraindications of thrombolytics?**

IV thrombolytic therapy is contraindicated in patients with significant risk factors for bleeding such as uncontrollable systolic blood pressure > 185 or diastolic blood pressure > 110, recent history of stroke/myocardial infarction/head trauma in the past 3 months, major surgery within the past 14 days, GI/GU bleeding in the past 21 days, any history of intracranial hemorrhage and thrombocytopenia or active therapeutic anticoagulation.

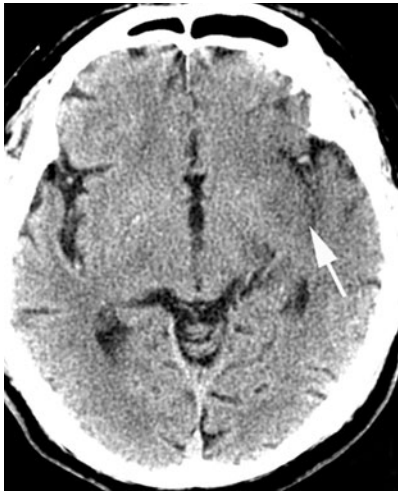

FIGURE 10-3. The “insular ribbon sign” in early cerebral infarction, which is caused by edema (darker signal) within the left insular cortex and basal ganglia (arrow). (Reproduced, with permission, from Kasper DL, Braunwald E, Fauci AS, Hauser SL, Longo DL, Jameson LJ, Isselbacher KJ, eds. *Harrison’s Principles of Internal Medicine*, 16th ed. New York: McGraw-Hill, 2005: Fig. 349-12).

► **CASE 18**

A 65-year-old man presents to a neurologist complaining of a resting tremor. He is accompanied by his wife, who points out that her husband has been moving much more slowly, has not been sleeping well, and has been depressed and anxious. During the interview, the patient speaks in a low tone without facial expression, and his left hand has a resting tremor involving the fingers and wrist. Physical examination reveals a wide-based, shuffling gait without arm swing. Passive movement of the arms demonstrates uniform resistance to movement with a ratchet-like quality. His temperature is 37°C (98.6°F), heart rate is 90/min, and blood pressure is 140/85 mm Hg.

-
- **What is the most likely diagnosis?** Parkinson's disease (PD). PD, the most common of the bradykinetic disorders, is idiopathic and usually presents after age 50. The diagnostic tetrad includes: (1) resting tremor (usually unilateral at onset, with a "pill-rolling" quality), (2) rigidity (especially the "cogwheel" type described above), (3) bradykinesia (overall slowness with difficulty initiating movement), and (4) postural/gait instability. Other manifestations are micrographia, hypophonia, masked facies, memory loss, and other neuropsychiatric symptoms (particularly depression and sleep disorder).

 - **What is the pathophysiology of this condition?** PD affects the basal ganglia circuitry. Specifically, dopaminergic cells in the substantia nigra pars compacta (which project to the striatum) slowly degenerate and develop Lewy bodies (cytoplasmic inclusion bodies filled with α -synuclein), with a loss of pigmented cells seen on gross pathology. Dopaminergic input to the striatum facilitates movement.

 - **What conditions should be included in the differential diagnosis?** Other causes of parkinsonism, while distinctly less common, include progressive supranuclear palsy, multisystem atrophy, and corticobasilar degeneration. Secondary parkinsonism can be ischemic, postencephalitic, or secondary to neuroleptics, toxins, or other medications.

 - **What comorbid conditions are associated with this condition?** Common conditions include psychosis, sleep disturbances, and depression. The incidence of dementia in PD patients is six times higher than in the general population. Diagnosis and management of these conditions is complicated because many of these symptoms are side effects from the dopaminergic or anticholinergic medications, and because typical antipsychotic agents can exacerbate parkinsonism.

 - **What is the most appropriate treatment for this condition?** Treatment in PD focuses on replenishing dopamine. Dopamine agonists, such as pramipexole, ropinirole, and pergolide, act directly on the striatum, while levodopa is a dopamine precursor with a shorter half-life. The addition of carbidopa in the levodopa preparation prevents peripheral decarboxylation and minimizes adverse effects, such as nausea and orthostasis. Long-term use of levodopa is associated with motor fluctuations and dyskinesias. Alternative agents that can be used concomitantly with dopamine include monoamine oxidase type B inhibitors (selegiline, which may be neuroprotective) and catechol O-methyltransferase inhibitors (entacapone). Anticholinergic medications (benztropine) and the antiviral amantadine are also useful in younger patients with tremor. Surgical options include deep brain stimulation or, less frequently, pallidotomy.
-

► **CASE 19**

A 75-year-old man presents to his neurologist with difficulty walking. His gait has become progressively more spastic and ataxic over the past several months, and he reports increased problems with fatigue and forgetfulness. He has lived in a residential facility for the past 5 years and complains that the food is terrible, so he has been eating very poorly. He is otherwise very healthy and takes no medications or supplements. On physical examination, his vital signs include a temperature of 36.3°C (97.4°F), pulse of 99/min, and blood pressure of 120/80 mm Hg. He is alert and oriented but scores 25/30 on the Mini Mental Status Examination (MMSE). Neurologic examination is significant for 4+/5 strength in the bilateral lower extremities, 5/5 in the bilateral upper extremities, a positive Romberg test, and increased muscle tone in the lower extremities. On sensory testing, there are notable deficits in fine discriminative touch, vibration and conscious proprioception but retained pain and temperature sensation in the lower extremities. The remainder of his examination is within normal limits. A complete blood count (CBC) reveals hemoglobin of 8.3 g/dL, hematocrit of 26%, and mean corpuscular volume (MCV) of 110 fl. Hypersegmented neutrophils are visible on peripheral smear.

-
- **What is the most likely diagnosis?** Subacute combined degeneration secondary to vitamin B₁₂ (cobalamin) deficiency. He has a macrocytic anemia with hypersegmented neutrophils and neurologic symptoms, suggesting the disease has progressed to spinal cord dysfunction. B₁₂ deficiency is also a treatable cause of dementia, suggesting that his MMSE score might improve with treatment. B₁₂ deficiency often coexists with folate deficiency (in addition, folic acid deficiency can cause falsely low serum vitamin B₁₂ levels), so patients should be evaluated for both conditions.

 - **What is the most appropriate next step in management?** The first step in the workup is to draw blood for folate and B₁₂ levels (note that a single hospital meal or blood transfusion can normalize these values temporarily). Normal B₁₂ level is > 400 pg/mL; levels < 100 pg/mL confirm B₁₂ deficiency. With an intermediate level (100–400 pg/mL), checking homocysteine and methionine levels can confirm the diagnosis as one or both will be elevated in the setting of B₁₂ deficiency.

 - **What is the pathophysiology of this condition?** B₁₂ is ingested in meat and dairy products in the diet and binds to R factor in the stomach, preventing gastric degradation. Pancreatic proteases free the B₁₂ from R factor in the duodenum, where it binds intrinsic factor (IF), secreted by the gastric parietal cells. The B₁₂-IF compound is absorbed in the ileum after binding to specific receptors. Disruption of any of these steps can lead to B₁₂ deficiency. B₁₂ is stored in the body, especially in the liver, so it may take several years for deficiency to become clinically significant.

 - **What are the common neurologic symptoms of this condition?** Subacute combined degeneration is due to dysfunction of the dorsal columns and corticospinal tracts in the spinal cord; B₁₂ deficiency leads to defects in myelin formation, but the exact mechanism is unknown. Patients present with a symmetrical neuropathy affecting the legs more than the arms. Early symptoms include paresthesias and ataxia; the disease can progress to weakness, spasticity, clonus, paraplegia, and fecal and/or urinary incontinence.
-

■ **What risk factors are associated with an increased incidence of this condition?**

- Strict vegetarian diet.
- Malabsorption (pernicious anemia, gastric surgery, chronic atrophic gastritis, etc.).
- Alcoholism in the elderly (poor intake).
- Nitrous oxide exposure (inactivates cobalamin; must check cobalamin levels prior to using for anesthesia).

■ **What is the most appropriate treatment for this condition?**

Most cases, especially those in which disease has progressed to subacute combined degeneration, are treated initially with intramuscular B₁₂, 1 mg daily for one week, followed by 1 mg weekly for 4 weeks, then 1 mg monthly indefinitely. Some patients can be switched to oral or nasal formulations. Patients with concurrent folate deficiency should also receive oral folate supplements.

► **CASE 20**

A 56-year-old man is brought to the emergency department (ED) by a coworker after suffering from severe headache, nausea, and vomiting over the past 2 hours. The patient was sitting at his desk when he suddenly developed a knifelike headache that he states is “10 out of 10” in intensity. He has never had a headache like this before. Shortly after headache onset, the patient became nauseous and vomited a few times before insisting that he be brought to the ED. On presentation to the ED, the patient is increasingly drowsy and is having difficulty answering questions. He denies any recent illness, head trauma, or history of migraine. He smokes one pack of cigarettes per day but denies any alcohol or intravenous drug abuse. His temperature is 37°C (98.6°F), heart rate is 86/min, respiratory rate is 14/min, and blood pressure is 126/60 mm Hg. The patient has no back or neck pain. WBC, blood chemistry, and coagulation laboratory values are all within normal limits. His neurologic examination is notable for a sluggishly responsive pupil on the right.

■ What conditions should be included in the differential diagnosis?	In a patient with a history of nontraumatic acute onset severe headache, the differential should include migraine, cluster headache, subarachnoid hemorrhage, meningitis, encephalitis, temporal arteritis, and stroke. While a primary headache such as migraine is common and would present with similar symptoms, new-onset headache in a patient over 50 years old is a red flag that another, more serious etiology may be the cause of headache.
■ What is the most likely diagnosis?	Subarachnoid hemorrhage (SAH). This patient’s presentation of acute-onset severe headache (often described as the “worst headache ever”), nausea, vomiting, and confusion in the absence of abnormal laboratory findings is classic for SAH. Most SAHs are caused by a ruptured saccular (berry) aneurysm. In this case, the patient has an aneurysm of the right posterior communicating artery leading to compression of the right third nerve with resultant papillary dysfunction. Other causes include trauma, arteriovenous malformations, vasculitis, amyloid angiopathy, intracranial arterial dissection, and illicit drug use.
■ What risk factors are associated with an increased incidence of this condition?	Major risk factors for SAH include family history of SAH, cigarette smoking, alcohol abuse, hypertension, and estrogen deficiency. Risk factors for saccular aneurysms include chronically elevated blood pressure and conditions that weaken blood vessel walls (e.g., connective tissue disorders, infections); other notable risk factors include coarctation of the aorta and autosomal dominant polycystic kidney disease.
■ What tests and/or imaging tools could be used to confirm the diagnosis?	The mainstay of diagnosis is a noncontrast CT scan of the head. Noncontrast CT scan is a sensitive diagnostic tool and detects 92% of bleeds in the subarachnoid space within the first 24 hours. Patients in whom there is a strong suspicion of SAH but a negative CT scan of the head should have a lumbar puncture. Classically, this will demonstrate an increased number of red blood cells in the cerebrospinal fluid (CSF). Centrifugation of the CSF will demonstrate xanthochromia (an amber or pink hue) in the supernatant that results from the degradation of hemoglobin.

- **What is the most appropriate treatment for this condition?**

Patients with SAH are admitted to an intensive care unit for continuous monitoring. Major complications following a subarachnoid hemorrhage include rebleeding, vasospasm, hydrocephalus, and seizures. Tight blood pressure control is important for minimizing risk of rebleeding. Nimodipine (a calcium channel blocker) is helpful for preventing complications from vasospasm in cases of SAH caused by aneurysm. An antiepileptic is given for seizure prophylaxis. Once the patient is stabilized and the source of the hemorrhage is found, definitive treatment is recommended. Treatment involves either surgical clipping or endovascular coiling, depending on the location and morphology of the aneurysm.

► **CASE 21**

A 78-year-old woman is found by her son lying at the bottom of the stairs in their house where they live together. After calling for an ambulance, the patient is brought to the emergency department for further evaluation. The son is not sure how long his mother was at the bottom of the stairs, but suspects that she must have fallen while attempting to descend the stairs. He states that she does not smoke or drink, and that she is fairly healthy except for a history of hypertension, for which she takes atenolol, and hip arthritis, for which she takes ibuprofen. The patient is unresponsive except to painful stimuli. The right pupil is 4 mm and sluggishly reactive, and the left pupil is 3 mm and reactive to 2 mm. Painful stimulation of the right lower and upper extremities elicits movement, whereas painful stimulation of the left produces no response. A Babinski reflex test elicits downgoing toes on the right and upgoing toes on the left. Vital signs include a temperature of 37°C (98.4°F), heart rate of 90/min, respiratory rate of 16/min, and blood pressure of 135/75 mm Hg. CBC and blood chemistry values are within normal limits. The patient undergoes a noncontrast CT scan of the head, as shown in Figure 10-4.

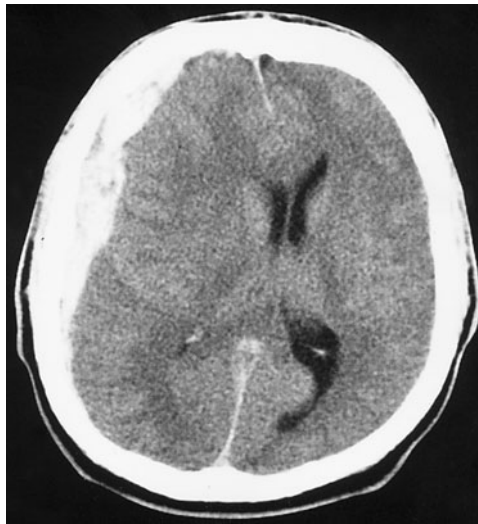

FIGURE 10-4. (Reproduced, with permission, from Kasper DL, Braunwald E, Fauci AS, Hauser SL, Longo DL, Jameson LJ, Isselbacher KJ, eds. *Harrison's Principles of Internal Medicine*, 16th ed. New York: McGraw-Hill, 2005: Fig. 357-3.)

■ **What is the most likely diagnosis?**

Subdural hematoma (SDH). A history of head trauma, diminished consciousness, and focal neurologic deficit, combined with CT findings consistent with hemorrhage forming a crescent-shaped lesion, is consistent with SDH. SDH is a collection of blood found between the dura mater and arachnoid membrane. Frequency is directly related to the incidence of blunt head trauma. SDH is the most common type of intracranial mass lesion, occurring in about a third of those with severe head injuries. Mortality is related to associated brain parenchymal injury, which when present increases mortality from 20% to 50%.

<ul style="list-style-type: none"> ■ What are the typical clinical findings associated with this condition? 	<p>SDH has a variable clinical presentation based on size and location of the lesion, speed of progression, and associated injuries to the brain parenchyma. While most patients immediately become unconscious or suffer a decline in consciousness, in some cases patients do not present until clinical decompensation occurs weeks after the initial trauma. Most symptoms associated with SDH are associated with increased intracranial pressure and mass effect of the lesion causing compression of the underlying brain parenchyma. Other typical findings may include an ipsilateral dilated and/or nonreactive pupil, contralateral hemiparesis, papilledema, and cranial nerve VI palsy (either unilateral or bilateral) from mass effect impingement of the abducens nerve somewhere along its long subarachnoid course (the latter is an example of a “false-localizing sign”).</p>
<ul style="list-style-type: none"> ■ What risk factors are associated with an increased incidence of this condition? 	<p>SDH is most common in people > 60 years old. With age-associated brain atrophy, there is thought to be an increase in tension on the bridging dural veins, leading to a greater risk of tearing during head trauma, which may be negligible. Other risk factors include coagulopathies and alcoholism.</p>
<ul style="list-style-type: none"> ■ What imaging studies could be used to confirm the diagnosis? 	<p>Both MRI and CT scan of the head are useful in diagnosing subdural hematoma. While MRI is superior for demonstrating the size of an acute SDH and its effect on the brain, noncontrast head CT remains the test of choice in the urgent care setting. On CT, acute SDH classically presents as a hyperdense (white) crescentic mass along the inner table of the skull, most commonly over the cerebral convexity in the parietal region (see Figure 10-4). A unilateral SDH does not cross the midline, but, not uncommonly, blood collection can also be seen just above the tentorium cerebelli.</p>
<ul style="list-style-type: none"> ■ What is the most appropriate treatment for this condition? 	<p>Initial management focuses on hemodynamic stabilization and management of life-threatening issues. In patients who are neurologically stable with minimal or no deficits, treatment involves medical management and close monitoring. Definitive surgery (craniotomy and excavation of the underlying hematoma) may be required in less stable patients, patients who have significant neurologic deficits, or those with worsening deficits; Burr hole placement at bedside in rare cases may be necessary in the setting of imminent death from herniation.</p>

► **CASE 22**

A 27-year-old man is having breakfast with his wife when suddenly he arches his back, turns his head to the side, shrieks loudly, and falls to the ground. His arms and legs remain extended for approximately 30 seconds, after which his arms and legs begin to flex and extend rhythmically for the next 2 minutes. The patient's wife calls 911, and on arrival the paramedics find the patient lying on the floor. He appears stuporous but can respond to vocal commands. He has bitten his tongue badly, and is soiled from having lost control of bowel and bladder functions. The patient is confused and appears to have no knowledge of what has happened to him. The paramedics transfer the patient to the ambulance and bring him to the emergency department for further evaluation.

- **What is the most likely diagnosis?** Generalized tonic-clonic seizures (GTCSs) involve both cortical hemispheres, as opposed to a specific seizure focus in one hemisphere (partial seizures). GTCSs may be primary generalized seizures, which originate from both cortical hemispheres simultaneously, or partial with secondary generalization. The latter results from interhemispheric spread of an initially focal seizure. GTCSs typically begin with a short tonic phase in which there is an abrupt loss of consciousness and a stiffening of the muscles of the extremities, chest, and back. Patients may become apneic during this period. The clonic phase is typically longer, consisting of rhythmic muscle jerking and twitching for 1–2 minutes; it is during this phase that patients may bite their tongue. Immediately following the seizure, there may be global relaxation of the body; it is during this phase that patients may be incontinent due to sphincter relaxation. The postictal state begins after the tonic stage and can continue for hours, leaving patients in a stuporous postictal state, unaware of the seizure that occurred.

 - **How is this condition diagnosed?** In patients without a history of epilepsy or seizure, a GTCS can either indicate the new onset of primary epilepsy or may be the consequence of a provoking stimulus (i.e., secondary, or symptomatic, seizure). Potential provoking factors include metabolic derangements, infections, inflammatory conditions, brain injury, drugs, or toxins. A thorough workup must carefully rule out secondary causes of seizure. A good past medical history, neurologic exam, imaging, and laboratory studies are important in making the right diagnosis.

 - **What is the etiology of this condition?** Primary generalized seizures occur in both cerebral hemispheres and are thought to be due to an instability of the thalamocortical circuitry. Partial seizures that secondarily generalize begin with paroxysmal high-voltage electrical discharges of susceptible neurons within a specific epileptogenic focus. This results in excitation that spreads to other cortical areas, but also to subcortical structures via corticothalamic fibers. This in turn leads to the instability of bihemispheric thalamocortical circuitry, resulting in a generalized seizure.

 - **What clinical tests could be used to confirm the diagnosis?** Electroencephalography (EEG) plays an important role in the evaluation of seizures; abnormalities on EEG may be evident in the interictal, ictal, and/or postictal phases. Prolonged monitoring in an epilepsy monitoring unit (EMU) can increase chances of capturing abnormalities. Despite this, interictal EEG is often normal in GTCS patients. Both hyperventilation and sleep deprivation may increase the likelihood of detecting abnormalities on EEG. Imaging studies such as MRI and CT scan can identify a structural lesion or congenital anomaly associated with GTCS.
-

- **What is the most appropriate treatment for this condition?**

A provoked seizure is managed by addressing the underlying etiology. In the interim, anticonvulsant medication can be used to help prevent further seizures. Recurrent seizures define epilepsy and require pharmacologic intervention. There are several antiepileptic drugs, some of which are specific for a particular class of epilepsy. Valproic acid is considered a first-line agent for GTCS. Phenytoin and carbamazepine are good for partial seizures with secondary generalization, but may potentially worsen primary generalized seizures. Many of the relatively newer agents (e.g., lamotrigine, topiramate, zonisamide, and levetiracetam) treat secondarily generalized tonic-clonic seizures as well as primary GTCS.

► **CASE 23**

A 68-year-old African-American man presents to his physician with his daughter, who brought him in due to concerns about his ability to walk. He lives with her and her husband, and over the past 5 months they have noticed him falling and bumping into objects with increasing frequency. The patient complains of shooting pains down both his legs. On physical examination, his vital signs are normal, but he has decreased proprioception and vibratory sense in his lower extremities. He has a wide-based gait, extreme difficulty with heel-toe walking, and a positive Romberg test. He has absent deep tendon reflexes. With his eyes closed, he cannot tell whether his toe is moving up or down, but pain and temperature sensations are intact. His pupils are not reactive to light but do accommodate. There are several plaque-like growths on the inside of his mouth which have ulcerated but are not painful.

-
- **What is the most likely diagnosis?** This patient has tertiary syphilis. The plaque-like growths on the inside of his mouth are gummas, manifestations of tertiary syphilis that most commonly occur in skin, bone, and liver. Other signs can include a murmur due to aortic regurgitation secondary to an aortic aneurysm from years of syphilitic aortitis.
-
- **What tests and/or imaging tools could be used to confirm the diagnosis?** An rapid plasma reagin (RPR) or Venereal Disease Research Laboratory (VDRL) test would detect active syphilis infection whereas fluorescent treponemal antibody absorption test (FTA-ABS) detects any treponemal infection, active or treated.
-
- **What specific neuropathways have degenerated in this patient?** This patient suffers from tabes dorsalis—degeneration of the dorsal roots and dorsal columns in the spinal cord. This causes decreased proprioception, resulting in a positive Romberg test, wide-based gait, and difficulty with heel-toe walking. It also impairs fine discriminative touch and vibratory sensation. Involvement of the pretectum can cause Argyll Robertson pupil, in which pupils do not react to light; however, cortical neurons still connect to the unaffected Edinger-Westfall nucleus, allowing for intact accommodation. Sensorineural deafness can also result from cranial nerve VIII damage.
-
- **What is the epidemiology of this condition?** Since the advent of penicillin, syphilis has been a treatable disease. A nadir of incidence of primary syphilis infections occurred in 2000; since that time, the incidence has increased, primarily in high-risk groups, with significant coinfection rates of HIV and other sexually transmitted diseases. Tertiary syphilis is still uncommon.
-
- **What is the most appropriate treatment for this condition?** For primary syphilis, treatment with 2.4 million units of benzathine penicillin G in one dose is adequate. For latent or tertiary syphilis treatment with gumma/aortic involvement, three doses of 2.4 million units are required over 3 weeks. Any stage of neurosyphilis requires 18–24 million units of aqueous crystalline penicillin G per day for 10–14 days. For late stage neurosyphilis, an additional three doses of 2.4 million units of benzathine penicillin G can be added over 3 weeks.
-

Obstetrics

Case 1	292
Case 2	293
Case 3	294
Case 4	295
Case 5	296
Case 6	298
Case 7	300
Case 8	302
Case 9	303
Case 10	304
Case 11	305
Case 12	306
Case 13	307
Case 14	308
Case 15	309
Case 16	310
Case 17	312
Case 18	313
Case 19	314
Case 20	316
Case 21	317
Case 22	318
Case 23	320
Case 24	321
Case 25	322
Case 26	323
Case 27	324
Case 28	326

► **CASE 1**

A 35-year-old G3P3 woman presents to the office complaining of breast tenderness, bloating, and mild nausea. Her last menstrual period was 6 weeks ago. She is married and has three children under 5 years of age. She uses oral contraceptive pills for birth control. On physical examination, she is afebrile, with a heart rate of 90/min and blood pressure of 140/80 mm Hg. Pelvic examination reveals a normal cervix with a bluish tint. Results of a urine pregnancy test are positive. Transvaginal ultrasound reveals a 6-week-sized gestational sac with detectable fetal heartbeat. The patient is visibly distressed upon hearing about the pregnancy, which she says was unplanned. She says she is overwhelmed with taking care of her three children and does not think she can support another child, financially or emotionally. She says she has considered working with an adoption center, but she was on bed rest for 6 weeks during her last pregnancy and is afraid of the risks and difficulties of carrying this pregnancy to term. She asks for information about abortion.

■ **What types of abortion are available for this patient?**

There are two types of abortion available to this patient: medical and surgical. Medical abortion is available for patients with unwanted pregnancies up to 10 weeks' gestation. Medical abortion uses a combination of mifepristone (formerly known as RU-486) and misoprostol. Mifepristone is a progesterone antagonist administered orally at the provider's office. Two days later misoprostol, a prostaglandin, is taken orally or vaginally, either at the provider's office or at home. Most patients will pass the products of conception at home in the next 4–24 hours.

Surgical abortion is available until 22–24 weeks' gestation (depending on state law), with procedures available in the third trimester to protect the life or health of the mother. The most common surgical abortion procedure is dilation and suction curettage (D&C). The cervix is dilated and the uterine contents are evacuated with electric suction.

■ **What is the epidemiology of abortion?**

Half of all pregnancies every year in America are unplanned, and half of those end in abortion. If current rates continue, 35% of American women will have had an abortion by the time they are 45 years old. Eighty-eight percent of abortions are performed in the first trimester, while only 2% are done after 21 weeks' gestation. Fifty percent of women having an abortion report that they were using birth control at the time of conception.

■ **What are the complications of abortion?**

The most common complications of medical abortion are incomplete abortion or prolonged bleeding, both of which are treated with a suction procedure. The passage of the uterine contents is often uncomfortable, with heavy cramping similar to that experienced during a spontaneous miscarriage. Complications of surgical abortions are rare, but include perforation, infection, and reactions to anesthesia. There is no evidence linking abortion and increased breast cancer risk.

■ **What is the recommended follow-up after an abortion?**

Medical abortion requires a follow-up visit 7–14 days after administration of the mifepristone to ensure that the abortion was completed. Surgical abortion follow-up is usually 2–3 weeks after the procedure. Contraception counseling should be started on the day of the procedure and continued at the follow-up visit.

► CASE 2

A 28-year-old woman presents to her gynecologist to discuss changing her contraceptive method. She has been using condoms with her partner, but they are monogamous and she would like to try something else. She has never been pregnant, but she thinks that she will one day want to have a child. She has never smoked. On physical examination, her heart rate is 80/min and her blood pressure is 130/80 mm Hg. A pelvic examination is unremarkable.

- | | |
|--|---|
| <ul style="list-style-type: none"> ■ What are the major categories of contraceptive methods? | <p>Contraception can be divided into the following categories: permanent, hormonal, barrier, intrauterine, or behavioral. The permanent methods are vasectomy for men and tubal ligation for women. Hormonal methods either have combined estrogen and progesterone preparations or are progesterone only, and can be administered orally, intravaginally, transdermally, intramuscularly, or as part of an intrauterine device (IUD). Barrier methods include condoms, diaphragms, and the cervical cap, while there are two types of IUDs: copper and progesterone secreting. Behavioral methods include abstinence, withdrawal, and fertility awareness methods.</p> |
| <ul style="list-style-type: none"> ■ What considerations should be used to decide on a contraceptive method? | <p>Each woman should decide on the appropriate method based on her own personal preferences and values. Only condoms prevent sexually transmitted infections (STIs), and they should be used when with a new partner. Condoms and diaphragms require placement before each act of intercourse, while hormonal methods and the IUD do not. Oral contraceptives and fertility awareness methods require daily diligence, while methods like the patch, vaginal ring, or injection have weekly, monthly, or seasonal administration, respectively.</p> |
| <ul style="list-style-type: none"> ■ What are some absolute contraindications to contraceptive methods? | <p>Absolute contraindications to combined hormonal contraception include a history of deep venous thrombosis, pulmonary embolus, stroke, coronary artery disease, or hypertension. Women older than 35 years of age who smoke or women with breast cancer should also not use hormonal methods. The contraindications to an IUD are recent pelvic inflammatory disease. A culture for gonorrhea and <i>Chlamydia</i> can be done at the time of insertion and, if positive, treated at that time. Unexplained vaginal bleeding is a contraindication to both methods.</p> |
| <ul style="list-style-type: none"> ■ How is the effectiveness of contraception measured? | <p>Two figures are quoted when describing a method's effectiveness: typical and perfect-use failure rate. Perfect-use failure rate is the percentage of women who will get pregnant after the first year, using the method perfectly all the time. Typical use failure rate is the first-year pregnancy rate seen in epidemiologic studies and reflects actual patterns of effectiveness. The two rates differ most dramatically in methods that require frequent patient involvement. The typical use failure rate should be used when counseling patients about starting a new method.</p> |
| <ul style="list-style-type: none"> ■ What is emergency contraception? | <p>Emergency contraception is best used 3 days after unprotected intercourse, but can be used up to 5 days later, and can reduce the risk of pregnancy by 89%. The only commercially available preparation consists of two pills of high-dose progesterone (levonorgestrel). It does not affect an established pregnancy and should be taken as soon as possible after unprotected intercourse for best results.</p> |
-

► **CASE 3**

A 31-year-old woman develops pain and swelling in her right calf on postoperative day 3 after an uncomplicated cesarean section for placenta previa. She denies any other complaints, including shortness of breath or heart palpitations. Her pain is relatively well controlled, and she has been using her incentive spirometer regularly. On physical examination, the patient is afebrile, heart rate is 88/min, and blood pressure is 125/75 mm Hg. Her right calf is tender, warm to the touch, and noticeably larger than the left calf.

- **What is the most likely diagnosis?** Deep venous thrombosis (DVT). A Doppler ultrasound of the lower extremities should be used to confirm the diagnosis, although there is a high clinical suspicion for this diagnosis given the tenderness, warmth, and asymmetric enlargement of this patient's right calf. A Doppler ultrasound, however, is unable to detect occlusions of the iliac or pelvic veins. Contrast venography is the gold standard for diagnosis of a DVT, with a sensitivity and specificity of almost 100%, and thus it may be used in patients in whom an absolute diagnosis is necessary.

 - **What is the most appropriate treatment for this condition?** Warfarin is the most appropriate long-term anticoagulant therapy. Warfarin, however, is associated with a hypercoagulable state during the first few days after initiation of treatment; this is due to its deactivation of the anticoagulants protein C and protein S prior to its deactivation of the coagulation factors. Therefore, patients are started on intravenous heparin and then switched to oral warfarin once the heparin has reached therapeutic levels. Warfarin therapy for treatment of a postpartum DVT is for at least 6 weeks. Treatment may last for up to 3–6 months.

 - **What is the mechanism of action of this treatment?** Warfarin blocks the actions of vitamin K within the liver, which reduces the production of clotting factors II, VII, IX, and X. This decrease in production impairs the activity of the intrinsic pathway of the coagulation cascade. To reverse the effects of warfarin, vitamin K can be administered orally or intravenously.

 - **Is this treatment contraindicated in breast-feeding mothers?** Warfarin is not a contraindication to breast-feeding, as it is highly bound to plasma proteins and minimally secreted into breast milk. Mothers should be encouraged to breast-feed their infants during the entire course of their anticoagulant treatment, but infants should nonetheless be monitored for signs and symptoms of anticoagulation, such as easy bleeding or bruising.

 - **Is breast-feeding a risk factor for this condition?** No. Breast-feeding alone does not increase a woman's risk of developing a DVT. Pregnancy, however, is a hypercoagulable state, and all women remain at increased risk of thromboembolic events for 6 weeks postpartum.
-

► **CASE 4**

A 34-year-old G3P2 woman at 33 weeks' gestation with a history of hypertension presents to the emergency department complaining of severe pelvic pain and persistent vaginal bleeding. Transvaginal ultrasound reveals a large retroplacental clot. Vital signs are significant for a blood pressure of 170/90 mm Hg, and the fetal heart rate tracing is nonreassuring. The patient is diagnosed with a placental abruption and preeclampsia and undergoes an emergent cesarean section. Postoperatively, the patient is unable to be extubated. Physical examination is notable for petechiae on all four extremities. Relevant laboratory studies are as follows:

WBC count: 9.0/mm³
 Hemoglobin: 8.7 g/dL
 Platelet count: 55/mm³
 Fibrinogen: 100 mg/dL
 Fibrin split products: elevated

■ What is the most likely diagnosis?	Consumptive coagulopathy (disseminated intravascular coagulation [DIC]). The most common obstetric cause for developing DIC is a placental abruption. Up to 10% of women with placental abruptions will manifest some signs of a consumptive coagulopathy. This diagnosis is made by history, presentation, thrombocytopenia, and schistocytes on blood smear. It is confirmed with elevated fibrin degradation products (FDPs) and hypofibrinogenemia.
■ What is the pathophysiology of this condition?	The coagulation cascade may be activated via the extrinsic pathway by thromboplastin from tissue destruction or via the intrinsic pathway by collagen or other tissue components from endothelial damage. With placental abruption, thromboplastin may be released, which triggers the coagulation cascade and in turn triggers fibrinolysis. In DIC, these two processes continue unabated. Platelets and coagulation factors are consumed, which results in severe bleeding, and fibrin is deposited in small vessels, which can lead to hypoperfusion and ischemia as well as a microangiopathic hemolytic anemia.
■ What is the most appropriate treatment for this condition?	Treatments must be directed at the underlying condition to reverse the coagulopathy. If the patient is bleeding or has a high risk of bleeding, platelets and fresh frozen plasma should be given. Heparin should not be given as a treatment for consumptive coagulopathy, as it has no role in reducing morbidity or mortality.
■ What changes in the coagulation cascade normally occur during pregnancy?	Pregnancy normally induces an increase in the concentrations of fibrinogen and coagulation factors VII, VIII, IX, and X. Additionally, plasminogen levels are increased, but plasmin activity antepartum is normally decreased when compared to its activity in the nonpregnant state, thus contributing to the hypercoagulable state of pregnancy.
■ How may elevated fibrinogen levels be protective?	In the third trimester of pregnancy, fibrinogen levels are typically elevated to 300–600 mg/dL. With DIC, these high levels may protect against clinically significant hypofibrinogenemia (defined as < 150 mg/dL).
■ What are fibrin degradation products?	Fibrin degradation products are the by-products that result from the lysis of fibrinogen, fibrin monomers, or fibrin polymers by plasmin.

► **CASE 5**

A 24-year-old G0 woman comes to the emergency department (ED) complaining of left lower abdominal pain and intermittent vaginal bleeding. The patient reports being sexually active with her husband and states that she only intermittently uses contraception. She denies any medical problem but does state that she had a chlamydial infection 7 years ago. Her last menstrual period was 6 weeks ago. On physical examination, the patient is in mild discomfort, with a heart rate of 98/min and a blood pressure of 130/85 mm Hg. Pelvic examination is remarkable for cervical motion tenderness and a closed cervical os. Her β -human chorionic gonadotropin (β -hCG) level is 2000 mIU/mL, and a transvaginal ultrasound is shown in Figure 11-1.

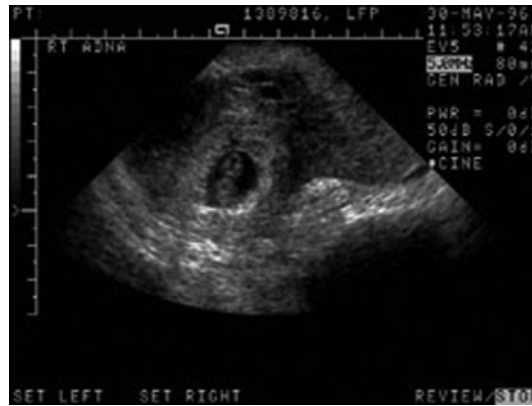

FIGURE 11-1. (Reproduced, with permission, from the Pathology Education Instructional Resource Digital Library [<http://peir.net>] at the University of Alabama, Birmingham.)

-
- | | |
|---|--|
| <p>■ What is the most likely diagnosis?</p> | <p>This patient most likely has an ectopic pregnancy in her left fallopian tube. The positive serum β-hCG suggests that this patient is pregnant, and her clinical symptoms of left abdominal pain and abnormal uterine bleeding suggest an abnormal pregnancy. Figure 11-1 shows an ectopic pregnancy in the right adnexal region.</p> |
| <p>■ What conditions should be included in the differential diagnosis?</p> | <p>Ovarian torsion, appendicitis, normal pregnancy, abortion, ovarian cyst, gastroenteritis, pelvic inflammatory disease.</p> |
-

- What is the appropriate workup if this condition is suspected?
 - An unstable patient requires an immediate surgical consult.
 - A stable patient can undergo transvaginal US (TVUS) to differentiate an intrauterine pregnancy (IUP) from an ectopic pregnancy (EP).
 - In the case of a nondiagnostic TVUS, a quantitative β -hCG should be obtained.
 - **> 1500: above threshold for TVUS to detect IUP**
 - With a suspicious adnexal mass, the patient should be treated for EP.
 - Without a mass, the hCG and TVUS should be repeated in 48 hrs; if no IUP is detected at 48 hrs, the diagnosis is either EP or failed pregnancy.
 - **< 1500: repeat in 72 hours**
 - If hCG doubles, pregnancy is presumed, and she will require serial TVUS to differentiate IUP from EP.
 - If hCG decreases, it is assumed that the pregnancy failed; she can be followed up with weekly hCG measurement.
 - If hCG rises slowly, the diagnosis remains unclear, and she will need a repeat TVUS; if it remains negative, she should be treated for either EP or failed IUP.

- What is suggested by fluid in the cul-de-sac on ultrasound?

The ultrasound finding of fluid in the cul-de-sac in the context of a positive β -hCG in a patient with abdominal pain and abnormal uterine bleeding strongly suggests the rupture of an ectopic pregnancy.

► **CASE 6**

A 31-year-old obese G4P3 woman with a history of gestational diabetes in two of her previous pregnancies is in active labor at 41 weeks' gestation. She had an uncomplicated pregnancy and a negative glucose tolerance test. The patient's membranes spontaneously ruptured 2 hours ago, and she is currently experiencing regular contractions every 2–3 minutes. The patient's vital signs are within normal limits, and her pain is adequately controlled with an epidural. The fetal heart tracing is illustrated in Figure 11-2.

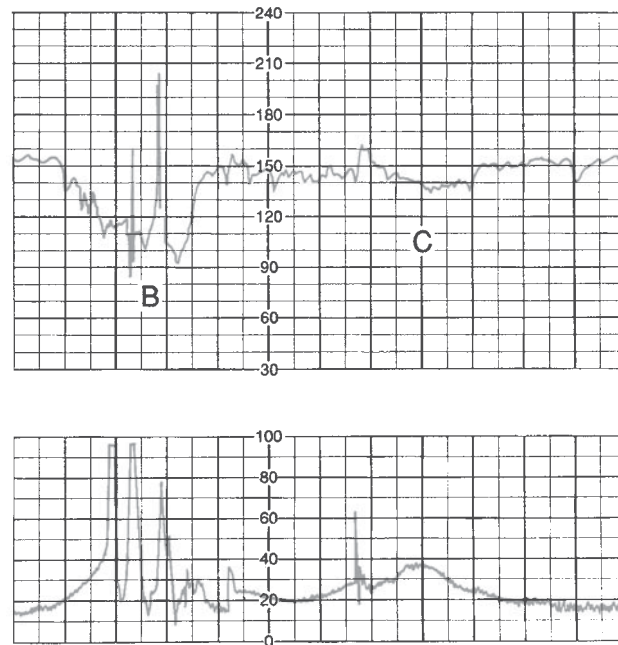


FIGURE 11-2. (Reproduced, with permission, from Cunningham FG, Leveno KL, Bloom SL, Hauth JC, Gilstrap LC III, Wenstrom KD. *Williams Obstetrics*, 22nd ed. New York: McGraw-Hill, 2005: Fig. 18-15).

■ What abnormality is illustrated by “C” on the fetal heart tracing in Figure 11-2?	These are early decelerations. Early decelerations are shallow, symmetric decelerations in which the nadir of the deceleration is simultaneous with the peak of the uterine contraction.
■ What causes this abnormality?	Early decelerations are mediated by vagal stimulation due to fetal head compression from the contracting uterus and thus indicate a normally functioning fetal autonomic nervous system. They are not associated with fetal hypoxia, acidosis, or poor neonatal outcome.
■ What is the most appropriate treatment for this condition?	No specific treatment is necessary, as fetal head compression is not associated with adverse outcomes. Conditions in which fetal oxygenation is compromised, such as with cord compression, require emergent treatment.

- **What is the indication for an amnioinfusion?**

An amnioinfusion is used to prevent or relieve umbilical cord compression during labor when altering the mother's position (from back to side or side to back) is ineffective. Cord compression compromises fetal blood flow and oxygenation. It is manifested by repetitive variable decelerations, not early decelerations, and requires urgent attention.

-
- **What is the indication for a fetal scalp probe?**

A fetal scalp electrode provides a direct measurement of the fetal heart rate tracing. It is inserted transcervically into the fetus's scalp. It is indicated when external fetal heart rate monitoring is inadequate secondary to fetal position or maternal body habitus.

► **CASE 7**

A 37-year-old G4P3 obese woman at 26 weeks' gestation presents to her obstetrician for a routine prenatal visit. She states that diabetes runs in her family. She has no significant past medical history and denies gestational diabetes in her previous pregnancies. She was screened at 10 weeks in this pregnancy and has been receiving routine prenatal care at regular intervals. The results of a 3-hour glucose tolerance test (GTT) are as follows:

Time	Glucose Level (mg/dL)
0 (fasting)	90
1-hour	200
2-hour	170
3-hour	135

-
- **What is indicated by this patient's 3-hour GTT?**

Gestational diabetes. Although this patient does not have a history of diabetes, she is at risk in this pregnancy due to her family history, advanced maternal age, and obesity. A 3-hour GTT indicates gestational diabetes if two of the following are abnormal:

 - Fasting serum glucose > 95 mg/dL
 - 1-hour serum glucose > 180 mg/dL
 - 2-hour serum glucose > 155 mg/dL
 - 3-hour serum glucose > 140 mg/dL
-
- **What risk factors are associated with an increased incidence of this condition?**
 - Family or personal history of diabetes.
 - History of a macrosomic (> 4000 g) or congenitally deformed infant.
 - History of polyhydramnios.
 - History of prior stillbirth.
 - History of recurrent abortions.
 - Maternal age > 35 years.
 - Obesity.
-
- **What causes this condition and when does it usually occur?**

Gestational diabetes is caused by insulin resistance secondary to the anti-insulin effect of hormones from the placenta, such as human placental lactogen or cortisol, and from elevated circulating estrogens and progesterone. It usually occurs later in pregnancy, as the levels of human placental lactogen increase throughout pregnancy. Hyperglycemia that occurs in the first trimester is more often an indication of preexisting diabetes mellitus, and patients should be screened and treated accordingly.
-
- **What is the most appropriate treatment for this condition?**

Tight maternal glucose control decreases both maternal and fetal morbidity and mortality. Mothers with gestational diabetes should start with a diet recommended by the American Diabetes Association and regular exercise. If they are unable to achieve adequate glycemic control, mothers are most commonly placed on insulin therapy, but oral hypoglycemic agents are beginning to be used.
-
- **What common complications are associated with this condition?**

Common complications of gestational diabetes include macrosomia, polyhydramnios, preeclampsia-eclampsia, infections, prematurity, stillbirth, shoulder dystocia, and neonatal demise. While these risks are greater with greater fluctuations of blood glucose levels, they still exist for patients with appropriate glycemic control. Furthermore, approximately 50% of women with gestational diabetes will develop glucose intolerance or type 2 diabetes mellitus later in life.
-

■ **What effects does pregestational diabetes have on the pregnancy?**

Glucose, in excess, is a teratogen for the newly developing fetus, particularly in the first 4–8 weeks of development. Poorly controlled diabetes mellitus, as indicated by an HbA_{1c} level > 8%, carries an increased risk of associated congenital anomalies, including neural tube defects, cardiac cushion defects, and caudal regression syndrome. Patients with known diabetes mellitus are thus counseled to have a normal hemoglobin A_{1c} prior to conception.

► **CASE 8**

An 18-year-old G1 woman at 16 weeks' gestation presents to her obstetrician for severe vomiting. She has difficulty even keeping fluids down and has been vomiting at least 10 times daily. The pregnancy has otherwise been uneventful. On physical examination, her vital signs include a temperature of 37.2° C (99.0° F), heart rate of 110/min, blood pressure of 100/58 mm Hg, and respiratory rate of 15/min. She appears dehydrated, with sunken eyes and tacky mucous membranes. Her uterus is measured at 20 weeks' size; no fetal heart tones can be heard. Transabdominal ultrasound reveals a “snowstorm” pattern.

- | | |
|---|--|
| ■ What is the most likely diagnosis? | Hydatidiform mole. This is an abnormal form of pregnancy, occurring in approximately every 1000 pregnancies in the United States. Clinical characteristics include painless bleeding, an enlarged uterus, very high β -hCG levels, hyperemesis, and a “cluster of grapes” or “snowstorm” on ultrasound. Moles can be partial or complete; a partial mole may contain some fetal parts, but the fetus is never viable. |
| ■ What is the pathogenesis of this condition? | Moles all contain improper combinations of parental genes. Complete moles typically arise when an empty egg is fertilized by a single sperm, which then duplicates its DNA; therefore, complete moles contain entirely paternal DNA. Partial moles are generally triploid and result when a normal (haploid) egg is fertilized by two sperm. The conceptus implants in the uterus but does not develop properly. There is trophoblastic hyperplasia, and the chorionic villi become filled with fluid, leading to the macroscopic appearance of “grapes.” |
| ■ What is the most appropriate treatment for this condition? | Hydatidiform moles should be removed as soon as they are diagnosed, due to the small but clinically significant risk of conversion to choriocarcinoma. The uterus is evacuated by suction and surgical curettage. Patients are followed with weekly β -hCG levels, which should fall to undetectable levels if the mole was completely removed. Invasive moles are treated with methotrexate or other chemotherapy. |
| ■ What is the prognosis for patients with this condition? | In more than 80% of patients, hydatidiform moles are benign and completely removed upon uterine evacuation. These patients are advised to wait one year prior to conceiving again, and their risk of another molar pregnancy is ~1%. In 10–15% of patients, the mole is invasive, necessitating chemotherapy in addition to uterine evacuation; these patients are at increased risk for uterine hemorrhage or rupture. In 2–3% of patients, the mole undergoes malignant conversion to choriocarcinoma; their long-term survival remains excellent with current chemotherapy. |
-

► **CASE 9**

A 32-year-old G2P1 woman presents to her obstetrician at 12 weeks' gestation for a screening visit. Her past medical history is unremarkable, and her routine prenatal laboratory studies are all within normal limits. Urine dipstick analysis is negative for glucose and for protein. On physical examination, she is found to have a temperature of 35.1° C (98.7° F), a heart rate of 92/min, and a blood pressure of 130/100 mm Hg. Two weeks later, the patient returns to the office and reports no complaints. Her blood pressure at that time is 140/112 mm Hg.

- | | |
|---|---|
| ■ What is the most likely diagnosis? | Chronic hypertension is hypertension present before conception and at < 20 weeks' gestation or that persists for > 12 weeks postpartum. This is differentiated from pregnancy-induced hypertension, which is idiopathic hypertension without significant proteinuria (< 300 mg/L) that begins in the second half of pregnancy, during labor, or within 48 hours of delivery. Hypertension with proteinuria would be defined as preeclampsia. |
| ■ What risk factors are associated with an increased incidence of this condition? | Patients with chronic hypertension tend to be > 30 years old, obese, and multiparous; they often have other medical problems, such as diabetes or renal disease. The incidence is greater in African-American women and in women with a family history of hypertension. |
| ■ To what complications does this condition predispose the fetus? | The fetus has a 25–30% risk of prematurity and a 10–15% risk of intrauterine growth restriction. There is also increased risk of stillbirth or intrapartum fetal distress due to placental abruption or chronic intrauterine asphyxia. These risks are proportional to the severity of the maternal hypertension. |
| ■ To what complications does this condition predispose the mother? | The primary complication of chronic hypertension in pregnancy is superimposed preeclampsia, which occurs in approximately one-third of patients; these patients tend to deteriorate faster than patients with preeclampsia alone. Additionally, there is an increased risk of placental abruption (0.4–10%) in those with chronic hypertension. |
| ■ What abnormalities are seen on the fetal monitoring strip in the event of a placental abruption? | Late decelerations would be seen; these are due to a central nervous system reflex response to fetal hypoxia. Hypoxia generally results from uteroplacental insufficiency, which is commonly a sign of placental abruption or hypotension. In the case of known maternal hypertension, evidence of late decelerations must prompt the consideration of placental abruption, which may require emergent cesarean section. |
| ■ What is the most appropriate treatment for this condition? | Hypertension with diastolic blood pressures > 110 mm Hg should be treated during pregnancy, as treatment decreases the incidence of both maternal and fetal complications. Methyldopa, a central α -adrenergic agonist, is the only antihypertensive with proven long-term safety for mother and fetus, although β -blockers are also frequently used. Methyldopa reduces total peripheral resistance without causing physiologically significant changes in heart rate or cardiac output. |

► **CASE 10**

A 30-year-old G0 woman with a past medical history significant for dysmenorrhea presents to the infertility clinic with her husband for a follow-up visit. The couple has been trying to get pregnant for the past 3 years but has not had any success. A semen analysis and a hysterosalpingogram, as well as estrogen, progesterone, and follicle-stimulating hormone blood levels were all normal. A recent pelvic ultrasound revealed a 3-cm well-circumscribed mass on the patient's left ovary. Her last menstrual period was 3 weeks ago. The couple presents now to discuss the possibility of a diagnostic laparoscopy.

■ What are common causes of female infertility?	■ Anatomical factors: <ul style="list-style-type: none">■ Adhesions■ Leiomyoma■ Obstruction of fallopian tube■ Uterine anomalies ■ Hormonal factors: <ul style="list-style-type: none">■ Pituitary dysfunction■ Polycystic ovarian syndrome■ Premature ovarian failure
■ What is the most likely cause of this patient's infertility?	The patient's infertility and dysmenorrhea are most likely secondary to endometriosis. Patients with endometriosis often experience chronic pelvic pain, typically more severe during menses, dysmenorrhea, dyspareunia, dyschezia, abnormal menstrual bleeding, and infertility.
■ How is this condition diagnosed?	The optimal method of diagnosis is direct visualization via laparoscopy. Surgery is therapeutic intervention, as well as being diagnostic.
■ What is the pathogenesis of this condition?	The pathogenesis of endometriosis is presumed to be retrograde menstruation, in which endometrial tissue flows from the uterus through the fallopian tubes and into the abdominal cavity during menses. The tissue subsequently invades and proliferates in the peritoneum, resulting in endometrial lesions or cysts. Other theories also exist, including hematologic and lymphogenous dissemination as well as coelomic metaplasia.
■ What treatment options are available for patients with this condition?	Current treatment options are either surgical or medical. Surgical intervention includes laparotomy or laparoscopy, with the lysis of adhesions, excision of cysts, and laser ablation of lesions. Medical interventions include continuous hormonal contraception, for its elevated progesterone effect and to decrease retrograde menstrual flow, as well as gonadotropin-releasing hormone agonists to put the patient into a pseudomenopause state and decrease the estrogen stimulation to the ectopic foci of endometrium.

► **CASE 11**

A 29-year-old G2P2 woman presents to the emergency department in labor and gives birth at 39 weeks' gestation to a baby girl who has difficulty breathing and appears grossly edematous and lethargic. She had received all appropriate prenatal care until 23 weeks, but she has not seen a doctor since then due to loss of health insurance. The infant is intubated and taken to the neonatal intensive care unit (NICU). She is tachycardic with muffled heart sounds, and she has a distended abdomen. She is hypotensive and difficult to arouse. Ultrasound examination reveals a pericardial effusion and ascites. Despite all resuscitative efforts, the infant dies after 4 hours of life.

-
- **What is the most likely diagnosis?** Hydrops fetalis is an accumulation of edematous fluid in a least two compartments including polyhydramnios, subcutaneous tissue, pleura, pericardium or abdomen. Mortality is approximately 50%.

 - **What are the causes of this condition?**

Immune-mediated fetal hydrops (IMFH): Alloimmune hemolytic disease of the newborn is caused by the destruction of fetal red blood cells by maternal immunoglobulin G (IgG) antibodies. The mother must be exposed and sensitized to fetal erythrocyte major and minor antigens, so first pregnancies are unlikely to be complicated by IMH. Rh and Kell blood group antibodies cause the most severe hydrops; less severe forms may result in only hyperbilirubinemia.

Nonimmune fetal hyrops (NIFH): The pathophysiology of NIFH is thought to be the result of reduced lymphatic or venous return, increased capillary permeability, and/or reduced osmotic pressure. Structural or rhythmic cardiac abnormalities, chromosomal abnormalities (Turner's is most common), twin-twin transfusion syndrome, and infections such as syphilis, cytomegalovirus, and Parvo B19 may cause NIFH. Nonhemolytic hematologic causes include thalassemias, glucose-6-phosphate dehydrogenase (G6PD), and leukemia.

 - **What is the most likely cause of this condition in this case, and what could have been done to prevent this occurrence?**

The incidence of Rh incompatibility immune-mediated hydrops has decreased significantly since the development of Rh Ig prophylaxis. All Rh-negative women should undergo an antibody screen at the first prenatal visit and again at 28 weeks' gestation. Women who are Rh negative and may have an Rh-positive fetus should receive anti-D immune globulin (RhoGAM) at 28 weeks and after the delivery of an Rh-positive infant.

 - **Can this condition develop if the mother is Rh positive or if the father is Rh negative?**

IMFH can only develop if (1) the mother is Rh negative, (2) the infant is Rh positive, and (3) fetomaternal blood transfusion occurs. Fetomaternal blood transfusion generally occurs perinatally as a result of transplacental hemorrhage. If the father is also Rh negative, the infant cannot develop IMFH.

 - **How is fetal anemia assessed?**

Doppler ultrasound of the middle cerebral artery (MCA) is the best tool for assessing fetal anemia. Oxygen delivery to the brain will be preserved if possible, so a more anemic patient will require faster blood flow. This is the best and most widely used test. Fetal blood sampling, by cordocentesis, is used if anemia is suggested by MCA velocities. It can be used to obtain direct samples of fetal blood for more extensive testing, and it may be used therapeutically for transfusion if anemia is sufficiently severe.

 - **Should chorionic villus sampling be used to determine Rh status of a fetus potentially at risk for this condition?**

No. CVS increases the risk of fetomaternal hemorrhage and should be avoided in cases of potential Rh incompatibility.
-

► **CASE 12**

A 29-year-old G1P1 woman presents to her obstetrician for her postpartum checkup 4 weeks after an uncomplicated delivery of a term male. She has been breast-feeding her son without difficulty until several days ago, when she noticed that her left nipple became dry and irritated, and the surrounding skin started to crack. Since then, her left breast has become increasingly sensitive, but she has continued to breast-feed despite the discomfort. Vital signs are notable for a temperature of 38° C (100.4° F). Physical examination reveals an erythematous left breast that is warm and tender to light touch. No pus can be expressed from the left nipple.

■ What is the most likely diagnosis?	Mastitis. Breast tenderness and inflammation accompanied by fever in a breast-feeding woman is most likely mastitis. It is unlikely that this woman has a breast abscess, as no pus can be expressed from the nipple. Furthermore, the patient's fever would likely be higher in the event of a breast abscess.
■ What is the most appropriate initial treatment for this condition?	Mastitis is a cellulitis of the periglandular breast tissue that frequently occurs within the first 3 months postpartum. Mastitis results from breast-feeding-related nipple trauma and the concurrent introduction of <i>Staphylococcus aureus</i> from the infant's nostril into the nipple ducts. Initial treatment consists of an oral antibiotic effective against penicillin-resistant staphylococci, such as dicloxacillin or a cephalosporin.
■ How should the treatment be modified if the patient does not respond to the initial treatment?	Antibiotic coverage against oral flora from the suckling baby should be considered in a patient not responding to antistaphylococcal therapy. It is also important to rule out a breast abscess in such a patient, as a breast abscess requires incision and drainage in addition to antibiotic therapy.
■ Should a patient with this condition continue to breast-feed?	A patient with mastitis should continue to breast-feed her infant provided that she is not prescribed an antibiotic such as a tetracycline, which is contraindicated in breast-feeding mothers. Studies have shown that mastitis clears more quickly in breast-feeding mothers than in non-breast-feeding mothers.

► CASE 13

A 28-year-old G3P2 woman presents to the labor and delivery triage unit at 39 weeks' gestation complaining of regular uterine contractions at intervals of 5–15 minutes. The patient's pregnancy was complicated by preterm labor at 31 weeks' gestation. Sterile speculum examination at that time was negative and revealed no pooling in the vaginal vault, a negative Nitrazine blue test, and a negative fern test. Her cervix was dilated to 2 cm and the patient was given two doses of betamethasone and 24 hours of intravenous magnesium sulfate. She was discharged on bed rest and had no further complications. On physical examination now, the patient is afebrile with a blood pressure of 115/70 mm Hg. Her cervix is dilated to 4.5 cm and 25% effaced.

-
- | | |
|--|--|
| <ul style="list-style-type: none"> ■ What is the most likely diagnosis? | <p>This patient is in the active phase of labor and should be admitted to the labor and delivery unit. Labor is strictly defined as uterine contractions that bring about demonstrable effacement and dilation of the cervix. While this diagnosis can often be confirmed only in retrospect, in practice, the diagnosis of labor is based on cervical dilation of 3–4 cm in the setting of painful, regular uterine contractions.</p> |
| <ul style="list-style-type: none"> ■ What are the stages of labor? | <ul style="list-style-type: none"> ■ First stage: This stage is further subdivided into a latent and an active stage. ■ Latent: Begins with the onset of regular uterine contractions with cervical change; it lasts 4–11 hours for multiparous patients and up to 20 hours for primiparous patients. ■ Active: Begins at > 4 cm dilation and ends at 10 cm dilation. This stage can last 2–6 hours with a relative rate of change of 1 cm/hr for primiparas and 1.2 cm/hr for multiparas. ■ Second stage: The second stage occurs from complete cervical dilation at 10 cm to delivery of the infant and can last from 5 minutes to 3 hours. ■ Third stage: This stage includes the delivery of the placenta and usually lasts 1–30 minutes. |
| <ul style="list-style-type: none"> ■ What is the most important initial diagnostic test? | <p>Every patient admitted with labor must receive an ultrasound of the abdomen to assess fetal presentation. A breech presentation at term would require a cesarean section without a trial of labor.</p> |
| <ul style="list-style-type: none"> ■ What are common causes of prolongation of the first stage of labor? | <p>Prolongation of the latent phase is generally due to excessive sedation or hypotonic uterine contractions. Prolongation of the active phase is associated with cephalopelvic disproportion.</p> |
| <ul style="list-style-type: none"> ■ When does fetal descent begin? | <p>Rapid descent of the fetus begins in the later stage of active dilatation, commencing at about 7–8 cm in primiparous women and becoming most rapid after 8 cm. The fetus generally remains in the 0 position throughout the latent phase and reaches a +1 position only at the onset of active labor. Rapid descent to +3 and +4 positions occurs only with further dilation.</p> |
| <ul style="list-style-type: none"> ■ What is considered a normal amount of blood loss in a vaginal delivery? | <p>Blood loss < 500 mL is considered normal in a vaginal delivery, which usually corresponds to a 3-point drop in the hematocrit.</p> |
-

► **CASE 14**

A 27-year-old G2P1 woman who is 20 weeks pregnant presents to her obstetrician's office complaining of persistent coughing and chest discomfort for the past 2 weeks. She states that her coughing is intermittent and worse after eating. She experiences chest discomfort only when lying flat on her back and describes the discomfort as a sense of "fullness" with "occasional burning." She has not been ill recently, has had no sick contacts, and denies sore throat, rhinitis, dyspnea, chest pain, chest tightness, or palpitations. She has no history of any medical problems and has had an uncomplicated pregnancy, except for some nausea and vomiting during her first trimester. She is up to date on all of her prenatal tests. On physical examination, the patient has a heart rate of 85/min, a blood pressure of 125/75 mm Hg, a respiratory rate of 10 breaths per minute, and a temperature of 37.2° C (99.0° F). Head, ears, eyes, nose, and throat (HEENT) examination reveals no facial fullness or sinus tenderness. Her oropharynx is clear. The patient's lungs are clear to auscultation bilaterally, and her heart has a regular rate and rhythm. She has no lower-extremity edema, and her pulses are 2+ and symmetric in all four extremities.

■ What is the most likely diagnosis?	This patient is experiencing symptoms of acid reflux. Acid reflux is due to lowered gastroesophageal sphincter tone, a normal physiologic change of pregnancy. Acid reflux may be further exacerbated during the late second or third trimester due to the increase in abdominal pressure secondary to increased abdominal girth.
■ What conditions should be included in the differential diagnosis?	In any patient presenting with chest discomfort, cardiac causes must be considered. This patient could be experiencing atypical angina due to an unknown medical problem. Pulmonary conditions, such as a pulmonary embolus, should be considered. The patient does not describe symptoms relating to a respiratory tract infection, but it is always a possibility.
■ What is the most appropriate treatment for this condition?	Patients should avoid caffeine and chocolate. Antacids can be used liberally; if the pain is persistent, a histamine blocker or a proton pump inhibitor can be given.
■ What are other changes in gastrointestinal physiology during pregnancy?	<ul style="list-style-type: none">■ Up to 70% of pregnant women experience nausea and/or vomiting during the first trimester as β-human chorionic gonadotropin (β-hCG) levels rise. These symptoms usually resolve by 14–16 weeks.■ Women will often experience symptoms of constipation as a result of decreased large bowel motility and increased water resorption.■ Women may experience biliary colic as a result of gallstone formation precipitated by increased biliary cholesterol saturation in pregnancy.
■ What are normal hemodynamic changes during pregnancy?	Pregnancy causes a physiologic increase in cardiac output by 30–50%. An increase in systemic progesterone causes smooth muscle relaxation in the vasculature, which decreases systemic vascular resistance and, therefore, blood pressure. Blood pressure reaches a physiologic nadir at approximately 24 weeks and then normalizes by 40 weeks. An elevation in blood pressure during pregnancy may be a sign of preeclampsia and should always be investigated.

► **CASE 15**

A 29-year-old G2P1 woman presents to her obstetrician's office at 10 weeks' gestation for her screening visit. She reports no complaints and states that she has been feeling well. Her past medical history is significant for a seizure disorder that began when she was a teenager. Her seizures have been well controlled with valproic acid, and she was able to discontinue her medication during her previous pregnancy without incident. Since discovering she was pregnant again, she self-discontinued her medication and has had no seizure activity. She is concerned about maintaining an adequate nutritional intake during her current pregnancy.

- | | |
|--|---|
| <ul style="list-style-type: none"> ■ What is the most appropriate treatment for epilepsy during pregnancy? | <ul style="list-style-type: none"> ■ All antiepileptic drugs (AEDs) have teratogenic potential and the regimen should be optimized prior to conception since teratogenesis occurs early in the pregnancy. ■ If the patient has been seizure free for ≥ 2 years, consider discontinuing AEDs ≥ 6 months prior to planned conception. ■ Monotherapy at lowest effective dose is best if AED is used. ■ Avoid valproate if possible. This pregnancy is at risk. ■ Do not change AEDs in established pregnancy since teratogenesis has already occurred. |
| <ul style="list-style-type: none"> ■ What is the most important vitamin for this patient to take? | <p>All women of childbearing age are advised to supplement their diet daily with 0.4 mg of folic acid to prevent neural tube defects. High-risk patients, such as those with a history of antiepileptic medications use, are advised to supplement 4 mg of folic acid daily beginning at least 1 month prior to conception since the neural tube closes at 18–26 days' gestation.</p> |
| <ul style="list-style-type: none"> ■ What is the mechanism of action of this vitamin? | <p>Folic acid, a biochemically inactive compound, is the precursor for tetrahydrofolic acid and methyltetrahydrofolate, compounds that are essential for the maintenance of normal erythropoiesis and required cofactors for the synthesis of purine and thymidylate nucleic acids.</p> |
| <ul style="list-style-type: none"> ■ What vitamin should be avoided during pregnancy? | <p>Vitamin A, also known as retinoic acid, is frequently used to treat severe cystic acne. Vitamin A should be avoided during pregnancy because of its association with spontaneous abortion and neural tube defects. Although vitamin A is most teratogenic when taken at 5–7 weeks' gestation, it should be avoided at all gestational ages.</p> |
| <ul style="list-style-type: none"> ■ When is iron supplementation required in pregnancy? | <p>Pregnancy causes a physiologic anemia. This is the result of the physiologic increase in plasma volume, which results in an effective decrease in hemoglobin and hematocrit. All pregnant women should take a daily prenatal vitamin that contains iron in order to avoid worsening anemia. Additional iron supplementation at higher doses should be given to any woman with a superimposed cardiac or hematologic condition, such as sickle cell disease.</p> |

► **CASE 16**

A 19-year-old G3P0111 woman at 34 weeks' estimated gestational age presents to the emergency department complaining of 3 hours of persistent lower abdominal pain and increased vaginal discharge. She states that she cannot remember what she was doing when the pain began, but it began suddenly and since then she has noticed dark brown fluid soaking her underwear. She has had no prenatal care. On examination, the patient is an anxious-appearing woman, 152 cm (5'4") and 50.9 kg (122 lb). Vital signs are blood pressure of 167/74 mmHg, heart rate of 98/min, and temperature of 37.9° C (100.3° F). She has 4.5-mm pupils and appears pale and diaphoretic. Sterile speculum exam reveals dark blood in the vaginal vault. The remainder of her physical exam is normal.

■ **What is the most appropriate next step in management?**

Third-trimester bleeding may be an emergency and result in hemodynamic instability, even if only a moderate amount of blood is noted from the vagina; blood loss may be concealed by extravasation into the myometrium (Couvelaire uterus) or behind the placenta. Management should begin with assessment of volume status, placement of two large-bore IVs, and administration of a bolus of normal saline or lactated Ringer's. Labs should be sent immediately for complete blood count, coagulation studies, and fibrinogen levels. Transfusion of packed RBCs, platelets, and fresh frozen plasma should follow these goals: Hct > 30; Plt > 50,000; Fibrinogen 150–200 mg/dL.

Ultrasound may be used if the patient is hemodynamically stable. While ultrasound has a low sensitivity for diagnosing abruption, it is very specific and may be used as a "rule in" test. Continuous fetal monitoring should be started immediately.

■ **What is the most likely diagnosis?**

The most likely diagnosis of painful third-trimester bleeding is placental abruption, premature separation of a normally implanted placenta. Risk factors for abruption are hypertension, trauma, smoking, and cocaine use. This patient is exhibiting signs and symptoms of cocaine abuse. Furthermore, her lack of prenatal care and obstetric history make this more likely.

■ **What is the Kleihauer-Betke test?**

One complication of placental abruption is fetal-to-maternal hemorrhage. This test may be used to detect fetal erythrocytes present in the maternal circulation by distinguishing fetal from adult hemoglobin.

■ **How should this pregnancy be managed?**

The management of placental abruption is dependent on three factors: gestational age, fetal stability, and maternal stability.

- All fetuses > 34 weeks' gestation should be delivered because partial abruption will likely extend.
- Premature fetuses with partial abruption may be managed expectantly if the mother is stable with no bleeding. Delivery is typically vaginal but may be by cesarean section.
- A fetal demise should be delivered vaginally. Disseminated intravascular coagulation (DIC) should be ruled out.

■ **What is the differential diagnosis of third-trimester bleeding?**

See Table 11-1.

TABLE 11-1. Late Trimester Bleeding

DIAGNOSIS	DEFINITION	KEY SIGNS AND SYMPTOMS	DIAGNOSIS/MANAGEMENT
Placental abruption	Premature placental separation	<ul style="list-style-type: none"> ■ Painful bleeding ■ Coagulopathy/DIC 	<ul style="list-style-type: none"> ■ > 34 weeks: deliver ■ < 34 weeks: expectant management
Placenta previa	Placenta implanted over os	<ul style="list-style-type: none"> ■ Painless bleeding ■ Bleeding stops spontaneously ■ Prior cesarean section, grand multiparity 	<ul style="list-style-type: none"> ■ No vaginal exam ■ Ultrasound ■ Deliver if: <ul style="list-style-type: none"> ■ Persistent labor ■ > 500 mL blood loss ■ Coagulopathy ■ Fetal lungs mature or > 36 weeks
Vasa previa	Vessels traverse lower uterine segment in advance of fetal presenting part	<ul style="list-style-type: none"> ■ Painless bleeding ■ Fetal bradycardia ■ Vessels may rupture with artificial rupture of membranes 	Emergent cesarean section
Uterine rupture	Rupture of uterine wall	<ul style="list-style-type: none"> ■ Painful bleeding ■ Loss of fetal heart tones ■ Loss of station ■ History of classical cesarean section 	Emergent laparotomy

► **CASE 17**

A 28-year-old G1P1 woman at 39 weeks' gestation presents to the emergency department complaining of severe, regular uterine contractions. On cervical examination, she is 5 cm dilated and is promptly admitted to the labor and delivery unit. The patient reports no complications with her pregnancy and has no medical problems. After almost 22 hours of active laboring, the patient delivers a 3.6-kg (8-lb) healthy baby girl. The placenta is delivered without difficulty, but the patient continues to bleed. Vaginal examination reveals the patient has extensive perineal lacerations.

- | | |
|--|--|
| ■ How is this condition classified? | First-degree perineal laceration due to birth trauma is a common obstetric complication caused by stretching of the birth canal. It is limited to the vaginal mucosa, skin, and superficial subcutaneous and submucosal tissues. Second-degree lacerations penetrate into the superficial fascia and transverse perineal musculature. Third-degree lacerations extend into the anal sphincter. Fourth-degree lacerations extend beyond the anal sphincter and into the rectal mucosa. |
| ■ What risk factors are associated with an increased incidence of this condition? | Risk factors associated with lower genital tract trauma in the obstetric setting include nulliparity, a large infant, precipitous birth, operative vaginal delivery with vacuum or forceps, and episiotomy. |
| ■ What is the most appropriate treatment for this condition? | First-degree lacerations of the perineum or vagina not involving underlying tissues rarely require repair, as they tend to heal quickly and neatly. Sutures are needed only for control of active bleeding. Second-, third-, and fourth-degree lacerations, however, always require surgical repair. In these lacerations the tissues may be distorted, making identification of the fascial planes more difficult. In the event of a fourth-degree laceration, the torn rectal mucosa must be repaired separately from the rest of the tissue with the desire to avoid the formation of a rectovaginal fistula. |
-

► **CASE 18**

A 36-year-old G5P4 woman at 27 weeks' gestation presents to her obstetrician complaining of vaginal bleeding. She states that the bleeding began 2 days ago as mild, pinkish spotting but has recently worsened. She denies any abdominal or pelvic pain with the bleeding and states that she has not experienced any recent trauma. She has no medical problems except for a history of preeclampsia in a previous pregnancy, which necessitated an emergent cesarean section. Vital signs are notable for a temperature of 37.3° C (99.2° F), a heart rate of 90/min, and a blood pressure of 105/70 mm Hg. Physical examination is notable for a gravid uterus with sizes equal to dates, and a cervical exam was not performed.

-
- **What is the most likely diagnosis?** Placenta previa. A placenta previa is a placenta that is located directly over or very near the internal cervical os. In a complete placenta previa, the internal os is completely covered, while in a partial placenta previa, the internal os is only slightly covered, and in a marginal placenta previa, the edge of the placenta abuts the internal os. A low-lying placenta is implanted in the lower uterine segment but does not touch the internal os. It is unlikely that this patient's bleeding is the result of a placental abruption, as this patient denies recent trauma or pain associated with the bleeding (see below). Given that the patient is in her second trimester of pregnancy, her bleeding cannot be the result of a missed abortion.

 - **What risk factors are associated with an increased incidence of this condition?** Common risk factors for a placenta previa are advanced maternal age, multiparity, multifetal gestation, a prior cesarean delivery, and smoking.

 - **How is this condition diagnosed?** Diagnosis of a placenta previa is by clinical history and sonography. A placenta previa should always be suspected in a woman with uterine bleeding during the latter half of her pregnancy. A sonogram will demonstrate the position of the placenta and whether it is free of the internal os. It is important to note that a pelvic examination in which a finger is passed through the cervix in an attempt to palpate the placenta should not be performed, as direct manipulation of the placenta can induce severe hemorrhage.

 - **Is the use of transvaginal ultrasonography contraindicated in this condition?** No. Although it may appear to be dangerous to introduce an ultrasound probe into the vagina of a woman with a placenta previa, this technique has routinely been shown to be safe. Given the substantially improved quality of sonograms with the transvaginal approach, this technique is often preferred to a transabdominal ultrasound.

 - **What is the other most common cause of antepartum hemorrhage?** Placental abruption. A placental abruption is the premature separation of the normally implanted placenta. In contrast to the **painless** bleeding associated with a placenta previa, a placental abruption is usually **painful**.

 - **What is placental "migration"?** Placental "migration" describes the phenomenon in which a partial or marginal placenta previa early in pregnancy "migrates" upward as the uterus expands so that the placenta is completely free of the internal os by term.
-

► **CASE 19**

A 27-year-old G2P1 woman is 2 days postpartum after a cesarean delivery of a 2.8-kg (6 lb 4 oz) boy. The patient's pregnancy was complicated by preterm premature rupture of membranes (PPROM) at 32 weeks, for which she was hospitalized. Fetal heart tracings were reassuring throughout the patient's hospitalization, and she began labor spontaneously at 34 weeks and 4 days. A cesarean section was performed due to nonreassuring heart tracings after 10 hours of labor. The patient complains of worsening abdominal pain and general malaise. On physical examination, she has a temperature of 38.9° C (102.1° F), a heart rate of 120/min, uterine tenderness, and foul-smelling lochia.

■ **What is the most likely diagnosis?**

Endometritis is an infection of the endometrial tissue that usually occurs on the second or third postpartum day. It is most common in patients with prolonged rupture of membranes, prolonged labor, operative vaginal deliveries, cesarean section, poor nutrition, and obesity.

■ **Which conditions must be ruled out?**

The classic causes of postoperative fever must be considered in any febrile patient who is status post cesarean section. These include the "5 W's":

- **Wind** (postoperative days 1–2): Atelectasis without pneumonia, predominantly in the dependent lower lung segments. This often occurs as a result of inadequate ventilation due to ventilator support or incisional pain on deep breathing.
- **Water** (postoperative days 3–5): Urinary tract infection. This is frequently caused by ascending infection from urinary catheters used during and/or after surgery.
- **Walking** (postoperative days 4–6): Deep venous thrombosis. This is most common in patients recovering from pelvic, orthopedic, or general surgeries and is best prevented by early and frequent ambulation.
- **Wounds** (postoperative days 5–7): Wound infections or abscess formation. This can be caused by aerobic or anaerobic bacteria, depending on the site of infection.
- **Wonder drugs** (postoperative days 7+): Medications prescribed postoperatively may induce a febrile reaction.

Obstetrics then adds two additional W's with:

- **Womb** (postoperative days 2–7): This represents endometritis and is a common cause of postpartum fever.
 - **Weaning** (4–5 days postpartum to 3–4 months): This primarily represents mastitis, but a patient can also have a low-grade fever when her milk supply develops. Engorgement happens usually postpartum day 3.
-

■ **What laboratory test should be obtained prior to initiating treatment?**

Blood cultures should be obtained in any postpartum febrile patient, as bacteremia (which may result in sepsis) occurs in 10–20% of such patients. Due to the polymicrobial nature of endometritis, both anaerobic and aerobic cultures must be drawn prior to beginning antibiotic therapy, as antibiotics will decrease the organism load in the blood and may cause a false-negative result.

<ul style="list-style-type: none"> ■ What other laboratory test would be helpful? 	<p>A complete blood count (CBC) with a differential is helpful in following the patient's response to treatment. A leukocytosis with an elevated neutrophil count and bandemia are highly suggestive of an infectious process. These parameters, along with clinical signs and symptoms, can be followed to track the patient's response to antibiotics. Note that a CBC is not needed before starting antibiotics.</p>
<ul style="list-style-type: none"> ■ What laboratory test would be of little help? 	<p>Endometrial cultures would be of little clinical and diagnostic utility. Endometritis is commonly caused by local flora of the genital tract; and therefore, it is difficult to isolate an uncontaminated specimen through the cervix.</p>
<ul style="list-style-type: none"> ■ What is the most appropriate treatment for this condition? 	<p>Antibiotic therapy is guided by epidemiologic considerations rather than laboratory findings. Endometritis is typically a polymicrobial infection due to anaerobic streptococci, gram-negative coliforms, <i>Bacteroides</i> species, and aerobic streptococci. Antibiotic coverage with a cephalosporin and clindamycin is thus usually adequate, although hospital-specific infection patterns should be used to tailor therapy.</p>

► **CASE 20**

A 30-year-old woman with type 1 diabetes mellitus delivers a 4.3 kg (9 lb 8 oz) baby boy at 39 weeks' gestation. The first stage of labor progressed without incident, but the second stage was markedly prolonged. The patient received epidural anesthesia, which controlled her pain well. Immediately after the delivery of an intact placenta, the patient continues to bleed vaginally. Vital signs are significant for a blood pressure of 120/70 mm Hg and a heart rate of 79/min. The patient is alert and conversant. Bimanual examination reveals a soft, enlarged, boggy uterus.

-
- **What is the most likely diagnosis?** Postpartum hemorrhage secondary to uterine atony. The patient has several risk factors for uterine atony (see below). Her uterus is soft and “boggy,” a classic sign for uterine atony. She delivered an intact placenta, making retained products of conception an unlikely cause of her hemorrhage. It is possible that, in addition to an atonic uterus, this patient could have sustained perineal lacerations secondary to the size of her newborn, but the primary cause of the hemorrhage here is uterine atony.
-
- **What risk factors are associated with an increased incidence of this condition?** Uterine atony is the most common cause of postpartum hemorrhage. Risk factors include uterine overdistention secondary to multiple gestations, macrosomia (which commonly occurs in pregnancies of diabetic mothers), polyhydramnios, an exhausted myometrium due to rapid or prolonged labor or oxytocin stimulation, uterine infection, or conditions that interfere with contractions, such as anesthesia, myomas, or magnesium sulfate.
-
- **What is the most appropriate initial treatment for this condition?** The first step in treating uterine atony is bimanual uterine massage. This technique is usually successful in controlling bleeding without the need for medication or surgical interventions. Uterine massage should be performed bimanually, with one hand placed over the uterus externally and one hand placed in the vagina.
-
- **What agent can be administered as a second-line therapy to help reduce the bleeding?** Oxytocin is routinely given after delivery to stimulate uterine contraction and facilitate placental delivery. An additional oxytocin infusion can be administered to help control postpartum hemorrhage secondary to uterine atony. Oxytocin stimulates uterine contraction, which generally stops hemorrhage.
-
- **What are contraindications to this medication and why?** There are no absolute contraindications to an oxytocin infusion. However, it should never be given as an undiluted bolus due to the risk of serious hypotension or cardiac arrhythmias; it should always be diluted in lactated Ringer's solution or normal saline. If oxytocin is ineffective, an intramuscular dose of methylergonovine, an ergot derivative, can be administered. This drug may cause serious hypertension and therefore should not be administered to women with preeclampsia or eclampsia. Prostaglandin F₂-α (PGF-2α) can also be used but is contraindicated in women with a significant history of asthma. Another prostaglandin, misoprostol, can be used rectally but has a slower onset of action.
-
- **What invasive options are available if conventional medical therapies fail?** Uterine or internal iliac artery ligation or hysterectomy should be performed if hemorrhage persists after conventional therapies.
-

► CASE 21

A 22-year-old G2P0 woman presents to her obstetrician's office at 36 weeks' gestation complaining of a mild headache. She has a history of a missed abortion at 12 weeks' gestation 2 years ago, which required a dilation and curettage. Her pregnancy has been uncomplicated until last week, when she presented with a headache and blood pressure of 142/78 mm Hg. No proteinuria was noted at that time. Currently, the patient denies any complaints other than a mild headache and reports no uterine contractions or vaginal bleeding. On physical examination, her temperature is 36.6° C (97.9° F), her heart rate is 92/min, and her blood pressure is 148/88 mm Hg. Her urine dipstick result is 1+ protein, and 24-hour urine monitoring is initiated.

- | | |
|--|---|
| ■ What is the most likely diagnosis? | Preeclampsia is defined as elevated blood pressure and proteinuria after 20 weeks' gestation and until 6 weeks postpartum. Eclampsia occurs in the above setting with the addition of seizures. Classically, three elements were required for the diagnosis of preeclampsia-eclampsia: hypertension, proteinuria, and edema. Edema was difficult to objectively quantify and is no longer required. |
| ■ What is the epidemiology of this condition? | Preeclampsia-eclampsia develops in approximately 7% of pregnant women in the United States. Of women developing preeclampsia, 5% progress to eclampsia. Primiparous women are most frequently affected. Risk factors include multiple pregnancies, chronic hypertension, diabetes, renal disease, autoimmune disorders, and gestational trophoblastic disease. |
| ■ What are the stages of this condition? | Mild preeclampsia is diagnosed by a blood pressure > 140 mm Hg systolic or 90 mm Hg diastolic and proteinuria > 300 mg/24 hr. Severe preeclampsia is defined as blood pressures > 160 mm Hg systolic or 110 mm Hg diastolic and proteinuria > 5 g/24 hr or oliguria (< 500 mL urine/24 hr). |
| ■ What are clinical signs of this condition? | Signs of severe preeclampsia are persistent headache or other cerebral or visual disturbances, including blurred vision or scotomata, persistent right upper quadrant or epigastric pain, hyperreactive reflexes with clonus, and intrauterine growth restriction in the fetus. |
| ■ What laboratory parameters must be monitored routinely in patients with this condition? | Any patient with signs or symptoms of severe preeclampsia should be evaluated for HELLP syndrome, defined as H emolysis, E levated LFTs, and L ow Platelets. Patients should be routinely monitored with the following laboratory parameters: complete blood count, electrolytes, BUN/creatinine, uric acid, liver function tests, and prothrombin time/partial thromboplastin time. If disseminated intravascular coagulation (DIC) is considered, fibrinogen and fibrin split products should also be evaluated. |
| ■ What is the most appropriate treatment for this condition? | The only definitive treatment for preeclampsia-eclampsia is delivery of the fetus and placenta. A woman with preeclampsia at term is delivered. Mild preeclampsia in a preterm woman may be managed expectantly, depending on the risks and benefits for the fetus and the mother. Severe preeclampsia and eclampsia generally necessitate delivery regardless of gestational age of the fetus. When indicated, blood pressure should be controlled with β -blockers and/or hydralazine and seizure prophylaxis given with continuous magnesium sulfate. (Patients on magnesium sulfate must be monitored for signs of magnesium toxicity—loss of deep tendon reflexes, respiratory paralysis, and coma, which can be reversed with intravenous calcium gluconate.) |
-

► **CASE 22**

A 28-year-old G1 at 42 weeks' gestation is admitted to labor and delivery to undergo scheduled induction. Her prenatal care has been routine, regular, and uncomplicated. Her last obstetric ultrasound was at 36 weeks' gestation, which revealed a healthy male fetus. After several hours of labor, contractions are 4 minutes apart. Electronic fetal monitoring demonstrates repetitive late decelerations and minimal beat-to-beat variability, and an emergency cesarean section is performed. When membranes are ruptured, amniotic fluid appears brownish-green and has no odor. The infant has long, thin limbs with decreased fat on his body. He has peeling, brown-stained skin, long fingernails, and decreased vernix. His lips appear bluish, and he has subxiphoid and abdominal retractions with inspiration. Auscultation reveals rales bilaterally. Apgars are 4 and 3 at 1 and 5 minutes, respectively. Relevant findings on arterial blood gas are pH 7.25, P_{CO_2} 45, HCO_3 20, and PO_2 62.

■ What is the most likely diagnosis?	Meconium aspiration syndrome (MAS) classically occurs in postterm infants with signs and symptoms of fetal dysmaturity, including weight loss, long nails, and signs of intra-amniotic meconium such as stained skin, nails, and umbilical cord.
■ What is the pathophysiology of this condition?	Aspiration of meconium has three primary effects: (1) mechanical obstruction results in air trapping and uneven ventilation; (2) chemical inflammation; and (3) surfactant inactivation that result in atelectasis and intrapulmonary shunting. The final common pathway is hypoxemic acidosis and primary pulmonary hypertension.
■ Is meconium staining of amniotic fluid an indication for deep suctioning or intubation?	No. Thin meconium staining with an asymptomatic infant generally has a favorable outcome and should not be managed aggressively. If there is a need for intubation, immediate postpartum direct laryngoscopy with removal of residual meconium by deep suction is imperative.
■ What infants should receive deep endotracheal suctioning?	If meconium is thick, there is antenatal fetal distress, or oropharyngeal suctioning has been omitted.
■ What other risks exist for post-term infants?	Stillbirth and early neonatal deaths are twice as common at or greater than 42 weeks' gestation compared to term infants. Asphyxia, intrauterine infection, and macrosomia are all more common in postterm infants.

- **What is the proper management if the baby's head has exited the vagina but the remainder of the body cannot pass?**

Postterm infants may exhibit macrosomia (> 4500 g), which places them at risk for shoulder dystocia. Obstetric maneuvers should be used in combination by subsequently adding each maneuver in the order listed below:

- McRoberts: flexion of the hip, bringing the mother's knees toward her shoulders.
 - Suprapubic pressure: resolves > 50% of cases.
 - Rubin II: place hand behind baby's anterior shoulder and rotate anteriorly.
 - Woods screw: press on the clavicle of the posterior shoulder such that it rotates posteriorly.
 - Reverse Woods screw: change direction of rotation to anterior shoulder in posterior direction.
 - Removal of posterior arm: the physician places his entire hand into the birth canal. The fetal elbow is flexed, and the arm is delivered.
 - Gaskin all-fours maneuver: the patient rolls onto all fours into the knee-chest position.
 - Last resort moves:
 - Intentional clavicle fracture.
 - Emergent cesarean section following a return of the fetus into the vagina.
-

► **CASE 23**

A 31-year-old G3P2 woman presents to her obstetrician at 16 weeks' gestation. Both of her previous pregnancies were uncomplicated and resulted in normal spontaneous vaginal deliveries. The patient has no known medical problems and complains only of occasional morning sickness with nausea and vomiting. As part of her routine prenatal laboratory tests, the patient agrees to a triple screen test, which reveals a decreased maternal serum α -fetoprotein (MSAFP) level, elevated β -human chorionic gonadotropin (β -hCG), and a normal estradiol level.

■ What is α-fetoprotein (AFP)?	AFP is a protein produced by the fetus and found in the amniotic fluid. Small amounts of this protein cross the placenta and enter into the maternal circulation, providing the basis for the maternal serum AFP (MSAFP) blood test. This test is offered to all pregnant women.
■ What are possible causes of an abnormal MSAFP?	<ul style="list-style-type: none">■ Elevated MSAFP.■ Open neural tube defects (anencephaly, spina bifida).■ Abdominal wall defects (gastroschisis, omphalocele).■ Multiple gestation, incorrect gestational dating, fetal death, and placental abnormalities.■ Low MSAFP: trisomy 18 or trisomy 21, incorrect dating.
■ What is the triple screen test?	The triple screen test is more sensitive than the MSAFP alone and includes measurements of MSAFP, β -hCG, and estriol levels in the maternal serum. In trisomy 18, levels of all three compounds are typically decreased. In trisomy 21, levels of AFP and estriol are typically decreased while β -hCG is elevated.
■ What are the indications for an amniocentesis?	Amniocentesis is offered to women: <ul style="list-style-type: none">■ Who will be > 35 years old at the time of delivery.■ With an abnormal triple screen test in order to test for trisomy 18 or trisomy 21.■ With an Rh-sensitized pregnancy in order to obtain fetal blood type or to detect fetal hemolysis.■ Who may deliver prematurely to evaluate for fetal lung maturity.
■ What are the risks associated with amniocentesis?	Risks associated with an amniocentesis are fetal-maternal hemorrhage (1–2%) and fetal death (0.5%). This is in contrast to a 1% risk of fetal loss with chorionic villus sampling and an almost risk-free MSAFP or triple screen test.
■ At what gestational age are the above tests performed?	Amniocentesis is performed at 15–17 weeks gestation, and MSAFP and the triple screen test are performed at 15–20 weeks gestation. Chorionic villus sampling may be performed at 10–12 weeks to assess fetal karyotype.

► CASE 24

A 28-year-old G1 woman at 30 weeks' estimated gestation presents to her obstetrician complaining of painful contractions occurring every 8 minutes for the past 2 hours. She has received appropriate prenatal care with no complications to date. She denies changes in vaginal discharge or leakage of fluid. She reports feeling tired with significant back pain, but when asked to clarify, she states that she has felt this way for the last few months. On review of symptoms, she denies headache, vision changes, shortness of breath, or burning with urination. She has costovertebral tenderness bilaterally, and the remainder of the exam including vitals is normal. Relevant laboratory values include WBC 8000/mm³; urinalysis is normal.

- | | |
|--|--|
| <ul style="list-style-type: none"> ■ What is the next step in diagnosis? | <ul style="list-style-type: none"> ■ Assess the uterus for firmness, tenderness, fetal size and fetal position. Uterine tenderness with preterm contractions should raise concern for chorioamnionitis. ■ A sterile speculum exam should be performed to rule out rupture of membranes and uterine bleeding and collect a vaginal swab from the posterior fornix for fetal fibronectin. ■ A digital exam allows assessment of effacement and dilation. ■ Transvaginal ultrasound may evaluate cervical changes. ■ Secondary causes of preterm labor, such as urinary tract infection, should be sought. Group B strep (GBS) status of the mother should be assessed. |
| <ul style="list-style-type: none"> ■ What is the most likely diagnosis? | <p>Preterm labor (PTL) is defined as uterine contractions < 10 minutes apart and a cervix dilated at least 2 cm and changing or at least 80% effaced between 20 and 37 weeks' gestational age.</p> |
| <ul style="list-style-type: none"> ■ What are the most appropriate next steps in the management of this condition? | <p>The next step in management is to confirm the diagnosis of PTL. If the fetal fibronectin is negative, there is a > 95% chance that the patient will not deliver in the next 2 weeks. If the test is positive then the chance of delivery in the next 2 weeks is 50%.</p> <ul style="list-style-type: none"> ■ Rule out contraindications to tocolysis (i.e., preeclampsia, rupture of membranes, lethal fetal anomaly). ■ Hydrate: Insufficient hydration is a common cause of PTL. ■ Tocolysis with nifedipine, indomethacin, terbutaline, or magnesium sulfate. ■ Steroids: If the fetus is ≤ 34 weeks' gestation, two doses of IM betamethasone should be given 24 hours apart to stimulate fetal surfactant production and reduce risk of intracranial hemorrhage. It requires 48 hours for maximal response. ■ GBS prophylaxis with IV penicillin G. |
| <ul style="list-style-type: none"> ■ What risk factors are associated with an increased incidence of this condition? | <ul style="list-style-type: none"> ■ History of PTL. ■ Uterine anomaly or distension (multiple gestation, polyhydramnios). ■ Premature rupture of membranes. ■ Substances: smoking, cocaine. ■ History of cervical cone biopsy. ■ African-American race. ■ Pyelonephritis. ■ Stress: single women, depression, anxiety, low socioeconomic status. |
-

► **CASE 25**

A 23-year-old G2P1 woman at 28 weeks' gestation presents to the emergency department complaining of clear fluid on her underwear that has collected for the past 4 hours. She has had all appropriate prenatal care and is in good health other than continuing to smoke a half-pack of cigarettes daily. She denies fever and all constitutional symptoms of infection and states that when she woke this morning she could feel the baby moving. Her past medical history is unremarkable. Social history is significant in that she is currently unemployed and recently began dating a man who has moved in with her. On physical examination, her lungs are clear to auscultation, and she has no costovertebral tenderness. She has mild discomfort with lower abdominal palpation. Vital signs are 37.1° C (98.8° F), pulse 99/min, and blood pressure 145/88 mm Hg. Fetal heart tones have normal range and variability.

-
- | | |
|---|--|
| <p>■ What is the next step in diagnosis?</p> | <p>A sterile speculum exam must be performed to confirm the occurrence of preterm premature rupture of membranes (PPROM). Positive findings will include pooling, the collection of amniotic fluid in posterior vaginal vault, a positive nitrazine test, indicating alkaline changes of amniotic fluid, and ferning, a snowflake pattern seen when the collected fluid is analyzed by microscopy. The patient should also be evaluated for genital tract infections, including bacterial vaginosis, chlamydia, and gonococcal infection, which predispose to PPRM.</p> |
| <p>■ What is the most appropriate treatment for this condition?</p> | <p>The patient must be hospitalized and placed on electronic fetal monitoring. If at any point the baby becomes unstable or if the mother has already begun overt labor, the baby should be delivered. If the mother has a fever, urinary tract infection and upper respiratory infection should be ruled out. Chorioamnionitis is a consideration but is a diagnosis of exclusion; if no other source is found for the fever, she should be treated with gentamicin plus clindamycin or ampicillin plus gentamicin and delivered. If the baby and the mother are both stable, the condition should be managed according to gestational age. A fetus < 24 weeks will be nonviable, and labor should be induced. If the fetus is between 24 and 34 weeks, the mother should be given betamethasone to enhance fetal lung maturity, as well as antibiotics, then observed until at least 32 weeks' gestational age. If the fetus is > 34 weeks, he or she should be delivered.</p> |
| <p>■ What risk factors are associated with an increased incidence of this condition?</p> | <p>The single most common cause of PPRM is a genital infection. Other risk factors include a history of PPRM, antepartum bleeding, and cigarette smoking.</p> |
| <p>■ What are the most significant complications of this condition?</p> | <p>Complications of PPRM include intrauterine infection, such as chorioamnionitis or endometritis, premature delivery, placental abruption, and prolapsed umbilical cord.</p> |
| <p>■ How is chorioamnionitis diagnosed?</p> | <p>A maternal fever > 38° C (100.4° F) is required for diagnosis. In addition, at least two of the following must be present:</p> <ul style="list-style-type: none">■ Maternal WBC > 15,000/mm³■ Maternal HR > 100/min■ Fetal HR > 160/min■ Uterine tenderness■ Foul odor of amniotic fluid |
| <p>■ Can chorioamnionitis occur without rupture of membranes?</p> | <p>Yes, particularly with <i>Listeria monocytogenes</i>.</p> |
-

► **CASE 26**

A 27-year-old G4P1 woman at 30 weeks', 6 days' gestation presents to the emergency department complaining of headache, fever, chills, and dysuria that have been worsening over the past 2 days. Two days ago, her temperature was 37.8° C (100.1° F), but it has steadily increased since, and the last time she checked, her temperature was 38.8° C (101.8° F). She denies blurry vision, abdominal pain, or dizziness. She is unsure if she has had any recent vaginal discharge, but she has noticed mild and intermittent spotting over the past several weeks. She additionally complains of urinary frequency, but she states that ever since she began her second trimester, she has had to urinate frequently, so she did not think that this recent worsening was abnormal. On physical examination, the patient's temperature is 38.4° C (101.1° F), her heart rate is 108/min, and her blood pressure is 155/96 mm Hg. Her abdomen is soft, with no suprapubic tenderness. She has mild pain at the costovertebral angles bilaterally. Laboratory values reveal the following:

Hgb: 11.8 g/dL
WBC count: 15,700/mm³
Platelet count: 255,000/mm³
Na⁺: 140 mEq/L
K⁺: 3.7 mEq/L
Creatinine: 0.9 mg/dL

-
- **What is the most likely diagnosis?** The patient's symptoms of fever, chills, and dysuria combined with her costovertebral angle tenderness on physical examination and her elevated WBC suggest the diagnosis of pyelonephritis. This condition may have been precipitated by asymptomatic bacteriuria, an uncomplicated urinary tract infection, or cystitis, which then ascended to involve the renal collecting system.

 - **What other laboratory tests would be helpful in diagnosis?** To evaluate for pyelonephritis, a urinalysis and urine culture should be obtained. Typically, a urinalysis will demonstrate elevated leukocyte esterase and nitrite, and the urine culture may provide a causative pathogen. Since women with urinary tract malformations or renal calculi are more at risk for developing pyelonephritis, a renal ultrasound may be indicated to evaluate for renal anomalies or pathology, including hydronephrosis.

 - **What is the most appropriate treatment for this condition?** In the nonpregnant state, pyelonephritis can be treated in the outpatient setting for mild cases. Pregnant patients, however, require IV administration of antibiotics for at least 24–48 hours due to the increased risk of severe complications, such as bacteremia, sepsis, or acute respiratory distress syndrome. Antibiotic treatment is generally with a first-generation cephalosporin such as cefazolin to provide adequate coverage for the common pathogens: *Escherichia coli*, enterococci, *Proteus*, and group B *Streptococcus*.

 - **What are common symptoms of vaginal infections?** Patients with vaginal infections usually complain of vaginal discharge, pain, or pruritus. This patient's symptoms of urinary frequency and dysuria would be uncommon. Common causes of vaginal infections include *Gardnerella vaginalis*, *Bacteroides*, *Candida*, and sexually transmitted infections such as *Trichomonas vaginalis*. Other sexually transmitted infections, including *Chlamydia*, gonorrhea, HIV, syphilis, and human papillomavirus, are often asymptomatic in the initial stages and produce local or systemic symptoms at later stages.

 - **What is a normal creatinine value during pregnancy?** Due to the increases in glomerular filtration rate and renal plasma flow in pregnancy, serum creatinine levels decrease from a mean of 0.7 to a mean of 0.5. This patient's was elevated secondary to pyelonephritis.
-

► **CASE 27**

A 25-year-old G1 woman delivers a baby girl at 37 weeks' gestation. The baby has a purpuric rash covering her entire body, a weak cry, and abnormally small eyes. On further examination, she is tachycardic with a machine-like murmur. Her ophthalmologic exam is notable for leukocoria and microphthalmia. Standard postpartum hearing tests are notable for bilateral sensorineural hearing loss. Her mother is a recent immigrant from Guatemala. She reports having had a brief illness during her first trimester with a low-grade fever, lymphadenopathy, and a maculopapular rash that began on the face and spread to the rest of her body before resolving spontaneously.

■ What is the diagnosis for the infant?	Congenital rubella.
■ What infections can be transmitted transplacentally or during the passage through the birth canal?	TORCH infections: T oxoplasmosis, O ther (syphilis), R ubella, C ytomegalovirus, H erpes/HIV. See Table 11-2.
■ What prenatal testing should this patient have received to prevent TORCH infections?	Rubella and syphilis testing are recommended on the first prenatal visit. Additionally, maternal rubella immunization status should be confirmed.
■ What is the reservoir for toxoplasmosis?	Domestic cats are the reservoir for this intracellular parasite.
■ What are the potential complications of pyrimethamine/sulfadiazine treatment?	Pyrimethamine and sulfadiazine are folic acid antagonists that may cause bone marrow suppression.
■ Should the measles, mumps, and rubella (MMR) vaccine be given during pregnancy?	This is a live attenuated virus; therefore, it is not recommended during pregnancy. However, there have been no documented complications from the administration of this vaccine, so termination of the pregnancy should not be considered if the vaccine is inadvertently given.

TABLE 11-2. Overview of TORCH Infections

INFECTION	TRANSMISSION	KEY FEATURES	TREATMENT
Toxoplasmosis	Placental	<ul style="list-style-type: none"> ■ Hydrocephalus ■ Chorioretinitis ■ Intracranial calcifications 	<ul style="list-style-type: none"> ■ Maternal infection: spiramycin ■ Fetal infection documented: pyrimethamine + sulfadiazine + leukovorin
Syphilis	Vaginal and placental	<ul style="list-style-type: none"> ■ Deafness ■ Notched incisors ■ Interstitial keratitis ■ Hepatosplenomegaly ■ Saber shins 	Penicillin G, even if the patient needs to undergo desensitization secondary to a penicillin allergy
Rubella	Placental	<ul style="list-style-type: none"> ■ Petechial rash (“blueberry muffin”) ■ Sensorineural deafness ■ Cataracts, retinopathy ■ Congenital heart disease 	<ul style="list-style-type: none"> ■ Prevention: vaccination ■ Newborn: supportive ■ Fetal: maternal counseling of risks
Cytomegalovirus	Placental	<ul style="list-style-type: none"> ■ Microcephaly ■ Thrombocytopenia ■ Jaundice ■ Periventricular calcifications 	Parenteral ganciclovir
Herpes	Vaginal	<ul style="list-style-type: none"> ■ Vesicular rash ■ Retinopathy ■ Meningoencephalitis 	Parenteral acyclovir

► **CASE 28**

A 34-year-old G3P3 woman is 20 days postpartum after a vaginal delivery that was complicated by a 1500-mL hemorrhage secondary to uterine atony. The patient did not respond to oxytocin or methylergonovine administration and experienced a 10-minute episode of sustained hypotension ranging from 62/30 to 71/25 mm Hg that required 10 units of packed RBCs. The patient was finally stabilized after emergent uterine artery embolization. On postpartum day 2, the patient was found to have a creatinine level of 1.8 mg/dL, which peaked at 3.5 mg/dL on postpartum day 7, and has since returned to baseline. The patient is currently feeling well but presents to her obstetrician complaining of an inability to lactate.

■ What is the most likely diagnosis?	Sheehan's syndrome, or postpartum pituitary necrosis, is characterized by necrosis of the anterior pituitary secondary to ischemia from severe obstetrical hemorrhage and hypotension. The posterior pituitary is usually spared, while the larger and more vascular anterior pituitary suffers what is usually irreversible damage. The most common clinical feature of Sheehan's syndrome is the inability to lactate postpartum secondary to decreased prolactin production.
■ What are other features of this condition?	Other features of Sheehan's syndrome include fatigue, cold intolerance, hair loss secondary to hypothyroidism; amenorrhea and breast atrophy secondary to hypogonadism; and nausea, vomiting, and hypotension secondary to hypocortisolism.
■ What is the epidemiology of this condition?	Sheehan's syndrome is a very uncommon complication of profound obstetrical hemorrhage. The incidence of Sheehan's syndrome is estimated at < 1 in 10,000 deliveries.
■ What are the typical laboratory findings in this condition?	Patients with Sheehan's syndrome have decreased levels of all hormones produced by the anterior pituitary, including thyroid-stimulating hormone, follicle-stimulating hormone, luteinizing hormone, adrenocorticotropic hormone, and prolactin. Some patients may also experience a modest decrease in hormones released by the posterior pituitary, although involvement of the posterior pituitary is much less common.
■ What are the typical CT scan findings in this condition?	CT scan of the head demonstrates an abnormal-appearing pituitary gland with a totally or partially empty sella turcica.
■ What is the most appropriate treatment for this condition?	Treatment of patients with pituitary insufficiency involves hormone replacement with thyroxine, steroids, estrogens, and progesterones. For patients with amenorrhea who desire fertility, ovulation induction can usually achieve pregnancy. Patients often carry the pregnancy well and without complications once treatment is administered.

Gynecology

Case 1	328
Case 2	330
Case 3	331
Case 4	332
Case 5	334
Case 6	336
Case 7	338
Case 8	340
Case 9	342
Case 10	344
Case 11	345
Case 12	346
Case 13	347
Case 14	348
Case 15	350
Case 16	351
Case 17	352
Case 18	353
Case 19	354
Case 20	356
Case 21	357

► **CASE 1**

A 17-year-old girl is referred to a reproductive endocrinologist by her pediatrician because she has not yet menstruated. Both her mother and grandmother started their periods at age 16. She is in the 30th percentile for height, 50th percentile for weight, and is otherwise healthy and preparing to start college in the fall. Physical examination reveals a temperature of 37° C (98.6° F), heart rate of 65/min, and blood pressure of 130/80 mm Hg. She is Tanner stage I, with no breast development or pubic hair. Speculum examination reveals normal prepubescent genitalia with a patent vagina and uterus palpated on rectoabdominal examination.

■ What is the most likely diagnosis?	Primary amenorrhea, most likely due to Turner's syndrome or constitutional delay. Primary amenorrhea is the absence of menses after age 16, while secondary amenorrhea is the cessation of menstruation lasting at least 3 months after menarche. The workup of primary amenorrhea is complex and is directed by the presence or absence of breast and genital development.
■ What are the major causes of this condition?	See Table 12-1.
■ How should the workup proceed for this patient's condition?	This patient has not yet started puberty, so a workup must be done to identify the source of the pathology: hypothalamic, pituitary, or gonadal. The first step is to measure a follicle-stimulating hormone (FSH) level. Elevated FSH suggests gonadal failure, while low FSH suggests hypothalamic or pituitary dysfunction. If gonadal dysfunction is suspected, a karyotype should be obtained to rule out Turner's syndrome.
■ What other aspects of the medical history should be investigated?	Family history is very important in diagnosing amenorrhea because age at menarche tends to be conserved within families. Exercise, stress, eating, and sexual history should be investigated. A history of anosmia will point to Kallmann's syndrome.
■ What diagnostic tests could be used to confirm the diagnosis?	To confirm normal internal genitalia, an ultrasound can be performed. Prolactin, thyroid hormone, and testosterone levels can be tested if indicated. A pregnancy test is always recommended if the patient has normal pubertal development. In patients with abnormal anatomy, a karyotype of XY will reveal testicular feminization (androgen insensitivity).

TABLE 12-1. Major Causes of Primary Amenorrhea

ASSOCIATED FINDINGS	CAUSES
Absent breast development, normal pelvic examination	Hypothalamic failure <ul style="list-style-type: none"> ■ Anorexia, excessive stress or exercise ■ Chronic illness (diabetes, etc.) ■ Gonadotropin deficiency ■ Kallmann’s syndrome (if anosmia) ■ Pituitary dysfunction after head trauma Infiltrative or inflammatory process <ul style="list-style-type: none"> ■ Pituitary adenoma or craniopharyngioma ■ Gonadal failure ■ Gonadal dysgenesis ■ Turner’s syndrome (XO karyotype) ■ Premature ovarian failure (postradiation or chemotherapy)
Normal breast development, normal pelvic examination	Hypothyroidism Hyperprolactinemia Pregnancy Constitutional delay
Normal breast development, abnormal pelvic examination	Testicular feminization or androgen insensitivity (XY karyotype) Anatomic abnormalities <ul style="list-style-type: none"> ■ Uterovaginal septum ■ Imperforate hymen

► **CASE 2**

A 35-year-old G2P1 woman presents to her gynecologist claiming absence of menstruation for the past 4 consecutive months, except for occasional spotting. Her gynecologic history is notable for an incomplete miscarriage and therapeutic dilation and curettage (D&C) approximately 6 months ago, along with the birth of a child within the past year. She is currently not taking oral contraceptive pills (OCPs) and indicates that her periods have previously followed a regular cycle. She has a body mass index (BMI) of 24, her pulse is 84/min, and blood pressure is 120/75 mm Hg. On gynecologic exam, the physician notes that the patient expresses discomfort; the patient indicates that she has noticed her vagina is drier than normal and that this has inhibited her sexual activity. The physician does not note any other gynecologic abnormalities on exam.

- | | |
|---|---|
| ■ What is the most likely diagnosis? | Secondary amenorrhea. Secondary amenorrhea is defined as the cessation of menstruation for at least 6 months (in those with irregular periods) or for at least three of the previous cycle intervals, in a woman who has had at least one normal period. A patient who has primary amenorrhea has never menstruated; this form of amenorrhea may be accompanied by the absence of secondary sex characteristics. (See Case 1, Primary Amenorrhea.) |
| ■ What are some of the underlying causes of this condition? | <ul style="list-style-type: none">■ Pregnancy or lactation■ Premature ovarian failure■ Hyperprolactinemia■ Thyroid dysfunction■ Menopause■ Exercise/stress/eating disorders■ Polycystic ovarian syndrome (PCOS)■ Asherman's syndrome■ Medications |
| ■ What is the next step in the evaluation and diagnosis of this patient? | The first step is administration of a pregnancy test. The clinician should also determine if this patient is currently breast-feeding, since she does have a child less than 1 year old and lactational amenorrhea can occur. If the pregnancy test is negative, the next step is to obtain thyroid function tests, luteinizing hormone/follicle-stimulating hormone (FSH), and prolactin levels. Elevated prolactin levels (> 5000 mIU/L) would most likely indicate a pituitary adenoma. Low FSH could indicate a pituitary tumor or hypothalamic disease. High levels of FSH and low estrogen could indicate premature ovarian failure (defined as amenorrhea, hypogonadism, and elevated gonadotropins in women < 40 years old). Since this patient also received a D&C fairly recently, Asherman's should be considered. Trauma to the basal layer of the endometrium following a D&C results in intrauterine scarring; scarring across the cervix or lower part of the uterus can block menstruation. If Asherman's is suspected, the clinician should perform a hysteroscopy to confirm the diagnosis. Lab values will be within normal limits in a patient with Asherman's. |
| ■ What is the most appropriate treatment for this condition? | If the patient's secondary amenorrhea is a result of Asherman's syndrome, hysteroscopy and/or laparoscopy must be employed to dissect the scar tissue/adhesions; this can be followed by estrogen therapy postoperatively. All patients with Asherman's have an increased risk of placenta accreta, uterine rupture, and premature delivery. |
-

► CASE 3

A 55-year-old postmenopausal woman presents to her primary care physician for an annual physical examination. She has no complaints and feels healthy. On physical examination, she is afebrile (37.0° C [98.6° F]), with a heart rate of 80/min and blood pressure of 140/85 mm Hg. During the breast examination, a small, hard, fixed nodule is palpated in the upper outer quadrant of the left breast. The skin on the breast is without abnormality, there is no nipple discharge, and no abnormal lymph nodes are palpated. She is sent for a diagnostic mammogram, which reveals a 3-cm nodule with microcalcifications. A core-needle biopsy is scheduled, and the pathology report is read as “invasive ductal carcinoma without clear margins, estrogen receptor positive (ER+), HER2/neu receptor negative.”

-
- | | |
|--|--|
| <ul style="list-style-type: none"> ■ What is the most likely diagnosis? | <p>This patient has breast cancer, stage not yet determined. All new breast lumps found on breast examination or mammogram must be biopsied in patients > 35 years of age. The clinical features of this lump (hard, fixed) suggest cancer rather than a benign cyst or adenoma.</p> |
| <ul style="list-style-type: none"> ■ How is this condition staged? | <p>Breast cancer is staged by the TNM (tumor, node, metastasis) classification system, which is simplified as follows:</p> <ul style="list-style-type: none"> ■ Stage I—tumor < 2 cm and node negative. ■ Stage II—tumor 2–5 cm. ■ Stage III—tumor > 5 cm or fixed axillary node involvement. ■ Stage IV—any distant metastases or direct extension to the chest wall or skin. |
| <ul style="list-style-type: none"> ■ What risk factors are associated with an increased incidence of this condition? | <p>Breast cancer is the most common cancer and the second leading cause of cancer death in women. One of the most important risk factors is estrogen exposure; early menarche, late menopause, and nulliparity therefore contribute to increased risk. Most women have no identifiable risk factors other than age and gender, but there is an association with a personal or family (first-degree relative) history of breast cancer or <i>BRCA1/BRCA2</i> mutations.</p> |
| <ul style="list-style-type: none"> ■ What is the most appropriate next step in management? | <p>In patients with small, isolated carcinomas, breast conservation therapy (lumpectomy plus adjuvant radiation) is equally effective when compared with mastectomy. Whichever surgical approach is chosen, sentinel lymph node sampling should be done during the procedure. At this early stage, metastatic workup requires a complete blood count and liver function tests, with optional bone scan. A CT scan of the chest and pelvis is indicated in stage III patients.</p> |
| <ul style="list-style-type: none"> ■ What pharmacologic treatments are available for this patient? | <p>Adjuvant chemotherapy and/or hormonal therapy have been shown to improve outcome and prevent recurrence in early-stage breast cancer. This patient is ER+, so she would benefit from hormonal therapy with either tamoxifen or an aromatase inhibitor (anastrozole). Anastrozole is indicated only in postmenopausal patients. All patients with stage II or higher receptor-positive cancers would benefit from a course of chemotherapy before the start of hormone therapy. Patients with overexpression of HER2/neu would benefit from trastuzumab, a monoclonal antibody to the HER2/neu receptor.</p> |
| <ul style="list-style-type: none"> ■ What is the prognosis for patients with this condition? | <p>Breast cancer in its early stages is curable, with 5-year survival rates for strictly localized receptor-positive tumors being > 90%. Stage IV disease is almost always fatal.</p> |
-

► **CASE 4**

A 26-year-old engaged woman presents with the complaint of a foul-smelling vaginal discharge. She denies any vulvar pruritus or dyspareunia, although she has noticed the presence of a thin, grayish discharge. Physical examination reveals an afebrile, well-appearing, slightly anxious young woman with a blood pressure of 125/85 mm Hg and heart rate of 80/min. A pelvic examination shows watery, grayish discharge with a vaginal pH > 4.5. Mixing the discharge with potassium hydroxide produces a fishy odor. Results of a wet prep for microscopic evaluation are shown in Figure 12-1.

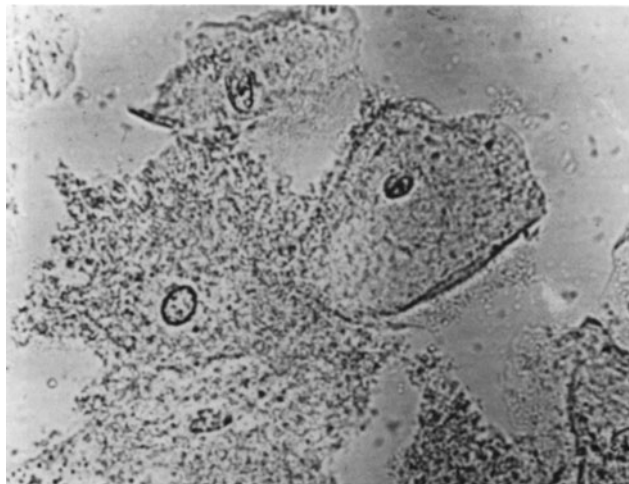

FIGURE 12-1. (Reproduced, with permission, from Tintinalli JE, Kelen GD, Stapczynski S, Ma OJ, Cline DM. *Tintinalli's Emergency Medicine: A Comprehensive Study Guide*, 6th ed. New York: McGraw-Hill, 2006: Fig. 108-1.)

■ **What is the most likely diagnosis?**

Bacterial vaginosis (BV). BV is the most common cause of vaginitis in women of childbearing age, although it is often called “vaginosis” rather than “vaginitis” due to the absence of inflammation. It is not a sexually transmitted disease. The condition is thought to arise when there is a shift in the normal vaginal flora, with a reduction of lactobacilli and an increase in other organisms such as *Gardnerella vaginalis*, *Mobiluncus* species, *Mycoplasma hominis*, and anaerobic gram-negative rods such as *Bacteroides* and *Peptostreptococcus* species. Thus, any condition that leads to an imbalance of the normal vaginal flora, such as antibiotic administration or pregnancy, can increase the risk of BV.

■ **What are the diagnostic criteria for this condition?**

Three of the four following criteria must be met:

- **Clue cells** on saline wet mount. Clue cells are vaginal epithelial cells with adherent coccobacilli seen on the edge of the cells (as shown in Figure 12-1); they are pathognomonic for BV.
- Vaginal pH > 4.5.
- Positive “whiff test” (presence of a fishy odor when KOH is added to a sample of vaginal discharge).
- Homogenous gray-white discharge.

<ul style="list-style-type: none"> ■ What is the most appropriate treatment for this condition? 	<p>All symptomatic women as well as asymptomatic women undergoing certain gynecologic procedures (hysterectomy, abortion) should be treated with oral or intravaginal metronidazole or clindamycin, as the presence of BV in these surgical patients has been linked to a greater incidence of pelvic inflammatory disease (PID). For recurrent BV, the treatment of sexual partners can be considered.</p>
<ul style="list-style-type: none"> ■ What are possible complications from this condition? 	<p>BV is associated with an increased risk of preterm labor and delivery in affected pregnant women, increased acquisition and transmitting HIV, and postpartum endometritis. BV is more common in women with PID, but it does not appear to be independently causal.</p>
<ul style="list-style-type: none"> ■ What are possible complications from the treatment of this condition? 	<p>Patients taking oral metronidazole should avoid alcohol, as it can lead to a disulfiram-like reaction, with flushing, headaches, nausea, vomiting, sweating, or tachycardia. Disulfiram-like reactions have not been reported with topical metronidazole use.</p>

► **CASE 5**

A 45-year-old G4P3 woman presents to her gynecologist complaining of a 3-month history of spotting and postcoital bleeding. She takes no medication and has not seen a doctor in 10 years. Her last Pap smear was 15 years ago; she thinks it was normal. On physical examination she is afebrile, with a heart rate of 80/min and blood pressure of 130/80 mm Hg. Speculum examination reveals normal external genitalia and normal vaginal mucosa, but the cervix has a 2-cm friable lesion protruding from the os. Bimanual examination reveals a retroverted uterus with no masses palpated.

- **What is the most likely diagnosis?** Invasive cervical carcinoma. Cervical carcinoma is rare in the developed world because of widespread screening protocols. It is usually caught before symptoms develop, but a common presentation of advanced cervical cancer includes vaginal discharge, metrorrhagia, postcoital bleeding, and pain.

 - **How is this condition staged?** Pap smear abnormalities are reported using the Bethesda classification, which rates abnormal cells as being of unknown significance, low- or high-grade intraepithelial lesions, or carcinoma. Histologic diagnosis from a biopsy will report levels of cervical intraepithelial neoplasm (CIN I, II, and III represent mild, moderate, or severe dysplasia, respectively) that precede carcinoma. Once the diagnosis of cancer is made, the International Federation of Gynecology and Obstetrics (FIGO) staging system is as follows:
 - Stage 0—carcinoma in situ (preinvasive).
 - Stage I—confined to the cervix.
 - Stage II—extending to upper two-thirds of vagina and uterus.
 - Stage III—extending to lower vagina or pelvic sidewall.
 - Stage IV—spreading to adjacent or distant organs.

 - **What risk factors are associated with an increased incidence of this condition?** The most important risk factor for cervical cancer is infection with oncogenic human papillomavirus (HPV) type 16, 18, or 31. A greater number of sexual partners increases the risk of contracting HPV and thus cervical cancer. Other associated risk factors are lack of screening, multiparity, smoking, and HIV infection.

 - **What is the most appropriate treatment for this condition?** The treatment modalities used for precancerous lesions include observation, colposcopy with directed biopsy, loop electrocautery, cryotherapy, and cone biopsy. See Table 12-2. Once a lesion is visible and highly suspicious for carcinoma (as in this patient), a biopsy is taken and an examination under anesthesia is done for clinical staging. Treatment involves surgery with or without radiation and chemotherapy. Stage III and IV cancers are treated with chemotherapy and radiation alone.

 - **How may this condition be prevented?** Pap smear screening is the best tool against cervical cancer because of the predictable, slow progression before invasive carcinoma develops, and intervention at one of the earlier stages can be curative. Current recommendations are that annual screening begin within 3 years of initiation of sexual activity or age 21, while women 30 years and older can increase the interval to 2–3 years if they have had three consecutive normal Pap smears. HPV testing can be used in the management of minimally abnormal Pap smears and as an additional screening test for women > 30 years of age.
-

TABLE 12-2. Diagnostic Screening of Precancerous Lesions

	ADOLESCENTS (20 Years Old and Younger)	WOMEN < 30 YEARS OLD	WOMEN > 30 YEARS OLD	PREGNANT WOMEN
Abnormal squamous cells of undetermined significance (ASCUS)	Repeat Pap smear in 12 months. Colposcopy if still positive	If HPV positive, perform colposcopy	Managed same as women under 30; only difference is with negative HPV testing can reduce screening to once every 2–3 years	If HPV positive, may perform colposcopy, but strong recommendation to wait 6 weeks postpartum
Low-grade squamous intraepithelial lesion (LSIL)	Repeat Pap smear in 12 months. Colposcopy if still positive	Colposcopy		Colposcopy recommended. Note that endocervical curettage is contraindicated
High-grade squamous intraepithelial lesion (HSIL)	Loop electrosurgical excision procedure (LEEP) or colposcopy			Same as above; note that invasive carcinoma will require aggressive treatment despite pregnancy

► **CASE 6**

A 22-year-old woman presents to the health clinic complaining of fever and malaise. Upon further questioning she admits to a foul vaginal discharge, vulvar pain, and pain with urination. She recently returned home from a study abroad program in Southeast Asia and admits to being sexually active with another student in her program. Her temperature is 38.6° C (101.5° F). There is significant tender left-sided lymphadenopathy in the inguinal region. Examination of the external genitalia reveals three painful, well-demarcated soft ulcers on the labia majora and minora. The ulcers have ragged edges and necrotic bases. Pelvic examination reveals a foul-smelling purulent discharge.

-
- **What is the most likely diagnosis?** Chancroid. Chancroid is a sexually transmitted infection caused by the gram-negative bacillus *Haemophilus ducreyi*. The infection is spread by direct sexual contact when the organism invades an open lesion; the organism cannot invade intact tissue. Chancroid, along with granuloma inguinale, is most common in developing or third-world countries; thus, these organisms are most often seen in the United States in patients with a recent travel history to those countries. It is important to differentiate a chancroid from the primary chancre of syphilis, although the chancre is usually painless.

 - **How is the diagnosis made?** Chancroid is generally diagnosed clinically, as it is difficult to isolate the causative organism, *H. ducreyi*. In some patients, the swollen inguinal lymph nodes (usually unilateral) may break through the skin and produce draining abscesses. These abscesses are called buboes, and aspirated pus from a bubo provides the best material for culturing and isolating the organism. Polymerase chain reaction of genital samples is becoming a more widely available form of testing.

 - **What other infections should be considered in a patient with this condition?** Patients presenting with genital ulcers should be screened for other sexually transmitted infections such as chlamydia, gonorrhea, HIV, hepatitis B virus, and hepatitis C virus. Genital ulcers are an important factor in the spread of HIV, as HIV-negative persons with genital ulcers have higher rates of acquisition, and HIV-positive persons with genital ulcers transmit HIV more effectively.

 - **How do the genital lesions in this condition compare to those in other sexually transmitted diseases?** See Table 12-3.

 - **What is the most appropriate treatment for this condition?** The best treatment option is one dose of azithromycin (1 g by mouth) or ceftriaxone (250 mg intramuscularly). Ciprofloxacin (500 mg by mouth twice a day for 3 days) is another option, but less desirable given the multidose requirement.
-

TABLE 12-3. Differential Diagnosis of Genital Ulcerative Lesions

	GRANULOMA INGUINALE	CHANCROID	HERPES SIMPLEX VIRUS (HSV)	LYMPHOGRANULOMA VENEREUM	SYPHILIS
Causative agent	<i>Calymmatobacterium granulomatis</i>	<i>Haemophilus ducreyi</i>	HSV type 2 (most cases)	<i>Chlamydia trachomatis</i> L1–L3	<i>Treponema pallidum</i>
Appearance/ characteristics of lesions	Granulomatous ulcers with rolled edges	Irregular, deep, well demarcated, nonindurated ulcers	Multiple, small grouped vesicles on erythematous base	Small, shallow rapidly healing ulcers; usually not observed	Indurated, smooth borders on a clean base
Pain	No	Yes	Yes	No	No
Adenopathy	Pseudobuboes	Inguinal; unilateral, painful	Reactive nodes	Matted clusters, often bilateral, painful buboes	Regional, nontender
Other	Over 50% of patients have lesions in the anal area			Women rarely notice this lesion in primary stage (3–12 days or longer)	

► **CASE 7**

A 32-year-old woman presents with a chief complaint of bilateral breast pain, with greater pain in her right than left breast. The patient's maternal grandmother had breast cancer at age 60, but otherwise there is no family history of breast or ovarian cancer. On physical examination, the patient's breasts appear symmetric, without dimpling, rashes, or nipple inversion or discharge. Her breasts are tender to palpation bilaterally, and several 2–3-cm masses are palpated in her upper outer right breast. The masses are movable and round, with discrete borders and a “rubbery” feel. The patient reports that the pain increases toward the latter part of her menstrual cycle and that she is currently not taking any contraceptives.

- **What is the most likely diagnosis?** Fibrocystic breast disease. This benign source of breast pain most frequently occurs in women aged 30–50, with resolution of symptoms occurring at menopause. Symptoms worsen throughout the latter part of the menstrual cycle, due to the associated increase in estrogen. The pain usually occurs in both breasts, and patients will complain that their breasts feel “heavy,” “lumpy,” or otherwise tender. The breast “masses” in fibrocystic disease are movable and of a rubbery or cystlike consistency, can change shape, and usually have smooth borders. While nipple discharge is not a usual symptom, it can occur.

 - **What conditions should be included in the differential diagnosis?** The clinician should be able to differentiate between a fibrocystic mass and fibroadenoma or malignant breast cancer. Missed breast cancer diagnoses are among the most frequent malpractice claims, and a diagnosis of fibrocystic disease should not preclude a thorough exam and workup for underlying malignant causes. A patient with breast cancer would most likely present with a hard, fixed, and irregular mass. Most breast cancers are painless (excluding inflammatory breast cancer), and nipple discharge is more likely depending on what type or stage of breast cancer is present. A fibroadenoma, though benign, can be hard to distinguish from fibrocystic disease on physical exam, but fibroadenomas are usually painless. They also most frequently occur in women under the age of 35. Malignant degeneration of a fibroadenoma occurs in less than 1% of patients; this malignant form of fibroadenoma is known as cytosarcoma phyllodes.

 - **What is the most appropriate next step in diagnosis?** The patient has two dominant, palpable breast masses > 1 cm in diameter. The physician can proceed either with ultrasound or fine-needle aspiration (FNA). If the mass cannot be visualized on ultrasound, or if imaging reveals a complex cyst or solid mass, the patient should undergo a core-needle biopsy (mammograms in this age group are usually not recommended, due to the density of breast tissue). If the mass appears to be a simple cyst on ultrasound, the physician may perform an FNA and repeat a breast exam in 4–6 weeks. If the aspirate is bloody or the mass does not resolve after FNA, the patient should receive a core-needle biopsy (or mammogram if over the age of 40). If the FNA reveals the presence of a solid mass, the physician should be most concerned about a malignant tumor, and core-needle biopsy should be performed.
-

- **What is the most appropriate treatment for this condition?**

Once the diagnosis of fibrocystic breast disease is confirmed, this patient should be encouraged to continue breast self-exams and alert the physician of any changes. The patient should return to the office in 4–6 weeks, and the drained cystic area should be examined for resolution. Dietary changes may also help this patient cope with fibrocystic pain. Reducing salt intake and caffeine and taking nonsteroidal anti-inflammatory drugs and vitamin E supplements all may provide relief. Prescribing oral contraceptives may also help alleviate breast pain in this patient; they have been reported to help over 70% of women in alleviation of symptoms.

► **CASE 8**

A 29-year-old nulligravid woman presents to her gynecologist complaining of pelvic pain, dyspareunia, and heavy cramping and back pain during her menses. On physical examination, she has a heart rate of 75/min and blood pressure of 125/80 mm Hg. Pelvic examination reveals a normal cervix, with tenderness of the posterior fornix on bimanual examination. No masses are palpated. Gonorrhea and chlamydia cultures are negative, as is a pregnancy test.

-
- **What is the most likely diagnosis?** Endometriosis. In endometriosis, isolated implants of endometrial tissue are found outside of the uterine lining, scattered in the pelvic cavity; see Figure 12-2 for the sites most commonly involved. These estrogen-dependent implants cause dysmenorrhea and can result in extensive scarring and pelvic pain. With pregnancy and pelvic inflammatory disease (PID) ruled out, this diagnosis is suggested by her typical symptoms.

 - **What tests and/or imaging tools could be used to confirm the diagnosis?** Laparoscopy, with direct visualization and biopsy of suspected lesions, is used to confirm cases of endometriosis. Typical lesions have a “raspberry” or “powder-burned” appearance, while implants on the ovary are known as endometriomas or “chocolate cysts.” While the disease is graded (minimal, mild, moderate, severe) based on pathology, symptom severity is not well correlated with the number of lesions. Endometriosis is more prevalent in Asians and whites than African-Americans and is most frequently diagnosed in women aged 25–35.

 - **What is the most appropriate treatment for this condition?** Treatment of endometriosis is divided into medical and surgical options. When nonsteroidal anti-inflammatory drugs do not offer relief, medical management focuses on mimicking the states of pregnancy and menopause during which the disease often remits. Thus, options include oral contraceptive pills (OCPs, combined or progesterone only), danazol (an androgen with progestin-like activity), and gonadotropin-releasing hormone (GnRH) analogs (nafarelin or leuprolide, which suppress the gonadal axis at the pituitary). Because diagnostic laparoscopy is so commonly performed, lesions are often ablated at the same time. However, in severe cases, hysterectomy and oophorectomy can be performed if fertility is not desired.

 - **What adverse events are associated with treatment?** OCPs are well tolerated and can be used for a long duration if fertility is not desired. Danazol and GnRH analogs have more severe side effects; their use is limited to 4–9 months. Adverse effects of danazol include weight gain, acne, and hirsutism. GnRH agonists induce a “pseudomenopause” with all the associated symptoms: vasomotor activity, vaginal dryness, and decreased bone mineral density. Add-back therapy with estrogens or progestins can decrease these adverse effects and increase the possible duration of therapy.

 - **What are possible complications of this disorder?** Severe endometriosis can cause infertility, disabling pain, and bowel or urinary obstruction. An associated disorder, adenomyosis, is the presence of endometrial glands within the myometrium of the uterus, with major symptoms of dysmenorrhea and menorrhagia.
-

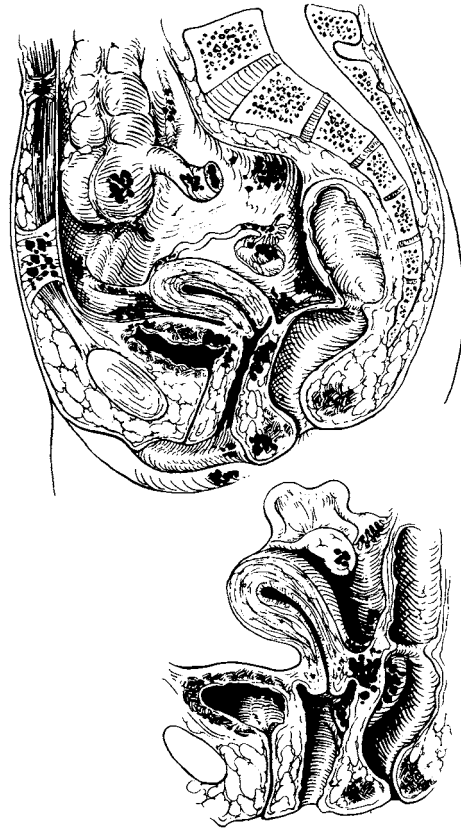


FIGURE 12-2. Frequent sites of deposits in endometriosis. (Reproduced, with permission, from Doherty GM, Way LW. *Current Surgical Diagnosis and Treatment*, 12th ed. New York: McGraw-Hill, 2006: Fig. 41-1.)

► **CASE 9**

A 32-year-old African-American G0 woman presents to her gynecologist for her annual examination. She complains of increased fatigue over the past year and thinks her periods may be heavier than before. She also notes increasing dysmenorrhea. Menarche was at age 9, and she denies previous problems with her periods. She has generally been healthy and takes hydrochlorothiazide for high blood pressure. On physical examination, she appears pale and tired. Vital signs include heart rate of 105/min and blood pressure of 120/78 mm Hg. Cardiac, lung, and abdominal exams are within normal limits. On pelvic exam, there is no discharge or cervical motion tenderness. Her uterus feels enlarged to 12-week size and misshapen. Laboratory tests reveal a hemoglobin of 8.7 g/dL and hematocrit of 27%.

- **What is the most likely diagnosis?** Uterine leiomyomata, or fibroids, leading to menorrhagia and iron-deficiency anemia. These monoclonal growths of uterine smooth muscle are the most common benign neoplasm of the female genital tract. Malignant transformation to leiomyosarcoma is extremely rare.

 - **How is this condition classified?** Fibroids are classified based on their location in the uterine wall:
 - Intramural: found within the uterine wall.
 - Submucosal: develop just below the endometrium and may protrude into the uterine cavity; most likely to interfere with fertility and cause bleeding.
 - Subserosal: originate just below the serosal surface; may have a broad or pedunculated base.Fibroid location can be most clearly delineated by MRI.

 - **What is the epidemiology of this condition?** Fibroids are extremely common, found in ~80% of hysterectomy specimens. The disease is slightly more prevalent and seems to be more severe in African Americans, who typically present with disease in their 20s, versus Caucasians, who present in their 30s. Risk factors include:
 - Early menarche (< 10 years).
 - Family history.
 - Polycystic ovarian syndrome.
 - Hypertension, especially in African-Americans.The following factors are thought to be protective:
 - Parity (pregnancies beyond 20 weeks).
 - Use of oral contraceptives.

 - **How can this condition present?** The majority of fibroids are asymptomatic. When symptoms do result, they fall into three major categories.
 - Increased uterine bleeding
 - Pelvic pressure and pain
 - Reproductive dysfunctionIncreased bleeding due to fibroids occurs only during a woman's period; intermenstrual bleeding necessitates a workup for endometrial pathology. Symptoms typically abate with menopause, as fibroids shrink.
-

■ **What is the most appropriate treatment for this condition?**

Treatment of fibroids depends on the woman's desire for childbearing and the severity of symptoms. Nonsteroidal anti-inflammatory drugs can be taken for fibroid-associated pain. Other pharmacologic management includes medroxyprogesterone acetate or danazol to control bleeding. Gonadotropin-releasing hormone analogs can decrease myoma size and growth, thus decreasing symptoms. Women with severe symptoms who still desire fertility should undergo myomectomy; those who have completed childbearing can have a total or subtotal abdominal or vaginal hysterectomy.

► **CASE 10**

A 21-year-old sexually active college student visits the student health office complaining of “bumps” on the posterior introitus. She denies dyspareunia, vulvar itching, change in vaginal discharge, or dysuria. She admits to having multiple sexual partners. She uses oral contraceptive pills; her partners use condoms rarely. On physical examination, there are multiple 2–3-mm flesh-colored, pedunculated papules on the posterior introitus and the labia.

■ **What is the most likely diagnosis?** Condyloma acuminata (genital warts). Genital warts are caused by the human papillomavirus (HPV), of which there are more than 70 subtypes. Certain subtypes, such as HPV 16 and 18, are able to integrate into the host genome and have been strongly associated with squamous cell carcinomas including cervical and anal cancers. Subtypes 6 and 11 are considered low risk for causing malignant changes and are most frequently associated with benign condylomas.

■ **What risk factors are associated with an increased incidence of this condition?**

- History of sexually transmitted diseases.
- Immunosuppression such as HIV infection.
- Multiple sexual partners.
- Preexisting vaginitis.
- Pregnancy.
- Diabetes.

The disease can be acquired through sexual activity as well as contact via digital/anal, oral/anal, or digital/vaginal routes.

■ **What is the most appropriate treatment for this condition?**

There are three approaches to treating this condition: chemical/physical destruction, immunologic therapy, or surgical excision. The number and extent of lesions should be considered when choosing a therapy. For lesions that do not respond, an excisional biopsy should be performed to rule out malignancy. Initial treatment options include topical podophyllin or trichloroacetic acid followed by home treatments of imiquimod (an immune modulator) or podofilox. Cryotherapy, laser therapy, or surgical excision may be considered for lesions that do not respond to topical therapies or cover an extensive area.

■ **What are the potential complications if this condition is untreated?**

Untreated lesions may grow to the point of requiring surgical excision. Although the HPV subtypes associated with genital warts do not generally cause malignant changes, the patient may be coinfecting with other subtypes with a malignant potential. Pap smears should be performed on women to look for evidence of cervical dysplasia or neoplasia.

► CASE 11

A 44-year-old woman presents to her gynecologist complaining of menstrual irregularity. In the past year, she has missed four periods, and her menstrual flow has been lighter than usual. She has not noticed the presence of clots and denies spotting between periods or after intercourse. She reports frequent headaches, difficulties sleeping, and mood swings. She denies the presence of hot flashes, decrease in libido, or vaginal dryness. She does not take oral contraceptives (OCPs) and has never had gynecologic surgery. Physical examination reveals no abnormalities.

- | | |
|---|--|
| <p>■ What is the most likely diagnosis?</p> | <p>Perimenopause. This is the transitional period that occurs before a woman becomes completely amenorrhoeic. To be classified as menopausal, a woman must experience at least 12 months of amenorrhea. Perimenopause is marked by various menopausal symptoms, accompanied by erratic menstruation. This period can extend as long as 10 years prior to menopause.</p> |
| <p>■ What other symptoms are common in patients with this condition?</p> | <ul style="list-style-type: none"> ■ Mood disturbance ■ Sleep disturbances ■ Hot flashes ■ Depression/difficulty with concentration ■ Osteoporosis ■ Urinary incontinence/frequency ■ Urogenital atrophy/vaginal dryness |
| <p>■ What is the most appropriate next step in diagnosis?</p> | <p>Although follicle-stimulating hormone (FSH) levels can be obtained to confirm the onset of menopause, they are unreliable throughout perimenopause because FSH is intermittently elevated and fluctuates greatly throughout this time period. Consistently elevated FSH levels (> 30 IU/L) are indicative of menopause, in addition to amenorrhea of at least a year's duration. A clinician making a diagnosis of perimenopause based on symptomatology should be aware of other possible causes of irregular menstruation in a woman of this age. Pregnancy must still be ruled out, and patients should be screened for fibroids, thyroid disease, and endometrial cancer.</p> |
| <p>■ What is the most appropriate treatment for this condition?</p> | <p>Many women go through perimenopause without utilizing medications. Women can be prescribed OCPs to stabilize hormonal fluctuations and antidepressants to stabilize mood swings. Physicians can counsel women to make lifestyle changes that will make the transition into menopause easier; exercising regularly, minimizing caffeine intake, and starting herbal treatments may all provide relief from menopausal symptoms. It is also important to advise patients that they still must use a form of contraception while in perimenopause, since they are not anovulatory until they actually enter menopause.</p> <p>Many women choose to take hormone replacement therapy (HRT) to reduce the symptoms of menopause. Women who have not undergone a hysterectomy usually receive estrogen/progestin therapy (unopposed estrogen increases the risk for endometrial cancer), while women who have undergone hysterectomies can receive estrogen-only therapy. While HRT reduces the incidence of osteoporosis in this population, it also can increase the risk of blood clots, stroke, breast cancer, and heart disease, so short-term treatment is recommended.</p> |
-

► **CASE 12**

A 55-year-old postmenopausal G1P1 woman presents to her primary care physician complaining of fatigue, abdominal discomfort, and bloating. She has mild nausea and anorexia, but no vomiting. On physical examination, she has a temperature of 38° C (100.4° F), heart rate of 85/min, respiratory rate of 18/min, and blood pressure of 130/80 mm Hg. Abdominal examination reveals distention, shifting dullness, a fluid wave, and slight tenderness to palpation with no masses. Head and neck, cardiovascular, chest, and musculoskeletal examinations are all unremarkable. Pelvic examination reveals normal external genitalia and cervix, but a fixed, nodular mass is palpated on the left adnexa. A transvaginal ultrasound reveals a 5-cm mass with cystic and solid elements on the left ovary and fluid in the cul-de-sac. No abnormalities are appreciated on the right ovary. CA-125 level is 150 U, while complete blood count and electrolyte panel are within normal limits.

-
- **What is the most likely diagnosis?** Ovarian cancer. While most ovarian masses are benign, ovarian cancer is the fifth leading cause of cancer death in women. Clues that this mass is malignant rather than benign are the presence of ascites; a fixed, palpable mass > 5 cm; a complex, rather than simple, cystic composition; and a CA-125 level > 35 U.
-
- **What risk factors are associated with an increased incidence of this condition?** Ovarian cancer is rare, with risk related to the total number of ovulation events. Thus, nulliparity and delayed childbearing are risk factors, while oral contraceptive pills are protective. Carriers of *BRCA1* and *BRCA2* mutations are at high risk and are the only individuals for whom screening is advocated. Ovarian cancer is also a feature of the Lynch II syndrome of familial malignancies.
-
- **How is this condition classified?**
- Stage I—growth limited to ovaries.
 - Stage II—growth extending to pelvis or presence of ascites.
 - Stage III—peritoneal or omental implants or inguinal or retroperitoneal nodes.
 - Stage IV—distant metastases, including malignant pleural effusion.
- Most cases are not diagnosed until they cause clinical symptoms, usually already stage III or IV. If ovarian cancer is diagnosed before spread outside the ovaries, over 90% of patients will survive > 5 years.
-
- **What is the most appropriate next step in management?** A staging and debulking procedure should be scheduled as soon as possible. As part of the preoperative workup, a CT scan of the abdomen and pelvis should be done to further evaluate the mass and look for metastases. An x-ray of the chest will look for pleural effusions, a common complication and indicator of more severe disease.
-
- **What is the surgical management of this condition?** Even if all of the tumor cannot be surgically removed, a thorough debulking procedure should be done. To stage the disease, multiple biopsies should be taken of lymph nodes and peritoneal surfaces, even if there is no macroscopic disease. A bilateral salpingo-oophorectomy/total abdominal hysterectomy with omentectomy and removal of all tumor with < 1 cm of visible disease remaining will improve outcome and should be performed by an experienced gynecologic oncologist.
-
- **What is the medical management of this condition?** After cytoreductive surgery, chemotherapy is essential in all but confirmed early stage I disease. The most common combination is paclitaxel and a platinum agent.
-

► **CASE 13**

A 22-year-old woman presents to the gynecologist's office complaining of pain with sexual intercourse. She states that the pain began 1 week prior but has continued to worsen. In addition to the dyspareunia, she complains of vaginal itching. She is in a steady relationship, although she does admit to having intercourse with more than one partner in the past month. She does not use condoms but does take an oral contraceptive pill. On physical examination, she is a well-appearing young woman. She is afebrile, with blood pressure of 120/80 mm Hg and heart rate of 75/min. She is nontender to palpation throughout her abdomen. On pelvic examination, a mucopurulent discharge is noted. Visualization of the cervix reveals a red, inflamed cervix. The cervix is extremely tender when swabbed and when moved on bimanual examination.

-
- **What is the most likely diagnosis?** Cervicitis. Cervicitis is an infection of the cervix that often presents with vaginal itching, burning, and/or a mucopurulent discharge. The infection may also be asymptomatic. Because of the continuous nature of the female genital tract, there is some overlap between cervicitis and vulvovaginitis. Cervicitis is distinguished from pelvic inflammatory disease by the lack of systemic symptoms and lack of abdominal or adnexal tenderness. However, cervical motion tenderness is often present in both conditions.
-
- **How is the diagnosis made?** The diagnosis is made based on clinical history and clinical examination findings. The history and examination findings that support a diagnosis of cervicitis include unprotected sexual intercourse with multiple partners and examination findings of mucopurulent cervical discharge, cervical erythema, and friability of the cervical os. Microscopic inspection of vaginal discharge to identify bacterial vaginosis or trichomoniasis, a Pap smear to identify atypical cells (and possibly human papillomavirus), and culture for *Neisseria gonorrhoeae* and *Chlamydia trachomatis* are all appropriate measures.
-
- **What is the etiology of this condition?**
- Infectious (most common)
 - *Chlamydia trachomatis*
 - Human papillomavirus (HPV)
 - *Neisseria gonorrhoeae*
 - *Trichomonas*
 - Herpes simplex virus (HSV)
 - Noninfectious
 - Autoimmune diseases
 - Measles
 - Neoplasia
 - Stevens-Johnson syndrome
 - Trauma (mechanical or chemical)
-
- **What is the most appropriate treatment for this condition?** Patients should be treated for both gonorrhea and chlamydia since coinfection occurs frequently. Sexual partners should be treated as well. Treatment regimens include:
- One of the following for gonorrhea:
 - Ceftriaxone
 - Ciprofloxacin
 - Ofloxacin
 - Levofloxacin
 - Plus one of the following for chlamydia:
 - Azithromycin
 - Doxycycline
-

► **CASE 14**

A 19-year-old woman presents to the emergency department complaining of abdominal pain. She states that the pain is worse in her lower abdomen. She has had multiple sexual partners and rarely uses condoms since she is taking an oral contraceptive. She has noticed increased pain with sexual intercourse over the past few weeks. Her last menstrual period was 5 days ago. On physical examination, her temperature is 39.0° C (102.2° F), blood pressure is 110/70 mm Hg, and heart rate is 80/min. Her abdomen is soft but tender to palpation in the lower quadrants. The pelvic examination reveals a purulent discharge from the cervical os with cervical motion tenderness. A Gram stain of the discharge reveals intracellular gram-negative diplococci.

-
- **What is the most likely diagnosis?** Pelvic inflammatory disease (PID). PID is a polymicrobial sexually transmitted ascending infection of the upper genital tract. *Neisseria gonorrhoeae* and *Chlamydia trachomatis* are known causative pathogens, often with both infections occurring simultaneously. Fifteen percent of endocervical infections with gonorrhea or chlamydia progress to PID. Other organisms such as *Bacteroides* species, *Escherichia coli*, *Haemophilus influenzae*, and *Mycoplasma* may be involved.
-
- **What risk factors are associated with an increased incidence of this condition?**
- African-American ethnicity.
 - Age < 35 years.
 - Having a partner with symptomatic chlamydial or gonococcal urethritis.
 - History of PID.
 - Multiple sexual partners.
 - Nonbarrier contraception.
- Up to 75% of cases present within 1 week of menses.
-
- **What tests and/or procedures could be used to confirm the diagnosis?**
- The diagnosis of PID is complicated by the fact that PID represents a spectrum of disease, and many women may have only mild symptoms. Empiric treatment is recommended if the patient has an examination suggestive of PID (lower abdominal pain, purulent cervical discharge, and/or cervical motion tenderness, adnexal or uterine tenderness), the patient's risk factors are consistent with PID, and a pregnancy test is negative. A diagnosis of PID may be confirmed by histologic evidence of endometritis on biopsy or laparoscopy, demonstration of *N. gonorrhoeae* or *C. trachomatis* in the genital tract, or imaging studies revealing fluid-filled oviducts. Other noninvasive diagnostic tests that may be helpful include laboratory studies looking for evidence of inflammation (C-reactive protein, CBC, erythrocyte sedimentation rate).
-
- **What is the most appropriate treatment for this patient?**
- This patient has an examination suggestive of PID; she should therefore be started on therapy. Treatment options include intramuscular ceftriaxone followed by doxycycline for 14 days or cefoxitin plus probenecid. Patients may require hospitalization if a tubo-ovarian abscess is present, they are noncompliant, there are signs of systemic infections, or they are unable to take or absorb oral antibiotics. Inpatient therapy includes cefoxitin or cefotetan plus doxycycline. Clindamycin plus gentamicin is an alternative regimen. Sexual partners should be examined and treated as necessary.
-

■ **What are the potential complications associated with this condition?**

- Dyspareunia
 - Ectopic pregnancy
 - Gonococcal perihepatitis (Fitz-Hugh–Curtis syndrome)
 - Increased risk of infertility
 - Repeated infection
 - Tubo-ovarian abscess formation
 - Chronic pelvic pain
-

► **CASE 15**

A 22-year-old nulligravid woman presents to her gynecologist because of irregular, widely spaced menses. Menarche was at age 14, but she has rarely had regular cycles. For the past year, she has had only three complete menses, once going 6 months between periods. She is sexually active and uses condoms for contraception. Upon physical examination, she has a temperature of 37° C (98.6° F), heart rate of 80/min, and blood pressure of 140/85 mm Hg. She is 165 cm (5'4") tall and weighs 83 kg (190 lb). She is overweight, with acne and a few dark hairs on her upper lip and chin. Speculum and bimanual examination reveal normal external and internal genitalia without tenderness or masses.

-
- **What is the most likely diagnosis?** Polycystic ovarian syndrome (PCOS). Based on the Rotterdam criteria, a patient must have any two of the following:
 - Oligo and/or anovulation.
 - Clinical and/or biochemical signs of hyperandrogenism (hirsutism/acne).
 - Polycystic ovaries by ultrasound.
-
- **What are other causes of this condition?** Secondary amenorrhea can be due to hormonal or anatomical causes. Pregnancy is the most common cause, with premature menopause, discontinuing hormonal contraception, and hypo- or hyperthyroidism as other prevalent causes. Other underlying disorders include Asherman's syndrome, pituitary adenoma, or functional ovarian or adrenal tumor. Hypothalamic disturbance due to stress, weight change, or systemic disease should also be investigated.
-
- **What tests could be used to confirm the diagnosis?** A pregnancy test should be done. An ultrasound will look for the "string of pearls" sign indicating classic polycystic ovaries and confirm normal uterine anatomy. A positive progestin withdrawal test (induced menses after 10 days of progestin therapy) will identify anovulatory cycles rather than uterine abnormalities or estrogen deficiency as the cause of the amenorrhea. Levels of follicle-stimulating hormone (FSH), luteinizing hormone (LH), testosterone, and dehydroepiandrosterone sulfate (DHEAS) should be measured. PCOS patients have a high LH/FSH ratio and elevated total testosterone. If PCOS is ruled out, prolactin and thyroid-stimulating hormone (TSH) levels should be measured, and a dexamethasone stimulation test should be performed to rule out hypercortisolism.
-
- **What are the management options for this patient?** The management of PCOS focuses on treating the hyperandrogenism and hirsutism, metabolic disturbances, and infertility. Oral contraceptive pills are very effective at creating regular cycles and halting excess androgen production, although they do nothing to affect hair that is already established. Metformin and weight reduction have been shown to help insulin resistance and promote normal follicular cycles. Clomiphene is used for ovulation induction if fertility is desired.
-
- **What are the potential complications associated with this condition?** The unopposed estrogen resulting from anovulatory cycles puts patients with PCOS at higher risk for endometrial hyperplasia and neoplasm. An association has also been noted between PCOS and insulin resistance, type 2 diabetes mellitus, and metabolic syndrome. Prolonged exposure to high levels of testosterone can lead to virilization, with male-pattern baldness, voice deepening, and clitoromegaly.
-

► CASE 16

A 70-year-old G3P3 woman complains of 2 months of painless intermittent vaginal spotting. She went through menopause at age 52 and was using hormone replacement therapy (HRT) until 3 years ago. Her past medical history is significant for type 2 diabetes. She is 170 cm (5'6") tall and weighs 82 kg (180 lb). On physical examination, she is afebrile, with heart rate of 75/min and blood pressure of 135/80 mm Hg. On speculum examination, the external genitalia are normal, while the vaginal walls are dry and atrophic. The cervix has no lesions, and a drop of blood is seen at the os. An intravaginal ultrasound is performed in the office, revealing a 7-mm endometrial stripe. A Pap smear and endometrial biopsy are done and results are sent to pathology.

-
- **What is the most likely diagnosis?** Endometrial hyperplasia. This patient presented with postmenopausal bleeding, defined as any vaginal bleeding that starts after 12 months of postmenopausal amenorrhea. The most important consideration in postmenopausal women presenting with bleeding is to rule out endometrial carcinoma and its precursor, endometrial hyperplasia. The thickened stripe seen on ultrasound suggests hyperplasia; the biopsy specimen will determine if it has malignant potential.

 - **What conditions should be included in the differential diagnosis?** While the uterus is the most likely source of postmenopausal bleeding, other locations in the genital tract must be investigated. Atrophic vaginal mucosa is friable and tends to bleed easily. Cervical carcinoma must be ruled out with a Pap smear and biopsy if a lesion is seen. Within the uterus, benign polyps, leiomyomas, or adenomyosis can also cause bleeding.

 - **What risk factors are associated with an increased incidence of this condition?** The risk factors for endometrial hyperplasia and carcinoma are the same, with the most important being unopposed estrogen. This can be endogenous (nulliparity, late menopause) or exogenous (HRT). Progesterone must be given to any woman with a uterus on estrogen replacement. Obesity and diabetes are risk factors due to the excess estrogen produced by adipose tissue. In younger women, polycystic ovarian syndrome is an important cause of unopposed estrogen, and any woman on tamoxifen for breast cancer treatment is at higher risk for hyperplasia. It should be noted that there is a second, rare class of endometrial cancer that is not hormone dependent; this cancer tends to be more malignant, has serous or clear-cell histology, and appears in multiparous women.

 - **How is this condition classified?** Endometrial hyperplasia is a histologic diagnosis made from an endometrial biopsy taken when the endometrial stripe on ultrasound is ≥ 4 –5 mm or if suspicion of cancer is high. Endometrial hyperplasia is classified as simple or complex, with or without atypia. Simple hyperplasia without atypia is benign, while complex hyperplasia with atypia is considered premalignant.

 - **What are the management strategies for this condition?** If the patient has hyperplasia without atypia, the treatment is a 3-month course of cyclic progestin therapy (medroxyprogesterone acetate or norethindrone acetate) followed by another endometrial biopsy to ensure resolution. If hyperplasia with atypia or carcinoma is found, hysterectomy is recommended. Because excess unopposed estrogen causes hyperplasia, estrogen levels should be determined to rule out an estrogen-producing ovarian neoplasm.
-

► **CASE 17**

A 32-year-old woman presents to the city health clinic after she noticed an ulceration on her vulva. She first noticed the lesion about 1 week prior. She has a history of gonorrhea and is worried that this may be another sexually transmitted infection. She recently became sexually active with a new partner, and she denies using any form of protection. She denies any other symptoms. On examination of the external genitalia, a painless, ulcerated papule is observed in the vestibule of the vagina. The ulcer has a smooth, clean base with indurated borders. The remainder of the pelvic examination is unremarkable.

- | | |
|---|--|
| ■ What is the most likely diagnosis? | Primary syphilis, the first stage of infection by the spirochete <i>Treponema pallidum</i> , is characterized by a painless ulcer (also known as a chancre) that appears on or near the site of contact 10–60 days after infection. Often the lesion will go unnoticed and heal spontaneously in 1–2 months. |
| ■ What conditions should be included in the differential diagnosis? | The conditions that should be considered in the differential for the chancre observed in primary syphilis include: <ul style="list-style-type: none">■ Genital herpes■ Lichen planus■ Lymphogranuloma venereum■ Psoriasis■ Chancroid (<i>Haemophilus ducreyi</i>) |
| ■ What tests could be used to confirm the diagnosis? | <ul style="list-style-type: none">■ Dark-field microscopy: identifies motile spirochetes from primary and secondary lesions only.■ Venereal Disease Research Laboratory (VDRL) test/rapid plasma reagin (RPR): a rapid and cheap test, but with only 60–75% sensitivity in primary syphilis. The test becomes negative after treatment.■ Fluorescent treponemal antibody absorption test (FTA-ABS): a sensitive and specific test that remains positive for life. It is used as a secondary diagnostic test. |
| ■ What is the most appropriate treatment for this condition? | Intramuscular penicillin is the treatment of choice. In patients who are allergic to penicillin, tetracycline or doxycycline may be used. In cases of neurosyphilis, intravenous penicillin should be used. |
| ■ What is the natural progression of this condition if left untreated? | If left untreated, primary syphilis may progress to secondary syphilis 4–8 weeks after the appearance of the chancre. <ul style="list-style-type: none">■ Secondary syphilis is characterized by low-grade fever, generalized lymphadenopathy, and a maculopapular rash on the palms and soles. Condyloma lata (hypertrophic, flat, wartlike lesions) may also be observed.■ Secondary syphilis is followed by the early latent phase, which encompasses the first year of infection. No symptoms are present, but serology is positive.■ The late latent phase is characterized by asymptomatic infection < 1 year during which serologies may be positive or negative. One-third of cases will go on to tertiary syphilis.■ Tertiary syphilis occurs 1–20 years after initial infection. It is characterized by granulomatous gummas, neurologic findings (tabes dorsalis, Argyll Robertson pupils), and cardiac findings (aortic root aneurysms, aortitis, aortic regurgitation). |
-

► **CASE 18**

A 38-year-old woman presents to the emergency department with nausea, vomiting, fever, and chills. A few days prior to the onset of these symptoms, she developed a rash over most of her body that resembles a sunburn. She has no prior medical history. She is currently menstruating and regularly uses “super-absorbent” tampons. She reports that she has not been changing her tampons as frequently since her pharmacy was out of her usual brand. On examination, her temperature is 39.0° C (102.2° F), blood pressure is 90/60 mm Hg, heart rate is 110/min, and oxygen saturation is 96%. She appears visibly ill. A diffuse macular erythematous rash is present over most of her body, and her conjunctivae appear injected. Relevant laboratory findings include a WBC count of 18,000/mm³, hemoglobin of 11.0 g/dL, and a platelet count of 90,000/mm³.

-
- **What is the most likely diagnosis?** Toxic shock syndrome (TSS). TSS results from localized infection of soft tissues with *Staphylococcus aureus*. Infections may arise from tumors, abscesses, burns, osteomyelitis, and postsurgical sites. TSS has been associated with the use of tampons, with higher-absorbency products leading to greater risk. Contraceptive sponges have also been associated with TSS. Most cases of TSS occur in women of childbearing age; however, non-menstrual-related cases have become almost as common as menstrual-related cases.

 - **What is the pathogenesis of this condition?** TSS is caused by the preformed *Staphylococcus aureus* exotoxin TSST-1. TSST-1 acts as a superantigen that stimulates the production of interleukin-1 (IL-1) and tumor necrosis factor (TNF), leading to systemic inflammation. This causes generalized vasodilation and subsequent loss of blood pressure.

 - **What are the typical laboratory findings in this condition?** The abnormal laboratory findings reflect the multisystem involvement of TSS and include the following:

 - CBC: leukocytosis, anemia, thrombocytopenia (< 100,000).
 - Urinalysis: mild pyuria, elevated BUN and creatinine.
 - Liver function tests: elevated bilirubin, elevated AST and ALT.
 - Blood cultures: negative (illness is due to an exotoxin, not invasion of the organism).

 - **What are the typical physical findings in this condition?** All patients with definite TSS have fever > 38.9° C (102.0° F), hypotension, and skin manifestations. The initial rash is characterized by a diffuse, red, macular rash resembling a sunburn. Late-onset skin manifestations include a pruritic maculopapular rash that may occur 1–2 weeks after disease onset and desquamation of the palms and soles that characteristically begins 1–3 weeks after illness develops. TSS can involve all other organ systems. Many patients report diffuse myalgias and weakness as presenting symptoms. Gastrointestinal symptoms are also common, particularly profuse diarrhea.

 - **What is the most appropriate treatment for this condition?** Immediate supportive treatment with fluid replacement is indicated if hypotension and shock are present. This also includes oxygen therapy and placement of a central venous pressure line or a pulmonary arterial catheter for hemodynamic monitoring. Any potential sources of infection should be addressed, including removal of tampons or drainage of abscesses. Systemic antistaphylococcal therapy should be started with a β-lactamase-resistant penicillin (e.g., nafcillin or oxacillin) or a cephalosporin.

 - **What is the prognosis for patients with this condition?** The mortality rate for TSS is approximately 5%. Most patients will recover in 1–2 weeks. Up to 30% of women with a history of TSS may have a recurrence.
-

► **CASE 19**

A 27-year-old woman in her first trimester of pregnancy complains of intense vaginal itching with a profuse greenish discharge. She also notes a foul odor to the discharge. She states that she is in a monogamous relationship with her boyfriend of 6 months. They initially used condoms during intercourse, but they have not used any form of contraception for the past 2 months. On physical examination, the patient is afebrile, with blood pressure of 125/80 mm Hg and heart rate of 85/min. The pelvic examination reveals a malodorous, frothy greenish-gray discharge with inflammation of the cervix and vaginal mucosa. Punctate hemorrhages are visible on the cervix. The vaginal pH is > 4.5 , and motile organisms are seen on a wet prep of the vaginal discharge (as seen in Figure 12-3).

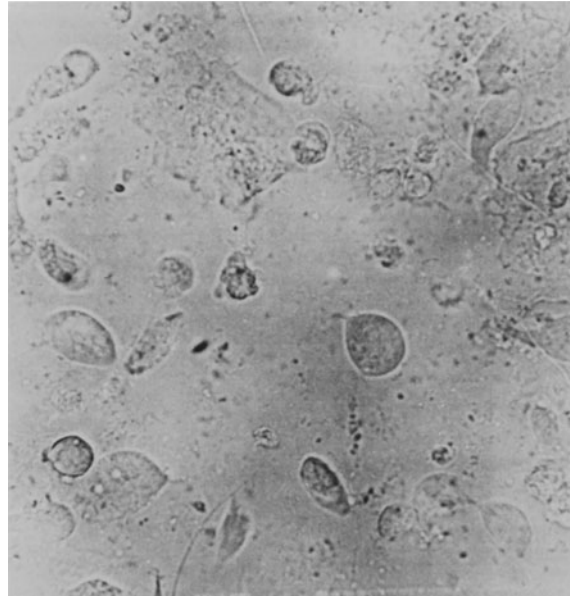


FIGURE 12-3. (Reproduced, with permission, from Tintinalli JE, Kelen GD, Stapczynski S, Ma OJ, Cline DM. *Tintinalli's Emergency Medicine: A Comprehensive Study Guide*, 6th ed. New York: McGraw-Hill, 2006: Fig. 108-3.)

-
- | | |
|--|--|
| <p>■ What conditions should be included in the differential diagnosis?</p> | <ul style="list-style-type: none">■ Atrophic vaginitis■ Bacterial vaginosis■ Candidiasis■ Chlamydia■ Gonorrhea■ Irritant or allergic vaginitis■ Trichomoniasis |
|--|--|
-

<ul style="list-style-type: none"> ■ What is the most likely diagnosis? 	<p>Trichomonal vaginitis is a sexually transmitted infection caused by the flagellated protozoan <i>Trichomonas vaginalis</i>. The incidence of this infection is approximately 25%. Changes in the cervical and vaginal epithelium caused by the infection may result in false-positive Pap smear results. Patients with <i>Trichomonas</i> are twice as likely to develop HIV as the general population, and other sexually transmitted diseases such as chlamydia and gonorrhea are frequently found to coexist along with <i>Trichomonas</i>.</p>
<ul style="list-style-type: none"> ■ How is the diagnosis made? 	<p>The diagnosis is made by visualizing motile flagellated organisms (as seen in Figure 12-3) with polymorphonuclear leukocytes on a saline smear of the vaginal discharge. Evidence of trichomonal infection may be seen on a Pap smear.</p>
<ul style="list-style-type: none"> ■ What risk factors are associated with an increased incidence of this condition? 	<ul style="list-style-type: none"> ■ Intrauterine contraceptive device use. ■ Tobacco use. ■ Unprotected sex with multiple partners.
<ul style="list-style-type: none"> ■ What is the most appropriate treatment for this condition? 	<p>Trichomonal vaginitis is a sexually transmitted infection, therefore the partners of infected patients should be tested and treated as appropriate. A single dose of metronidazole is the treatment of choice.</p>

► **CASE 20**

A 67-year-old woman is being seen by her primary care physician for her annual checkup. She denies any recent illness but states that she has been having a problem with very sudden, severe urges to go to the bathroom. If she cannot find a restroom quickly, she sometimes loses control of her bladder. She is becoming more and more nervous about going out in public. She denies dysuria or stool incontinence. She does not take any medications. On physical examination, she is comfortable, and her vital signs are within normal limits. Abdominal examination does not reveal any evidence of fecal impaction. Neurologically, she has good muscle tone, including the rectal sphincter. Urinalysis is negative for WBCs, bacteria, and leukocyte esterase.

■ **What is the most likely diagnosis?** Urge incontinence. Urinary incontinence, or the involuntary leakage of urine, affects 30–50% of women and 17% of men over 60 years of age; however, it is frequently underdiagnosed due to patients' reluctance to report it to their provider. Urge incontinence is due to overactivity of the detrusor muscle or sphincter dysfunction. Etiologies include neurological causes (inhibited contractions, central nervous system dysfunction) and inflammatory conditions (cystitis, stone, or tumor).

■ **How is this condition classified?** There are a number of different types of incontinence:

- Total: uncontrolled, continuous loss of urine due to fistula or loss of sphincter activity.
- Stress: loss precipitated by an increase in intra-abdominal pressure (coughing, sneezing) due to pelvic floor weakness; common in multiparous women.
- Urge: loss follows a strong, unexpected urge to void.
- Overflow: patients have chronic urinary retention, leading to chronically distended bladder that leaks urine past the sphincter.

■ **If no urogenital pathology is found, what are other possible causes of this condition?** Other causes include increased need to void or functional impairment preventing continent voiding, more common in the elderly. These etiologies can be remembered with the mnemonic **DIAPPERS**:

Delirium/confused state
Infection
Atrophic urethritis/vaginitis
Pharmaceutical
Psychiatric causes (i.e., depression)
Excessive urinary output (i.e., diabetes)
Restricted mobility
Stool impaction

■ **How are the different types of incontinence managed?** Patients with total incontinence should undergo a cystogram to identify the fistula; surgery will be required. Stress incontinence is initially managed medically with Kegel exercises to strengthen the pelvic floor; pessary use may be considered. Surgery may be required to move the bladder neck to the appropriate location if medical therapy fails. Urge incontinence can be treated with anticholinergic medications or tricyclic antidepressants. Finally, overflow incontinence is managed with intermittent self-catheterization and/or timed voiding; underlying diseases should be identified and treated.

► **CASE 21**

A 35-year-old G1P1 woman presents to her gynecologist complaining of vaginal itching, discomfort, and discharge of a white “creamy” consistency. Her last menstrual period was 3 weeks ago, and she does not report any new sexual partners. She uses an intrauterine device (IUD) for contraception. Her temperature is 37.0° C (98.6° F), heart rate is 80/min, and blood pressure is 125/80 mm Hg. Speculum examination reveals erythematous and slightly edematous external genitalia. The vaginal walls are coated with a thick, white discharge, but the cervix appears normal, and the IUD string is visible from the os. A sample is taken, two slides are made, and the pH is determined to be 4.0. The saline-prepared slide shows only epithelial and inflammatory cells, while the potassium hydroxide-treated slide shows pseudohyphae and budding yeasts. There was no odor noted upon treatment with potassium hydroxide.

-
- **What is the most likely diagnosis?** Vulvovaginal candidiasis. Classic symptoms include a white, odorless, “cheesy” discharge and vulval swelling, itching, and discomfort. The wet mount with budding yeasts and pseudohyphae confirms the diagnosis.
-
- **What conditions should be included in the differential diagnosis?** The two other common causes of vaginitis are bacterial vaginosis and trichomoniasis.
- Bacterial vaginosis is caused by *Gardnerella vaginalis* and other anaerobes that are usually suppressed by the dominance of *Lactobacillus* species. The most common symptom is a discharge with an unpleasant, “fishy” odor. The wet mount in *G. vaginalis* infection shows epithelial cells with adherent bacteria (“clue cells”) without the presence of inflammatory cells. Preparation with potassium hydroxide reveals the characteristic amine odor (the “whiff test”).
 - Trichomoniasis is a sexually transmitted disease caused by the *Trichomonas* protozoa. The classic presentation is a frothy green discharge. Diagnosis is made by visualizing the motile protozoa on saline wet mount.
- Less common causes of vaginitis include atopic and contact dermatitis.
-
- **What risk factors are associated with an increased incidence of this condition?** Risk factors for vulvovaginal candidiasis include:
- Antibiotic use
 - Diabetes mellitus
 - Immunosuppression (steroids, HIV)
 - Oral or barrier contraceptive use
 - Pregnancy
-
- **What is the pathophysiology of this condition?** Like *Gardnerella*, *Candida* species (most commonly *C. albicans*) are part of the normal vaginal flora. However, when the vaginal pH changes or normal flora are eradicated by antibiotics, *Candida* rapidly replaces normal flora and causes symptoms. It can be “bounced back” by a partner and cause recurrent infection but is not considered a sexually transmitted disease.
-
- **What is the most appropriate treatment for this patient?** This patient has an uncomplicated infection, so her treatment options include 3–7 days of topical azole treatment or single-dose oral fluconazole. A complicated infection is one in a diabetic, immunosuppressed, or pregnant patient, in a patient with a history of recurrence (≥ 4 /year) or severe symptoms, or disease caused by a *Candida* species other than *C. albicans*. Treatment of complicated infection requires 14 days of a topical azole or 2 days of fluconazole.
-

Pediatrics

Case 1	360
Case 2	362
Case 3	364
Case 4	365
Case 5	366
Case 6	368
Case 7	370
Case 8	371
Case 9	372
Case 10	374
Case 11	376
Case 12	377
Case 13	378
Case 14	380
Case 15	382
Case 16	384
Case 17	385
Case 18	386
Case 19	387
Case 20	388
Case 21	389
Case 22	390
Case 23	391
Case 24	392
Case 25	393
Case 26	394
Case 27	396
Case 28	398
Case 29	399

► CASE 1

An 8-month-old girl is brought to the emergency department by her grandmother for being “too sleepy.” On the day of admission, the grandmother noted that she was difficult to arouse and had decreased oral intake. On examination, the child has a temperature of 37.5° C (99.5° F), a heart rate of 140/min, and a respiratory rate of 28/min. She is somnolent but withdraws all four extremities to painful stimuli. Physical examination is unremarkable except for a 2 × 2-cm hematoma on her right buttock. Relevant laboratory findings include a WBC count of 9000/mm³ (85% neutrophils), hemoglobin of 9.4 g/dL, and platelet count of 355,000/mm³. Lumbar puncture reveals a WBC count of 4/mm³, RBC count of 264/mm³, glucose of 82 mg/dL, and protein of 41 mg/dL. An x-ray of the chest reveals a fracture of the lateral aspect of the right first rib and a healing fracture of the right clavicle.

-
- **What is the most likely diagnosis?** Nonaccidental trauma (child abuse). Without a history of trauma (including a difficult delivery) or intrinsic bone disease, rib fractures in infancy are strongly suggestive of abuse. Examination findings of injuries that are not consistent with the history or age of the child, multiple injuries in various stages of healing, injuries that are pathognomonic for child abuse (e.g., cigarette burns), or different types of coexisting injuries (bruises, burns, fractures) are concerning for abuse.
-
- **What conditions should be included in the differential diagnosis of fracture in a child?**
 - Metabolic or congenital:
 - Ehlers-Danlos syndrome
 - Osteogenesis imperfecta
 - Rickets
 - Accidental trauma:
 - Stress fracture
 - Toddler’s fracture (subtle nondisplaced spiral fracture resulting from a rotational injury while running or playing)
-
- **What is the next step in the workup of this patient?** A complete skeletal survey is indicated in preschool-aged children when physical abuse is suspected. Radiographs in a skeletal survey should minimally include single anteroposterior (AP) views of each extremity and the pelvis, as well as AP and lateral views of the chest and skull. These films should be repeated in 7–10 days to reveal healing fractures not seen on the initial films.
-
- **What are the common radiological manifestations of this condition?** Certain fractures are much more specific for nonaccidental trauma:
 - Compression fractures of vertebral bodies.
 - Fractures at the edges of metaphyses—“bucket-handle” fracture, corner fracture.
 - Healing fractures of various ages, exuberant callus formation.
 - Isolated spiral fracture in infants.
 - Rib fractures—often posterior ribs.
 - Scapular and sternal fractures.
 - Separation of distal epiphyses.
-

- **What additional studies should be considered?**
 - Bone scan (skeletal scintigraphy) is complementary to skeletal survey.
 - CT scan of the head should be performed to identify subarachnoid, subdural, or intraparenchymal injury.
 - Liver and pancreatic enzyme studies or an abdominal CT scan may uncover damage to these organs.
 - MRI of the head can detect small subdural hemorrhages or parenchymal injury not visualized by CT and to provide better information than CT regarding age of the hemorrhage.
 - Ophthalmologic examination can identify retinal hemorrhages.
 - Urine and stool should be screened for blood if abdominal trauma is suspected.
-

► **CASE 2**

A 3-year-old boy with a history of recurrent infections is brought to the emergency department by his parents for left arm pain. The patient had fallen while climbing a tree 2 weeks ago and, 2 days prior to admission, had developed fever and left arm swelling. A radiograph of the left arm reveals an osteolytic lesion with periosteal reaction, consistent with osteomyelitis of the left ulna. Past medical history is significant for recurrent perianal abscesses since birth and repeated episodes of oral thrush, lymphadenitis, and bacterial enterocolitis. He was hospitalized at 14 months of age for osteomyelitis of the left proximal tibia caused by *Serratia marcescens* that responded well to antibiotic treatment. Family history is unremarkable, and there is no history of genetic disease.

■ What conditions should be considered in the differential diagnosis?	Immunodeficiency disorders should be considered when patients experience frequent or severe bacterial infections beginning in early life. The differential includes the following: <ul style="list-style-type: none">■ Primary immunodeficiencies including functional defects in the antibody-mediated system (B cells), the cell-mediated system (T cells), the phagocytic system, and the complement system.■ Secondary immunodeficiencies including immunosuppressive drugs and HIV.
■ A nitroblue tetrazolium dye reduction (NBT) test is positive. What is the most likely diagnosis?	Chronic granulomatous disease (CGD). A positive NBT test suggests phagocyte dysfunction and is the traditional diagnostic test for CGD (a newer test, dihydrorhodamine 123 [DHR] assay, is more sensitive than NBT and can differentiate among the different forms of the disease). CGD is a heterogeneous group of disorders characterized by genetic defects in the ability of phagocytes to generate reactive oxygen intermediates from molecular oxygen. The genetic mutations result in the loss or functional inactivation of one of the components of NADPH oxidase, which is used by phagocytes to generate reactive oxidants. For the boards: think CGD when you see a positive NBT test.
■ What are some of the common clinical manifestations of this condition?	<ul style="list-style-type: none">■ Chorioretinitis.■ Gingivitis.■ Granulomata are most commonly found in the GI tract.■ Lupus syndromes.■ Recurrent infections such as pneumonia, abscesses (including skin and liver), lymphadenitis, osteomyelitis, bacteremia/fungemia, and superficial skin infections (cellulitis/impetigo).
■ What are the most common offending pathogens in this condition?	In general, the organisms that infect patients with CGD are catalase producing. Common infecting organisms include the following: <ul style="list-style-type: none">■ <i>Aspergillus</i>■ <i>Burkholderia cepacia</i>■ <i>Candida albicans</i>■ <i>Nocardia</i> spp.■ <i>Serratia marcescens</i>■ <i>Staphylococcus</i> species, especially <i>Staphylococcus aureus</i>
■ What is the most common mechanism of inheritance in this condition?	Approximately 70% of patients with CGD are males who inherit their disease as an X-linked recessive trait. The other 30% of patients have autosomal recessive inheritance.

■ **What is the most appropriate treatment for this condition?**

- Long-term antimicrobial and antifungal prophylaxis, typically with trimethoprim-sulfamethoxazole (TMP-SMX). Trimethoprim alone or dicloxacillin may be used if patient is allergic to TMP-SMX. Itraconazole is the most commonly used antifungal agent.
 - Immunomodulatory prophylaxis: Interferon- γ has been shown to be beneficial in infection prevention.
 - Corticosteroids are beneficial in the treatment of noninfectious CGD-associated granulomata.
 - Bone marrow transplant is the only known cure for CGD.
-

► CASE 3

A 2-week-old girl is admitted to the neonatal intensive care unit (NICU) with hypovolemic shock and is found to have hyponatremia and hyperkalemia. She was born full term and was noted to have ambiguous genitalia with hypospadias and a marked ventral chordee that could have been either a penis or an enlarged clitoris. An ultrasound on her second day of life revealed a normal uterus and ovaries, as well as normal kidneys and bladder. Chromosomal analysis showed a 46,XX karyotype. In the NICU, she is found to have markedly elevated plasma 17-hydroxyprogesterone levels and low plasma cortisol levels.

-
- | | |
|---|--|
| <p>■ What is the differential diagnosis of virilization in a patient with XX genotype?</p> | <ul style="list-style-type: none">■ Congenital adrenal hyperplasia.■ Gestational hyperandrogenism due to exposure to maternal androgen or synthetic progestational agents.■ SRY translocation—the SRY gene is responsible for initiating male sexual differentiation.■ “True hermaphroditism”—when both an ovary and a testicle, or ovatestes, are present in an individual; due to 46,XY/46,XX mosaicism. |
| <p>■ What is the most likely diagnosis?</p> | <p>Congenital adrenal hyperplasia (CAH), due to a deficiency of 21-hydroxylase (also known as CYP21A2). CAH is the most common cause of female pseudohermaphroditism and the most common intersex disorder. Because of an enzyme defect, the adrenal glands overproduce testosterone and ACTH and decrease synthesis of cortisol. 21-Hydroxylase deficiency is the most common enzyme defect (95% of cases) that causes CAH. Many children are now screened for this condition at birth as part of routine neonatal screening.</p> |
| <p>■ What are the most common clinical features associated with this condition?</p> | <p>21-Hydroxylase deficiency results in several clinical syndromes. Two of these syndromes, a simple virilizing form (presenting as genital ambiguity) and a salt-wasting form, are recognized in neonates and very young infants. Salt wasting occurs in 75% of patients with classical disease and is evident within the first 2 weeks of life, with resultant hyponatremia, hypokalemia, and inappropriate sodium wasting (high urine sodium despite hyponatremia) due to low serum aldosterone and elevated plasma renin activity.</p> |
| <p>■ What laboratory and imaging studies should be done to evaluate the infant with ambiguous genitalia?</p> | <ul style="list-style-type: none">■ Biochemical studies—serum 17-hydroxyprogesterone, deoxycorticosterone, electrolytes, and glucose.■ Chromosomal karyotype.■ Cystovaginoscopy.■ Genitogram.■ Gonadal inspection and biopsy.■ Pelvic ultrasound. |
| <p>■ What is the most appropriate treatment for this condition?</p> | <p>Glucocorticoids are the mainstay of treatment for CAH in order to suppress abnormal adrenal steroidogenesis. Mineralocorticoid replacement (fludrocortisone) may also be needed to maintain electrolyte homeostasis.</p> |
| <p>■ What adverse events are associated with treatment?</p> | <p>Numerous adverse effects have been attributed to glucocorticoids. The major systemic side effects of glucocorticoid therapy are suppression of hypothalamic-pituitary-adrenal function (leading to adrenal atrophy and loss of cortisol secretory capability) and Cushing’s syndrome. If correctly dosed and monitored, adverse effects of replacement therapy are typically minimal.</p> |
-

► **CASE 4**

A boy at 33 weeks' gestation is born via spontaneous vaginal delivery. Membranes are ruptured at the time of delivery with clear amniotic fluid. His mother did not seek prenatal care but denies any medical problems during the pregnancy. She denies tobacco, alcohol, and illicit drug use. At delivery, the infant is small, and his length and weight are < 25% for gestational age. His head is microcephalic. Ophthalmologic examination reveals chorioretinitis. He is pink, with good respiratory effort. His skin is mildly jaundiced with diffuse raised red/purple lesions and petechiae. His anterior fontanelle is soft but full. His sclerae are mildly icteric. His abdomen appears distended and protuberant, but it is soft and nontender. A firm liver edge is felt 4 cm below the right costal margin, and the spleen is felt 3 cm below the left costal margin. The remainder of the examination is unremarkable. Laboratory results are significant for a hemoglobin of 9 g/dL and a platelet count of $45 \times 10^3/\text{mm}^3$ with an atypical lymphocytosis (10%). Direct serum bilirubin is elevated at 8 mg/100 mL. Three hours after birth, the infant develops generalized tonic-clonic seizures that stop after administration of 20 mg/kg of phenobarbital. Cranial ultrasound reveals periventricular calcifications.

<p>■ What conditions should be included in the differential diagnosis?</p>	<p>Infections in the newborn infant can be classified as congenital or perinatal. A congenital infection is an infection seen in the newborn infant that was acquired transplacentally. A perinatal infection is acquired either around the time of delivery or during the first week of extrauterine life. The patient's physical findings of jaundice, petechiae, blueberry muffin spots, hepatomegaly, and splenomegaly suggest congenital infection. The most common congenital infections are the ToRCHeS: Toxoplasmosis, Other (HIV, parvovirus), Rubella, Cytomegalovirus (CMV), Herpes, and Syphilis.</p>
<p>■ What is the most likely diagnosis?</p>	<p>Periventricular calcifications seen on cranial ultrasound, microcephaly, chorioretinitis, and petechiae suggest CMV infection, the most common congenital infection.</p>
<p>■ What tests could be used to confirm the diagnosis?</p>	<p>The diagnosis of congenital CMV infection is best made by isolating the virus in urine culture within the first 3 weeks of life. PCR can be used on amniotic fluid, urine, saliva, blood, CSF, and biopsy material to confirm the diagnosis.</p>
<p>■ What is the most appropriate treatment for this patient?</p>	<p>Gancyclovir is recommended for the treatment of infants with symptomatic congenital CMV infection to reduce progression of sensorineural hearing loss. The treatment of newborns with asymptomatic CMV congenital infection currently is not indicated.</p>
<p>■ What is the prognosis for this patient?</p>	<p>Mortality can be as high as 20–30% in this fulminant syndrome and occurs within a few days or weeks. Long-term morbidity is the rule for survivors. More than 80% of infants with congenital CMV infection who are symptomatic at birth will develop late complications that may include hearing loss, vision impairment, and varying degrees of mental retardation and delay in psychomotor development.</p>
<p>■ If the cranial ultrasound had revealed diffuse calcifications in the brain, what would be the most likely diagnosis?</p>	<p>Congenital toxoplasmosis causes diffuse intracranial calcifications. Other common findings in congenital toxoplasmosis infections include chorioretinitis, hydrocephalus, and ring-enhancing lesions on head CT.</p>

► **CASE 5**

A 7-year-old boy is admitted to the hospital with abdominal pain and weight loss of 4.5 kg (10 lb) over the past 5 months. During this time, his parents have noticed a change in his bowel habits, from 4–5 stools per week to daily stools that are occasionally mixed with blood. The abdominal pain is intermittent and cramping. On examination, he is thin, tired, and pale. His heart and lung examinations are normal. His abdomen is soft, with mild tenderness to palpation in the right lower quadrant. Rectal examination reveals an anal skin tag and guaiac-positive stool. Laboratory findings are significant for hemoglobin of 7.3 g/dL and erythrocyte sedimentation rate (ESR) of 77 mm/hr.

■ **What additional studies should be considered in the workup of this patient?**

- Abdominal plain film or CT scan.
- C-reactive protein.
- Celiac disease testing (e.g., anti-endomysial antibody titer).
- Colonoscopy.
- Liver function tests including albumin, PT, and PTT.
- Stool culture and test for *C. difficile* toxins A and B.
- Upper endoscopy.
- Upper gastrointestinal barium study with small bowel follow-through.

■ **Colonoscopy reveals linear ulcerations and luminal edema in the descending colon. What is the most likely diagnosis?**

The radiologic findings combined with the presence of bloody stool, history of abdominal pain and weight loss, anemia, and elevated ESR are strongly suggestive of Crohn's disease.

■ **What are the typical pathologic findings of this condition?**

- An abrupt transition between ulcerated and adjacent normal mucosa ("skip lesions").
- Chronic mucosal damage is the hallmark of inflammatory bowel disease.
- Crypt abscesses and ulceration.
- Mucosal inflammation.
- Noncaseating granulomas.
- Stricture formation.
- Transmural inflammation affecting all layers.

■ **What are the typical upper and lower endoscopy findings in this condition?**

- Crohn's disease may involve any part of the gastrointestinal tract, from the mouth to the anus. Involvement of the small intestine alone occurs in about 40% of cases, small intestine and colon in 30%, and the colon alone in about 30%.
- Focal mucosal ulcers resembling canker sores (aphthous ulcers), edema, and loss of the normal mucosal texture are commonly seen early in disease.
- Serosal extension of mesenteric fat (creeping fat).
- Narrowed lumen; in the small intestine this is evidenced on upper GI barium study as the "string sign."

■ **What are some extraintestinal manifestations of this condition?**

- Arthritis—peripheral (knees, ankles, hips, wrists, elbows) or axial (sacroiliitis, ankylosing spondylitis).
- Erythema nodosum.
- Hepatic primary sclerosing cholangitis.
- Renal stones.
- Uveitis, nonspecific mild hepatic pericholangitis, and renal disorders secondary to trapping of the ureters in the inflammatory process sometimes develop.

■ **What is the most appropriate treatment for this condition?**

- 5-Aminosalicylates—sulfasalazine, mesalamine.
 - Antibiotics—metronidazole.
 - Corticosteroids.
 - Immunomodulators—tumor necrosis factor- α (TNF- α), infliximab (anti-TNF- α immunoglobulin G antibody).
 - Bowel resection for severe cases.
-

► **CASE 6**

A 26-year-old woman gives birth to her first child at the local hospital. The mother's pregnancy was uncomplicated, but the delivery was complicated by breech presentation. On successful delivery of a female infant, the pediatrician performed a full newborn examination. Apgar scores were 9 and 10 at 1 and 5 minutes, respectively. All appropriate reflexes were present, and examination of the head, back, heart, lungs, and abdomen was normal. On examination of the hips, flexion and adduction of the hips produces an audible “clunk” and dislocation of the right hip. On flexion and abduction, the right hip relocates in the acetabulum.

- **What is the most likely diagnosis?** Developmental dysplasia of the hip (DDH). This is the diagnosis given to patients born with dislocation or instability of the hip and/or with abnormal growth of the hip. Many cases can be detected by the newborn hip exam, notably with the Barlow maneuver (flexion, adduction, and pressure directed backward on the knees causes dislocation) and the Ortolani maneuver (flexion and abduction or pressure directed outward on the knees causes relocation). Ultrasonography of the hips is currently the most sensitive method of detection in infants < 4 months of age. If the diagnosis is not made as a newborn, patients are often identified in the 3- to 6-month-old age group, when they will often present for a “well baby” visit with Allis’s (Galeazzi’s) sign (chronic hip dislocation leads to a leg length discrepancy detectable when the patient lies supine with knees flexed). DDH occurs in about 1.5% of newborns and is 4–8 times more common in females than males.

 - **What is the pathogenesis of this condition?** DDH occurs when there is a disruption of the normal relationship of the femoral head and the acetabulum. Without adequate contact, neither can develop normally, leading to an abnormally small femoral head and a shallow acetabulum. At birth, the acetabulum has a small bony component and a larger cartilaginous component. Because of this, the acetabulum is susceptible to remodeling during the first 6 weeks postnatally, making early diagnosis and treatment important to improving prognosis.

 - **What risk factors are associated with an increased incidence of this condition?**
 - Breech presentation.
 - Familial history of DDH.
 - Female sex.
 - First pregnancy.
 - High birth weight.
 - Multiple gestation.
 - Oligohydramnios.
 - Other postural or nonpostural deformities (e.g., clubfoot, congenital torticollis).
-

- What is the most appropriate treatment for this condition?

Management of this condition is largely determined by the age of the patient at diagnosis. The goals of treatment should be to establish and maintain a concentric reduction of the femoral head in the acetabulum; this will provide the necessary environment for full development of the femoral head and acetabulum. Children < 6 months old are best treated by a Pavlik harness (Figure 13-1). Children > 6 months old typically require open or closed reduction and a spica cast, with open reduction favored in those children > 2 years old. In patients > 3 years of age, open reduction, femoral shortening, and/or acetabular osteotomy may be required to maintain a concentric reduction of the hip joint.

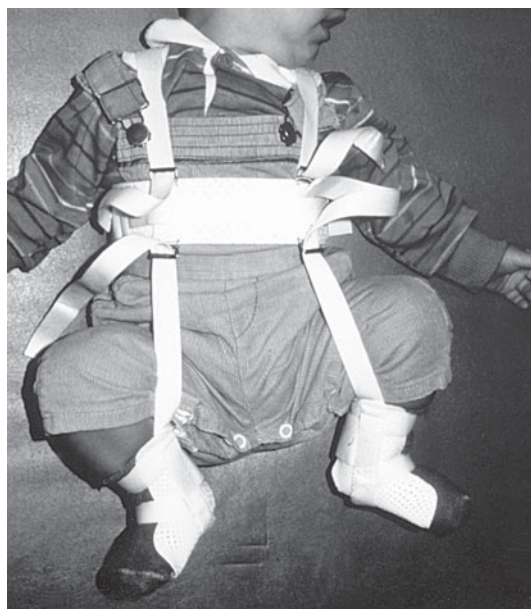

FIGURE 13-1. Pavlik harness. (Reproduced, with permission, from Skinner HB. *Current Diagnosis & Treatment in Orthopedics*, 3rd ed. New York: McGraw-Hill, 2006: Fig. 11-5.)

► **CASE 7**

A previously healthy 3-year-old boy presents to the emergency department with fever, stridor, and hoarseness. His mother reports that he has had a runny nose and mild cough for the past week. Overnight, she noted his cough had worsened and sounded “barking.” On examination, he has a temperature of 38.2° C (100.8° F), heart rate of 95/min, respiratory rate of 20/min, and pulse oximetry of 97% on room air. Pulmonary exam is significant for tachypnea and inspiratory stridor; mild retractions and nasal flaring are noted. Cardiac exam is unremarkable. Anteroposterior x-ray of the neck demonstrates subglottic narrowing consistent with a “steeple sign.”

■ What is the most likely diagnosis?	Laryngotracheobronchitis, or croup. This is a viral disease of the larynx commonly seen in patients aged 3 months to 3 years. It is a clinical diagnosis based on fever, stridor, and the characteristic barking cough; the “steeple sign” on x-ray supports the diagnosis but is neither sensitive nor specific. It is important to rule out other rare but significant causes of acute upper airway obstruction, such as epiglottitis or soft tissue infection.
■ What is the differential diagnosis for stridor?	<ul style="list-style-type: none">■ Laryngomalacia/tracheomalacia.■ Vocal cord paralysis.■ Infectious or spasmodic croup.■ Epiglottitis.■ Tracheitis.■ Tonsillitis/peritonsillar abscess/retropharyngeal abscess.■ Foreign body.
■ What are the common pathogens associated with this condition?	Parainfluenza virus types 1, 2, and 3 are the most common pathogens. Other possibilities include influenza, respiratory syncytial virus, and adenovirus. Bacterial superinfection may result in tracheitis.
■ What is the most appropriate treatment for this condition?	Croup is treated based on its clinical severity. Mild cases are discharged on outpatient mist therapy. More severe cases are distinguished by stridor at rest, respiratory distress, hypoxemia, cyanosis, pallor, altered mental status, or high fever. These patients are often admitted for nebulized racemic epinephrine and oral/IM corticosteroids.
■ What is the presentation of epiglottitis?	Patients with epiglottitis have the sudden onset (within 4–12 hours) of a high fever, muffled “hot potato” voice, dysphagia, and drooling. They adopt the “tripod position,” leaning forward with a hyperextended neck and their mouth open. Severe respiratory distress develops within minutes to hours, and these patients must undergo emergent intubation or tracheostomy. The incidence of epiglottitis has substantially decreased with the introduction of the HIB (<i>Haemophilus influenzae</i> type B) vaccine.

► **CASE 8**

A mother brings her three children to their pediatrician’s office for checkups. While in the waiting room, the oldest child hops around the room and then begins to play with blocks. She speaks clearly and can count 10 blocks. When another child comes over, they build a block tower together. The middle child is using the furniture for support as he explores the waiting room. He sees a red crayon and picks it up using his thumb and forefinger. He then waves bye-bye to a child who is leaving the office. The youngest child sits on her mother’s lap and holds a toy. She babbles while her mother reads to her. When one of her siblings comes over, she smiles at them. When a nurse says hello, she does not smile immediately but she takes a toy from her. All three children are healthy and have no developmental issues.

<p>■ What is the most likely age range of the oldest child?</p>	<p>Between 4 and 5 years. This child is speaking clearly so that strangers understand her, is hopping around the room, and is able to engage in cooperative play. She is also able to count to 10. It is likely that she is also able to throw a ball overhead, copy basic shapes, and correctly name some colors. Over the next year, she will likely begin to print some letters, dress herself, and use a fork and spoon.</p>
<p>■ What is the most likely age of the middle child?</p>	<p>Approximately 12 months. This child is able to cruise (walk while holding onto furniture) and uses a pincer grasp to pick up a crayon. In the next 6 months, he will likely begin to say a few words, walk without help, identify pictures in a book, and follow simple one-step directions.</p>
<p>■ What is the most likely age of the youngest child?</p>	<p>Six months. This child is babbling, knows familiar faces, has some stranger anxiety, and reaches for and grasps objects. She can also probably sit by herself, help hold the bottle during feeding, and move toys from one hand to another. Over the next 6 months, she will likely begin to crawl, drink from a cup, feed herself finger food, and say her first word.</p>
<p>■ Assuming the youngest child is 6 months old, which vaccinations will she be receiving during this visit?</p>	<p>Assuming she is up to date with all her previous vaccinations, she will probably be getting her third dose of DTaP (diphtheria, tetanus, and pertussis), HiB (<i>Haemophilus influenzae</i> type B), rotavirus, and conjugate pneumococcal vaccine. She may also receive her third dose of hepatitis B vaccine and polio vaccine, which can be given any time from 6 to 18 months of age.</p>
<p>■ The middle child is noted to have a runny nose and a low-grade fever 37.6° C (99.6° F) during this visit. Should he still receive his vaccinations?</p>	<p>Yes, he should still receive his vaccinations despite having a mild illness. Contraindications to getting vaccinations include:</p> <ul style="list-style-type: none"> ■ A moderate or severe illness. ■ A severe allergy to a component of the vaccine. ■ Anaphylactic egg allergy for influenza vaccine. ■ Encephalopathy within 7 days of prior pertussis vaccination. ■ Live vaccines in immunocompromised and pregnant patients. ■ Recent administration of immunoglobulin (for live injected vaccines, i.e., varicella and measles, mumps, and rubella [MMR]).

► **CASE 9**

A 2-week-old girl is brought to the clinic for her first checkup. She was born full term to a 37-year-old G6P3 mother who received no prenatal care and delivered the infant at home. Weight and height are both under the 5th percentile. She is dysmorphic, with upslanting palpebral fissures, epicanthal folds, small ears, and a protruding tongue. Physical examination is significant for a 3/6 harsh holosystolic murmur best heard at the left mid- to lower sternal border and generalized hypotonia. Her extremities are warm and well perfused. She has a transverse palmar crease on both hands.

-
- **What is the most likely diagnosis?** Down syndrome. The dysmorphic features of upslanting palpebral fissures, epicanthal folds, and transverse palmar (simian) creases are highly suggestive of trisomy 21 (Down syndrome). Frequency increases with advanced maternal age. In mothers < 25 years of age, the risk is 1 in 2000 births and climbs to 1 in 20 births for mothers over age 40 years.
-
- **What are the methods of inheritance for this condition?** Down syndrome is caused by trisomy 21, the most common autosomal trisomy in newborns. There are three types of cytogenic abnormalities that result in Down syndrome:
- Trisomy 21: The additional copy of chromosome 21 usually results from nondisjunction, an error in meiosis. This genotype occurs in 94% of children with Down syndrome.
 - Robertsonian translocation involving chromosome 21: The entire long arm of chromosome 21 is translocated to the long arm of an acrocentric chromosome. This accounts for 3–4% of cases.
 - Trisomy 21 mosaicism: There are two populations of cell types: a normal cell line and a second cell line with trisomy 21. This occurs in 2–3% of cases.
-
- **What is the most likely explanation of the heart murmur?** Approximately 50% of individuals with Down syndrome have congenital heart disease. The harsh holosystolic murmur is most likely caused by a small ventricular septal defect. The most common heart lesions in these patients are:
- Atrioventricular septal defect—45%.
 - Ventricular septal defect—35%.
 - Isolated secundum atrial septal defect—8%.
 - Isolated patent ductus arteriosus—7%.
 - Isolated tetralogy of Fallot—4%.
 - Other—1%.
-
- **What are other common clinical findings seen in children with this condition?**
- Atlanto-axial instability (C1–C2).
 - Endocrine—thyroid disorders, diabetes.
 - GI abnormalities—duodenal atresia/stenosis, celiac disease.
 - Growth—short stature.
 - Hearing loss.
 - Hematologic disorders (especially leukemias).
 - Mental retardation, behavior disorders.
 - Ophthalmologic—refractive errors, strabismus, nystagmus.
-

- **What is the prognosis and life expectancy for patients with this condition?**

Life expectancy in Down syndrome is shorter than that in the general population. Patients with Down syndrome are more likely to die from congenital heart defects, dementia, hypothyroidism, or leukemia than the general population. Adults with Down syndrome usually develop neuropathic and functional changes typical of Alzheimer's disease by their fifth decade.

-
- **What are features of the other two common trisomies?**

- Trisomy 18 (Edwards' syndrome): Severe mental retardation, rocker-bottom feet, low-set ears, micrognathia, clenched hands, horseshoe kidneys.
 - Trisomy 13 (Patau's syndrome): Severe mental retardation, microphthalmia, microcephaly, cleft lip/palate, polydactyly.
-

► **CASE 10**

A 10-hour-old boy is admitted to the neonatal intensive care unit because of abdominal distention. The infant was born full term weighing 3 kg (6.6 lb) to a G1P1 mother by spontaneous vaginal delivery. There was no fetal distress. The pregnancy was complicated by polyhydramnios. Physical examination after birth revealed upper abdominal fullness. The infant was doing well without any respiratory distress. An x-ray of the abdomen is shown in Figure 13-2.

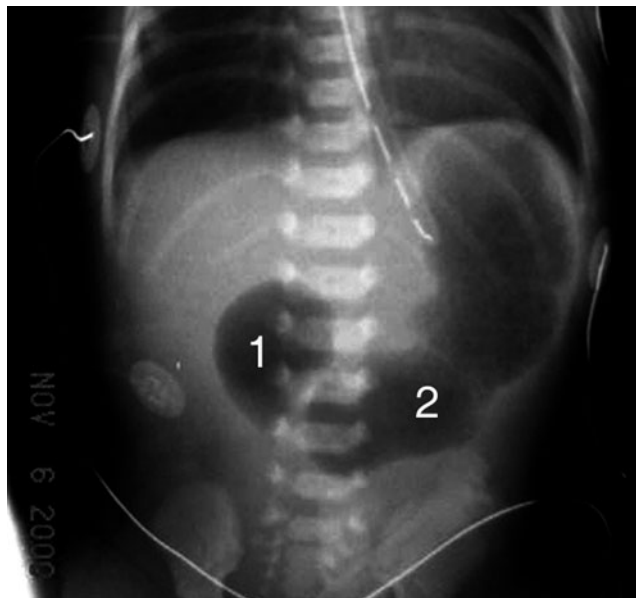


FIGURE 13-2. (Reproduced, with permission, from Brunicaardi FC, Andersen DK, Billiar TR, Dunn DL, Hunter JG, Matthews JB, Pollock RE, Schwartz SI. *Schwartz's Principles of Surgery*, 8th ed. New York: McGraw-Hill, 2005: Fig. 38-13.)

-
- | | |
|--|---|
| <ul style="list-style-type: none">■ What is the differential diagnosis of a newborn presenting with abdominal distention and vomiting? | <ul style="list-style-type: none">■ Duodenal atresia■ Hirschsprung's disease■ Malrotation with volvulus■ Meconium ileus |
| <ul style="list-style-type: none">■ What is the most likely diagnosis? | <p>Duodenal atresia. The history of polyhydramnios, a distended abdomen, and the “double bubble” sign on abdominal x-ray is most suggestive of intestinal obstruction caused by duodenal atresia. It is thought to be caused by complete or partial failure of the duodenal lumen to recanalize during gestational weeks 8–10. In Figure 13-2, the numbers 1 and 2 refer to the double bubbles.</p> |
| <ul style="list-style-type: none">■ What is the typical presentation of patients with this condition? | <p>Infants with duodenal atresia typically have gastric distention and vomiting that may be bilious. Bilious vomiting may begin hours after first feeding.</p> |
-

■ **How is the diagnosis of this condition made prenatally?**

Although most infants with bowel obstruction present in the early postnatal period, intestinal atresias often are detected by prenatal ultrasound examination. Proximal atresias are more likely than distal lesions to be detected prenatally. Distal lesions usually are detected after birth. Ultrasound findings that suggest intestinal atresia include polyhydramnios, a dilated loop of bowel, hyperechoic bowel, and ascites. On prenatal ultrasound, duodenal atresia usually has the characteristic “double bubble” appearance that is seen on a postnatal abdominal radiograph.

■ **What other abnormalities can be associated with this condition?**

Duodenal atresia is an isolated finding in one-third to one-half of cases. However, it is often associated with other malformations, including gastrointestinal (biliary atresia, agenesis of the gallbladder), cardiac, renal, and vertebral anomalies. Approximately 24–28% of newborns with duodenal atresia or stenosis have Down syndrome.

■ **What is the appropriate treatment for this condition?**

Treatment consists of initial preoperative management followed by surgical correction. Initially, patients should have feedings withheld and a nasogastric or orogastric tube placed to suction. Abnormalities in fluid and electrolyte balance should be corrected. Broad-spectrum antibiotics may be used to prevent postoperative infection.

► **CASE 11**

A 1-month-old Caucasian girl is sent to the emergency room by her pediatrician for failure to thrive. She was born at full term, weighing 2.72 kg (6 lb), via spontaneous vaginal delivery with no complications. She was discharged to home with her mother and has been feeding well; she takes 3–4 ounces of formula every 2–3 hours. Her parents deny any emesis, fevers, or diarrhea, although her mother notes frequent foul-smelling loose stools. Family history is unremarkable. She lives with her parents and four siblings. She is afebrile with normal vital signs. Her weight is 3.3 kg (7.3 lb) (< 5th percentile), length is 50 cm (19.7 in) (< 5th percentile), and head circumference is 37 cm (14.6 in) (at 10th percentile). She is cachectic but interactive. The remainder of her examination is unremarkable.

■ What is the definition of failure to thrive (FTT)?	The term FTT may be attributed to a child who meets any of the following criteria: <ul style="list-style-type: none">■ Has weight < 5th percentile for age and sex.■ Has depressed weight for height.■ Has a rate of weight gain that causes a decrease across two or more major percentile lines over time.■ Has a rate of daily weight gain less than expected for age.
■ What are the two types of FTT?	Organic and nonorganic. Organic causes of FTT include: <ul style="list-style-type: none">■ Abnormal loss of calories.■ Increased metabolic requirements.■ Failure to ingest an appropriate number of calories.■ Failure to metabolize. Most cases of FTT are due to nonorganic causes, typically psychosocial factors.
■ What organic causes of FTT should be considered in a patient < 6 months old?	<ul style="list-style-type: none">■ Cystic fibrosis.■ Gastroesophageal reflux.■ HIV infection.■ Inborn errors of metabolism.■ Milk-protein intolerance.■ Perinatal or postnatal infections.■ Renal tubular acidosis.
■ While in the hospital the patient feeds well, but despite adequate caloric intake, she fails to gain weight. What tests should be included in the initial workup of this patient's case of FTT?	Malabsorption must be considered when a patient fails to gain weight despite feeding well. Initial screening studies for malabsorption include: <ul style="list-style-type: none">■ Serum electrolytes, albumin, and total protein.■ Stool exam for <i>Clostridium difficile</i>, ova and parasites, and stool cultures for bacterial pathogens.■ Stool exam for occult blood, leukocytes, reducing substances, and pH.■ Sweat chloride test.■ Urinalysis and culture.
■ What is the most likely diagnosis?	In a Caucasian patient with a history of FTT, malabsorption, and foul-smelling stools, cystic fibrosis must be considered. In addition to the sweat chloride test, many states now screen for cystic fibrosis at birth.
■ What is the most appropriate treatment for malabsorption?	The mainstay of treatment for pancreatic insufficiency in cystic fibrosis is pancreatic enzyme replacement. In addition, patients should receive supplementation of fat-soluble vitamins (vitamins A, D, E, and K).

► **CASE 12**

A 2-year-old previously healthy girl is brought to the emergency department (ED) after a seizure. She had been watching television when she developed full-body stiffening, followed by convulsions and twitching of all four extremities. According to her parents, the seizure lasted approximately 5 minutes and was followed by a brief postictal period of drowsiness. She had had a runny nose for 1 day, which her mother attributed to sick contacts at day care. On examination, she has a temperature of 39.9° C (103.8° F), heart rate of 140/min, respiratory rate of 22/min, blood pressure of 95/75 mm Hg, and pulse oximetry of 99% on room air. She is well appearing and in no acute distress. She has moist mucous membranes with rhinorrhea. Lung examination is significant for decreased breath sounds at the base of the right lung. The remainder of her physical examination is unremarkable.

<p>■ What is the most likely diagnosis?</p>	<p>Simple febrile seizure in the context of pneumonia. Febrile seizures occur in 2–5% of children aged 6 months to 5 years. Simple febrile seizures are the most common type of febrile seizure and are characterized by seizures that last < 15 minutes and have no focal features, and if they occur in a series, the total duration is < 30 minutes.</p>
<p>■ What should be included in the workup of a seizure in a child with a fever?</p>	<p>During the acute evaluation, a physician’s most important responsibility is to determine the cause of the fever and to rule out meningitis. Laboratory tests may include:</p> <ul style="list-style-type: none"> ■ Lumbar puncture (especially if < 1 year old). ■ Electrolytes and glucose. ■ Complete blood count. ■ Toxicology screen.
<p>■ What is the recommended treatment and prognosis for this patient?</p>	<p>A patient with a simple febrile seizure does not need anticonvulsant therapy. Treatment should be directed at the underlying cause of the fever. Children with a previous simple febrile seizure are at increased risk of recurrent febrile seizures; this occurs in approximately one-third of cases. Children who have simple febrile seizures are also at slightly increased risk for epilepsy. The prevalence of epilepsy by age 25 years is approximately 2.4%, which is about twice the risk in the general population.</p>
<p>■ Five hours later the same patient presents to the ED after having a generalized tonic-clonic seizure for 25 minutes. Her temperature is 40.1° C (104.1° F). What is the most likely diagnosis?</p>	<p>Complex febrile seizure. These are characterized by a seizure lasting over 15 minutes, recurring within 24 hours of a previous febrile seizure, or showing signs of focality.</p>
<p>■ What should now be included in the workup of this patient?</p>	<ul style="list-style-type: none"> ■ Electroencephalography (EEG). ■ MRI or CT of the head may be warranted.
<p>■ What are some treatment options for recurrent febrile seizures?</p>	<ul style="list-style-type: none"> ■ Phenobarbital—daily administration may be considered in patients with recurrent or complex febrile seizures and for patients at high risk of developing epilepsy (e.g., those with cerebral palsy, a structural brain lesion, febrile status epilepticus, or a very abnormal EEG). ■ Rectal diazepam—administered for seizures lasting longer than 5–10 minutes.

► **CASE 13**

A 5-year-old girl is brought to her pediatrician with a rash on her legs, abdominal pain, and arthralgias. Two weeks ago, the patient had an upper respiratory infection. Three days prior to this visit, the patient complained of abdominal pain and was taken to a local emergency department. Abdominal radiograph and obstruction series were normal and the patient was sent home. The morning of admission, her mother noticed “red bumps” on both of the patient’s legs. The patient had no history of fever, diarrhea, or bloody stools. Her temperature is 37.5° C (99.5° F), heart rate is 115/min, respiratory rate is 22/min, and blood pressure is 95/70 mm Hg. Physical examination is significant for 2–5-mm erythematous, nonblanching papules on the lower extremities as well as a slightly swollen and tender right knee. The remainder of the examination is unremarkable. Relevant laboratory findings are as follows:

WBC count: 11,000/mm³
Hemoglobin: 9.4 g/dL
Platelet count: 465,000/mm³
Prothrombin time (PT): 12 s
Partial thromboplastin time (PTT): 20 s
Erythrocyte sedimentation rate: 20 mm/hr
Electrolytes: normal
Urinalysis: moderate blood

-
- | | |
|---|--|
| <p>■ What conditions should be included in the differential diagnosis?</p> | <ul style="list-style-type: none">■ Henoch-Schönlein purpura (HSP) is the most likely diagnosis given the triad of a purpuric rash on the lower extremities, abdominal pain, and arthralgias.■ Clotting disorders are less likely given the normal PT and PTT.■ Infection including <i>Neisseria meningitidis</i> and sepsis is less likely in a well-appearing afebrile patient.■ Idiopathic thrombocytopenic purpura (ITP), leukemia, and hemolytic uremic syndrome (HUS) should be considered in a patient with abdominal pain and purpura; however, her acute symptoms and her normal CBC make these less likely.■ Juvenile rheumatoid arthritis (JRA) should be considered with a presentation of rash and a swollen joint; however, the purpuric rash and the timing of the symptoms are not consistent with JRA.■ Systemic autoimmune diseases should be considered, including hypersensitivity vasculitis and systemic lupus erythematosus (SLE). |
| <p>■ What is the pathogenesis of this condition?</p> | <p>HSP is a systemic small-vessel vasculitis characterized by the tissue deposition of immunoglobulin A (IgA)-containing immune complexes. The pathogenesis is similar to that of IgA nephropathy, which is associated with identical histological findings in the kidney. The exact cause is unknown, but many cases follow an upper respiratory infection, suggesting that the precipitating antigen may be infectious.</p> |
| <p>■ What are the clinical manifestations of this condition?</p> | <p>Diffuse inflammation of the small vessels causes abdominal pain, arthritis, and palpable purpura. Renal involvement occurs in 50% of patients, manifested by hematuria, proteinuria, and cellular casts on urinalysis. The hallmark of this disorder on physical examination is a symmetric pattern of purpura, primarily involving the buttocks and lower extremities as well as sites of pressure (e.g., areas of sock or pants elastic).</p> |
-

- **How is this condition diagnosed?** The diagnosis of HSP is made clinically. The characteristic tetrad of (1) rash, (2) arthralgias, (3) abdominal pain, and (4) renal disease is virtually pathognomonic of HSP in children. Microscopically, tissue deposition of IgA may be seen in the skin or kidney.

- **What is the most appropriate treatment for this condition?** HSP is a self-limited disorder and usually resolves in 1–6 weeks. Complete recovery occurs in approximately 94% of patients. Treatment is primarily supportive; however, corticosteroids may be used in more severe disease.

► **CASE 14**

A 4-month-old girl with a history of chronic constipation and failure to thrive is brought to the emergency department with a 2-day history of fever to 39.1° C (102.3° F), bilious vomiting, and decreased oral intake. Her parents deny any change in her bowel habits from her usual 1–2 stools per week. Her only medication is docusate sodium for chronic constipation since 2 months of age. On examination, she has a temperature of 38.6° C (101.4° F), heart rate of 144/min, and blood pressure of 95/63 mm Hg. Her height, weight, and head circumference are all below the 5th percentile. Physical examination is significant for a thin and tired-appearing infant. Her abdomen is soft and distended with distant bowel sounds. There is palpable stool in the lower left quadrant. Rectal examination is significant for a small ampulla that is empty of stool. A radiograph of the abdomen is performed and shows dilated loops of bowel with an absence of rectal air.

■ **What is the differential diagnosis of chronic constipation in children?**

The major causes of constipation can be broadly categorized as either functional or organic. Functional constipation is defined as persistent, difficult, infrequent, or incomplete defecation without evidence of a structural or biochemical cause. Causes of organic constipation make up < 5% of cases and include:

- Anatomic malformations (e.g., anal stenosis, imperforate anus).
- Certain drugs such as antacids (containing aluminum or calcium), opiates, and phenobarbital.
- Metabolic and GI causes such as hypothyroidism, hypercalcemia, cystic fibrosis, diabetes mellitus; neuropathic conditions (e.g., spinal cord abnormalities, tethered cord, neurofibromatosis, static encephalopathy).
- Nerve and muscle disorders (e.g., Hirschsprung disease, prune-belly syndrome, Down syndrome).
- Other disorders such as cow's milk protein intolerance and infant botulism.

■ **What is the most likely diagnosis?**

The patient's history of chronic constipation and failure to thrive, her empty rectal ampulla, and the radiographic findings are suggestive of Hirschsprung disease.

■ **What is the pathophysiology of this condition?**

Hirschsprung disease is believed to result from failure of the ganglion cell precursors to migrate along the gastrointestinal tract in a craniocaudal direction during weeks 5–12 of gestation. Incomplete parasympathetic innervation in the aganglionic segment results in abnormal peristalsis, constipation, and a functional intestinal obstruction. It occurs in 1 in 5000 live births and often presents with delayed passage of meconium. The disease is four times more common in boys than in girls, and 10–15% of patients have Down syndrome.

■ **What are the next steps in diagnosis?**

- Rectal biopsy is considered the gold standard. The absence of ganglion cells in the submucosa (Meissner's plexus) and myenteric level (Auerbach's plexus) is diagnostic.
- Unprepped barium enema—diagnostic findings include a cone-shaped transition zone or caliber change.
- Anorectal manometry (balloon distention of the rectum)—demonstrating a lack of relaxation of the internal anal sphincter is suggestive of Hirschsprung disease.

■ **What are some of the major complications of this condition?**

- **Obstruction:** Patients often present with bilious emesis, abdominal distention, and failure to pass stool.
- **Enterocolitis:** Hirschsprung-associated enterocolitis (HAEC) is the most severe and potentially lethal complication. Patients usually present with explosive, foul-smelling diarrhea, fever, vomiting, and abdominal pain and distention. It results from ulceration and erosion of the mucosa proximal to the involved segment. The affected area is then invaded by colonic organisms and can lead to intestinal perforation, peritonitis, sepsis, shock, and death.
- **Volvulus:** A rare complication of Hirschsprung disease.

■ **What is the most appropriate treatment for this condition?**

Surgery is the mainstay of treatment. The goal is to resect the affected segment and anastomose the normal bowel to the anus, preserving sphincter function. It is usually performed in two stages: patients initially undergo a diverting colostomy (to allow the normal dilated bowel to decompress) followed by definitive repair 3–12 months later depending on the age of the patient and severity of disease.

► **CASE 15**

An 8-month-old boy with no significant past medical history presents to his pediatrician with irritability and one episode of stool mixed with blood and mucus. His mother notes that he began crying inconsolably for about 30 minutes after waking up early from his morning nap and then began acting like himself again. An hour later, he began crying again and was noted to be pulling his knees toward his abdomen. He continued to have episodes of irritability and crying that lasted approximately 20 minutes and occurred at 30–45-minute intervals. On examination, he is afebrile, and vital signs are within normal limits. He has normal rectal tone with Hemoccult-positive stool. Laboratory results are all unremarkable.

■ **What are the most common causes of lower gastrointestinal bleeding in infants?**

- Gastrointestinal duplication.
 - Hemolytic uremic syndrome (HUS).
 - Henoch-Schönlein purpura (HSP).
 - Intussusception.
 - Lymphonodular hyperplasia.
 - Meckel's diverticulum.
 - Milk- or soy-induced enterocolitis (allergic colitis).
-

■ **What is the most likely diagnosis?**

The history of episodic colicky abdominal pain, with knees drawn up to the chest, that wakened the child from sleep is classic for intussusception. The stool with blood and mucus (currant-jelly stool) is also suggestive of intussusception, the most common cause of bowel obstruction in the first 2 years of life. In this condition, a portion of the bowel (often containing a lead point) telescopes into the adjacent bowel.

■ **What are some of the clinical manifestations that are associated with this condition?**

Patients typically develop sudden onset of intermittent, severe, crampy, progressive abdominal pain, accompanied by inconsolable crying and drawing of the legs up to the chest. The intussusception may intermittently resolve, resulting in intervals when the child is pain free. Vomiting and the passage of “currant-jelly” stool may occur. A sausage-shaped mass may be felt in the right side of the abdomen. The classic triad of pain, a sausage-shaped mass, and currant-jelly stool is seen in < 15% of patients.

■ **What are some pathologic conditions associated with this condition?**

- Cystic fibrosis—thick, inspissated stool may act as lead point.
 - Duplication cysts, polyps, vascular malformations.
 - Henoch-Schönlein purpura—bowel wall hematoma acts as lead point.
 - Meckel's diverticulum.
 - Parasites (e.g., *Ascaris lumbricoides*), adenovirus.
 - Preceding gastroenteritis.
 - Small bowel lymphoma (especially > 6 years of age).
-

■ **What tests and/or imaging tools could be used to confirm the diagnosis?**

- Abdominal radiograph—may show intestinal obstruction, massively distended loops of bowel, or decreased air in the right lower quadrant. A soft tissue density (the intussusception) projecting into the gas of the large bowel is called the “crescent sign.”
- Abdominal ultrasound—highly sensitive and specific; classic image is the “bull’s-eye” or “coiled spring” lesion representing layers of the intestine within the intestine.
- Barium enema—confirms the presence of a telescoping intraluminal intestinal mass.

■ **What is the most appropriate treatment for this condition?**

- Barium enema has been the standard diagnostic and therapeutic tool for intussusception. Air enema can be used for treatment. This technique has a success rate of 80–90% and less potential for peritoneal cavity contamination should perforation occur.
 - Recurrence after successful nonoperative reduction is ~10%.
 - Surgery is necessary if enema reduction is unsuccessful.
-

► **CASE 16**

A previously healthy 5-year-old boy presents to the emergency department with a 6-day history of fever and rash. Four days prior to admission the patient developed a small papular rash all over his body, bilateral conjunctival injection without exudate, and a temperature of 38.7° C (101.7° F). He was seen by his pediatrician on day 3 of fever and was diagnosed with a viral syndrome. The rash disappeared by day 4, but his fever persisted. On examination, he has a temperature of 39.0° C (102.2° F), heart rate of 130/min, respiratory rate of 24/min, and blood pressure of 99/62 mm Hg. He is irritable and difficult to console. His sclerae are injected bilaterally, and his oropharynx is mildly erythematous. His lips are dry and cracked. A 1.5 × 2-cm lymph node is palpable on the left anterior cervical chain. His chest is clear to auscultation. He does not have a rash. Relevant laboratory findings are as follows:

WBC count: 16,500/mm³
Hemoglobin: 9.8 g/dL
Platelet count: 420,000/mm³
C-reactive protein: 23.15 mg/mL
Erythrocyte sedimentation rate: 75 mm/hr
Urinalysis: small ketones, no WBCs, no blood

■ What conditions should be included in the differential diagnosis?	<ul style="list-style-type: none">■ Adenovirus, other viral exanthems.■ Cat-scratch disease.■ Cytomegalovirus, Epstein-Barr virus.■ Hepatitis.■ Infection with group A β-hemolytic <i>Streptococcus</i> or <i>Staphylococcus</i>.■ Kawasaki disease.
■ The fever continues, and on day 7 the patient develops edema of the hands and feet with desquamation. What is the most likely diagnosis?	The constellation of fever ≥ 5 days, rash, cervical adenopathy, cracked lips, injected sclerae, and edema of the hands and feet are most consistent with Kawasaki disease, a vasculitis of small and large arteries.
■ How is this condition diagnosed?	Kawasaki disease is a clinical diagnosis, which requires the presence of fever lasting at least 5 days, combined with at least four of the five following physical findings: <ul style="list-style-type: none">■ Bilateral conjunctival injection.■ Cervical lymphadenopathy (at least one lymph node > 1.5 cm).■ Oral mucous membrane changes.■ Peripheral extremity changes, including erythema of palms or soles or edema of hands or feet.■ Polymorphous rash.
■ What is the natural history of this condition?	Kawasaki disease is typically self-limited, with fever and manifestations of acute inflammation lasting for an average of 12 days without therapy. However, the disease may be complicated by the development of aneurysms in coronary arteries, which can lead to myocardial ischemia or infarction. In untreated patients, the incidence of coronary artery aneurysms is about 20–25% with a mortality rate of approximately 2%.
■ What is the most appropriate treatment for this condition?	Initial treatment is with intravenous immune globulin (IVIG), at a dose of 2 g/kg infused over 12 hours. Long-term aspirin therapy is also prescribed for its antithrombotic effects.
■ What adverse events can rarely be associated with initial treatment?	<ul style="list-style-type: none">■ Anaphylactic hypersensitivity reactions.■ Aseptic meningitis.■ Acute renal dysfunction.

► **CASE 17**

A 7-month-old boy presents to the emergency department with a history of lethargy. He was seen by his pediatrician 3 days ago with fever and symptoms of an ear infection. He was diagnosed with otitis media and treated with oral amoxicillin. The morning of admission, he became irritable and was less active than usual. He has vomited three times, and his urine output is noticeably decreased. He has no diarrhea. He has a temperature of 40.2° C (104.0° F), heart rate of 100/min, respiratory rate of 20/min, and blood pressure of 110/80 mm Hg. He is lethargic and arousable only to painful stimuli. Physical examination shows his anterior fontanelle is full and tense. His tympanic membranes are red and bulging. His pupils are reactive, but his eyes do not focus well on his parents. His heart, lungs, and abdomen are normal. His color and perfusion are good. He has no petechiae. He moves all his extremities weakly, and his deep tendon reflexes are hyperactive.

-
- **What is the most likely diagnosis?** Meningitis. Signs of meningitis include fever, vomiting, headache, lethargy, irritability, and stiff neck. On exam, there may be lethargy, irritability or coma, fever, bulging fontanelle (in infants), and nuchal rigidity (in children > 1 year old). Kernig’s sign (back pain when the leg is extended > 135 degrees with the hip flexed to 90 degrees) and Brudzinski’s sign (flexion of the patient’s hips and knees when the neck is flexed) are rarely present in children < 2 years old.

 - **What is the most appropriate next step in management?** The workup should begin with a lumbar puncture (LP) to collect cerebrospinal fluid for WBC count with differential, glucose, protein, RBC count, Gram stain, and culture. A CT scan should be obtained prior to LP if signs of increased intracranial pressure or focal neurological signs are present. Other tests include a CBC, electrolytes, and blood cultures.

 - **Cerebrospinal fluid (CSF) shows 5000 WBC with 75% neutrophils, glucose of 30 mg/dL, and protein of 300 mg/dL. What pathogens are most likely causing this condition?** In children, 90% of bacterial meningitis cases are caused by *Streptococcus pneumoniae*, *Neisseria meningitidis*, *Escherichia coli*, group B streptococci, and *Haemophilus influenzae* type B. In patients > 6 months old, the three most common bacterial pathogens are *S. pneumoniae*, *N. meningitidis*, and *H. influenzae* type B.

 - **What is the most appropriate treatment for this condition?** Treatment should begin immediately with empiric intravenous antibiotics. In children without known immune problems, high doses of third-generation cephalosporins, such as cefotaxime or ceftriaxone, plus vancomycin should be started. Additionally, dexamethasone is often given shortly before or at the time of initial administration of antibiotics in an attempt to diminish the incidence of hearing loss and other neurologic complications in children with *H. influenzae* or pneumococcal meningitis. However, steroid use is controversial.

 - **The Gram stain of the CSF reveals gram-positive diplococci. What is the most likely diagnosis?**

 - Gram-positive diplococci suggest pneumococcal infection.
 - Gram-negative diplococci suggest meningococcal infection.
 - Small pleomorphic gram-negative coccobacilli suggest *Haemophilus influenzae*.
 - Gram-positive cocci or coccobacilli suggest group B *Streptococcus*.
 - Gram-positive rods and coccobacilli suggest listerial infection.
-

► **CASE 18**

A 6-day-old girl born at 35 weeks' gestation is being evaluated because of a 24-hour history of abdominal distention, decreased feeding, and vomiting. She was delivered by induced vaginal delivery to a 26-year-old G2P2 mother with preeclampsia. She was stabilized in the neonatal intensive care unit and had been doing well with no signs of respiratory distress. Over the past day, she has gradually become more irritable and has been vomiting her formula. The last stool she passed was guaiac positive. The nurse also describes one episode where she appeared to stop breathing. On examination, she appears lethargic and is lying still. Her temperature is 37.8° C (100.1° F), heart rate is 145/min, blood pressure is 91/60 mm Hg, and respiratory rate is 20/min. Birth weight was 1139 g (2 lb 8 oz), and her current weight is 1077 g (2 lb 6 oz). Her abdomen is distended and tender to palpation with decreased bowel sounds. Pulmonary and cardiac exams are within normal limits. X-ray of the abdomen reveals distended loops of bowel with pneumatosis intestinalis.

■ What is the most likely diagnosis?	Necrotizing enterocolitis (NEC). NEC is a condition caused by bowel ischemia with subsequent bacterial invasion of the intestinal wall. It is most commonly seen in premature infants but has also been described in full-term neonates. There are an estimated 2200 cases annually in the United States, resulting in over 900 deaths.
■ What signs and symptoms are common in patients with this condition?	Many symptoms of NEC overlap significantly with those of neonatal sepsis, including temperature instability, lethargy, and apnea. GI symptoms such as vomiting, bloody stool, and abdominal distention should raise suspicion.
■ What radiographic findings are common in this condition?	X-ray of the abdomen may show pneumatosis intestinalis (air in the bowel wall), air in the portal vein, or free air under the diaphragm (signifying perforation), which are very suggestive of NEC.
■ What is the most appropriate treatment for this condition?	Bowel rest is the first step in managing these patients. Enteral feeds are discontinued, and the bowel is decompressed with a nasogastric or orogastric tube. IV fluids and antibiotics are given. Serial abdominal x-rays are performed to evaluate for bowel perforation, which necessitates operative repair.
■ What is the prognosis for patients with this condition?	Despite aggressive treatment, mortality of NEC remains between 20% and 40%. Serious complications include bowel perforation, sepsis, and shock. Long-term sequelae can include intestinal strictures and short gut syndrome. However, infants with uncomplicated NEC that is medically managed have outcomes comparable with other infants at their birth weight.

► **CASE 19**

A newborn infant boy is transferred to the neonatal intensive care unit because of a defect in his abdominal wall. He was born by repeat low-transverse cesarean section at term to a 34-year-old G4P4 mother who did not receive any prenatal care. She denies any problems with this pregnancy. On examination, there is a 6-cm sac protruding from the midline of the abdomen; bowel and liver can be seen within the sac. The infant is hemodynamically stable and not in acute distress.

■ What is the most likely diagnosis?	An abdominal wall defect, specifically omphalocele. Omphalocele is the herniation of abdominal contents (bowel with or without liver and spleen) through the umbilical root into a membranous sac of peritoneum; it is differentiated from an umbilical hernia by length > 4 cm.
■ What is the most appropriate management for this condition?	The abdominal cavity is typically underdeveloped in omphalocele, so surgical repair is deferred. Contents are placed in a plastic covering termed a <i>silo</i> and gradually reduced into the abdomen until skin closure is possible.
■ Would management change if the bowel were herniated to the right of the umbilicus and not covered by peritoneum?	Yes. Gastroschisis is an abdominal wall defect in which bowel alone is eviscerated, usually to the right of the umbilicus; there is no peritoneal covering. This condition requires immediate surgical repair due to the risks of dehydration and infection of exposed bowel. The abdominal cavity is typically better developed in gastroschisis; however, postoperative respiratory distress due to the increase in intra-abdominal pressure remains a concern.
■ How are abdominal wall defects diagnosed prenatally?	Both omphalocele and gastroschisis result in elevated levels of maternal serum α -fetoprotein (MSAFP), measured during the triple screen. Defects can also be visualized by prenatal ultrasound.
■ What other conditions are associated with abdominal wall defects?	Omphalocele is frequently associated with chromosomal anomalies (most commonly trisomy 18), heart defects, and congenital diaphragmatic hernia. In contrast, gastroschisis is typically an isolated abnormality; intestinal atresia and cryptorchidism are seen in some cases.

► **CASE 20**

A 12-month-old girl is brought to the pediatrician for fever and fussiness. Her mother reports that her daughter has had a mild cough and nasal congestion for 1 week but has been acting normally. Two days ago, she developed a fever of 38.9° C (102.1° F) orally and became increasingly fussy. Her mother also notes that she has been tugging on her left ear. On physical examination, she is irritable and febrile to 38.8° C (101.8° F). Her left tympanic membrane (TM) is bulging and immobile. The remainder of her exam is unremarkable.

■ What is the most likely diagnosis?	Acute otitis media (AOM). This infection is typically associated with fluid in the middle ear, known as an effusion. Signs seen on physical examination include a bulging TM, TM with limited or no mobility, the presence of an air-fluid level, or visible pus behind the TM. Additionally, symptoms of middle ear inflammation must be present, such as erythema of the TM, otalgia, or fever.
■ What risk factors are associated with an increased incidence of this condition?	AOM is more common in children than in adults; the eustachian tube in children is more horizontal and less likely to drain middle ear fluid, particularly during upper respiratory infections. Other risk factors include parental smoking, day care attendance, and nighttime bottle feeding. Breast-feeding and pacifier use have been found to be protective.
■ What pathogens are most commonly implicated in this condition?	<ul style="list-style-type: none">■ <i>Streptococcus pneumoniae</i>■ <i>Haemophilus influenzae</i> (nontypeable)■ <i>Moraxella catarrhalis</i>
■ What is the treatment for this condition?	First-line therapy for AOM is high-dose amoxicillin; cefuroxime, cefdinir, and cefpodoxime are alternatives in the case of amoxicillin allergy. Resistant or recurrent AOM is treated with high-dose amoxicillin-clavulanate or the above alternatives. Intramuscular ceftriaxone is another option.
■ What are the indications for tympanostomy tubes?	Tympanostomy tubes ventilate the middle ear and allow drainage of the effusion. They are placed by an ear, nose, and throat surgeon. Typical indications include prolonged effusion (3–4 months) with or without infection or multiple ear infections (4 in 6 months, or 6 in 1 year). Tubes typically remain in place up to 12 months. Tubes allow for spontaneous drainage of fluid in subsequent infections.
■ What are the potential complications if this condition is left untreated?	Untreated AOM can result in direct damage to middle ear structures, with such findings as tympanosclerosis, cholesteatoma, or TM perforation. Rarely, infection can extend into adjacent structures and cause mastoiditis or meningitis. Facial nerve paralysis can also be seen due to inflammation in the middle ear.

► **CASE 21**

A 3-day-old boy is brought to the pediatrician by his mother, who is worried that her son is turning progressively yellow. He was born by spontaneous vaginal delivery at 36 weeks' gestation to a 25-year-old G1P1; she had good prenatal care, and there were no complications with the pregnancy. He was discharged from the newborn nursery at 30 hours. He is breast-feeding and stooling well. On examination, he is a well-appearing infant with marked jaundice over his face and torso. Serum studies reveal total bilirubin of 13 mg/dL with conjugated bilirubin < 0.3 mg/dL.

<p>■ What is the most likely diagnosis?</p>	<p>Physiologic jaundice, likely breast-feeding jaundice. Prenatally, bilirubin is cleared through the placenta; postnatally, there is increased production of bilirubin coupled with lower rates of hepatic uptake and conjugation that lead to an almost universal hyperbilirubinemia in the first week of life. Acceptable levels of bilirubin vary based on the infant's gestational age and postnatal age. Breast-feeding has been associated with physiologic jaundice. Physiologic jaundice is generally seen after the first 24 hours of life, peaks at 3 days, and resolves over 2 weeks.</p>
<p>■ What are the two types of jaundice associated with breast-feeding?</p>	<ul style="list-style-type: none"> ■ Breast-feeding jaundice occurs in the first 2–4 days and resolves rapidly. ■ Breast milk jaundice occurs in 4–7 days and is longer lasting.
<p>■ What is the differential diagnosis of nonphysiologic jaundice?</p>	<ul style="list-style-type: none"> ■ Increased bilirubin production: <ul style="list-style-type: none"> ■ Hemolysis (isoimmunization vs. genetic condition). ■ Sepsis. ■ Hematoma/hemorrhage (e.g., cephalohematoma). ■ Increased enterohepatic circulation: Bowel obstruction or ileus. ■ Decreased clearance: <ul style="list-style-type: none"> ■ Prematurity. ■ Glucose-6-phosphate dehydrogenase (G6PD) deficiency. ■ Inborn errors of metabolism: <ul style="list-style-type: none"> ■ Crigler-Najjar syndrome. ■ Gilbert syndrome. ■ Galactosemia. ■ Metabolic: Hypothyroidism.
<p>■ What is the feared outcome of untreated neonatal jaundice?</p>	<p>Kernicterus (neurotoxicity resulting from deposition of bilirubin in the basal ganglia). Affected infants have altered tone, a high-pitched cry, and lethargy. Long-term sequelae include mental retardation, sensorineural hearing loss, choreoathetoid cerebral palsy, and abnormalities of upward gaze.</p>
<p>■ What is the most appropriate treatment for neonatal jaundice?</p>	<p>Infants with excessively high bilirubin levels for their age are treated to prevent kernicterus. Moderate elevations (usually 12–20 mg/dL) are often treated with phototherapy, in which the infant is placed under a blue-green light that converts bilirubin in the skin to isomers that can be excreted without conjugation. Severe elevations (above 20–25 mg/dL) often require exchange transfusion.</p>

► **CASE 22**

A 6-week-old boy is referred to the emergency department by his pediatrician for dehydration and vomiting. The infant had been feeding well until 3 weeks prior to admission when he began having nonbloody and nonbilious vomiting after most feeds. In the week prior to admission, the vomiting had increased in frequency and force, becoming projectile and occurring after every feed. Review of systems is significant for increased sleepiness in the past 2 days, decreased urine output, and less frequent bowel movements. His mother denies any diarrhea, hematochezia, or fever. On examination, the child has normal vital signs, with height at the 50th percentile and weight at the 30th percentile. Physical examination is significant for a sunken anterior fontanelle. Relevant laboratory findings are as follows:

WBC count: 9000/mm ³	Cl ⁻ : 75 mEq/L
Hemoglobin: 15.4 g/dL	HCO ₃ ⁻ : 47 mEq/L
Platelet count: 255,000/mm ³	Blood urea nitrogen (BUN): 51 mg/dL
Na ⁺ : 130 mEq/L	Creatinine: 0.9 mg/dL
K ⁺ : 3.9 mEq/L	

-
- | | |
|--|--|
| ■ What conditions should be included in the differential diagnosis? | <ul style="list-style-type: none">■ Enterocolitis.■ Esophagitis.■ Gastric outlet obstruction: pyloric stenosis.■ Serious bacterial infection (e.g., meningitis, urinary tract infection).■ Severe gastroesophageal reflux.■ Small bowel obstruction: duodenal atresia, malrotation, volvulus. |
| ■ What is the physiology of this patient's electrolyte abnormalities? | This patient has a hypochloremic metabolic alkalosis (low chloride levels, high bicarbonate level) resulting from the loss of large amounts of gastric hydrochloric acid. Hypokalemia is not typically seen early but can also occur in infants who have prolonged vomiting (> 3 weeks) as a result of a shift of hydrogen ions into the extracellular space and potassium to the intracellular space. His elevated BUN is most likely due to dehydration. |
| ■ What would be the most likely diagnosis if an "olive-like" mass was palpated in the right upper quadrant of the abdomen? | Pyloric stenosis. The "olive-like" mass (felt best after emesis or emptying of the stomach with a nasogastric tube) is produced by hypertrophy and hyperplasia of the antral and pyloric musculature. |
| ■ What tests and/or imaging tools could be used to confirm the diagnosis of the condition in the question above? | Diagnosis is straightforward when the "olive" is palpated; otherwise, it can be difficult to differentiate pyloric stenosis from gastroesophageal reflux, especially in the early stages. Imaging modalities include: <ul style="list-style-type: none">■ Abdominal ultrasound: typically reveals thickening of pyloric muscle wall.■ Radiograph of the abdomen: may show a markedly distended stomach with a paucity of bowel gas beyond the stomach.■ Upper endoscopy: typically reserved for patients in whom other imaging modalities are inconclusive.■ Upper GI barium study: classic signs are an elongated pyloric canal, the "double-track" sign (two thin tracks along the pyloric canal), and the "shoulder" sign created by the prepyloric bulge of barium. |
| ■ What drug has been associated with this condition? | An association exists between pyloric stenosis and oral erythromycin given to infants in the first 2 weeks of life. |
| ■ What is the most appropriate treatment for this condition? | An incision is made along the mucosa for the length of the pylorus (pyloromyotomy). |
-

► **CASE 23**

A 2-hour-old neonate boy in the newborn nursery is found to have respiratory distress. He was born at 37 weeks' gestation to a 25-year-old G1P1 mother who had an uncomplicated pregnancy and normal prenatal laboratory values. His Apgar scores were 9 and 9 at 1 and 5 minutes, respectively. On examination, he is afebrile with heart rate of 170/min, respiratory rate of 80/min, blood pressure of 65/40 mm Hg, and oxygen saturation of 95% on 2 L/min oxygen via mask. His length, weight, and head circumference are at the 50th percentile. He is in obvious respiratory distress. His head is normocephalic and his anterior fontanelle is open and flat. He has some nasal flaring. Lung and cardiac auscultation are normal, although mild to moderate retractions are present. His skin is pink without petechiae, ecchymoses, or lesions. The remainder of his examination is unremarkable. An x-ray of the chest reveals streaky, perihilar densities and small, scattered, patchy densities bilaterally.

-
- **What is the differential diagnosis for respiratory distress in the newborn?**

- Meconium aspiration.
 - Pneumonia (typically group B *Streptococcus*).
 - Pulmonary air leak: pneumomediastinum, pneumothorax, or pneumopericardium.
 - Respiratory distress syndrome.
 - Transient tachypnea of the newborn (TTN).
 - **What is the most likely diagnosis?**

Since this patient is a term male with no known complications during pregnancy, labor, or delivery, the most likely diagnosis is TTN. TTN is a self-limited parenchymal lung disorder characterized by pulmonary edema resulting from delayed resorption and clearance of fetal lung fluid. TTN is a common cause of respiratory distress in the immediate newborn period. Potential causes include short labor and cesarean section, because mechanisms to reabsorb lung fluid are not initiated.
 - **What common findings are associated with this condition?**

- Breath sounds in affected infants typically are clear, without rales or rhonchi.
 - Characteristic findings on chest radiograph include fluid in the fissures and central/perihilar congestion.
 - Cyanosis and increased work of breathing, manifested by nasal flaring, mild intercostal and subcostal retractions, and expiratory grunting.
 - Tachypnea (respiratory rate > 60/min) is the most prominent feature.
 - **What is the prognosis for patients with this condition?**

Infants with mild to moderate TTN are symptomatic for 12–24 hours, but signs may persist as long as 72 hours in severe cases. Infants rarely require a supplemental oxygen concentration > 40% to achieve adequate oxygenation. TTN is generally self-limiting and has no long-term sequelae.
 - **If this patient had been born a month earlier, what would be the most likely diagnosis?**

Respiratory distress syndrome (RDS) is the most common disorder of the premature infant. Most infants are < 34 weeks' gestation, and disease incidence and severity increase with decreasing gestation age. These premature infants have progressively more severe respiratory distress after birth. The major etiology of RDS is surfactant deficiency. Without surfactant, the surface tension of the alveolar sacs is high, leading to an increased tendency of the alveoli to collapse. Risk factors include maternal diabetes, male sex, and the second born of twins.
 - **If this patient had been born a month earlier, what would an x-ray of the chest most likely show?**

The classic findings of RDS on chest x-ray include decreased lung inflation with diffuse symmetric reticulogranular lung fields (**ground-glass** appearance) and air bronchograms.

► **CASE 24**

A 9-month-old boy presents to the emergency department in January with a 1-day history of fever and wheezing. Three days prior, he had developed nasal congestion and a mild cough. He was born prematurely at 36 weeks but is otherwise healthy. On examination, he has a temperature of 39.2° C (102.5° F), heart rate of 130/min, respiratory rate of 28/min, and oxygen saturation of 95% on room air. He is a well-nourished, acyanotic infant in moderate respiratory distress. He has clear rhinorrhea, no conjunctival injection, and moderate intercostal and subcostal retractions. Lung examination is significant for diffuse expiratory wheezing. No murmurs or gallops are heard on cardiac examination. The remainder of his examination is normal. An x-ray of the chest is notable for hyperinflation and peribronchial thickening.

- | | |
|--|--|
| ■ What is the differential diagnosis of new-onset wheezing in infants? | <ul style="list-style-type: none">■ Bronchiolitis.■ Chronic lung disease.■ Congenital heart disease, heart failure.■ Foreign body aspiration.■ Gastroesophageal reflux disease with aspiration.■ Pneumonia.■ Reactive airway disease.■ Vascular rings (a condition in which an anomalous aortic arch and/or associated vessels surround the trachea and esophagus, completely encircling and often compressing them). |
| ■ What is the most likely diagnosis? | Bronchiolitis. Bronchiolitis typically affects children < 2 years, principally in the winter months. The majority of cases of bronchiolitis are caused by respiratory syncytial virus (RSV). Other pathogens include parainfluenza, influenza, adenovirus, and human metapneumovirus. |
| ■ In pediatric patients with this diagnosis, what risk factors predispose for more severe disease? | <ul style="list-style-type: none">■ Age < 6 months.■ Chronic lung disease.■ Congenital heart disease.■ Immunodeficiency.■ Prematurity. |
| ■ What is the epidemiology of this condition? | RSV causes seasonal outbreaks throughout the world. In the northern hemisphere, these usually occur from November to April, with peaks in January or February. RSV pneumonia has been blamed for an average of 2700 adult and pediatric deaths each year. RSV is the most common cause of lower respiratory tract infection in children < 1 year old. |
| ■ What is the most appropriate treatment for this condition? | Treatment for RSV bronchiolitis consists of supportive measures, including oxygen supplementation and nasal suctioning. Nasogastric feedings or intravenous fluids are useful in maintaining hydration in the presence of tachypnea and decreased oral intake. |
| ■ If this patient had hemodynamically significant congenital heart disease, what would be the recommended prophylaxis for this condition? | The American Academy of Pediatrics recommends that immunoprophylaxis be considered for certain groups of children who are at risk for severe RSV infection. Palivizumab is a humanized monoclonal antibody against the RSV F glycoprotein. It is licensed for use in children < 2 years of age with chronic lung disease, premature birth (< 35 weeks), or hemodynamically significant congenital heart disease. |
-

► **CASE 25**

An 8-month-old girl is brought to the hospital because of motor deterioration and convulsions. She was born at 38 weeks' gestation without complications. Her past medical history was unremarkable, and she had been meeting her developmental milestones normally until 2 weeks prior to admission, when her parents noted that she had lost the ability to sit unassisted. On the morning of admission she had a tonic-clonic seizure lasting 2 minutes. Physical examination is significant for generalized hypotonia and macrocephaly. She is also noted to have a dramatic startle reflex. Ophthalmic examination reveals a retinal cherry-red spot. She has no evidence of organomegaly.

■ What is the most likely diagnosis?	The child's motor deterioration and loss of milestones suggest a metabolic disorder. The exaggerated startle reflex and the retinal cherry-red spot are most consistent with Tay-Sachs disease.
■ What is the pathogenesis of this condition?	Tay-Sachs disease results from a mutation in β -hexosaminidase A. The absence of the hexosaminidase enzyme causes lysosomal accumulation of GM ₂ gangliosides, particularly in the central nervous system. This ongoing accumulation causes progressive cellular damage. In children, the destructive process begins in the fetus early in pregnancy, although the disease is not clinically apparent until the child is several months old. The retinal cherry-red spot is the result of accumulation of GM ₂ in the ganglion cells in the retina. (Mnemonic: Tay-saX lacks heXosaminidase.)
■ What is the epidemiology and mode of inheritance of this condition?	Tay-Sachs disease is an autosomal recessive trait. The incidence of the disease is significantly higher among people of eastern European (Ashkenazi) Jewish descent, with a carrier rate of about 1 in 30. The carrier rate is about 1 in 300 for the general population.
■ If this patient also had doll-like facies, hepatosplenomegaly, and cardiomegaly, what would be the likely diagnosis?	Sandhoff disease, a more rare and severe form of Tay-Sachs, results from mutations in the β -subunit gene. This leads to deficiency of both β -hexosaminidases A and B (as opposed to Tay-Sachs, in which only β -hexosaminidase A is absent).
■ What is the prognosis for patients with this condition?	Patients with the infantile form of Tay-Sachs disease have clinical manifestations in infancy of loss of motor skills, increased startle reaction, and macular pallor with retinal cherry-red spots. Affected infants usually develop normally until 4–5 months of age, when decreased eye contact and an exaggerated startle response to noise (hyperacusis) are noted. Macrocephaly, not associated with hydrocephalus, may develop. In the second year of life, seizures requiring anticonvulsant therapy develop. Neurodegeneration is relentless, with death occurring by the age of 4 or 5 years.

► **CASE 26**

A 5-month-old boy is brought to the emergency department for cyanosis. The child was born full term and was noted to be mildly cyanotic at birth. The cyanosis resolved after 20 minutes, and he was discharged home after 3 days. His parents note that he occasionally has episodes of irritability, crying, hyperventilation, and breathlessness that are usually self-limiting and are followed in most cases by a period of sleep. His mother also notes that he has occasional difficulty breathing while breast-feeding. On the morning of admission, his parents noticed that his lips and fingertips turned blue while he was crying. On physical examination, the patient is sleeping comfortably with no signs of respiratory distress. His heart rate is 130/min, respiratory rate is 24/min, blood pressure is 95/65 mm Hg, and oxygen saturation is 92% on room air. Subtle cyanosis of his mucous membranes is present. Cardiac examination reveals a normal S1 and a single S2. A 4/6 systolic ejection murmur is heard loudest at the left upper sternal border. His lungs are clear to auscultation bilaterally. The remainder of the physical examination is unremarkable.

-
- **What is the most likely diagnosis?** Congenital heart disease must be considered in a patient presenting with cyanosis and a heart murmur. The history of episodes of dyspnea, irritability, and cyanosis during exertion (crying) are suggestive of tetralogy of Fallot (TOF) and most likely represent “tet spells,” which are caused by reduction of an already compromised pulmonary blood flow and occur spontaneously or following periods of exertion. (Think of the **5 Terrible T’s** for cyanotic congenital heart disease: **T**etralogy of Fallot, **T**runcus arteriosus, **T**ricuspid atresia, **T**otal anomalous pulmonary return, and **T**ransposition of the great vessels.)
-
- **What are the anatomic features of this condition?**
- A ventricular septal defect—due to septal malalignment.
 - An overriding aorta that receives blood from both ventricles.
 - Right ventricular hypertrophy—due to the high-pressure load placed on the right ventricle by the pulmonic stenosis.
 - Subvalvular pulmonic stenosis—due to obstruction from the infundibulum.
-
- **Which of the anatomic anomalies present in this condition most determines the severity of the cyanosis?** Right ventricular outflow tract obstruction, caused by pulmonic stenosis, determines the clinical presentation of the patient. Children with severe obstruction and inadequate pulmonary blood flow typically present in the immediate newborn period with profound cyanosis, while children with minimal obstruction may be asymptomatic and present later in life with pulmonary congestion and heart failure.
-
- **What are some of the typical imaging and laboratory findings?**
- X-ray of the chest: The classic presentation is a “boot-shaped” heart resulting from a large right ventricle and a decrease in the size of the main pulmonary artery. Pulmonary vascular markings are usually diminished.
 - Echocardiography: Details all essential features of the defects.
 - Electrocardiogram: Right atrial enlargement and right ventricular hypertrophy.
-

■ **What other cardiac abnormalities are associated with this condition?**

Approximately 40% of patients with TOF have associated cardiac anomalies, including:

- Right aortic arch (40%).
 - Atrial septal defect (10%).
 - Abnormalities of the coronary arteries (9%).
-

■ **What are some noncardiac anomalies associated with this condition?**

- Alagille syndrome.
 - DiGeorge and velocardiofacial syndromes due to a deletion on chromosome 22q11.
 - Trisomy 21.
-

► CASE 27

A 2-year-old girl is brought to her pediatrician for evaluation of a new rash. Her mother notes that she had a fever to 38.3° C (101.0° F) yesterday and complained of headache and abdominal pain. She awakened this morning with a pruritic rash on her face. She has no past medical history, but neither she nor her sister, who is also sick, is up to date on their vaccinations; her last immunizations were received at 9 months of age. On examination, she is playful and interactive. Her temperature is 36.9° C (98.5° F), heart rate is 85/min, blood pressure is 95/75 mm Hg, and respiratory rate is 14/min. There are small vesicles across her face, and the skin surrounding each vesicle appears erythematous. Linear excoriations are present. A few papules are visible on her neck and shoulders.

■ What is the most likely diagnosis?	Varicella, or chickenpox. Infection with varicella-zoster virus (VZV) results in a highly contagious, self-limited disease with a characteristic pruritic rash. Papular lesions evolve into small vesicles on an erythematous base, the “dewdrops on a rose petal.” The vesicles crust over within days, as new lesions appear; the disease typically resolves within 5 days. Chickenpox is predominantly seen in children < 10 years old; viral reactivation in adults manifests as herpes zoster.
■ How can this condition be differentiated from other viral exanthems?	See Table 13-1.
■ How can this condition be prevented?	Two doses of the live attenuated VZV vaccine are typically administered between 12 and 18 months of age.
■ What is the most appropriate treatment for this condition?	For immunocompetent children, treatment focuses on relief of pruritus with oral antihistamines, topical calamine lotion, and cool compresses. Immunocompromised individuals and older patients at risk of more severe disease are often treated with acyclovir.
■ When is varicella-zoster immune globulin (VZIG) used?	VZIG is used for prophylaxis in exposed individuals at high risk for severe disease. This includes immunocompromised patients and newborns whose mothers have active varicella at or soon after delivery.

TABLE 13-1. Features of the Common Pediatric Viral Exanthems

DISEASE	PATHOGEN	RASH	OTHER SYMPTOMS	COMPLICATIONS	VACCINE
Varicella	Varicella-zoster virus (VZV)	Pruritic; vesicles on erythematous base; begins on the face and spreads to trunk	May have short prodrome of fever, malaise	Secondary bacterial infection, pneumonia, encephalitis, Reye's syndrome	Live attenuated VZV vaccine
Rubeola	Paramyxovirus	Maculopapular; begins on cheeks and spreads to chest and upper arms	High fever, runny nose, dry cough, Koplik spots	Otitis media, pneumonia, encephalitis	Live-attenuated measles, mumps, and rubella (MMR) vaccine
Fifth disease	Parvovirus B19	"Slapped cheek" rash spreads to trunk and extremities	Prodrome of low-grade fever, upper respiratory infection (URI) symptoms	Arthropathy, transient aplastic crisis in patients with chronic hemolysis	None
Roseola	Human herpesvirus 6 and 7	Small raised lesions; start on trunk and spread to face, proximal extremities	High fever that breaks with rash onset, mild URI symptoms	None	None
Rubella	Rubella virus	Nonpruritic; begins on face, then spreads to trunk	Mild fever prodrome, mild conjunctivitis	Rare progressive panencephalitis	Live attenuated MMR vaccine

► **CASE 28**

A 4-month-old boy is brought to his pediatrician because of an increased difficulty in breathing and poor weight gain. His mother notes that he often perspires and appears dusky during feeds. His past medical history is significant for a suspected pneumonia at 2 months of age that resolved with antibiotic therapy. He was born full term without complications. His physical examination is remarkable for a 4/6 blowing holosystolic murmur in the left lower sternal border as well as a diastolic rumble heard at the apex.

-
- **What is the most likely diagnosis?** The child's history of dyspnea, feeding difficulties, and duski-ness without frank cyanosis, combined with the blowing holosystolic murmur, is suggestive of a large, nonrestrictive ventricular septal defect (VSD).

 - **Assuming the patient has had appropriate medical care, why might this condition not have been diagnosed until 4 months of age?** Normally, pulmonary vascular resistance (PVR) declines over the first several weeks of life. In infants with a large VSD, the decline in PVR may be delayed for several months. Thus, the size of the left-to-right shunt may initially be small. A murmur related to a large VSD is heard as soon as a significant difference is reached in the level of resistance between the pulmonary and systemic vascular circuits. Because the natural decrease in PVR may not reach a point that would allow for a substantial amount of blood to flow across the defect for the first few months of life, a murmur related to a large VSD may not be heard until the 2- to 4-month postnatal visit.

 - **What is the physiology of the heart murmur?** The murmur of a large VSD is holosystolic, reflecting the persistent pressure difference between the right and left ventricles throughout systole. It is heard best at the left lower sternal border. A low-pitched diastolic rumble at the apex is caused by a relative mitral stenosis secondary to the increased blood volume returning to the left atrium. In small (restrictive) VSDs, the murmur can be significantly louder due to turbulent blood flow across the small lesion.

 - **What are the typical radiographic and electrocardiographic findings in this condition?** In large VSDs, the chest x-ray shows gross cardiomegaly with prominence of both ventricles, the left atrium, and the pulmonary artery. Pulmonary vascular markings are increased, and frank pulmonary edema, including pleural effusions, may be present. The electrocardiogram shows biventricular hypertrophy; P waves may be notched or peaked.

 - **If this condition were not diagnosed, what other symptoms would this patient likely develop over time?** Infants with small VSDs usually remain asymptomatic. In contrast, infants with moderate to large VSDs can begin to manifest signs of pulmonary congestion and heart failure by 3–4 weeks of age. Symptoms include: tachypnea, poor feeding (tires easily, sweats), poor weight gain, tachycardia, respiratory infections, hepatomegaly, pulmonary rales, grunting, and retractions. If a large VSD is undiagnosed or untreated for years, patients can develop Eisenmenger syndrome, an irreversible condition caused by right-to-left shunting due to high PVR.

 - **What is the most appropriate treatment for this condition?** A large VSD does not undergo spontaneous closure; therefore, surgery is required. A VSD with a pulmonary-to-systemic flow ratio > 2:1 (as calculated by cardiac catheterization) is considered physiologically large and requires surgical closure. Pulmonary vascular disease can be prevented when surgery is performed in the first year of life.
-

► **CASE 29**

A 3-year-old boy is brought to his pediatrician because his mother noticed a “tennis-ball” sized mass in the lower-right side of his abdomen while giving him a bath. He is otherwise healthy, and his past medical history is unremarkable. On examination, he has a temperature of 36.5° C (97.7° F), heart rate of 120/min, respiratory rate of 18/min, and blood pressure of 98/65 mm Hg. He has a nontender 4 × 4-cm smooth, firm mass in the right lower quadrant and mild abdominal distention. The remainder of his examination is normal.

<p>■ What is the differential diagnosis of an abdominal mass in a pediatric patient?</p>	<p>Prior to the advent of prenatal ultrasound, hydronephrosis was the most common abdominal mass in the newborn period. Wilms’ tumor and neuroblastoma are the most common intra-abdominal tumors; others include leukemia, lymphoma, hepatic tumors, ovarian tumors, and soft-tissue sarcomas. The age of the child helps in the differential diagnosis. Wilms’ tumor and neuroblastoma occur more commonly in infants, whereas leukemic or lymphomatous involvement of the liver, spleen, or retroperitoneal lymph nodes occurs more commonly in older children.</p>
<p>■ An abdominal ultrasound shows a right intrarenal mass. What is the most likely diagnosis?</p>	<p>Wilms’ tumor (“nephroblastoma”), the most common intra-abdominal malignancy in children.</p>
<p>■ What is the pathogenesis of this mass?</p>	<p>Wilms’ tumor is a complex mixed embryonal neoplasm of the kidney composed of three elements: blastema, epithelia, and stroma.</p>
<p>■ What are some congenital abnormalities associated with this condition?</p>	<ul style="list-style-type: none"> ■ Beckwith-Wiedemann syndrome — characterized by hemihypertrophy, macroglossia, and visceromegaly. ■ Denys-Drash syndrome — comprised of male pseudohermaphroditism, early-onset renal failure, and increased risk of Wilms’ tumor. ■ Neurofibromatosis. ■ Von Willebrand disease. ■ WAGR syndrome — comprised of Wilms’ tumor, aniridia, genitourinary abnormalities, and mental retardation; caused by a constitutional deletion of chromosome 11p13.
<p>■ What is the most appropriate treatment for this condition?</p>	<p>Wilms’ tumor is treated with surgical resection and chemotherapy. Specific treatment and prognosis depend on the staging of the tumor.</p>
<p>■ If this patient had presented with an abdominal mass and had elevated vanillylmandelic acid (VMA) in his urine, what would be the most likely diagnosis?</p>	<p>Neuroblastoma, a malignancy arising from neural crest cells. It is the second most common malignancy of childhood. In approximately two-thirds of patients, the primary site is in the abdomen (usually adrenal); the thoracic region is the second most common site. Neuroblastoma tumor cells are characterized by defective catecholamine synthesis, which results in the accumulation and excretion of the intermediates homovanillic acid (HVA), VMA, and dopamine. Secretion of these catecholamines may give rise to symptoms such as hypertension. HVA and VMA can be measured in the urine and are useful in diagnosis and in monitoring disease activity.</p>

Psychiatry

Case 1	402
Case 2	404
Case 3	405
Case 4	406
Case 5	407
Case 6	408
Case 7	410
Case 8	412
Case 9	413
Case 10	414
Case 11	415
Case 12	416
Case 13	417
Case 14	418
Case 15	420
Case 16	422
Case 17	423
Case 18	424
Case 19	425
Case 20	426
Case 21	428
Case 22	429
Case 23	430
Case 24	432

► **CASE 1**

A 19-year-old student is being evaluated at his student health center. The physician notes the young man is tachycardic at 101/min with a blood pressure of 145/93 mm Hg. His pupils are dilated, and there is a fine tremor in his hands. The patient appears agitated and is sweating. The student says he is just anxious about upcoming final examinations, but when questioned further he becomes angry and belligerent. He finally admits that for the past 2 weeks he has been taking pills his roommate gave him in order to help him stay awake. He says they improve his concentration and allow him to get by on only a few hours of sleep. He has not been eating as much and says his clothes are fitting more loosely on him. He does not see a problem with this, saying many people in the dormitory do the same thing and that he will stop taking the pills after his exams are done. The rest of the physical examination is unremarkable. On mental status examination, he is alert and oriented to person, place, and time. He is mildly uncooperative, and his speech is rapid. He describes his mood as “terrific,” but his affect is angry. He denies suicidal or homicidal ideation, perceptual disturbances, or delusions. He does not have a prior history of mental illness.

-
- **What is the most likely diagnosis?** Amphetamine intoxication. He admits to recent use of pills acquired from his roommate to help him study. Although it is not known exactly what kind of pills he has been taking, the illicit use of dextroamphetamines is a significant problem on college campuses. According to the *Diagnostic and Statistical Manual of Mental Disorders*, 4th ed., Text Revision (DSM-IV-TR), this patient is most likely experiencing amphetamine intoxication: He has not been sleeping or eating regularly, and there is evidence of recent weight loss; his pulse and blood pressure are elevated, his pupils are dilated, and a tremor is present. He is also exhibiting behavioral and psychological changes, such as euphoria, anxiety, tension, and anger. Abuse of stimulants may also result in symptoms of psychosis such as paranoid delusions.
-
- **What are the DSM-IV-TR criteria for substance abuse?** The criteria for substance abuse can be remembered with the mnemonic **HARP**:
- H**azardous use (e.g., driving while intoxicated).
 - A**rrests (legal problems).
 - R**ole failure (repeated work absences due to substance use).
 - P**ersistent use despite consequences.
- Only one of these four criteria need be met during a 12-month period. Substance dependency is diagnosed by meeting three of seven criteria within a 12-month period. The criteria for substance dependency can be remembered with the mnemonic **WITHDrawIT**:
- W**ithdrawal.
 - I**nterest or important activities given up or reduced.
 - T**olerance.
 - H**arm (physical and psychosocial) with continued use.
 - D**esire to cut down or control use.
 - I**ntended time/amount of use exceeded.
 - T**ime spent obtaining/using the substance is increased.
- This patient does not meet the criteria for substance dependency.
-

■ **What might happen if the patient suddenly stopped taking this drug?**

Amphetamine withdrawal is characterized by fatigue, depression, nightmares, headache, profuse sweating, muscle cramps, and hunger. Withdrawal symptoms such as intense dysphoria usually peak in 2–4 days and resolve within 1 week.

■ **Is treatment necessary for patients with this condition?**

Since amphetamine intoxication and withdrawal are generally self-limiting, no specific treatment is necessary. Benzodiazepines (e.g., diazepam, lorazepam) can be used to treat agitation or anxiety but have their own abuse potential. Therapeutic drugs to treat the withdrawal are not routinely used in clinical practice.

► **CASE 2**

A 64-year-old man is brought to the emergency department by ambulance after losing consciousness at a local bar. On arrival he is awake but intoxicated, and physical examination reveals a haggard-looking man with contusions on his left elbow and knee. His blood alcohol level is 307 mg/dL, and a urine toxicology screen excludes the presence of other substances. He tells the physician that he has been in and out of alcohol treatment facilities several times and once had a seizure when he tried to stop drinking. He is admitted to the hospital for observation. The next morning, a mental status examination reveals he is alert and oriented to person, place, and time. His speech is of normal rate and tone, and he is cooperative with the physician. He tells the examiner that the previous night he consumed 8–10 beers and several shots. His mood is depressed; his affect is congruent and dysphoric. Otherwise, no abnormalities are noted.

■ **What is alcohol withdrawal syndrome?**

This syndrome includes a continuum of signs and symptoms, ranging from tremulousness to delirium tremens (DTs).

- Mild alcohol withdrawal usually occurs < 24 hours after cessation of or decrease in alcohol intake. It may include tremulousness, anxiety, nausea, vomiting, diaphoresis, hyperreflexia, and minor autonomic hyperactivity.
- Moderate alcohol withdrawal is an intermediate position along the continuum. Hallucinoses can occur, which consists of hallucinations with an otherwise clear sensorium.
- Severe alcohol withdrawal occurs > 24 hours and up to 5 days after cessation of or decrease in alcohol intake. It is characterized by disorientation, agitation, hallucinations (usually visual), and severe autonomic derangement. Pupils tend to be dilated and slow to react. Seizures and DTs are considered major phenomena, although seizures can occur with any level of withdrawal.

■ **What pharmacologic therapy is expected to have been initiated in the emergency department?**

The mainstays of therapy are the long-acting benzodiazepines, such as diazepam or chlordiazepoxide, which control seizures with minimal respiratory or cardiac depression. Short-acting benzodiazepines, including lorazepam and oxazepam are recommended for patients with reduced liver function. The patient should also receive IV fluids and IV thiamine, folate, and magnesium sulfate to address probable nutritional deficiencies. Administration of thiamine also prevents Wernicke-Korsakoff syndrome when given before glucose (which can precipitate Wernicke's encephalopathy).

■ **What is the pathophysiology of Wernicke-Korsakoff syndrome?**

Wernicke's encephalopathy is an acute, usually reversible encephalopathy characterized by the triad of delirium, ophthalmoplegia, and ataxia; it results from acute thiamine depletion. Korsakoff's syndrome is due to chronic thiamine depletion, as from long-term alcohol use, and is usually irreversible. It is marked by an inability to learn new information, known as anterograde amnesia.

► CASE 3

An 18-year-old woman is being evaluated by her physician at the urging of her parents. Her mother says she is concerned about her daughter's dramatic weight loss over the past year. The patient states that her mother is worrying over nothing, and that she agreed to the doctor's appointment just to get her off her back. She reports that she feels just fine, has been sleeping well, although her mood is "a little depressed." She admits she has not had her period in several months. She says she eats when she is hungry but admits that she's not hungry very often. She also says she is unhappy with her current weight and would be happier if she just lost a few more pounds. She is an accomplished ballet dancer and often spends hours in the evening dancing at the studio. She describes her relationship with her mother as "very tense"; she feels like her mother is too controlling. On physical examination, the patient is 173 cm (5'8") tall; she weighs 46.7 kg (103 lb) and appears cachectic. Relevant laboratory findings reveal a WBC count of $4.5/\text{mm}^3$, hemoglobin of 9.8 g/dL, and a platelet count of $140/\text{mm}^3$.

-
- | | |
|--|--|
| <ul style="list-style-type: none"> ■ What is the most likely diagnosis? | <p>Anorexia nervosa is diagnosed when a person:</p> <ul style="list-style-type: none"> ■ Induces weight loss leading to a body weight of < 85% of a healthy norm or refuses to gain appropriate weight when growing taller. ■ Has an intense fear of gaining weight or becoming fat even though underweight. ■ Has a disturbance in the perception of his or her body shape. ■ Has missed three consecutive menstrual cycles (in women). <p>This patient's body mass index is 15.7 kg/m^2 (normal is $18.5\text{--}24.9 \text{ kg/m}^2$); a healthy weight for a female of her height and age is 60–68 kg (approximately 131–151 lb).</p> |
| <ul style="list-style-type: none"> ■ What steps are appropriate in the approach to this patient? | <p>This patient should be hospitalized, although it is unlikely she will agree. Treatment should be aimed at restoring her nutritional status, as she is severely malnourished. Dehydration and electrolyte imbalances must be corrected. The patient should be weighed daily, and her daily fluid intake and output should be monitored.</p> |
| <ul style="list-style-type: none"> ■ Who should be included on her treatment team? | <p>The most accepted treatment for eating disorders, including anorexia nervosa, bulimia nervosa, and binge eating disorder, involves an interdisciplinary team approach. This team should include a medical provider, dietitian (with experience in treating eating disorders), and a mental health professional.</p> |
| <ul style="list-style-type: none"> ■ What should be the focus of psychotherapy? | <p>Psychotherapy is the mainstay of treatment for eating disorders, as is family involvement in therapy. Cognitive behavioral and supportive approaches help the patient work on underlying issues that may have initiated the eating disorder. A therapist with experience and expertise in the treatment of eating disorders is essential. Much of the psychological work will focus on the affective issues that surround the eating disorder rather than the eating behaviors. Issues of control and autonomy are often central.</p> |
| <ul style="list-style-type: none"> ■ What is refeeding syndrome? | <p>When previously malnourished patients are fed with high carbohydrate loads, a rapid fall in serum phosphate, magnesium, and potassium ensues along with an increase in extracellular fluid volume. There is a subsequent increase in cardiac workload, with increased stroke volume, heart rate, and oxygen consumption. This sudden increase in demand for nutrients and oxygen may outstrip supply. Moreover, in patients with cardiovascular disease, the sudden increase in cardiac work and circulating fluid can precipitate acute heart failure.</p> |
-

► **CASE 4**

An 8-year-old boy is referred to his pediatrician at the recommendation of his teacher because of difficulties he has been having in school for the past year. According to the teacher, he is not completing assignments and often makes careless mistakes. He is easily distracted and must constantly be told to sit still and remain in his seat; he frequently is found staring out the window or talking to other students at their desks. She also says that he is very disruptive and blurts out answers to questions before she has completed them. He cannot seem to wait his turn in the cafeteria line and insists on playing games that others have not invited him to play. His parents describe him as a happy boy who enjoys playing with his brother and neighborhood friends. They have seen some of the same behaviors at home that are giving him trouble at school. They describe him as “constantly on the go” and describe the evenings as “a battle” to get him to finish his schoolwork or to clean his room, which is always a mess. He complains that he does not like school except for recess and physical education. Evaluation by the school counselor showed no evidence of a learning disorder.

-
- | | |
|---|--|
| <p>■ What is the most likely diagnosis?</p> | <p>Attention-deficit/hyperactivity disorder (ADHD), hyperactive and impulsive type. He shows many of the traits of this disorder, including fidgeting that makes it difficult for him to sit still in class, leaving his seat inappropriately, talking excessively, and being constantly “on the go.”</p> |
| <p>■ What are the different classifications of this condition?</p> | <ul style="list-style-type: none">■ Hyperactive and impulsive type: see above.■ Inattentive type: This type affects girls more frequently than boys. The chief symptoms include: difficulty following instructions, paying attention, organizing tasks, and forgetfulness. These children tend to be less disruptive, and thus are often more difficult to diagnose than their hyperactive-impulsive counterparts.■ Combined type: Displays at least six inattentive symptoms and at least six hyperactive symptoms. <p>Also note that the symptoms of ADHD must be present for at least 6 months and observable in two or more settings. Some of the symptoms must be present before age 7.</p> |
| <p>■ What is the epidemiology of the disorder?</p> | <p>It is common in school-aged children, with estimates of its prevalence ranging from 3–10% of youths. It is three times more common in boys than in girls.</p> |
| <p>■ Is this strictly a childhood condition?</p> | <p>Although it was originally classified as a childhood disorder, increasing numbers of adults have also been diagnosed with ADHD. There is concern about overdiagnosis, however, because of the risks of substance abuse (see below) and a propensity for secondary gain (this diagnosis is regarded as a disability under the Americans with Disabilities Act). An adult cannot be diagnosed with ADHD without evidence of the disorder in childhood.</p> |
| <p>■ What imaging abnormalities have been noted in patients with this condition?</p> | <p>Quantitative magnetic resonance imaging (MRI) studies have shown that the prefrontal cortex, basal ganglia, and cerebellum are either smaller or asymmetric in ADHD. These findings correlate well with neuropsychological data, which indicate that those with ADHD have trouble with the following two functions: response inhibition (executive functions mediated by the prefrontal cortex) and timing functions (mediated by the cerebellum).</p> |
| <p>■ What is the most appropriate treatment for this condition?</p> | <p>The recommended treatment is a psychostimulant. Methylphenidate is usually the first line of treatment, followed by D-amphetamine. If these are not successful, amoxetine (a norepinephrine reuptake inhibitor), tricyclic antidepressants (e.g., imipramine), or bupropion may be used.</p> |
-

► CASE 5

The parents of a 28-month-old boy present to their pediatrician expressing concern about his development. Until age 2, their son had met all his developmental milestones; he was able to follow simple directions, respond to his name, and speak 8–10 words. However, over the past 4 months, their son has progressively become more withdrawn. He rarely makes eye contact and does not respond to his parents' laughter or affectionate gestures. He does not play with other children his age and frequently rocks back and forth. Of most concern to his parents, he rarely speaks and often does not respond to his name. He does not compensate for his lack of speech through other communication, such as miming or gesturing.

- | | |
|--|--|
| <ul style="list-style-type: none"> ■ What is the most likely diagnosis? | <p>Autistic disorder, regressive type. Children with the regressive form of autism show relatively normal development from 12 to 24 months of age but subsequently lose the skills they have previously obtained. According to the <i>Diagnostic and Statistical Manual of Mental Disorders</i>, 4th ed., Text Revision (DSM-IV-TR), a patient must exhibit impairments in all of the following:</p> <ul style="list-style-type: none"> ■ Qualitative impairment in social interaction. ■ Qualitative impairment in communication. ■ Restricted, repetitive, and stereotyped patterns of behavior. <p>This patient most likely meets the criteria for autism; he is showing marked impairment in the use of nonverbal behavior (i.e., eye-to-eye gaze), does not attempt to develop peer relationships, and lacks social/emotional reciprocity. He also has stopped speaking, with no accompanying compensation mechanism, and engages in repetitive motor movements. Autism affects boys about four times more frequently than girls and occurs in approximately 6 per 10,000 people. Genetic factors seem to be contributory; autism is seen more frequently in identical twins than fraternal twins.</p> |
| <ul style="list-style-type: none"> ■ What conditions should be included in the differential diagnosis? | <p>Autism is a pervasive developmental disorder (PDD), and other conditions in this class must be ruled out to confirm the diagnosis.</p> <ul style="list-style-type: none"> ■ Rett's disorder occurs almost exclusively in girls; children afflicted develop relatively normally until 6–18 months of age, then subsequently exhibit many of the symptoms common to autism. Many children with Rett's also experience a deceleration in head growth, resulting in microcephaly in some patients. Gastrointestinal problems, seizures, and scoliosis are all common. ■ Asperger's disorder is a form of "high functioning" autism and usually is not diagnosed until later in life, typically once a child enters school. While these patients show impairment in social interaction and restricted, repetitive motor movements, they do not show a clinically significant delay in language, as autistic children do. ■ A hearing disorder should also be ruled out; however, children with hearing difficulties will normally try to compensate through mimes and gestures. |
| <ul style="list-style-type: none"> ■ What other conditions are associated with this condition? | <p>Approximately half of autistic children are mentally retarded, and seizures occur in about one-third. Medical conditions or syndromes associated with autism include phenylketonuria, fragile X syndrome, Angelman syndrome, and fetal alcohol syndrome, but these disorders are usually diagnosed well before 2–3 years of age.</p> |
| <ul style="list-style-type: none"> ■ What is the most appropriate treatment for this condition? | <p>Patients with autism do best in structured educational and social programs. Risperidone may be indicated for children ages 5–16 years to address the irritability and aggression associated with autism.</p> <hr/> |

► **CASE 6**

A 19-year-old woman presents to her primary care physician for a routine examination. She denies any complaints at present. The patient is 160 cm (5'3") tall and weighs 52 kg (115 lb). Physical examination reveals a temperature of 37.0° C (98.6° F), pulse of 82/min, and blood pressure of 118/70 mm Hg. The patient is also noted to have some dental enamel erosion, slightly enlarged parotid glands bilaterally, and scarring over her right second and third metacarpophalangeal joints. Relevant laboratory findings are as follows:

Na⁺: 135 mEq/L
K⁺: 2.8 mEq/L
Cl⁻: 96 mEq/L
HCO₃⁻: 33 mEq/L
Serum amylase: 130 U/L

■ What is the most likely diagnosis?	Bulimia nervosa. This condition is characterized by frequent episodes of binge eating associated with emotional distress and a sense of lack of control over eating. This distress is accompanied by compensatory behaviors aimed at preventing weight gain. Such compensatory behaviors must occur at least two times per week for more than 3 months and often include purging, fasting, misuse of diuretics/laxatives, or intense exercise after eating. Bulimia must be distinguished from an occurrence of anorexia nervosa, purging type. However, bulimic patients often have a normal body weight, in contrast to patients with anorexia nervosa, and conceal their behaviors from family and friends.
■ What is the epidemiology of this condition?	Bulimia nervosa is primarily a disorder of adolescent girls and young women. Prevalence may be as high as 5–10% of college-age women. This condition is much more common in females than in males.
■ How is this condition classified?	<ul style="list-style-type: none">■ Purging type—patients vomit and use diuretics or cathartics.■ Nonpurging type—patients restrict calories or exercise.
■ What other symptoms are common in patients with this condition?	Individuals with bulimia nervosa have an increased frequency of mood and anxiety symptoms. They also have an increased frequency of personality disorders and substance abuse. Symptoms of impulsivity are also common.
■ What are the medical complications associated with this condition?	<ul style="list-style-type: none">■ Chronic sore throat, esophagitis, or Boerhaave's syndrome.■ Dental erosion and caries.■ Gastric dilatation and rupture.■ Menstrual irregularities.■ Parotid gland swelling.■ Pancreatitis.
■ What are the typical laboratory findings in this condition?	Frequent purging can produce electrolyte abnormalities, most commonly hypokalemia, hyponatremia, and hypochloremia. The loss of stomach acid through vomiting may result in a metabolic alkalosis with elevated serum bicarbonate. Laxative abuse may cause a metabolic acidosis. Additionally, serum amylase may be elevated.

■ **What is the most appropriate treatment for this condition?**

Individual psychotherapy is recommended, particularly focusing on behavior modification and body image. The symptoms of bulimia nervosa are responsive to antidepressants, particularly selective serotonin reuptake inhibitors; however, other classes of antidepressants have also been shown to be effective. Notably, bupropion is contraindicated in patients with bulimia nervosa, as it has been associated with an increased incidence of seizures.

► **CASE 7**

A 26-year-old G7P3 woman at 34 weeks' gestation presents to the emergency department because she feels she is beginning to experience contractions and does not have an outpatient obstetrician. On examination, her pupils are dilated and she appears agitated and nervous. She then changes her mind and says she does not want further evaluation because it has been too long since her last "smoke." She is adamant about needing to leave right away. Upon further questioning, she states that if she does not get to smoke soon, she will become very sleepy and depressed and will have intense food cravings. She has been in inpatient drug rehabilitation twice but always relapses back to her drug of choice. She is currently living at a halfway house, is on welfare, and does not have custody of any of her three children. "They will probably take this one away from me, too," she adds as she begins to cry. She says she used to be able to get high for \$10 per day, but now it costs up to \$100 per day. She affords her habit by trading drugs and money for sex; she cannot recall if she has been tested for HIV or other sexually transmitted diseases.

- | | |
|---|---|
| <p>■ What is the most likely diagnosis?</p> | <p>Cocaine dependence. This patient exhibits the classic signs of addiction: she has tolerance for the drug (requires more to achieve the same effect) and experiences withdrawal symptoms without it. She has continued to use cocaine despite negative consequences, and she has been unable to stop despite repeated attempts. Smoking cocaine results in feelings of euphoria and heightened energy, while depression, hunger, and sleepiness are symptoms of withdrawal.</p> |
| <p>■ What behavioral changes are associated with use of this drug?</p> | <p>Behavioral changes may include:</p> <ul style="list-style-type: none">■ Blunting of feelings.■ Decreased appetite.■ Euphoria and increased energy.■ Heightened anxiety, irritability, or anger.■ Hypervigilance and heightened alertness.■ Impaired judgment.■ Increase in sexual excitement and spontaneous ejaculation.■ Increased risk for psychosis.■ Increased self-confidence. |
| <p>■ What physical changes are associated with use of this drug?</p> | <p>Physical changes may include:</p> <ul style="list-style-type: none">■ Chest pain and/or arrhythmias due to vasospasm in coronary arteries.■ Confusion, seizures, stupor, or coma.■ Diaphoresis or chills.■ Dilated pupils.■ Increased pulse and blood pressure due to vasoconstriction.■ Muscle weakness, dystonia, or dyskinesia.■ Nausea or vomiting.■ Psychomotor slowing or agitation.■ Respiratory depression.■ Weight loss. |
-

■ **What are the risks to this patient's unborn child?**

Cocaine readily crosses the placenta and is metabolized slowly by the fetus; thus, the fetus can be exposed to high levels of cocaine for long periods. Because of its vasoconstrictive properties, cocaine use increases the risk of fetal hypoxia and abruptio placentae.

Other risks include premature birth, lower birth weight, respiratory distress, bowel infarctions, cerebral infarctions, reduced head circumference, and increased risk of seizures. Behaviorally, these newborns show an increased degree of tremulousness, crying, and irritability and are overreactive to environmental stimuli; the behaviors decrease in the first month of life but never to normal levels. Cocaine can be found in breast milk up to 60 hours after the last use.

► **CASE 8**

A 13-year-old boy is brought to the pediatrician by his mother, who is concerned about his behavior. Over the past year, he has been suspended from school three times, once for fighting with another student and twice for stealing. His mother has also begun receiving calls from the local truancy officer, reporting her son's repeated absences from school. He was recently arrested by the police for breaking into a neighbor's car. He previously had a normal developmental course.

■ What is the most likely diagnosis?	Conduct disorder. Conduct disorder is a persistent pattern of behavior in children and adolescents, in which the rights of others or age-appropriate social norms are violated. These behavior patterns can be seen in a variety of settings—at home, at school, and in social situations. Conduct disorder is more common in boys, with studies indicating that the rate among boys in the general population ranges from 6% to 16%.
■ What conditions should be included in the differential diagnosis?	Notably, oppositional defiant disorder must be considered. Oppositional defiant disorder is a pattern of negativistic, hostile, and defiant behavior toward figures of authority lasting at least 6 months. The inattention, hyperactivity, and impulsivity of attention-deficit/hyperactivity disorder (ADHD) may be mistaken as oppositional behavior. Finally, the irritability and impulsivity associated with childhood bipolar disorder can also result in disruptive behaviors.
■ What are the signs and symptoms of this condition?	<ul style="list-style-type: none">■ Aggressive behavior that threatens or harms people or animals such as bullying or intimidating others, initiating physical fights, or abusing animals.■ Deceitfulness or theft, such as breaking into someone's house or car, or lying or "conning" others.■ Nonaggressive conduct that causes property loss or damage (i.e., vandalism or fire-setting).■ Serious rule violations like running away from home overnight or school truancy.■ At least three or more of the above must be present within the last 12 months, with at least one criterion present within the last 6 months.
■ What other problems are associated with this condition?	Conduct disorder may also be associated with other difficulties, such as substance use, risk-taking behavior, school problems, and physical injury from accidents or fights. Conduct disorder also tends to occur with a number of other emotional and behavioral disorders of childhood, particularly ADHD, anxiety disorders, and affective disorders.
■ What is the most appropriate treatment for this condition?	The mainstay of treatment for conduct disorder is behavioral therapy, although pharmacotherapy can be used adjunctively to target symptoms such as aggression, agitation, and impulsivity.
■ What is the prognosis for patients with this condition?	Most children and adolescents with conduct disorder do not grow up to have behavioral problems or problems with the law. However, conduct disorder in childhood and adolescence has been associated with antisocial personality disorder in adults.

► CASE 9

An 86-year-old woman is admitted to the intensive care unit after suffering a myocardial infarction. Despite her advanced age, she has no known previous medical history. Her son, who is her primary caregiver, is very concerned about her condition and insists on remaining at her bedside at all times. Shortly after midnight, she becomes agitated and removes her intravenous line. As the nursing staff attempts to replace the line and calm her, she begins screaming, "I have to clean the kitchen!" She does not appear to recognize her son. Physical examination reveals a temperature of 37.0° C (98.6° F), pulse of 101/min, and blood pressure of 132/84 mm Hg. Oxygen saturation is 98%, and blood glucose is 103 mg/dL.

-
- | | |
|--|--|
| <p>■ What is the most likely diagnosis?</p> | <p>Delirium. Delirium is a transient disturbance of consciousness with marked impairment in attention that develops over hours to days and waxes and wanes with time. Hospitalized patients, particularly those recovering from brain injuries, burns, or cardiac procedures, are especially susceptible to episodes of delirium.</p> <p>Delirium is often mistaken for dementia, depression, acute schizophrenia, or a disorder related to the patient's old age, as many of the patients presenting with delirium are elderly.</p> |
| <p>■ What are the signs and symptoms of this condition?</p> | <p>Delirium presents acutely as a disturbance in consciousness marked by impaired attention with cognitive and perceptual abnormalities. Delirium tends to have a waxing and waning course and may be characterized by anxiety, paranoia, or combativeness. Other characteristics include reversed sleep-wake cycles and worsening of symptoms at night.</p> |
| <p>■ What is the etiology of this condition?</p> | <p>Delirium most often results from a variety of general medical conditions or from substances that interfere with brain function. Some of these conditions include:</p> <ul style="list-style-type: none"> ■ Exogenous toxic agents: stimulants, lysergic acid diethylamide (LSD). ■ Primary intracranial disease: vasculitis, stroke, seizure. ■ Systemic disease secondarily affecting the brain: infection, cardiac events, metabolic disturbances, hyponatremia, hypoglycemia, vitamin deficiencies. ■ Withdrawal from substances of abuse. |
| <p>■ What tests could be used to confirm the diagnosis?</p> | <p>If delirium is suspected in a hospitalized patient, a vigorous search for an underlying medical etiology should be undertaken. Vital signs and pulse oximetry should be reviewed. Recent medications and medication changes, substance use patterns, and nutritional status should also be considered. Laboratory and radiological studies should be ordered to rule out infection, toxic-metabolic causes, or intracranial pathology.</p> |
| <p>■ What is the most appropriate treatment for this condition?</p> | <p>In addition to treating the underlying medical etiology, treatment for delirium includes both pharmacologic and supportive approaches. Quiet, well-lighted surroundings, as well as frequent orientation, can minimize patient agitation. Agitated patients may become suicidal or homicidal and should not be left alone. The use of physical restraints or low-dose antipsychotic medications may be indicated. Benzodiazepines should be avoided, as they may worsen delirium-associated confusion. Neuroleptics such as haloperidol or risperidone are also helpful.</p> |
-

► **CASE 10**

A 64-year-old man presents to the emergency department disoriented and confused. Airport security brought him into the hospital after he repeatedly accosted strangers in the airport, asking them his name and expressing confusion as to why he was there. The patient's physical examination is within normal limits, except for minor bruising on his legs, which he says was a result of a fall earlier in the day. When asked his name, the man replies, "I don't know." Flight records indicate that the patient flew from a city hundreds of miles away approximately a day ago and also confirm his identity. When family members are contacted, they indicate that the patient's wife died about 2 weeks ago, and the patient has also had some ongoing financial problems. Family members have been unable to reach him for the past several days. They indicate that he is not on any medications and that, while he had grieved his wife's death, he had appeared to be recovering well the last time they saw him. Medical evaluation including routine laboratory studies and a head CT is unrevealing.

- **What is the most likely diagnosis?** The most likely diagnosis is dissociative fugue. According to the *Diagnostic and Statistical Manual of Mental Disorders*, 4th ed., Text Revision (DSM-IV-TR), the predominant disturbance in dissociative fugue is sudden, unexpected travel away from home, coupled with confusion about personal identity or assumption of a new identity. Fugues may last from hours to months. Many patients exhibit only mild confusion during the fugue, and it is only after they emerge from the fugue that they panic or are disoriented, with limited recollection of events. Dissociative fugue is one of four dissociative disorders; the other three are dissociative amnesia, dissociative identity disorder (DID), and depersonalization disorder. Fugue is differentiated from dissociative amnesia by the sudden (and often extensive) travel undertaken by fugue patients. Patients with DID, although amnesic about certain events, do not claim to be confused about their identity; they simply assume multiple identities.

 - **What conditions should be included in the differential diagnosis?** By definition, a patient's disturbance during dissociative fugue cannot be due to the direct physiological effects of a substance or a general medical condition. Due to this patient's age and history, dementia and head trauma should both be ruled out. Although this patient is not on any prescribed medications, the physician should also screen for any substances the patient might have ingested to trigger this condition. The physician should also attempt to ascertain whether the patient is malingering; most fugues are a result of an unbearable trauma such as war, natural disasters, and childhood abuse. The patient, therefore, may attempt to absolve himself of accountability or otherwise remove himself from a hazardous situation by assuming a new identity. Other disorders that must be ruled out include bipolar disorder, schizophrenia, early symptoms of other neurological disorders such as multiple sclerosis, or a seizure disorder.

 - **What is the most appropriate treatment for this patient?** The goal of this patient's treatment should be to help him cope with the stress or trauma that originally triggered the fugue. The patient is likely suffering from depression, and appropriate psychotherapy and medication relating to that diagnosis should be prescribed. Family therapy may also be helpful, in order to teach family members about the disorder and how they might recognize future occurrences.
-

► CASE 11

A 32-year-old pregnant woman with a history of drug abuse and depression presents to the emergency department for evaluation of a sprained wrist. On physical examination, several bruises in various stages of healing are noted on her torso and upper extremities. The cause of her injuries is unclear, because she initially says that she slipped and fell against a table; the appearance and distribution of her bruises are not consistent with her story. She seems uncomfortable when pressed further for clarification and changes the details several times.

-
- | | |
|---|---|
| <ul style="list-style-type: none"> ■ What is the most likely cause of her injury? | <p>Physical abuse, specifically intimate partner violence (IPV). The following should lead a physician to suspect an abusive relationship:</p> <ul style="list-style-type: none"> ■ An inconsistent explanation of injuries or a delay in seeking treatment is often the first clue. ■ Frequent emergency room visits are also common with victims of abuse. Abusers may permit emergency room visits (as opposed to a primary care physician's office), where there is a lower risk of continuity of care and thus less of a chance for arousal of suspicion of abuse. ■ Gynecologic conditions that are seen more frequently in abused patients include premenstrual syndrome, sexually transmitted diseases, unintended pregnancy, and chronic pelvic pain. Abused women may have frequent abortions because of repeated sexual assaults and the inability to use birth control. ■ Poor follow-up is frequent because abusers will not let their victims come to the office or may take medications away as a means of retaliation. ■ Psychiatric disorders that are seen more frequently in abused patients include substance abuse, anxiety, depression, and eating disorders. ■ Victims of abuse often present with somatic complaints like chronic abdominal pain, headaches, and fatigue. |
| <ul style="list-style-type: none"> ■ What is the epidemiology of this condition? | <p>Women of all ages, socioeconomic classes, and ethnicities are victims of IPV, defined as either physical or sexual abuse. It is estimated that, in the United States, over 1.5 million women and 800,000 men are victims of abuse each year. Between 14% and 18% of couples reported episodes of physical violence in the previous year. Women who are pregnant or in the postpartum period are at increased risk of abuse. Abused pregnant women have a threefold increased risk of being victims of attempted or completed homicide than nonabused women with similar demographics.</p> |
| <ul style="list-style-type: none"> ■ What is the best approach to the patient in whom abuse is suspected? | <p>The Massachusetts Medical Society Committee on Violence recommends asking one question that can be adapted as needed: "At any time, has a partner hit, kicked, or otherwise hurt or threatened you?" This one question has been found to significantly increase the detection rate of partner violence. It is also important to assess whether the patient has a safe place to go if she is being abused. A physician should have ready access to appropriate resources for patients in abusive relationships.</p> |
-

► **CASE 12**

A 24-year-old nursing student presents to the emergency department (ED) after a syncopal episode. She was studying with a friend but took a break to go to the bathroom; when she returned, she complained of light-headedness and was diaphoretic. The friend states she then slumped over on the desk, unresponsive, so he called 911. Fingertick blood glucose en route was 24 mg/dL, and she was revived with glucose. She describes multiple similar episodes, for which she has undergone an extensive workup without diagnosis. She is reluctant to give the names of any of her former providers. Physical examination is within normal limits. A C-peptide level is low.

- **What is the most likely diagnosis?** Munchausen's syndrome. This is a form of factitious disorder, in which patients injure themselves or fabricate symptoms for primary gain (the sympathy and attention given to the sick). In Munchausen's syndrome, patients will fabricate physical symptoms (not those of a mental illness); it is more common among health care workers. In this case, the patient's symptoms are due to surreptitious injection of insulin, resulting in hypoglycemia.

 - **What is the C-peptide level?** C-peptide is a by-product of endogenous insulin production from the cleavage of proinsulin into insulin. It is not present in exogenous sources of insulin. In this case, the low levels of C-peptide suggest that the patient received exogenous insulin supplies (thus reducing clinical suspicion for an insulinoma or other pathology).

 - **What other conditions must be considered?** Hypochondriasis is a somatoform disorder in which the patient is convinced she has a specific disease, despite reassurance from medical providers. The patient may complain of physical symptoms (e.g., chest pain); however, she does not have conscious control over the symptoms and does not take measures to create these symptoms, unlike in a factitious disorder. Malingering is similar to factitious disorder, in that patients intentionally create or feign their symptoms. The motivation in malingering, however, is secondary gain, such as financial benefits.

 - **What are the five types of somatoform disorders?** Somatoform disorders are those in which the patients have no conscious control over their unexplained somatic symptoms. There are five types:
 - Somatization disorder: multiple chronic complaints from a variety of organ systems.
 - Conversion disorder: motor or sensory losses that are incompatible with a neurologic process and are closely related to a stressful event.
 - Hypochondriasis: preoccupation with a specific disease.
 - Body dysmorphic disorder: preoccupation with an imagined physical defect; typically seen in dermatology and plastic surgery offices.
 - Pain disorder: pain symptoms inconsistent with a physiologic process; frequently associated with depression.

 - **What is the most appropriate treatment for this condition?** While patients with Munchausen's syndrome are eager to seek treatment for their fabricated medical conditions, they are typically very unwilling to accept or be treated for their underlying diagnosis. Psychotherapy is the mainstay of treatment, which focuses on uncovering the psychological basis of the disorder. Family therapy may also be helpful, if the family is reinforcing the behavior by encouraging the sick role. Prognosis for these patients is generally poor; efforts should be made to protect them by preventing unnecessary medical procedures.
-

► CASE 13

A 42-year-old man presents to his primary care physician with a chief complaint of insomnia. He states he is able to fall asleep quickly but wakes up in the middle of the night and is unable to get back to sleep. He lies in bed worrying about his job as an accountant in a large firm, the health of his aging parents, the country's involvement in wars overseas, the encroachment of gangs in his city, and any number of seemingly random, unrelated topics. He complains of frequent tension headaches and does not feel like he is ever "really relaxed." He reports occasionally feeling short of breath and experiences heart palpitations. He is concerned because his restlessness is affecting his ability to concentrate at work, and they are heading into the busiest time of year. He says he has felt this way for most of his adult life but that his symptoms seem to be getting worse. The only thing that seems to help is if he has a few drinks after work, but he does not want to become dependent on alcohol to ease his nerves.

-
- | | |
|--|---|
| <ul style="list-style-type: none"> ■ What is the most likely diagnosis? | <p>This patient meets several of the DSM-IV-TR criteria for generalized anxiety disorder (GAD). This disorder is characterized by excessive worry and anxiety that is difficult for the patient to control. The focus of the worry is broad and includes issues regarding the patient's or others' health, life circumstances, finances, job performance, and more global issues. The criteria require that at least three of the following six symptoms be present for more days than not over a period of 6 months: restlessness or feeling keyed up or on edge, easy fatigability, difficulty concentrating, irritability, muscle tension, and sleep disturbance.</p> |
| <ul style="list-style-type: none"> ■ What is the epidemiology of this condition? | <p>GAD is common in the general population, with estimates of lifetime prevalence ranging from 4% to 7%. Women, African Americans, and persons under 30 are most likely to be affected; persons at any age, however, may develop the disorder. It is regarded as a chronic condition that worsens with life stressors and with the occurrence of negative life events. Few patients seek help to directly address the anxiety; most will consult their physicians regarding somatic complaints associated with the disorder.</p> |
| <ul style="list-style-type: none"> ■ What conditions should be included in the differential diagnosis? | <p>GAD often coexists with other mental disorders, especially phobias (specific and social), dysthymic disorder, depressive disorders, panic disorder, and substance abuse disorders. It is important to distinguish GAD from other anxiety disorders, depression with comorbid anxiety, and anxiety secondary to medical conditions, substance use, or that occurring exclusively during posttraumatic stress disorder. Social phobia is characterized by a fear of being humiliated publicly and a fear of social or performance situations. Panic attacks are discrete occurrences of intense fear; depression with comorbid anxiety has a predominating depressive nature. A careful history will differentiate substance intoxication (notably cocaine or amphetamines) or alcohol withdrawal symptoms from GAD.</p> |
| <ul style="list-style-type: none"> ■ What is the most appropriate treatment for this condition? | <p>Newer antidepressants, including the selective serotonin reuptake inhibitors and an extended-release form of the antidepressant venlafaxine, have proven successful and are now considered first-line therapies for GAD. Buspirone, a nonbenzodiazepine anxiolytic, is also effective. Benzodiazepines have also been used with success but must be closely monitored due to their abuse potential. Given the chronic nature of this condition, patients should be advised that the treatment course will be at least 6–12 months and may be needed indefinitely.</p> |
-

► **CASE 14**

An 81-year-old man is brought to his geriatrician by his daughter because she is concerned about his recent behavior. She says he has been crying frequently and not eating well. The patient admits that he has been feeling despondent lately and has told his children he no longer wishes to be a burden to them and that they would be better off if he weren't around anymore. Prior to the past few weeks, he was still active and played poker regularly with other men in his retirement community. He says he "has not been up to it" for the past 2 weeks and finds himself sleeping throughout the day. The patient denies experiencing manic symptoms or auditory or visual hallucinations. The results of his physical examination are essentially normal, although he has lost 4.5 kg (10 lb) since his last visit and exhibits psychomotor slowing. His medications include an angiotensin-converting enzyme inhibitor and a thiazide diuretic, neither of which were prescribed recently.

■ **What is the most likely diagnosis?**

This patient is showing signs and symptoms of major depression (decreased energy, hypersomnia, anhedonia, crying spells, suicidal ideation, anorexia with weight loss, guilt, and psychomotor retardation). A useful mnemonic for the criteria for major depression is **SIG E CAPS**:

S: sleep changes

I: (decreased) interest

G: (excessive) guilt

E: (decreased) energy

C: (poor) concentration

A: appetite changes

P: psychomotor agitation or retardation

S: suicidal ideation

Five or more of the above symptoms must be present during the same 2-week period, with at least one of the symptoms being either depressed mood or anhedonia.

■ **What further workup ought to be pursued?**

This patient has expressed thoughts of death. The treating physician must assess the scope of this patient's intentions (e.g., does he have a plan, does he have access to a weapon, etc.). Suicide rates among the geriatric population, especially among elderly Caucasian males, are increasing. In addition, older adults who are divorced or widowed are at higher risk for suicide than those who are married. Close observation in the hospital while treatment is being initiated would be warranted if he intends to harm himself.

■ **What treatment options are available for this patient?**

The treatment options are the same as those for younger patients. They include the selective serotonin reuptake inhibitors, monoamine oxidase inhibitors, atypical antidepressants, tricyclic antidepressants, electroconvulsive therapy (ECT), and psychotherapy. Because older patients have decreased metabolism and clearance rates, they may require smaller doses to achieve a therapeutic effect. As a rule of thumb, one should "start low and go slow" when titrating antidepressants in this population. Orthostasis and anticholinergic symptoms are more frequently reported because of increased sensitivity to side effects in elderly patients. It is also important to be aware of potential drug-drug interactions because of the prevalence of polypharmacy in the geriatric population.

■ **What is the role of ECT in the treatment of this condition?**

ECT is a treatment that involves the induction of generalized seizures by passing an electric current through the brain. It is thought that seizure induction releases chemicals such as serotonin and dopamine in the brain, thus creating an effect similar to that of antidepressant medication. It is one of the safest and most effective treatments available for depression, especially for elderly patients who cannot tolerate antidepressants or in cases where their use is contraindicated. Furthermore, the mood-enhancing effect of ECT is faster than that seen with antidepressants.

► **CASE 15**

A 31-year-old man has decided to seek treatment from a psychiatrist through his employee assistance program because he feels that his drinking is jeopardizing his work and that he might be fired if he does not quit. He states that his job as a computer programmer is “okay” because he can keep to himself and not be bothered by his coworkers. During the interview, he reveals that he lives alone and has never had a girlfriend. He states that he does not miss having sex and that masturbation and computer pornography satisfy his sexual needs. He speaks to his brother frequently but has not seen other members of his family in quite some time; he shows little interest or affection in describing his relationship with them. He says that most nights he stays home surfing the Internet, playing computer games, or watching TV, and drinking up to a 12-pack of beer per night. He also smokes marijuana 4–5 times per week. On a mental status examination, he appears detached and aloof toward the psychiatrist. He reports his mood as “a little depressed”; his affect is congruent, and his range is flat. No other disorders are noted on examination.

- | | |
|--|--|
| ■ What is the most likely diagnosis? | <p>Schizoid personality disorder. He meets the following <i>Diagnostic and Statistical Manual of Mental Disorders</i>, 4th ed., Text Revision (DSM-IV-TR) criteria for this diagnosis:</p> <ul style="list-style-type: none">■ Neither desires nor enjoys close relationships, including being part of a family.■ Almost always chooses solitary activities.■ Little, if any, interest in having sexual experiences.■ Takes pleasure in few, if any, activities.■ Lacks close friends or confidants other than first-degree relatives.■ Shows emotional detachment and a flat affect. <p>Another criterion for this diagnosis is that patients may appear indifferent to the praise or criticism of others. This disorder is included with the Cluster A personality disorders in the DSM-IV-TR, along with schizotypal and paranoid personality disorders.</p> |
| ■ What conditions should be included in the differential diagnosis? | <p>Schizophrenia, a mood disorder with psychotic features; avoidant personality disorder, another psychotic disorder; and a pervasive developmental disorder are all included in the differential diagnosis. Effects of a general medical condition must be ruled out as well. Note that individuals with avoidant personality disorder typically express a desire for interpersonal relationships, unlike those with schizoid personality disorder.</p> |
| ■ How is schizotypal personality disorder differentiated from this condition? | <p>Although both disorders are marked by social and emotional detachment, schizotypal personality disorder more closely mimics schizophrenia, even though most patients with schizotypal personality disorder do not ultimately develop schizophrenia. Patients often display odd behavior and unconventional beliefs (i.e., beliefs in clairvoyance, telepathy, or other superstitions inconsistent with subcultural norms).</p> |
| ■ What other traits are typically seen in patients with this condition? | <p>Patients with this disorder have a profound defect in the ability to form personal relationships and to make intimate attachments. They are unable to respond to others in a meaningful way and do not appear to be disturbed by this fact. These patients are not often seen in the clinical setting because they rarely seek professional help unless there is another disorder present such as depression, anxiety, or substance abuse.</p> |
-

- **What treatment approach would be best for this patient?**

These patients usually lack the insight or motivation to pursue individual therapy in order to address the underlying disorder, and a group therapy setting would likely prove too threatening. Therefore, this patient would benefit most from addressing his substance abuse issues.

► **CASE 16**

A 35-year-old homeless man is admitted to the medical ward for treatment of an acute asthma exacerbation. He has a medical history significant for chronic severe asthma with multiple hospital admissions, as well as tobacco use, heroin abuse, hypertension, and chronic, untreated tinea corporis infection. He is on his third day of supportive treatment with nebulized albuterol, metered-dose inhaled fluticasone, and an oral prednisone taper when he develops nausea, vomiting, and nonbloody diarrhea. He denies chest pain, palpitations, shortness of breath, dizziness, abdominal pain, fevers, or chills. His vital signs are within normal limits, and he has teary eyes with dilated pupils; he is yawning and sneezing intermittently.

- **What is the most likely diagnosis?** This constellation of signs and symptoms most likely represents opioid withdrawal. Pupillary dilation, lacrimation, rhinorrhea, yawning, piloerection, nausea, vomiting, and diarrhea are the most common signs and symptoms of acute opioid withdrawal. Given his history of heroin use, it is likely that the patient was actively using heroin immediately prior to his hospitalization.

 - **What is the epidemiology of this condition?** Approximately 2.4 million people have used heroin in the United States, as reported in the 1998 National Household Survey on Drug Abuse. Heroin-related emergency department visits more than doubled between 1990 and 1996 to approximately 70,000, according to the U.S. Department of Health and Human Services.

 - **What factors determine the severity and duration of this condition?** The time of onset, severity of symptoms, and duration of symptoms are directly related to the pharmacokinetics of the particular opioid involved. Of the most commonly abused opioids, heroin has an earlier, higher peak of severity (approximately 3 days of abstinence) compared with buprenorphine (4 days) and methadone (7–8 days), as well as a shorter overall duration of withdrawal symptoms.

 - **What is the most appropriate treatment for this condition?** Long-acting opioids such as methadone and buprenorphine are the most widely accepted first-line treatment for opioid withdrawal. Symptomatic treatments such as clonidine and bethyl for autonomic instability and abdominal distress may also be used. A point scoring system of clinical signs can be used, in which a score of zero is given if a sign is absent, a score of one if it is present, and a score of two if it is severe. The signs to be scored include dilated pupils, runny nose, watery eyes, “goose” flesh, nausea or vomiting, diarrhea, yawning, cramps, restlessness, voiced complaints, and increased vital signs. The point total is equated with a total dosage of methadone to be given, in milligrams. The patient should be rescored and redosed at 6-hour intervals. A 24-hour total should be calculated, and then, after the patient has been stabilized, should be reduced by 10% per day. After the acute withdrawal period has ended, the patient should be referred to an outpatient opioid maintenance program (i.e., a methadone clinic) or an abstinence-based program (e.g., Narcotics Anonymous) to prevent further drug abuse and related physical, social, and legal morbidity.
-

► **CASE 17**

A 21-year-old man is brought to the emergency department by his girlfriend because of his “wild” behavior over the past 2 weeks. His girlfriend reports that during this period of time he has slept very little each night and that he seems to be talking faster than usual. He also has stopped attending his classes at the local community college. He frequently writes in a notebook, although his girlfriend states that the excerpts she has read make no sense. She also reports that he has depleted his bank account on a buying spree at a department store. When questioned, he confirms his recent purchases and states that he will make more money after he completes the novel he is writing.

<p>■ What conditions should be included in the differential diagnosis?</p>	<ul style="list-style-type: none"> ■ Psychiatric disorders such as schizophrenia and schizoaffective disorder. ■ Substance-induced mood disorder. ■ Mood disorder due to a general medical condition such as AIDS, endocrinopathies, lupus, neurological disorders.
<p>■ What is the most likely diagnosis?</p>	<p>Bipolar I disorder. This condition is a mood disorder that can be diagnosed after a single manic episode, although most patients experience both manic and depressive episodes. A manic episode is defined as a period of persistently elevated, expansive, or irritable mood that lasts at least 1 week, causes marked impairment, is not due to the effects of a substance or a general medication condition, and presents with at least three (or four, if the mood is irritable) of the following symptoms, recalled best by the mnemonic DIG FAST:</p> <p>Distractibility Insomnia Grandiosity Flight of ideas Activity/psychomotor agitation Sexual indiscretions Talkativeness</p>
<p>■ How is this condition classified?</p>	<ul style="list-style-type: none"> ■ Bipolar I: At least one manic or mixed episode that may alternate with major depressive/hypomanic episodes. ■ Bipolar II: At least one major depressive episode and one hypomanic episode. Patients do not meet criteria for full manic or mixed episodes. ■ Rapid cycling: Four or more episodes (major depressive, manic, mixed, or hypomanic) in 1 year. ■ Cyclothymia: Chronic and less severe than rapid cycling; this diagnosis includes alternating episodes of hypomania and moderate depression.
<p>■ What is the epidemiology of this condition?</p>	<p>The lifetime risk of bipolar I disorder is approximately 1%, and it is equally prevalent among men and women and across racial groups. The mean age of onset is 30 years old, and the frequency of mood episodes increases with age. A family history of bipolar disorder increases the risk. Ten to fifteen percent of patients diagnosed with bipolar disorder successfully commit suicide.</p>
<p>■ What is the most appropriate treatment for this condition?</p>	<p>Acute mania is treated with mood stabilizing medications. These include lithium, antiepileptics, and/or antipsychotics. Benzodiazepines may be useful when there is prominent agitation. Electroconvulsive therapy has also been shown to be effective.</p>

► **CASE 18**

A 28-year-old woman presents to her primary care physician for an annual checkup. During the examination, the doctor notices several linear scars and a few dime-sized burns on her arms and thighs. When he inquires about these, the patient admits to cutting herself with a utility knife and burning herself with cigarettes. She then starts crying and states these episodes occur when she gets “stressed out” and agitated when she perceives that people have abandoned her. She denies that these are suicidal gestures but admits that she frequently threatens to commit suicide and drives erratically to see if she might get into a life-threatening accident. She describes her relationship with her boyfriend as “out of control” and states that they are constantly fighting with each other. These fights, which are often violent, are usually over her drinking and drug use. Surprised that she would reveal so much to him, the doctor questions her on this. She says she is willing to confide in him because she likes him more than any other doctor she has seen. In fact, she thinks the other doctors are “quacks” and should not be allowed to practice.

- **What is the most likely diagnosis?** Although a thorough diagnostic workup is needed, this patient exhibits several of the traits of borderline personality disorder (BPD). This Axis II, Cluster B disorder represents a pervasive pattern of mood instability, unstable and intense interpersonal relationships, impulsivity, inappropriate or intense anger, lack of control of anger, recurrent suicidal threats or gestures, self-mutilating behavior, marked and persistent identity disturbance, chronic feelings of emptiness or boredom, and frantic efforts to avoid real or imagined abandonment. They may also experience transient paranoid ideation or dissociative symptoms.

 - **Who is most likely to be affected with this condition?** This is one of the more common personality disorders among psychiatric patients. Its frequency in the general population is between 1% and 2%, and 15–20% in psychiatric inpatient populations. Women are three times more likely to be affected than men.

 - **What comorbid conditions often exist with this condition?** Other Axis II disorders are common among those with BPD; patients may also be histrionic, antisocial, or narcissistic types. Among Axis I comorbidities are mood disorders (especially depression), anxiety disorders, and substance abuse disorders. Most researchers believe there is a close association between childhood physical and sexual abuse and BPD. Forty to seventy-one percent report a history of sexual abuse, and 25% of patients with BPD also suffer from posttraumatic stress disorder.

 - **What defense mechanism is this patient exhibiting?** Her attitude toward this doctor and the others she has seen is an example of splitting. This is a defense mechanism in which patients rigidly separate positive and negative feelings in order to guard against uncomfortable emotional conflicts or stressors. Patients with BPD often see their world in a black or white perspective without any shades of gray. They alternately idealize and devalue important people in their lives and have enormous difficulty experiencing two contradictory emotions at one time. Borderlines can split the people in their life into warring “good” and “bad” factions that unwittingly act out the patient’s internal conflicts.

 - **What is the most appropriate treatment for this condition?** In addition to psychotherapy, practice guidelines recommend symptom-targeted pharmacotherapy. Antipsychotics such as risperidone or ziprasidone can be helpful in treating perceptual distortions; lithium carbonate, valproate, or other mood stabilizers can be useful in treating mood swings. Selective serotonin reuptake inhibitors are useful in treating depressive symptoms and suicidal ideations and behavior.
-

► CASE 19

A 22-year-old college student is referred to the dean of students because he is continuously missing assignment deadlines and is doing poorly on his examinations. He denies that he needs help with these issues and blames his poor performance on the unreasonable demands of his professors. He explains that he is unable to complete examinations because they are too long, and that the portions he does finish are very well written and infallible in their correctness. He explains that he keeps to a very rigid study schedule and does not waste time with “frivolous” activities like spending time with friends. As evidence, he presents his personal organizer that is impressive with the details of his schedule and long lists of things to do. When it is suggested that he join a study group, he adamantly refuses, stating that his classmates are inferior and would have nothing to contribute to his learning. He says that if the other students were more like him, they would get more done, but as it is, they are just lazy and unfocused. Sensing a deeper psychological root to his student’s problems, the dean refers him to the student counseling center but strongly doubts he will keep the appointment.

-
- | | |
|--|---|
| <p>■ What is the most likely diagnosis?</p> | <p>This student exhibits traits of obsessive-compulsive personality disorder (OCPD). According to the <i>Diagnostic and Statistical Manual of Mental Disorders</i>, 4th ed., Text Revision DSM-IV-TR, these patients are “preoccupied with orderliness, perfectionism, and mental and interpersonal control, at the expense of flexibility, openness, and efficiency.” The five areas that cause the most anxiety for individuals with OCPD are time, personal and social relationships, cleanliness, tidiness, and money. This manifests in their lives as rigidity and stubbornness, and they are often moralistic about others and their work habits, especially when they are compared to their own. In spite of this obsession with organization and schedules, they frequently have trouble meeting deadlines and run into trouble at work or school.</p> |
| <p>■ What other characteristics are typical of this condition?</p> | <p>Among the criteria that define this disorder in the DSM-IV-TR are the inability to discard worn-out or worthless objects that have no sentimental value to the patient, a miserly spending style in spite of adequate financial resources, an inflexibility concerning matters of morality, ethics, or values, and an unwillingness to delegate or work with others unless they submit exactly to their way of doing things. This is an ego-syntonic disorder, and those afflicted resist assuming responsibility for their failings. Instead, they blame others as the cause of their shortcomings.</p> |
| <p>■ What are the differences between this condition and obsessive-compulsive disorder (OCD)?</p> | <p>Because of the similarity of the names, the differences between OCPD and OCD can be difficult to distinguish. OCPD is an Axis II, Cluster C diagnosis that represents a lifelong pattern of perfectionism and inflexibility, typically associated with overconscientiousness and constricted emotions. No obsessions (intrusive, repetitive thoughts) or compulsions (ritualistic behaviors) are present that are typical of OCD, which is an Axis I diagnosis.</p> |
| <p>■ What is the most appropriate pharmacotherapy for this condition?</p> | <p>The heterocyclic antidepressant clomipramine and the selective serotonin reuptake inhibitors, such as fluoxetine, fluvoxamine, and paroxetine, have shown some efficacy in reducing the need for perfectionism and the unnecessary ritualizing that occasionally develops.</p> |
-

► **CASE 20**

A 20-year-old man is brought to his primary care physician by his mother, who is concerned about his behavior. Over the past year, he has become increasingly withdrawn and has stopped socializing with his friends. He typically spends the majority of each day alone in his room, although his mother often hears him talking loudly. When questioned, he states, “The FBI is looking for us, and all of my friends are working for them.” He admits to auditory hallucinations. He refuses a physical examination but is noted to have a flattened affect.

- **What is the most likely diagnosis?** Schizophrenia is a disorder characterized by hallucinations, delusions, disordered thoughts, behavioral disturbances, and negative symptoms. A diagnosis can be established if two or more symptoms are present for at least 6 months with social or occupational dysfunction. Positive symptoms include hallucinations, delusions, and disorganized speech/behaviors. Negative symptoms include flat affect, decreased emotional reactivity, poverty of speech, and lack of purposeful actions.

 - **How is this condition classified?**
 - Catatonic: Defined as a psychomotor disturbance with more than two of the following symptoms: excessive motor activity, immobility, extreme negativism or mutism, posturing, peculiar mannerisms, echolalia, or echopraxia.
 - Disorganized: Speech and behavioral patterns are highly disorganized. Flat affect is a prominent feature.
 - Paranoid: Delusions, often persecuting, and/or hallucinations are present. Cognitive function is preserved.

 - **What is the epidemiology of this condition?** The prevalence of schizophrenia is approximately 1%, and it occurs equally in men and women. However, men tend to develop the disease earlier than women. Peak age of onset is 18–25 years in men and 25–35 years in women. Schizophrenia in first-degree relatives increases the risk of the disorder.

 - **What conditions should be included in the differential diagnosis?**
 - Mood disorders with psychotic features: Psychosis occurs only during an episode of depression or mania.
 - Organic causes of psychosis including neurological and medical disorders.
 - Schizophreniform disorder: Symptoms of schizophrenia present < 6 months.
 - Schizoaffective disorder: The presence of both schizophrenia and a major affective disorder, with a period of 2 weeks of active psychotic symptoms without mood symptoms.
 - Substance abuse: Psychosis can occur as a result of cocaine, amphetamines, phencyclidine (PCP), and lysergic acid diethylamide (LSD).
-

- **What is the most appropriate treatment for this condition?**

Schizophrenia is best managed with antipsychotic medications and hospitalization during psychotic episodes. Cognitive-behavioral therapy, supportive psychotherapy, family therapy, and social skills training may be beneficial.

- **What adverse events are associated with treatment?**

Treatment with antipsychotics can result in neuroleptic malignant syndrome and extrapyramidal side effects like tardive dyskinesia, parkinsonism, akathisia, and acute dystonia. These result from the blockade of dopamine receptors in the basal ganglia and occur more commonly with high-potency antipsychotics. With the newer atypical antipsychotics, extrapyramidal side effects can occur although more rarely. A metabolic syndrome including increases in weight, fasting blood glucose, and cholesterol is more common.

► **CASE 21**

A 26-year-old man presents to a psychiatrist at the Veteran's Administration Behavioral Health Outpatient Clinic 2 years after being discharged from the Army. While enlisted, he served two tours overseas and saw active combat in the Persian Gulf region. He witnessed three fellow soldiers killed by a roadside bomb and states that he cannot get these and other disturbing images out of his head. He tells the psychiatrist that, since he returned home, "Things just have not been the same." He says he does not sleep much because of nightmares during which combat scenes are replayed. He also finds himself flinching each time he hears helicopters flying overhead. He refuses to watch the nightly newscasts that cover the war and will not read newspaper stories about it. He says he has not been able to "let down his guard," even with his wife. Their relationship has been strained by his emotional distance and his frequent angry outbursts. Since his discharge he has held four jobs, none longer than 5 months, and he is currently unemployed. On mental status examination, his appearance, behavior, and speech are normal. He does have an exaggerated startle response when his cellular phone rings during the interview. He describes his mood as "depressed," and his affect is congruently dysphoric. His thought process is linear and logical, and he denies auditory or visual hallucinations. He also denies homicidal or suicidal ideations.

- **What is the most likely diagnosis?** Chronic posttraumatic stress disorder (PTSD), as a result of the traumatic events he experienced while on active duty. He is persistently reexperiencing the scenes he witnessed in his nightmares. He avoids reminders of the events by refusing to watch or read about the war. He is emotionally detached from his wife and has symptoms of hyperarousal, including insomnia and angry outbursts. This is causing significant distress due to his inability to maintain employment and his relationship with his wife. Since the duration of symptoms is > 3 months, this is chronic PTSD and not acute PTSD (note that his symptoms must exist for at least 1 month in order to be qualified as PTSD). Any event that involves actual or threatened death, serious physical injury, or a threat to one's physical integrity may precipitate PTSD. The events, by definition, must be severe enough to be outside the range of normal human experience. Therefore, events such as divorce, loss of a job, or the death of a loved one would not be considered stressors that cause PTSD.

 - **What is the epidemiology of this condition?** The prevalence of PTSD in the general population ranges from 1% to 3%, with women being twice as likely to develop the disorder. The disorder is more likely to occur in those who have limited social support (e.g., single, divorced, widowed) or a lower socioeconomic status. The strongest predictor is a history of mental illness preceding the stressor.

 - **What is the course and outcome of this condition?** Symptoms of PTSD may occur immediately after the event or surface years afterward. For those with chronic PTSD, the symptoms can last for decades; they often fluctuate and are worse during times of stress. Many patients with the disorder develop mood disorders such as major depression, anxiety disorders, and substance use disorders, notably with alcohol. Rapid onset of symptoms, healthy functioning prior to the inciting event, strong social support, and the absence of comorbid psychiatric or medical issues are factors associated with a good outcome.

 - **What is the most appropriate pharmacotherapy for this condition?** Selective serotonin reuptake inhibitors such as sertraline and paroxetine, as well as tricyclic antidepressants and monoamine oxidase inhibitors, have been used to decrease symptoms of depression, reduce the intrusive symptoms such as nightmares and flashbacks, and normalize sleep.
-

► CASE 22

At her initial office visit, a 29-year-old woman presented with a chief complaint of weakness and malaise of 3 years' duration. She states, "I've learned to live with weakness and tiredness all the time." These symptoms began shortly after she gave birth to her only child, and she thought it might be because of her difficult pregnancy, during which she experienced nausea and vomiting throughout the 9 months. Over the course of the next 3 years, she consulted many physicians with a variety of complaints: diffuse abdominal pain, trouble swallowing, constipation, headache, back pain, joint pain, and excessive menstrual bleeding. To evaluate the abdominal pain and constipation, she had a barium enema examination and upper gastrointestinal x-ray series. The test results were normal. On her most recent visit, she states she has been feeling a strange numbness and tingling in her left leg. Her past surgical history is significant for an appendectomy, cholecystectomy, and arthroscopic surgery on her right knee. She has been unable to work because of her symptoms and claims they have "ruined her life." The mental status examination is notable for the patient's anxious affect.

- | | |
|--|--|
| ■ What is the most likely diagnosis? | This patient has somatization disorder. This disorder is characterized by numerous physical complaints that cannot be explained by any medical condition and that involve most of the organ systems. According to the DSM-IV-TR, these complaints must consist of four pain symptoms, two gastrointestinal symptoms, one sexual symptom, and one pseudoneurological symptom. These somatic complaints begin before the age of 30, must occur over a period of several years, and result in medical treatment or cause significant impairment in areas of functioning. There cannot be any evidence that the symptoms are feigned or intentionally produced, in which case the patient would more appropriately be diagnosed with factitious disorder or malingering. This disorder affects mostly women. |
| ■ What are other somatoform disorders? | Other somatoform disorders include: conversion disorder, pain disorder, hypochondriasis, body dysmorphic disorder, and undifferentiated somatoform disorder. Hypochondriasis is marked by an overreaction to minor physical symptoms or sensations. Patients usually do not complain of disabling pain and are more focused on the development of one severe condition rather than multiple conditions, as is the case in somatization disorder. |
| ■ What is the best approach for this patient? | A brief physical examination should be performed to address each new complaint, but laboratory and diagnostic procedures should be kept to a minimum or avoided to minimize the risk of iatrogenic complications. The presence or absence of objective signs should guide physicians to determine whether labs or procedures are needed. Patients with this disorder often visit several physicians with their multiple complaints; hence, an effort must be made to identify one primary caregiver who will be aware of all the specialists involved. It is recommended that the patient be scheduled for regular (usually monthly) brief visits with this physician, with an emphasis on "caring" rather than "curing" the patient. Psychotherapy is useful if the patient will pursue it. |
| ■ What is the prognosis for patients with this condition? | Somatization disorder is a chronic illness. The symptoms are chronic and fluctuating; they rarely disappear completely. It often leads to repeated surgeries, drug abuse, marital instability, major depression, and suicide attempts. Approximately two-thirds of patients also have personality disorders such as borderline or histrionic personality disorder. A family history of somatization disorder is very common. There is also a high comorbidity of childhood sexual abuse and neglect (30–70%). |
-

► **CASE 23**

A 14-year-old boy is being evaluated by his pediatrician. Two years ago he began repetitively shrugging his shoulders. He does so repeatedly throughout the day, but more frequently during times of stress. He is able to control the urge briefly but explains that eventually he must “shrug.” In the past few months, he has begun blurting out embarrassing obscenities in public. He realizes he is doing this, but again, can only exert brief control over it. He says this happens when he is alone and also at inappropriate times like in the classroom or at the movies. This has caused him to get in trouble with his teachers, although he is otherwise doing well in school and has no problems socializing with his peers. His mother was diagnosed with and is being treated for obsessive-compulsive disorder (OCD).

- **What is the most likely diagnosis?** Tourette’s disorder, which may be diagnosed when a person exhibits both multiple motor and one or more vocal tics over a period of a year, with no more than three consecutive tic-free months. According to the *Diagnostic and Statistical Manual of Mental Disorders*, 4th ed., Text Revision (DSM-IV-TR), tics are sudden, involuntary, recurrent, nonrhythmic, and stereotyped motor movements or vocalizations. This is in contrast to the compulsions of obsessive-compulsive disorder (OCD), which are voluntary acts. Further in contrast to OCD, the tics of Tourette’s need not interfere with normal function, cause marked distress, or be excessively time consuming (at least one of these features must be present for the diagnosis of OCD). The vocal tics are usually socially offensive, such as loud grunting, barking, or shouting words. Vocal tics can also include coughing, throat clearing, whistling, etc. Motor tics are also odd and often offensive movements, such as sticking out one’s tongue, sniffing, eye blinking, kicking, etc. There are many different ways patients can tic, but individuals usually identify one or two tics particular to them. They are able to exert a mild degree of control over the vocal and motor tics but ultimately must submit to them.

 - **What is the epidemiology of this condition?** Tourette’s is uncommon in the general population, with prevalence between 1 and 10 per 1000. Monozygotic twins have a concordance rate of 50%; dizygotic twins, 8%. Boys are three to nine times more likely to be affected than girls. Since tics tend to remit or subside as children mature, fewer adults have Tourette’s, and population estimates for adults may underestimate the prevalence rates in children. The motor component usually emerges by age 7, and the vocal component by 11 years of age.

 - **What factors are among the etiology and pathophysiology of this condition?** There is a strong familial and comorbid link between OCD and Tourette’s. Two-thirds of the first-degree relatives of patients with Tourette’s disorder have tics, and a substantial number have OCD or attention-deficit/hyperactivity disorder. Some children have the onset of Tourette’s symptoms after infection with group A β -hemolytic *Streptococcus*. Tourette’s, along with Sydenham’s chorea, is now among the group of syndromes known as the pediatric autoimmune neuropsychiatric disorders associated with streptococcal infections (PANDAS).
-

- **What is the most appropriate pharmacotherapy for this condition?**

The dopamine system appears to be involved in tic disorders; therefore, dopamine antagonists, such as haloperidol, are considered first-line treatment. Haloperidol is usually given in doses lower than those used to treat psychosis. Recently, Tourette's has been effectively treated with the atypical antipsychotics, such as risperidone. Adrenergic agonists such as clonidine have also shown some degree of tic reduction; a decrease in the release of norepinephrine in the central nervous system may lead to a reduction of dopaminergic activity.

► **CASE 24**

A 47-year-old man was diagnosed with AIDS 3 years ago. Shortly after his diagnosis, he informed his partner of 8 years over the phone; she subsequently hung up on him and refused to speak with him again. Since then, he has become progressively more socially isolated from his friends and family and has started drinking heavily. The pain from his peripheral neuropathy is a source of constant agony. On several occasions he has expressed a desire to die to his physician, and against the doctor's pleas he has stopped taking his antiretroviral medications. He refuses to seek help from a psychiatrist who could treat his depression and help him to cope with his illness. He views his illness as a punishment and sees no good in trying to delay the inevitable. He feels useless and beyond help.

■ **What is the epidemiology of suicide in the United States?**

The annual death rate from suicide is higher than the annual death rate from homicide. Suicide is the eighth leading cause of death for adults and the second leading cause of death for college students. Nearly 30,000 suicides occur each year; roughly 1% of the U.S. population commits suicide. For every completed suicide, there are 18 failed attempts. For men, suicides occur more frequently with age and peak at age 75 years; for women, the suicide rate peaks at 40–50 years. Men who commit suicide are most likely to be > 45 years old, white, and either separated, divorced, or widowed. Women are more likely to attempt suicide; men are more likely to complete the act. Most people who commit suicide see their physicians before they die, and some communicate their suicidal intentions to their physician. Research indicates that more than 90% of those who commit suicide have a major psychiatric illness, and half are clinically depressed at the time of the act.

■ **What is the relationship between physical illness and suicide?**

Nearly 5% of people who commit suicide have been diagnosed with a serious physical illness. Suicide rates are high among those diagnosed with AIDS, amyotrophic lateral sclerosis, Huntington's disease, traumatic brain injuries, epilepsy, multiple sclerosis, Parkinson's disease, and cancer. The suicide rate in patients with AIDS is nearly seven times greater than that in the general population. In many of these medical conditions, pain is often a contributing factor in the patient's decision to commit suicide.

■ **What assessment tools are helpful in identifying suicide risk?**

The following mnemonic (**SAD PERSONS**) is helpful to remember when assessing patients' suicide risk:

- Sex (male gender)
- Age (older)
- Depression
- Previous suicide attempt
- Ethanol abuse
- Rational thinking loss
- Social support lacking
- Organized plan
- No spouse or partner
- Sickness

Physicians should be direct in questioning and give the patient an opportunity to discuss his or her intentions. Questions to ask include:

- Have you been feeling like life is not worth living?
 - Have you been having thoughts of harming yourself?
 - Have you developed a plan for taking your life?
 - Do you have access to a weapon or means to commit the act?
-

Pulmonary

Case 1	434
Case 2	436
Case 3	438
Case 4	440
Case 5	441
Case 6	442
Case 7	443
Case 8	444
Case 9	446
Case 10	447
Case 11	448
Case 12	450
Case 13	452
Case 14	453
Case 15	454
Case 16	456
Case 17	458

► **CASE 1**

A 50-year-old woman is recovering in the surgical intensive care unit following emergency removal of a ruptured appendix. She was extubated on postoperative day 2 but has remained febrile with gram-negative bacteremia. She is receiving cefepime through a subclavian central venous catheter. Within the past 3 hours, she has become tachypneic and now requires oxygen via nasal cannula to keep her oxygen saturation level above 93%. The nurse notes that her temperature is 40.0° C (104.0° F), her heart rate is 100/min, her respiratory rate is now 30/min, her blood pressure is 90/50 mm Hg, and her oxygen saturation has dropped to 85%. The patient is complaining of difficulty breathing, and high-pitched rales are heard on lung auscultation. The patient is switched to 100% oxygen via nonrebreather mask, and an arterial blood gas analysis is performed with the following results: pH 7.30, CO₂ 50 mm Hg, PO₂ 55 mm Hg, HCO₃⁻ 18 mEq/L, and O₂ saturation 85%. An x-ray film of the chest is shown in Figure 15-1. A Swan-Ganz catheter is placed, and the wedge pressure is recorded as 15 mm Hg.

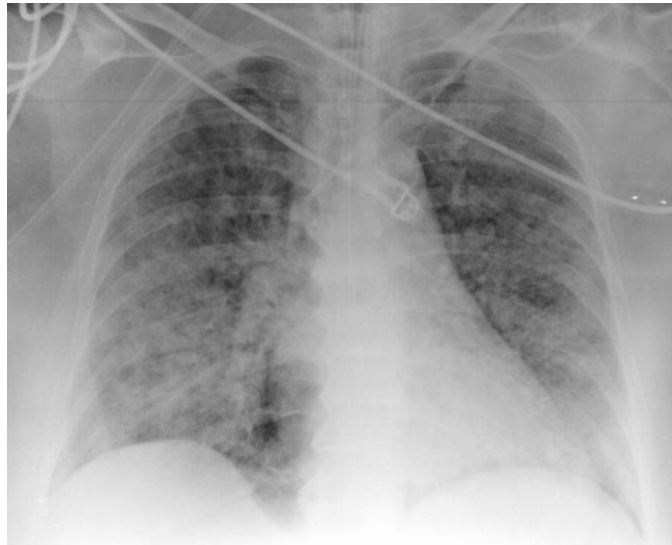

FIGURE 15-1. (Reproduced, with permission, from Kasper DL, Braunwald E, Fauci AS, Hauser SL, Longo DL, Jameson LJ, Isselbacher KJ, eds. *Harrison's Principles of Internal Medicine*, 16th ed. New York: McGraw-Hill, 2005: Fig. 251-2.)

-
- **What is the most likely diagnosis?** Acute respiratory distress syndrome (ARDS). ARDS is severe, acute respiratory failure due to endothelial injury and noncardiogenic pulmonary edema with hypoxemia and decreased lung compliance. The diagnostic criteria are summarized by the mnemonic **ARDS**:
Acute onset.
Ratio of PaO₂/FIO₂ < 200.
Diffuse bilateral infiltrates seen on x-ray of the chest.
Swan-Ganz wedge pressure < 18 mm Hg or no evidence of left atrial hypertension.

 - **What are some causes of this condition?** There are many conditions that can lead to ARDS. Most involve systemic inflammation leading to leakage of fluid into the alveolar spaces. These include sepsis, pneumonia, aspiration, trauma, smoke or toxic gas inhalation, shock, pancreatitis, transfusion reaction, surgery, obstetric emergencies, burns, disseminated intravascular coagulation, and multisystem organ failure.
-

<ul style="list-style-type: none"> ■ What are the typical radiologic findings in this condition? 	<p>X-ray of the chest will show diffuse bilateral alveolar infiltrates with a classic “ground-glass” appearance (see Figure 15-1).</p>
<ul style="list-style-type: none"> ■ What are the treatment options for this patient? 	<p>Treatment in ARDS focuses on treating the underlying disease process while supporting ventilation, oxygenation, and circulation. A low tidal volume ventilation strategy should be employed to minimize barotrauma. In this patient, broadening antibiotic coverage to treat potential causes of sepsis is also crucial.</p>
<ul style="list-style-type: none"> ■ What is the treatment strategy for ventilating this patient? 	<p>This patient will require invasive mechanical ventilation to maintain oxygenation. Ventilating with low tidal volumes (calculate 6 mL/kg of ideal body weight) has been shown to improve clinical outcomes in ARDS. Positive end-expiratory pressure (PEEP) can improve oxygenation by keeping collapsed alveoli open. Titrate PEEP and FiO_2 to achieve adequate oxygenation; no consensus exists on the optimum level. When possible, the fraction of inspired oxygen should be kept below 60% to avoid oxygen toxicity.</p>
<ul style="list-style-type: none"> ■ What is the natural history of this condition? 	<p>The inflammatory cascade in ARDS can either spontaneously remit or lead to progressive fibrosis and fibrosing alveolitis. Mortality remains high.</p>

► **CASE 2**

A 70-year-old man with chronic obstructive pulmonary disease (COPD), congestive heart failure (CHF), myasthenia gravis, and chronic back pain is recovering after a motor vehicle accident. The patient fractured both tibiae and multiple ribs but escaped serious internal organ injury. His problem during this hospitalization has been pain control. He has recently been transitioned to oral oxycodone, but morphine injections are still needed for breakthrough pain. At the 4 A.M. vital sign check, the night nurse finds him unarousable. He has a respiratory rate of 5/min and an oxygen saturation of 80% by pulse oximetry. His heart rate is 80/min, and blood pressure is 130/80 mm Hg. He has pinpoint pupils, a normal cardiac exam, and clear lung fields. Arterial blood gas analysis shows a pH of 7.02, partial pressure of CO₂ of 90 mm Hg, partial pressure of O₂ of 45 mm Hg, and bicarbonate of 24 mEq/L. Administration of 100% oxygen by nonrebreather mask raises the oxygen saturation to 95%. Review of the medication log shows that the patient got two morphine injections in addition to his maximum oxycodone dosage.

-
- **What is the most likely diagnosis?** Acute hypercarbic respiratory failure secondary to opiate overdose. Opiates depress the central drive to breathe, first causing hypercarbia and then hypoxia. Some of the other potential causes suggested by the patient's history include COPD or asthma exacerbation, flash pulmonary edema secondary to CHF, or respiratory muscle weakness due to myasthenia gravis. However, pinpoint pupils, decreased mental status, depressed respiratory rate, and recent opiate use suggest narcotic overdose.
-
- **How is the diagnosis approached?** The first step should be pulse oximetry and an arterial blood gas analysis. This will differentiate between hypercarbic or hypoxemic respiratory failure. Supplemental oxygen should also be administered. If this improves oxygenation, the pathology is due to ventilation/perfusion (V/Q) mismatch. If oxygenation does not improve, suspect a physiologic shunt.
-
- **How is the A-a gradient calculated, and what is its significance?** The A-a gradient is the difference between alveolar (PAO₂) and arterial (PaO₂) oxygenation. It is calculated as:
- $$[(P_{ATM} - 47) \times F_{IO_2}] - (P_{aCO_2} / 0.8) - PaO_2$$
- A normal A-a gradient is 5–10 mm Hg. An increased gradient indicates a problem getting alveolar oxygen into the bloodstream. Hypoventilation alone produces mild hypoxemia with a normal A-a gradient.
-
- **What conditions should be included in the differential diagnosis?** The differential diagnosis for acute respiratory failure is very broad and can be divided into two categories: hypercarbic and hypoxemic. Hypercarbia is caused by decreased ventilation due to loss of central drive (secondary to toxins or brain stem injury) or respiratory muscle failure (due to neuromuscular disease such as myasthenia gravis, Guillain-Barré syndrome, or botulism). Hypoxemic respiratory failure is most commonly caused by V/Q mismatch or shunt. Hypoxemia that corrects with oxygen therapy is due to V/Q mismatch, often due to intrinsic lung disease such as COPD, asthma, interstitial lung disease, or a pulmonary embolus. Hypoxemia due to shunt physiology can be the result of a true vascular or intracardiac shunt; severe alveolar filling as seen in ARDS, pneumonia, pulmonary edema, or hemothorax can also result in hypoxemia.
-

- **What is the most appropriate treatment for this condition?**

The underlying disease process must be addressed; in this case, naloxone will reverse the effects of the opiates on central hypoventilation. Patients may require intubation and mechanical ventilation to rapidly correct hypoventilation while the effects of the opiates wear off. Oxygenation can be improved by increasing F_{iO_2} and adding positive end-expiratory pressure in a mechanically ventilated patient. Hypercarbia is corrected by increasing the minute ventilation (by increasing respiratory rate and/or tidal volume in a mechanically ventilated patient).

► **CASE 3**

A 16-year-old boy presents to his pediatrician complaining of worsening cough, shortness of breath, and wheezing. Until a few months ago, he would have these symptoms only while exercising during the winter; lately, he has had to sit out during gym class three times a week. He has also awakened from sleep unable to catch his breath four times in the past month. He is asymptomatic at present. On physical examination, he is afebrile, with a heart rate of 80/min, respiratory rate of 12/min, and blood pressure of 120/80 mm Hg. His cardiovascular examination reveals a regular rate and rhythm with a normal S1 and S2 and no extra heart sounds. His chest is clear to auscultation, without wheezes, crackles, or rhonchi. In the office, his peak expiratory flow reading (PEF) is within normal limits.

-
- **What is the most likely diagnosis?** Asthma, which is a lung disease characterized by the presence of reversible airway obstruction, airway inflammation, smooth muscle hypertrophy, and bronchial hyperreactivity. The diagnosis is suggested by the classic triad of episodic cough, shortness of breath, and wheezing with a return to baseline normal lung function between exacerbations. While each symptom alone could be caused by a number of conditions, the positive predictive value increases as the number of symptoms increases. This patient's case would be classified as mild persistent due to his symptom frequency (see Table 15-1).
-
- **What tests and/or imaging tools could be used to confirm the diagnosis?** Because the patient is currently asymptomatic, the diagnosis should be confirmed with either serial peak flow measurements or bronchoprovocative testing. In asthmatic patients, PEF will decrease > 20% from baseline during symptoms. In a positive bronchoprovocative test, the inhalation of methylcholine induces bronchoconstriction and a decrease in the forced expiratory volume in 1 second (FEV₁); this effect is reversible with albuterol (a short-acting β-agonist). A chest x-ray should be performed to rule out other causes of airway obstruction. An eosinophil count and immunoglobulin E level may help provide evidence of other allergic, atopic, or vascular disease.
-
- **How is this condition classified?** See Table 15-1.
-
- **What is the most appropriate treatment for this condition?** Avoidance of triggers (pets, dust, perfumes, cold) is an important part of management; see also Table 15-1 for recommended pharmacologic management. Remember that patients with asthma more severe than the mild intermittent form should be on inhaled corticosteroids. The major medications used in asthma exacerbations can be remembered as summarized by the mnemonic **ASTHMA**:
Albuterol (for short-term rescue).
Steroids (inhaled or systemic in severe cases).
Theophylline (narrow therapeutic window).
Humidified oxygen (in acute exacerbations).
Mg (acute exacerbation) and Mast cell stabilizers (cromolyn sodium and nedocromil).
Anticholinergics (acute exacerbation) and Antileukotrienes (zileuton, montelukast, and zafirlukast in chronic therapy).
-

TABLE 15-1. Classification, Diagnosis, and Management of Asthma

CLASSIFICATION	DAYTIME SYMPTOMS	NIGHTTIME SYMPTOMS	PULMONARY FUNCTION TESTS	MANAGEMENT STRATEGY
Mild intermittent (Step 1)	≤ 2 times/week	≤ 2 times/month	FEV ₁ or PEF ≥ 80% of predicted; PEF variability ≤ 20%.	Short-acting bronchodilators only as needed.
Mild persistent (Step 2)	2–6 times/week	> 2 times/month	FEV ₁ or PEF ≥ 80% of predicted; PEF variability 20–30%.	Step 1 medications plus daily low-dose inhaled steroids (or mast cell stabilizer).
Moderate persistent (Step 3)	Daily	1 time/week	FEV ₁ or PEF 60–80% of predicted; PEF variability ≥ 30%.	Step 2 medications plus long-acting bronchodilators and antileukotriene trial.
Severe (Step 4)	Continuous	Frequent	FEV ₁ or PEF ≤ 60% of predicted; PEF variability ≥ 30%.	Step 3 medications plus high-dose inhaled steroids, systemic steroids, and other therapies.

► **CASE 4**

A 40-year-old woman presents to her physician complaining of a cough, headache, low-grade fevers, nausea, loose stools, and malaise for the past 2 weeks. Physical examination reveals a temperature of 38.0° C (100.4° F), heart rate of 90/min, and respiratory rate of 15/min. Chest examination reveals faint diffuse rales and wheezes in bilateral lung fields. X-ray of the chest shows bilateral interstitial infiltrates. Her CBC does not reveal any leukocytosis or other abnormality.

-
- **What is the most likely diagnosis?** Community-acquired pneumonia, likely an atypical pneumonia. The triad of indolent onset, extrapulmonary manifestations, and lack of leukocytosis suggests pneumonia caused by an atypical bacterial pathogen. The three most common bacterial pathogens causing atypical pneumonia are *Mycoplasma pneumoniae*, *Chlamydia pneumoniae*, and *Legionella pneumophila*. Viral causes of pneumonia, including influenza and respiratory syncytial virus (RSV), can also present in this fashion. The clinical history of this patient suggests *Mycoplasma* (which is the most common), but clinical presentation is neither sensitive nor specific.
-
- **What tests could be used to confirm the diagnosis?** Tests for the three common causes of bacterial atypical pneumonia should be performed as follows:
- *Mycoplasma*: While a cold agglutinin test is often taught, the recommended test is an immunoglobulin M (IgM) titer, PCR, or antigen detection, if available.
 - *Chlamydia*: Tests include serology, antigen detection, or PCR.
 - *Legionella*: The urine antigen test is the best method, although attempting a culture is also recommended.
-
- **What are some clinical clues to help make the diagnosis?** As stated above, it can be very difficult to differentiate between the three causes of atypical pneumonia clinically. However, some cases will present with classic signs suggesting a particular diagnosis. For example, *Mycoplasma* can be associated with hemolysis, skin rashes, and arthralgias. *Legionella* can have a gastrointestinal component, cause high fevers (> 39.0° C [102.2° F]), and can be associated with laboratory abnormalities such as hyponatremia, liver and kidney dysfunction, and bradycardia in elderly patients.
-
- **What are the typical radiologic findings in this condition?** While atypical pneumonia can present with a lobar consolidation similar to other forms of bacterial community acquired pneumonia, other patterns of infiltration are more frequently seen. In *Mycoplasma*, the most common pattern is peribronchial pneumonia, with streaks of infiltration and platelike atelectasis. The most common finding in *Legionella* is a patchy unilobar infiltrate, but interstitial infiltrates or pulmonary nodules can be seen. *Chlamydia* has no specific pattern, and often presents as a unilateral infiltrate. Pleural effusions can be seen in all types.
-
- **What is the most appropriate treatment for this condition?** Antibiotic coverage against all three atypical pathogens should be started empirically. Macrolides, such as azithromycin, are the first-line therapy. While fluoroquinolones are also effective, resistance is increasing, and they should not be used in pregnant patients or children.
-

► **CASE 5**

A 75-year-old man presents to his primary care physician complaining of decreased exercise tolerance and shortness of breath. He has a 50-pack-year history of smoking cigarettes. On physical examination, he has a barrel-shaped chest, a heart rate of 75/min, and a respiratory rate of 20/min. Cardiac examination is normal with no jugular venous distention. Chest examination reveals diminished breath sounds bilaterally with faint expiratory wheezing. He has an oxygen saturation of 93% by pulse oximetry and an arterial blood gas analysis that reveals pH 7.37, PCO_2 58 mm Hg, PO_2 65 mm Hg, and HCO_3^- 35 mEq/L. An x-ray film of the chest reveals hyperinflation and subpleural blebs. Results of pulmonary function tests (PFTs) are as follows:

Forced expiratory volume in 1 second (FEV_1) 1.50 L (65% of predicted)

FEV_1 /forced vital capacity (FVC) 60% predicted

Diffusion capacity (DL_{CO}) 14 mL/min/mm Hg (65% predicted)

-
- | | |
|---|---|
| <p>■ What is the most likely diagnosis?</p> | <p>Chronic obstructive pulmonary disease (COPD), most likely emphysema. COPD is a group of disorders that feature progressive, nonreversible airflow limitation. COPD is often thought of as either emphysema or chronic bronchitis, although clinical overlap is common. Emphysema is characterized by destruction of the normal alveoli-capillary structures and enlargement of the airspaces, while chronic bronchitis is clinically defined as 3 consecutive months of chronic productive cough twice within a 2-year period. Suggestive clinical features of COPD include dyspnea, barrel chest, diminished breath sounds, wheezing, and prolonged expiratory phase. Hypoxemia and/or hypercapnia with a chronic respiratory acidosis may be present. PFTs will demonstrate a decreased FEV_1/FVC ratio (< 70%) and FEV_1, indicating airway obstruction. The DL_{CO} is usually decreased in emphysema. The chest x-ray often reveals hyperinflation (with flattened diaphragms), bullae, and subpleural blebs.</p> |
| <p>■ What risk factors are associated with an increased incidence of this condition?</p> | <p>Smoking is by far the most important risk factor for COPD. The emphysema caused by smoke exposure is typically centriacinar and located in the upper lobes. Bibasilar panacinar emphysema, especially in a younger patient or in combination with cirrhosis, may be a clue to α_1-antitrypsin deficiency.</p> |
| <p>■ What is the medical management of this condition?</p> | <ul style="list-style-type: none"> ■ Smoking cessation (the most important intervention). ■ Inhaled bronchodilator (e.g., albuterol) combined with anticholinergic agent (e.g., ipratropium or tiotropium). ■ Inhaled corticosteroids (useful in some patients), with systemic steroids for acute exacerbations. ■ Influenza vaccination. ■ Pneumococcal vaccination. ■ Theophylline (useful in some patients). <p>Noninvasive positive pressure ventilation (i.e., bilevel positive airway pressure [BiPAP]) can be used for acute exacerbations of COPD with hypercarbia.</p> |
| <p>■ What are some nonpharmacologic interventions for this patient?</p> | <p>Many COPD patients learn “pursed lip” breathing techniques, and pulmonary rehabilitation has been shown to improve quality of life. Still, continuous oxygen therapy and smoking cessation are the only treatments that clearly improve mortality in COPD. Surgical options include lung volume reduction and lung transplantation in appropriate patients.</p> |
-

► **CASE 6**

A 35-year-old man presents to his primary care physician with shortness of breath, which has been worsening over the past few months. Always fairly active, he was unable to play tennis this past weekend. He notes a mild cough but denies chest pain with exertion, fevers, chills, or night sweats. He has no known sick contacts and has not traveled anywhere recently. He smoked for a few years in his 20s but does not currently smoke, has never used illicit drugs, and drinks alcohol socially. He has no significant past medical history except persistently elevated transaminases of unknown etiology. On physical examination, vital signs are within normal limits. The chest wall is tympanitic, and breath sounds are decreased in both bases. Basic labs and pulmonary function tests (PFTs) are as follows:

CBC: WBC 8000/mm³, hemoglobin (hematocrit) 14 g/dL (42%), platelets 330,000/mm³

LFTs: Aspartate transaminase (AST) 75 U/L, alanine transaminase (ALT) 92 U/L, alkaline phosphatase 200 U/L

PFTs: Forced expiratory volume in 1 second (FEV₁) 1.9 L (60% predicted), FEV₁/forced vital capacity (FVC) 58% predicted, total lung capacity (TLC) normal

-
- **What is the most likely diagnosis?** Emphysema. The patient's PFTs, demonstrating decreased FEV₁ and FEV₁/FVC with a normal TLC, are most consistent with an obstructive process such as chronic obstructive pulmonary disease (COPD) or asthma. In contrast, a restrictive process would have a decreased TLC with a normal or increased FEV₁/FVC. Combined with the physical exam and imaging findings, emphysema is the most likely diagnosis.
-
- **What is the most likely etiology and pathophysiology of this condition?** Emphysema in a patient under 45 years old, especially one with a minimal smoking history, is very concerning for α_1 -antitrypsin (AAT) deficiency. The persistently elevated transaminase levels, indicating chronic hepatocyte destruction, are often the earliest sign of the disease. Liver damage, beginning as early as infancy, is secondary to the abnormal polymerization of the AAT protein inside the hepatocyte, and this can result in cirrhosis. AAT is a protease that degrades the elastases produced by neutrophil activity; it can be normal, deficient, absent, or dysfunctional, depending on the patient's alleles. The most severe genotype is PiZZ, homozygous for deficient AAT deficiency. The lack of functional AAT leaves the lung parenchyma susceptible to degradation, which can ultimately produce severe emphysema. The emphysema in AAT deficiency is panacinar and basilar predominant, as opposed to centrilobular or centriacinar (seen in the more common tobacco-related emphysema). Damage from cigarette smoke, which is normally reduced by AAT, is markedly accelerated in patients with AAT deficiency.
-
- **Who should be screened for AAT deficiency?** Any patient with emphysema who is < 45 years of age or a nonsmoker should be screened, as well as neonates with prolonged neonatal jaundice or adults with chronic undefined liver disease. A history of young family members with early emphysema should prompt a screen as well.
-
- **What is the most appropriate treatment for this condition?** Treatment for AAT deficiency is centered around treating the patient's COPD symptoms. Chronic therapy with bronchodilators (β -agonists and anticholinergics) is recommended. Treatment of acute exacerbations is oxygen, β_2 -agonists, anticholinergics, and steroids. As with any COPD patient, smoking cessation and irritant avoidance, as well as vaccination against *S. pneumoniae* and influenza is recommended.
-

► CASE 7

A 50-year-old woman presents for preoperative testing before elective cholecystectomy. Her medical history is significant for biliary colic, a 40-pack-year smoking history, and chronic bronchitis. She is afebrile with a respiratory rate of 12/min. A chest examination is notable for diffuse wheezing, but no lymphadenopathy, clubbing, or breast lumps are appreciated on physical exam. X-ray of the chest is remarkable for a 3.0-cm noncalcified nodule with irregular margins in the right middle lobe. An x-ray film taken 1 year ago does not show this lesion. A CT scan of the chest confirms the nodule, which enhances upon intravenous contrast administration. A tuberculin skin test is nonreactive.

-
- | | |
|---|---|
| <p>■ What is the most likely diagnosis?</p> | <p>Solitary lung nodule, suspicious for lung cancer. The features of this nodule suggesting malignancy include a size > 2 cm, absence of calcification, irregular margins, and appearance within 1 year. In addition, a nodule in a patient > 45 years of age with a significant smoking history and chronic obstructive pulmonary disease must be evaluated for cancer.</p> |
| <p>■ What conditions should be included in the differential diagnosis?</p> | <ul style="list-style-type: none"> ■ Benign causes: <ul style="list-style-type: none"> ■ Arteriovenous malformations. ■ Hamartomas. ■ Infectious granulomas (tuberculosis and fungal disease). ■ Lung abscesses. ■ Malignant causes: <ul style="list-style-type: none"> ■ Bronchial carcinoid tumors. ■ Bronchogenic carcinoma (the most common). ■ Lymphomas. ■ Metastases from other primary cancers (colorectal, breast, renal cell, or melanoma). |
| <p>■ What is the next step in workup for this patient?</p> | <p>A biopsy must be performed for definitive tissue diagnosis. If the nodule is malignant, complete staging must include a complete blood count and liver function panels. Positron emission tomography (PET) scanning is increasingly used. Bone scans and head imaging are indicated for symptomatic patients.</p> |
| <p>■ How is this condition classified?</p> | <p>Lung cancer classification and treatment are divided into small cell lung cancer (SCLC) and non–small cell lung cancer (NSCLC).</p> <ul style="list-style-type: none"> ■ SCLC usually presents as a central lesion and is of neuroendocrine origin. ■ NSCLC is more common and includes squamous cell carcinoma (central location), adenocarcinoma (peripheral location), bronchoalveolar carcinoma (presents with multiple nodules or infiltrate), and large cell carcinoma (rare). |
| <p>■ What are the treatment options for this patient?</p> | <p>SCLC metastasizes earlier and is often diagnosed at a much later stage than NSCLC. It is not amenable to resection. It will often respond to chemotherapy and radiation, but almost always recurs and is associated with a high mortality rate. NSCLC is treated with surgical resection in the setting of localized disease. Adjuvant chemotherapy and radiation may be of benefit with more widespread disease.</p> |
| <p>■ What are some complications of this disease?</p> | <p>In addition to metastases (to brain, liver, bone, and adrenals) or locally invasive disease (bronchial obstruction, Horner’s syndrome), lung cancer can cause paraneoplastic syndromes. SCLC tumors can produce antidiuretic hormone and/or adrenocorticotrophic hormone, and can cause peripheral neuropathy and Lambert-Eaton syndrome. NSCLC causes hypercalcemia and gynecomastia.</p> |
-

► **CASE 8**

A 60-year-old lawyer presents to his primary care physician complaining of worsening shortness of breath and chronic dry cough. His past medical history is significant for well-controlled hypertension. He does not smoke. His temperature is 37.0° C (98.6° F), pulse 80/min, respiratory rate at rest 20/min, and blood pressure 130/80 mm Hg. Chest examination reveals fine, bibasilar “Velcro” crackles without wheezes. Joints are not swollen or tender, although clubbing of the digits is noted. Full hematology, electrolyte, serology, and liver function panels are normal. A CT of the chest is shown below (Figure 15-2). Results of pulmonary function tests (PFTs) are as follows:

Forced expiratory volume in 1 second (FEV₁)/forced vital capacity (FVC) ratio: 90% predicted
Total lung capacity (TLC): 3.8 L (60% predicted)
Diffusion capacity (DL_{CO}): 17.2 mL/min/mm Hg (70% predicted)

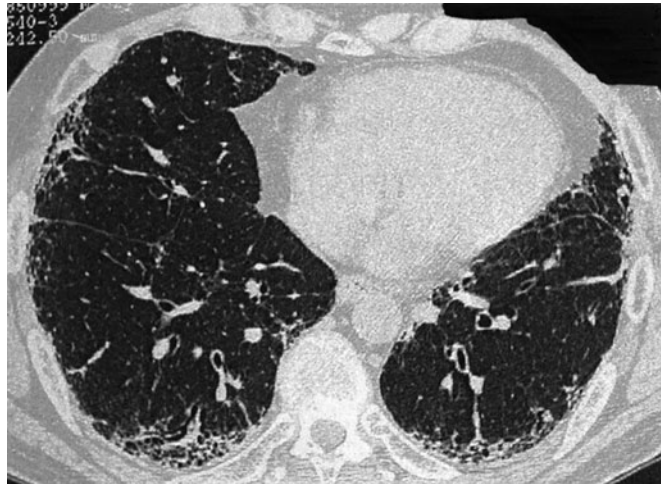


FIGURE 15-2. (Reproduced, with permission, from Kasper DL, Braunwald E, Fauci AS, Hauser SL, Longo DL, Jameson LJ, Isselbacher KJ, eds. *Harrison's Principles of Internal Medicine*, 16th ed. New York: McGraw-Hill, 2005: Fig. 243-1.)

-
- **What is the most likely diagnosis?** Idiopathic pulmonary fibrosis (IPF). PFTs suggest a restrictive process (preserved or increased FEV₁/FVC ratio, low TLC), and the imaging studies are characteristic of a diffuse interstitial lung disease (ILD) with fibrosis and honeycomb change. With no history, physical findings, or laboratory data to suggest an identifiable cause, the most likely diagnosis is IPF. Clubbing and dry cough, while nonspecific, are often seen in IPF.
-
- **What conditions should be included in the differential diagnosis?** ILD can be fibrotic/inflammatory or granulomatous. Fibrotic/inflammatory ILD is divided into four main categories: idiopathic, pneumoconioses, connective tissue diseases, and iatrogenic (secondary to drugs or radiation therapy). Granulomatous disease includes sarcoidosis.
 - The occupational pneumoconioses include asbestosis, silicosis, and coal miner's disease.
 - Connective tissue diseases that can manifest as ILD are rheumatoid arthritis, lupus, Sjögren's disease, and scleroderma.
 - Certain chemotherapeutic agents and amiodarone are the most common causes of drug-induced ILD.
-

<ul style="list-style-type: none"> ■ What are the typical radiological findings in this condition? 	<p>While ILD can be diagnosed from a chest x-ray film, a CT scan is preferred. The high-resolution CT scan in Figure 15-2 shows the typical CT findings of basilar and subpleural reticular fibrosis with honeycombing in severe disease.</p>
<ul style="list-style-type: none"> ■ How is the definitive diagnosis confirmed? 	<p>There are many types of ILD, each with different histopathology, and definitive diagnosis is made after lung biopsy. The histopathology of IPF is usual interstitial pneumonia (UIP), which shows alternating patterns of normal lung, interstitial inflammation, fibrosis, and honeycombing. A probable diagnosis of IPF can be made with a typical clinical history and characteristic high-resolution CT findings, preventing open lung biopsy in many patients.</p>
<ul style="list-style-type: none"> ■ What is the most appropriate treatment for this condition? 	<p>IPF is a progressive disease, with death usually occurring a few years after diagnosis. It does not respond well to available medications, but many patients are started on a trial of corticosteroids and immunomodulatory therapy (azathioprine or cyclophosphamide). Lung transplantation is the only treatment shown to improve survival, though not all patients are eligible.</p>

► **CASE 9**

A 56-year-old construction worker presents with increasing difficulty catching his breath and chest pain. Upon further questioning, he has had chest pain and trouble breathing for months. The pain is right-sided, sharp, worse with deep breathing, and nonradiating. In addition to his presenting symptoms, the patient's wife notes he is increasingly fatigued and has lost 4.6 kg (10 lb) over the last 2 months. The patient denies productive cough or recent infections. He has been in construction for most of his life, working for a company that remodels old buildings. He endorses a 35-pack-year smoking history. On physical examination, he is in mild respiratory distress, and there is dullness to percussion over his right lung base as well as decreased breath sounds. Serum chemistries, complete blood counts, and electrocardiogram are all within normal limits. A chest x-ray demonstrates a pleural-based mass and effusion in the right lower lung.

■ What is the most likely diagnosis, and what exposure contributed to his disease process?	The findings on chest x-ray of a pleural-based mass are most consistent with malignant mesothelioma. The patient's occupation of remodeling old buildings places him at risk for asbestos exposure, which is the primary risk factor for mesothelioma.
■ What is the pathophysiology of this condition?	Asbestos contributes to oncogenesis primarily by chronic irritation of the pleura and by inducing oxygen free radicals, which damage DNA of both pneumocytes and mesothelial cells. The chronic irritation can produce pleural plaques (benign) or mesothelioma. The free radical damage can produce mesothelioma or bronchogenic carcinoma of the lung.
■ What tests and/or imaging tools could be used to confirm the diagnosis?	Cytology from the pleural effusion is diagnostic in many cases. When cytology is inconclusive, tumor biopsy is helpful, especially with immunohistochemistry. MRI is useful for determining the extent of disease, while positron emission tomography (PET) scanning can help distinguish benign pleural plaques from mesothelioma.
■ Is smoking a risk factor that increases the incidence of this condition?	No. However, smoking does increase the risk for bronchogenic adenocarcinoma.
■ What is the most appropriate treatment for this condition?	The median survival for mesothelioma is 12 months after diagnosis, so treatments are primarily palliative. Surgical debulking is an option most commonly used in conjunction with radiation, chemotherapy, or immunotherapy. Recurrent pleural effusions can be treated with pleurodesis—scarring of the pleura to the chest wall to eliminate the potential space filled by pleural fluid. Somatic pain (caused by invasion of the chest wall) can be controlled with opiates and nonsteroidal anti-inflammatory drugs, while neuropathic pain (caused by invasion of intercostal nerves) may require the addition of an anticonvulsant.

► CASE 10

A 50-year-old woman presents to the emergency department complaining of sudden-onset shortness of breath with pain on inspiration. She is 2 weeks status post total knee replacement and has been recovering without complication, although she has not gone to her prescribed physical therapy sessions. Her medications are oxycodone for pain management and hormone replacement therapy. Her temperature is 38.0° C (100.4° F), pulse is 120/min, respiratory rate is 30/min, blood pressure is 110/75 mm Hg, and oxygen saturation is 89% by pulse oximetry. X-ray of the chest is normal. An electrocardiogram shows sinus tachycardia with no other abnormalities.

-
- | | |
|---|--|
| <p>■ What is the most likely diagnosis?</p> | <p>Pulmonary embolus (PE). Clinical signs and symptoms include acute-onset dyspnea, hypoxia, pleuritic chest pain, hemoptysis, low-grade fever, rales, and tachycardia.</p> |
| <p>■ What risk factors are associated with an increased incidence of this condition?</p> | <p>PE is caused by a blood clot from the venous system (deep venous thrombosis, or DVT) that travels to the lungs and obstructs the pulmonary vasculature. Thus, the risk factors are summarized by Virchow's triad:</p> <ul style="list-style-type: none"> ■ Endothelial injury—due to trauma, surgery, or previous DVT. ■ Hypercoagulability—can be due to estrogens, genetic conditions, or malignancy. ■ Stasis—immobility after surgery or due to other causes. |
| <p>■ What tests and/or imaging tools could be used to confirm the diagnosis?</p> | <p>The gold standard for diagnosis is pulmonary angiography. A more common test is the ventilation/perfusion (V/Q) lung scan, a nuclear medicine study used to identify V/Q mismatch. Spiral CT scans with contrast are by far the most common imaging study because of their ease of acquisition and ability to see other lung pathology. Lower extremity Doppler ultrasounds may identify the source of clot. Serum D-dimer levels are a sensitive but nonspecific marker of fibrinolytic activity and are primarily used to rule out DVT/PE in low-risk patients. Arterial blood gas analysis may show hypoxemia and/or respiratory alkalosis. The most common findings on electrocardiogram are sinus tachycardia or nonspecific ST-segment and T-wave changes. The classic S1Q3T3 (indicative of right heart strain) is worth knowing but is rarely seen.</p> |
| <p>■ What is the strategy for making the diagnosis?</p> | <p>It is important to identify and rapidly treat patients with PE, while assuring that those without PE are not subjected to unnecessary treatment. None of the noninvasive tests named above are sensitive and specific enough to be used alone. Before the results of an imaging test (V/Q or CT scan) are interpreted, the clinician must decide on the patient's pretest probability of having PE. Only with this information can the diagnosis be safely made, discarded, or deferred while other tests (D-dimer, ultrasound, angiography) are performed.</p> |
| <p>■ What is the most appropriate treatment for this condition?</p> | <p>Long-term anticoagulation is the cornerstone of PE treatment. If no contraindications exist, it should be started in patients with high-pretest probability (such as this one) before further testing is done. Inferior vena cava filters can be placed in patients with contraindications to or failures of anticoagulant therapy. Fibrinolytic therapy is generally reserved for patients who are significantly hemodynamically compromised.</p> |
-

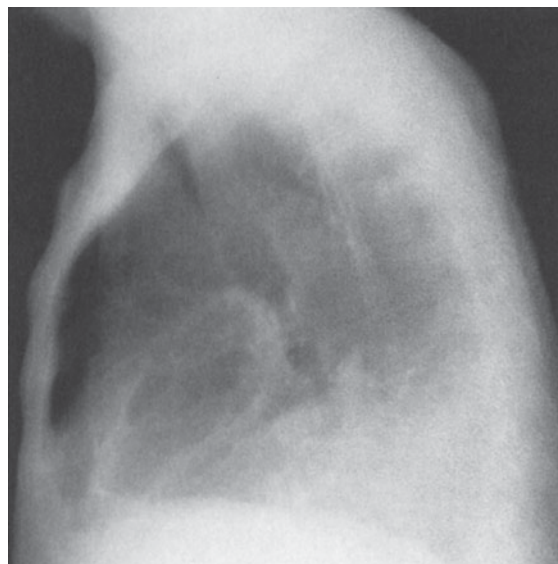
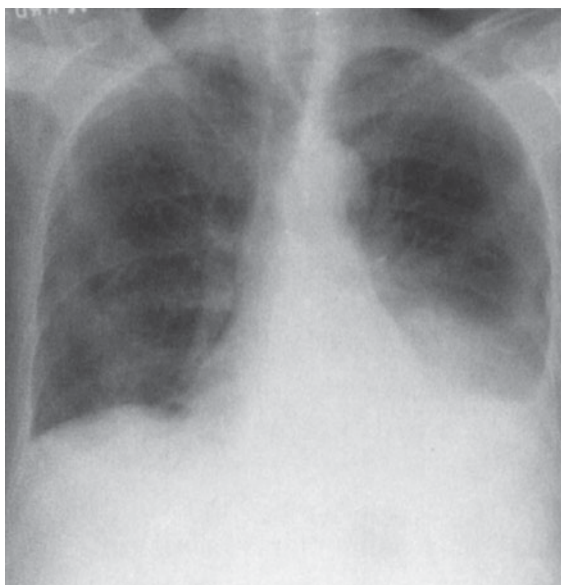
► **CASE 11**

A 75-year-old woman presents to the emergency department complaining of shortness of breath at rest. She has a history of non-small cell lung cancer treated 1 month ago with partial left lung resection. Her temperature is 38.0° C (100.4° F), pulse is 100/min, respiratory rate is 25/min, and blood pressure is 135/80 mm Hg. She is in mild respiratory distress, and chest examination reveals absent breath sounds and dullness to percussion at the base of the left lung field. Upright and lateral decubitus radiographs of the chest are shown in Figure 15-3. A left-sided thoracentesis yields 1 L of nonbloody, turbid fluid. The fluid is tested, and results are as follows:

Protein: 4.0 g/dL
Lactate dehydrogenase (LDH): 230 U/L
pH: 7.25
Glucose: 35 mg/dL
Hemoglobin: 2 g/dL
Triglycerides: 50 mg/dL
Cytology: negative for malignant cells
Gram stain: negative for bacteria
Cell count: 1500 WBC, 65% lymphocytes

Relevant laboratory test (in serum) are as follows:

Protein: 7.0 g/dL
LDH: 250 U/L
Glucose: 90 mg/dL
Hemoglobin: 12 g/dL
Triglycerides: 100 mg/dL



A

B

FIGURE 15-3. (Reproduced, with permission, from Chen MYM, Pope TL, Ott DJ. *Basic Radiology*. New York: McGraw-Hill, 2004: Fig. 4-52.)

-
- | | |
|--|---|
| <ul style="list-style-type: none">■ What is the most likely diagnosis? | <p>Exudative pleural effusion, likely secondary to malignancy. The diagnosis of pleural effusion is suggested by dullness to percussion or absent breath sounds plus radiographic findings (blunted costophrenic angle, asymmetric opacity at the base that moves with change in position, as seen in Figure 15-3) and confirmed with thoracentesis. Possible etiologies for the exudative effusion include malignancy, chylothorax, pulmonary embolus (PE), or parapneumonic effusion. Malignancy is most likely, as suggested by history, presence of an exudate, low glucose, and low pH. Cytology has a sensitivity of 65% and a specificity of 97% for malignancy.</p> |
| <ul style="list-style-type: none">■ How is this condition categorized? | <p>Pleural effusions are categorized as either transudative or exudative. An effusion is classified as an exudate if one or more of Light's criteria are positive:</p> <ul style="list-style-type: none">■ Pleural fluid protein/serum protein ratio > 0.5.■ Pleural fluid LDH/serum LDH ratio > 0.6.■ Pleural fluid LDH > two-thirds the upper limit of normal serum LDH. |
| <ul style="list-style-type: none">■ What conditions should be included in the differential diagnosis? | <p>Transudative effusions are due to elevated hydrostatic or decreased oncotic pressure; they can be caused by congestive heart failure (90%), cirrhosis, or nephrotic syndrome. Exudative effusions are due to pleural pathology and leaky capillaries. They are most commonly the result of malignancy, pneumonia, PE, tuberculosis, rheumatoid arthritis, lupus, pancreatitis, esophageal rupture, and post coronary artery bypass surgery. In addition to the effusions listed above, fluid in the pleural cavity can also be blood, pus, or chyle, causing the following:</p> <ul style="list-style-type: none">■ A hemothorax is usually grossly bloody, with a fluid hematocrit level at least 50% of serum levels.■ An empyema is pus in the pleural space. The pleural fluid is characterized by a low pH, low glucose, and bacteria seen on Gram stain.■ A chylothorax is most often iatrogenic and caused by transection of the thoracic duct. The pleural fluid will be milky with a high triglyceride count. |
-

► **CASE 12**

A 25-year-old man is brought to the emergency department following a stab wound to the right back. He complains of difficulty breathing and severe pain on his right side. His vital signs on arriving are a blood pressure of 140/80 mm Hg, heart rate of 100/min, and respiratory rate of 25/min with oxygen saturation of 90% by pulse oximetry. While undergoing an x-ray of the chest, he becomes agitated and develops severe respiratory distress. Vital signs are now blood pressure of 80/60 mm Hg, heart rate of 125/min, respiratory rate of 40/min, and oxygen saturation of 75% by pulse oximetry. Chest examination reveals an absence of breath sounds and hyperresonance over the right lung field. Neck examination reveals distended neck veins and leftward tracheal deviation.

- **What is the most likely diagnosis?** Tension pneumothorax. A tension pneumothorax is a medical emergency that should be suspected in any patient presenting with penetrating or blunt chest trauma. The signs and symptoms of a pneumothorax include unilateral pleural pain, dyspnea, sudden onset, decreased or absent breath sounds, hyperresonance, and hyperlucency seen on chest x-ray. Remember the mnemonic **P-THORAX**:

Pleuritic pain
Tracheal deviation
Hyperresonance
Onset sudden
Reduced breath sounds (and dyspnea)
Absent fremitus
X-ray shows collapse

The presence of hemodynamic instability, tracheal deviation, and distended neck veins indicate tension pneumothorax.

 - **What is the pathophysiology of this condition?** In a tension pneumothorax, the chest wall or visceral defect is an effective one-way valve, allowing air to accumulate within the pleural space that cannot be expelled. Pressure within the hemithorax deviates the trachea and compresses the mediastinum, which produces hypotension by compromising venous return.

 - **What are the etiologies of this condition?** A pneumothorax can be spontaneous, traumatic, or iatrogenic in origin.
 - Primary spontaneous pneumothoraces occur in patients with no underlying lung disease. It is most often seen in young, tall, thin males.
 - Secondary spontaneous pneumothorax is seen in patients with lung disease, usually chronic obstructive pulmonary disease (COPD), cystic fibrosis, *Pneumocystis jiroveci* pneumonia, or tuberculosis.
 - Traumatic pneumothorax can follow blunt or penetrating trauma.
 - Iatrogenic pneumothorax is the most common type, where lung is injured following central venous line placement, positive pressure mechanical ventilation, or thoracentesis.

 - **What are the typical radiographic findings in this condition?** A chest x-ray would reveal hyperlucency, absence of lung markings at the periphery, and a pleural line (see Figure 15-4). A tension pneumothorax is suggested by hyperexpansion of the ipsilateral hemithorax with mediastinal shift and tracheal deviation toward the contralateral side.
-

- What is the most appropriate treatment for this condition?

Tension pneumothorax is life threatening and is treated by inserting a large-bore needle in the second intercostal space in the midclavicular line. A rush of air will be appreciated and confirms the diagnosis. After hemodynamic stabilization, a chest tube should be placed. Small, spontaneous pneumothoraces can be managed with observation and oxygen therapy alone, while larger ones require evacuation with a catheter or chest tube.

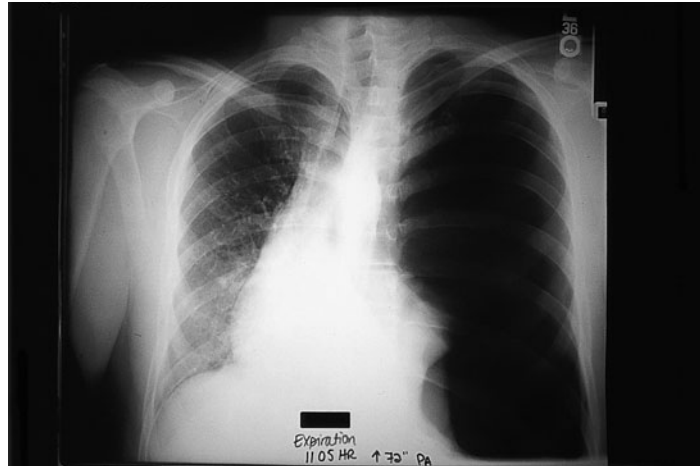


FIGURE 15-4. (Reproduced, with permission, from Le T, Bhushan V, Dierberg K, Grow RW. *First Aid for the USMLE Step 2 CK*, 5th ed. New York: McGraw-Hill, 2006: Fig. 2.15-6.)

► **CASE 13**

A 37-year-old woman with no significant past medical history presents to her primary care physician complaining of dyspnea on exertion accompanied by mild chest pain. She recently fainted after walking up a flight of stairs. She is afebrile, with a heart rate of 90/min, respiratory rate of 12/min, blood pressure of 90/70 mm Hg, and oxygen saturation of 89% by pulse oximetry on room air. Cardiac examination is notable for a loud pulmonic component to the second heart sound and a systolic murmur best appreciated at the lower sternal border. Distended neck veins, hepatomegaly, and lower extremity edema are appreciated. Skin and musculoskeletal examinations are normal. X-ray of the chest reveals normal lung fields with cardiomegaly and enlarged pulmonary vessels. Pulmonary function tests (PFTs) reveal a diffusion capacity of 50%.

- **What is the most likely diagnosis?** Idiopathic pulmonary arterial hypertension (PAH). As seen in this patient, PAH often goes undiagnosed until the disease is severe and the patient presents with symptoms of right heart failure. These signs include a tricuspid murmur, distended neck veins, hepatomegaly, and edema. Systemic blood pressure is often low due to decreased cardiac output. Common symptoms are dyspnea on exertion, chest pain, and syncope. In idiopathic PAH, an isolated decreased diffusion capacity is the most common abnormality on PFTs.

 - **What are some etiologies of this condition?** While some cases of PAH are idiopathic, secondary PAH is more common. Secondary causes include left heart disease (mitral valve disease, left ventricular dysfunction), connective tissue disease (lupus, scleroderma, and rheumatoid arthritis), parenchymal lung disease with chronic hypoxemia (emphysema, idiopathic pulmonary fibrosis, and cystic fibrosis), and chronic thromboembolic disease. It is also seen in patients with HIV, chronic liver disease, and obstructive sleep apnea. There is an association with amphetamines, diet pills, and intravenous drug use. It is estimated that 5–15% of idiopathic PAH is familial, and the gene *BMPR2* has been associated with the familial form.

 - **What tests could be used to confirm the diagnosis?** A treatable underlying disease should be investigated with liver function tests, HIV and autoimmune serologies, and a sleep study. PFTs and imaging to look for pulmonary thromboembolic disease are also performed. In cor pulmonale, the electrocardiogram may show right axis deviation and signs of right ventricular hypertrophy, while an echocardiogram will show enlargement of the right ventricle and tricuspid regurgitation with elevated pulmonary artery systolic pressures.

 - **How is the definitive diagnosis made?** A right-heart catheterization can determine pulmonary artery pressures and exclude the presence of pulmonary venous hypertension. PAH is defined as a pulmonary artery pressure of > 25 mm Hg at rest and > 30 mm Hg with exercise. A vasodilator trial during the procedure may help guide therapy.

 - **What is the most appropriate treatment for this condition?** The first step in management is to treat any underlying disease process. Unless contraindicated, PAH patients should be anticoagulated to minimize the risk of in situ thrombosis. Supplemental oxygen should be used to keep saturation levels > 90%, and right heart failure should be treated with diuretics. Acute responders to a vasodilator trial may be treated with calcium channel blockers. Symptomatic nonresponders may be treated with diuretics, endothelin receptor antagonists (e.g., bosentan), or prostacyclin analogues (e.g., treprostinil or epoprostenol). Lung transplantation may be indicated.
-

► **CASE 14**

A 29-year-old African-American woman presents to her primary care physician with a 6-month history of dyspnea on exertion, chronic dry cough, mild chest pain, malaise, and fatigue. Her temperature is 38.0° C (100.4° F), heart rate is 80/min, and respiratory rate is 20/min. Chest examination is notable for faint wheezes only. On eye examination, bilateral erythema at the scleral-corneal border is noted. Laboratory results are notable for a hemoglobin of 13 g/dL, a serum calcium of 12 mg/dL, and an elevated serum angiotensin-converting enzyme (ACE). Erythrocyte sedimentation rate (ESR) is elevated at 80 mm/hr. Results of pulmonary function tests (PFTs) are as follows:

Forced expiratory volume in 1 second (FEV₁/forced vital capacity (FVC) ratio: 80%

Total lung capacity (TLC): 3.7 L (70% predicted)

Diffusion capacity (DL_{CO}): 19.5 mL/min/mm Hg (75% predicted)

A lung biopsy is done, and the pathology is reported as “noncaseating granulomas.”

-
- | | |
|--|--|
| ■ What is the most likely diagnosis? | Sarcoidosis, a systemic disease marked by the presence of noncaseating granulomas in multiple organs. Ninety percent of cases have pulmonary symptoms, such as dyspnea and dry cough, and either an obstructive or restrictive pattern of PFTs. Primary features can be summarized with the mnemonic GRUELING :

G : granulomas (noncaseating)
R : rheumatoid-factor positivity, arthritis
U : uveitis (usually anterior)
E : erythema nodosum
L : lymphadenopathy and liver involvement
I : interstitial fibrosis
N : nervous system involvement and negative TB test
G : gammaglobulinemia |
| ■ What conditions should be included in the differential diagnosis? | Sarcoidosis causes interstitial lung disease (ILD) with a granulomatous pattern. The differential diagnosis of granulomatous ILD includes hypersensitivity pneumonitis and infectious causes such as tuberculosis, nontuberculous mycobacteria, and histoplasmosis. Berylliosis has a very similar clinical presentation to sarcoidosis. |
| ■ What is the epidemiology of this condition? | Sarcoidosis is more often seen in female patients aged 20–40 years, with a fourfold increase in incidence seen in the African-American population in the United States. |
| ■ What is the cause of the hypercalcemia seen in this condition? | Hypercalcemia is common in these patients, due to extrarenal calcitriol produced by activated macrophages in granulomas. Other common laboratory abnormalities include elevated erythrocyte sedimentation rate, alkaline phosphatase, angiotensin converting enzyme, and γ -globulin levels, as well as a positive rheumatoid factor and eosinophilia. |
| ■ What are the typical radiologic findings in this condition? | X-ray of the chest classically shows hilar adenopathy and interstitial infiltrates. There are four stages of sarcoidosis as characterized by chest x-ray. |
| ■ What is the most appropriate treatment for this condition? | Many cases of sarcoidosis spontaneously remit, though patients presenting at an advanced stage are more likely to have progressive disease. Extrapulmonary disease requires treatment, with corticosteroids used as the first-line therapy. Patients who do not respond to corticosteroids may be treated with other immunomodulators, including cyclophosphamide, mycophenolate mofetil, azathioprine, and methotrexate. |
-

► **CASE 15**

A 35-year-old man is sent to the emergency department by a homeless shelter caseworker after he is seen coughing up blood. He has been living on the streets for the past 6 months following his release from a 3-year incarceration. He complains of night sweats and fevers. On physical examination, his temperature is 38.5° C (101.3° F) with a heart rate of 90/min, a respiratory rate of 15/min, and a blood pressure of 120/80 mm Hg. His physical exam is notable for cachexia. Both lung fields are clear to auscultation. His chest x-ray film is shown in Figure 15-5, and two of three sputum samples are positive for acid-fast bacilli.

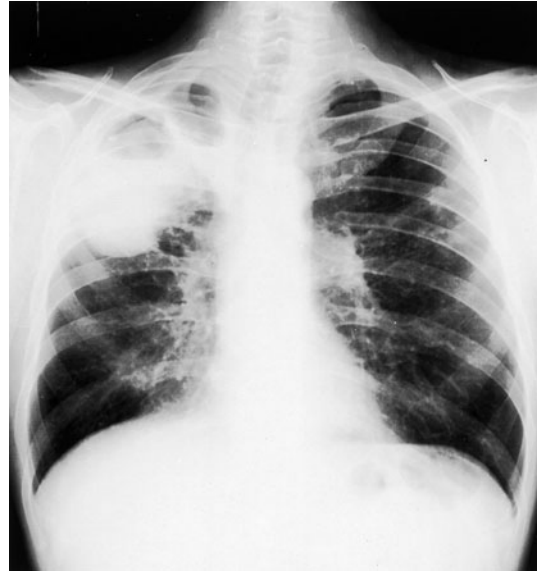

FIGURE 15-5. (Reproduced, with permission, from Doherty GM, Way LW. *Current Surgical Diagnosis and Treatment*, 12th ed. New York: McGraw-Hill, 2006: Fig. 18-19.)

-
- **What is the most likely diagnosis?** Reactivated tuberculosis (TB). This patient has two important risk factors for TB: homelessness and incarceration. The presentation of active TB includes night sweats, fevers, hemoptysis, and weight loss. Figure 15-5 shows cavitary tuberculosis of the right upper lobe. The presence of *Mycobacterium tuberculosis* on a sputum sample confirms the diagnosis.
-
- **What is the pathogenesis of this condition?** TB is spread via airborne particles from a person with active disease, usually after repeated exposure. In most patients, primary infection is subclinical and results in an asymptomatic latency period that reactivates in 10–20% of patients. Most often seen in immunocompromised patients, reactivated TB can manifest as infiltrates, consolidation, and/or cavitation frequently found in the upper lobes.
-

<ul style="list-style-type: none"> ■ How are asymptomatic cases detected? 	<p>The purified protein derivative (PPD), or tuberculin skin test, is used to screen for latent TB in patients with risk factors or in occupations with a high risk of exposure to TB. The PPD is considered positive at different diameters of induration depending on the clinical history of the patient:</p> <ul style="list-style-type: none"> ■ At 5 mm—history of HIV disease or other immunosuppression, contact with a known TB case, or with radiographic findings suggestive of TB. ■ At 10 mm—history of recent immigration from a high-prevalence country, residents or employees of high-risk settings (nursing homes or jails), or patients with certain medical illnesses. ■ At 15 mm—no identifiable risk factors.
<ul style="list-style-type: none"> ■ What is the most appropriate treatment for this condition? 	<p>The treatment of active TB requires 6 months of therapy with drugs to which the isolate is susceptible. The mnemonic STRIFE outlines the drugs used in treating TB:</p> <p>STreptomycin (the first successful anti-TB drug, currently not first-line therapy) Rifampin Isoniazid Pyrazinamide Ethambutol</p> <p>Directly observed therapy (DOT) is the most effective way to reduce emergence of resistance. Latent TB should be treated with 9 months of isoniazid. Rifampin resistance occurs rapidly, so it is never used alone.</p>
<ul style="list-style-type: none"> ■ What adverse events are associated with treatment? 	<p>Isoniazid upregulates cyp2E1 (the enzyme metabolizing acetaminophen to NADPQI, which is hepatotoxic) and is associated with age-related hepatotoxicity and peripheral neuropathy (which can be prevented with pyridoxine). Rifampin can interact with hepatic clearance of other drugs and is excreted as a red compound in urine and tears. The major toxicity of ethambutol is optic neuritis.</p>

► **CASE 16**

A 44-year-old man presents to the emergency department after coughing up blood intermittently for the last several days. He notes one prior episode of hemoptysis several months ago that resolved on its own. He generally dislikes going to the doctor because he has chronic sinusitis with intermittent bloody discharge, which never gets better “no matter what they try.” He denies any other medical conditions but notes that he has felt fatigued over the last year. He has never smoked, has never been incarcerated, and has never traveled outside the United States. He reports subjective fevers and night sweats but has no sick contacts. On physical examination, his temperature is 38.2° C (100.8° F), pulse is 95/min, blood pressure is 135/80 mm Hg, respiratory rate is 18/min, and oxygen saturation is 95% on room air. Rhonchi are heard in the upper left lung field. Urine histoplasma antigen was negative, as was a sputum stain for acid-fast bacilli. A CT scan of the head revealed patchy mucosal and periosteal thickening without fluid levels. A CT scan of the head revealed multiple nodules, some with cavitation as well as ground-glass infiltrates.

■ What conditions should be included in the differential diagnosis?	Causes of hemoptysis include cancer, infection, and vasculitis. This patient’s age and lack of smoking history make lung cancer less likely, and he has no significant risk factors for TB (incarceration, immunosuppression, or travel to a developing country).
■ What is the most likely diagnosis?	Wegener’s granulomatosis. Chronic sinusitis in combination with hemoptysis and his history makes Wegener’s granulomatosis the most likely cause of his symptoms.
■ What organ system involvement characterizes this condition?	Wegener’s is a small- and medium-sized blood vessel vasculitis characterized by a triad of upper airway involvement (sinusitis, otitis, oral/nasal ulcers, bloody nasal discharge), lower airway involvement (dyspnea, cough, hemoptysis), and renal involvement (glomerulonephritis). While only 20% of patients have renal involvement at presentation, it will develop in almost 80%.
■ What tests and/or imaging tools could be used to confirm the diagnosis?	A CT of the chest is often helpful, as it reveals nodules, cavitations, and affected blood vessels. Laboratory results are often inconclusive, with an elevated WBC count and sedimentation rates. When renal involvement is present, RBC casts and proteinuria may be seen on urinalysis as well as a rise in blood urea nitrogen (BUN) and creatinine. Most Wegener’s patients are antineutrophil cytoplasmic antibody (c-ANCA) positive, which can be the most useful clue since both Churg-Strauss and microscopic polyarteritis are perinuclear antineutrophil cytoplasmic antibody (p-ANCA) positive. Biopsy of the nose or throat is positive in only 20% of cases, so open or thoracoscopic lung biopsy may be needed to demonstrate the granuloma formation and vasculitis consistent with Wegener’s granulomatosis.
■ What is the most appropriate treatment for this condition?	It is imperative to rule out infectious etiologies prior to treating Wegener granulomatosis, as an infectious cause may significantly worsen when immunosuppressive therapy is initiated. In severe disease, remission is induced with cyclophosphamide followed by maintenance therapy with a less toxic medication. Disease that is not life threatening can be managed with milder immunosuppressants such as methotrexate and corticosteroids.

■ **What is the prognosis for patients with this condition?**

Chances of achieving remission are 90% with immunosuppression. Recurrence, expected in 50% of patients, is more likely if they continue to be ANCA positive during remission. Most patients will have some long-term sequelae, such as renal insufficiency or failure, hearing loss, facial deformities, thrombosis, or tracheal stenosis. Morbidity from medical therapy is also common and includes hemorrhagic cystitis and transitional cell carcinoma from cyclophosphamide.

► **CASE 17**

A 50-year-old man with a past medical history significant for type 2 diabetes mellitus presents to his primary care physician complaining of excessive daytime sleepiness. He claims that he gets 8 hours of sleep every night yet wakes up every morning with a headache and dry mouth. He finds himself to be lethargic and often falling asleep at work. His wife complains that he snores all night long. He is afebrile, with a heart rate of 90/min, respiratory rate of 12/min, and blood pressure of 150/90 mm Hg. He is 178 cm (5'10") tall and weighs 115 kg (253 lb). Head and neck examination is notable for a large, low-hanging soft palate, and a neck circumference of 43 cm (16.9 in). Heart, lung, and neurologic examinations are unremarkable. Hematology and electrolyte panels are normal.

- **What is the most likely diagnosis?** Obstructive sleep apnea (OSA). Sleep apnea is an important underdiagnosed cause of daytime hypersomnolence in obese patients. It is characterized by numerous awakenings during the night due to apneic episodes. Snoring, gasping, and choking are often reported by those sharing a bed with the patient.

 - **What conditions should be included in the differential diagnosis?** Apnea can be either obstructive or central. Obstructive apnea occurs when the resistance in the upper airways is greater than the respiratory effort. These episodes are characterized by respiratory effort without airflow. In central apnea, the drive to breathe is lost and the patient experiences apnea without respiratory effort. Other causes of daytime sleepiness include narcolepsy, depression, restless leg syndrome, and insomnia secondary to poor sleep hygiene.

 - **How is this condition diagnosed?** The definitive diagnosis is made with a sleep study, in which the patient spends the night in a sleep center for close monitoring of his or her breathing, oxygenation, arousal, and sleeping patterns. An absence of airflow for 10 seconds or more is considered an apneic episode, and the diagnosis of OSA can be made if a patient has 10 or more obstructive episodes per hour.

 - **What are potential complications of this disorder?** Daytime hypersomnolence and subsequent cognitive dysfunction caused by OSA is the most dangerous aspect of the disease, leading to motor vehicle and other accidents. OSA is thought to be an independent risk factor for systemic hypertension and cardiovascular disease. Sleep deprivation is also associated with increased appetite and difficulty losing weight, which complicates a disorder already more frequent in overweight individuals.

 - **What are the treatment options for this condition?**

Behavioral modifications include weight loss, avoiding alcohol and sedatives, and improved sleep hygiene.

Medical treatment involves continuous positive airway pressure (CPAP), a device that supplies positive pressure to keep the upper airway open during sleep. The patient wears either a nasal or oral-nasal mask connected to a machine. This therapy, while extremely effective, is often not well tolerated, so much care should be taken in finding a comfortable and properly fitting mask to improve compliance.

Surgical techniques to decrease the level of upper airway resistance are sometimes used in appropriate patients.
-

Renal/Genitourinary

Case 1	460
Case 2	461
Case 3	462
Case 4	464
Case 5	466
Case 6	468
Case 7	470
Case 8	472
Case 9	474
Case 10	476
Case 11	478
Case 12	479
Case 13	480
Case 14	482
Case 15	483
Case 16	484
Case 17	486
Case 18	487
Case 19	488
Case 20	490
Case 21	491

► **CASE 1**

A 44-year-old man with a history of chronic alcoholism enters the emergency department obviously intoxicated. He complains of severe epigastric abdominal pain radiating to his back, nausea, vomiting, and dyspnea for the past 2 days. On examination, his temperature is 38.8° C (101.8° F), pulse is 115/min, blood pressure is 110/60 mm Hg, and respirations are 28/min and shallow. His abdomen is rigid with diffuse tenderness and hypoactive bowel sounds. Chest examination reveals dullness to percussion at the right base. Relevant laboratory findings are as follows:

Serum Electrolytes	Arterial Blood Gas
Na ⁺ : 142 mEq/L	pH: 7.31
K ⁺ : 3.4 mEq/L	PCO ₂ : 41 mEq/L
Cl ⁻ : 98 mEq/L	PO ₂ : 58 mEq/L
BUN: 47 mg/dL	HCO ₃ ⁻ : 21 mEq/L
Glucose: 210 mg/dL	Serum ketones: 1 ⁺

Chest radiograph shows a large effusion and consolidation in the right lung.

■ What acid-base disturbances are suggested by the history and physical exam?	The complications of acute pancreatitis include vomiting, and pleural effusions. Vomiting causes a metabolic alkalosis, while pleural effusions cause a respiratory acidosis.
■ What acid-base disturbance is suggested by the electrolytes and blood gas?	The laboratory data indicate an anion gap of 23 (142 – [98 + 21]); therefore, a metabolic acidosis is also present. The blood gas is consistent with the diagnoses suggested by the history and lab data. The PCO ₂ is inappropriately normal for an acid pH (it should be low), indicating that there is a respiratory acidosis secondary to the pleural effusion.
■ Is the bicarbonate concentration what would be expected for such a large anion gap?	No. Normally, in an anion gap acidosis, the fall of the bicarbonate is proportional to the rise of the gap. For each hydrogen ion produced to lower the bicarbonate concentration, there is an unmeasured anion produced that raises the anion gap. In this patient, the fall in the bicarbonate concentration is less than would be expected, which, combined with the history of vomiting, indicates a metabolic alkalosis.
■ What is the differential diagnosis for anion gap acidosis?	Renal failure, ketoacidosis, and drug ingestion are the three broad categories causing anion gap acidosis. The mnemonic MUDPILES includes specific etiologies: Methanol Uremia Diabetic ketoacidosis (DKA) Paraldehyde Isoproterenol, iron, isoniazid Lactate Ethylene glycol Salicylates
■ What is the most appropriate treatment for this condition?	Depending on the cause, treatment may include administration of ethanol to decrease methanol and ethylene glycol metabolism to toxic metabolites by alcohol dehydrogenase. (Alcohol dehydrogenase has a 10 times greater affinity for ethanol than methanol.) Hemodialysis may be necessary to remove parent compounds and metabolites. Fomepizole is a new synthetic alcohol dehydrogenase inhibitor, which may also be appropriate in this setting.

► **CASE 2**

A 33-year-old woman presents to the emergency department with a three-day history of fever, malaise, and mild nausea. Over the past day, she has also noticed a new rash on her trunk and extremities. She denies any medical problems, except for a urinary tract infection (UTI) 1 week ago, for which she has been taking cephalexin. She is not on any other medications and denies alcohol use. On examination, her temperature is 39.0° C (102.2° F), pulse is 90/min, and blood pressure is 128/82 mm Hg. Findings from her heart and lung examinations are within normal limits, and her abdomen is soft, nontender, nondistended, and with normal bowel sounds present. Her laboratory results are as follows:

Sodium: 143 mEq/L

Potassium: 4.0 mEq/L

Chloride: 102 mEq/L

Bicarbonate: 24 mmol/L

Blood urea nitrogen: 55 mg/dL

Creatinine: 3.2 mg/dL

Glucose: 90 mg/dL

Urine sediment: white cells, red cells, white cell casts, occasional eosinophils.

Urinalysis: leukocyte esterase, negative; nitrites, negative.

-
- | | |
|--|--|
| <p>■ What is the most likely diagnosis?</p> | <p>The clinical picture is highly suggestive of acute interstitial nephritis (AIN). Although AIN can potentially be caused by infections and autoimmune diseases, the most common cause by far is medications, especially nonsteroidal anti-inflammatory drugs and antibiotics. Given the tight temporal relationship between the patient's use of antibiotics and the onset of symptoms, drug-induced AIN is the most likely diagnosis.</p> |
| <p>■ How do the urine sediment and urinalysis help to distinguish this condition from other causes of acute kidney injury and from a UTI?</p> | <p>The following findings would be expected for each condition:</p> <ul style="list-style-type: none"> ■ Acute tubular necrosis: sediment showing granular and epithelial cell casts and free epithelial cells. ■ Acute glomerulonephritis (GN): sediment showing red cell casts as well as free red and white cells. ■ Prerenal disease: normal sediment. ■ UTI: ≥ 5 white cells (PMNs)/high-powered field (pyuria), bacteria (bacturia), and positive leukocyte esterase and nitrites. <p>In contrast, this patient had white cells and casts with no bacteria (sterile pyuria), no red cell casts (argues against GN), eosinophils, and negative leukocyte esterase and nitrites (indicates that the UTI has been cleared).</p> |
| <p>■ What is the typical presentation of this condition?</p> | <p>AIN can be either subclinical or present as some combination of nausea, vomiting, and malaise if renal insufficiency is severe. Less than 10% of patients will have the classic triad of fever, rash, and eosinophilia, but a greater percentage will have at least one of those signs/symptoms.</p> |
| <p>■ What is the most appropriate treatment for this patient?</p> | <p>She should immediately discontinue the presumed offending drug. It would also be appropriate to consider a trial of corticosteroids, although this is not definitely proven therapy.</p> |
| <p>■ What are the typical renal biopsy findings in this condition?</p> | <p>Histologically, AIN manifests as interstitial edema and a marked interstitial infiltrate consisting of lymphocytes and monocytes, with associated tubular injury. Interstitial eosinophils, plasma cells, and rare neutrophils may also be found. Nonnecrotizing granulomas are also present in some cases of hypersensitivity-induced AIN.</p> |
-

► **CASE 3**

A 45-year-old man with a history of a cerebrovascular accident and seizure disorder is found unresponsive in his home by his neighbor. On arrival to the emergency department, his blood pressure is 90/50 mm Hg, heart rate is 110/min, and temperature is 37.2° C (99.0° F). Lung and heart examinations are normal, and there is no lower extremity edema. A Foley catheter is placed, and 50 mL of brown urine is obtained. Pertinent laboratory data are the following:

Potassium: 5.8 mEq/dL

Creatinine: 4.3 mg/dL

Phosphate: 7 mg/dL

Uric acid: 10 mg/dL

Creatine phosphokinase (CPK): 12,280 IU/L

Urinalysis: 1+ blood, trace protein. Urine sediment: many pigmented granular casts

■ What conditions should be included in the differential diagnosis?	Acute kidney injury (AKI; previously called acute renal failure) can result from damage to any one portion of the kidney: the glomerular compartment (e.g., acute glomerulonephritis), the tubulointerstitial compartment (e.g., acute tubular injury [ATI; previously called acute tubular necrosis], acute interstitial nephritis [AIN]), or the vascular compartment (e.g., thromboembolism, vasculitis, thrombotic microangiopathy).
■ What is the most likely diagnosis?	The absence of RBC casts and minimal proteinuria makes glomerular disease unlikely. AIN is associated with pyuria. The pigmented granular (or “muddy brown”) casts suggest ATI. The clinical setting raises the possibility of postictal rhabdomyolysis, supported by the elevated CPK level. In addition, hyperkalemia, hyperphosphatemia, and hyperuricemia occur commonly in patients with rhabdomyolysis and acute kidney injury, making myoglobinuric ATI the most likely diagnosis.
■ What explains the patient’s abnormal potassium, phosphate, and uric acid levels?	Necrosis of muscle cells releases large quantities of potassium, phosphate, and purines into the plasma. The end product of purine catabolism in the liver is uric acid.
■ Why did the patient develop this condition?	Myoglobin is a non-protein-bound monomeric protein and is therefore rapidly excreted in the urine. Large quantities cause kidney damage both by obstructing tubules and by causing oxidative injury via the release of free iron. In addition, the hypotension (probably secondary to extracellular fluid volume depletion) is of sufficient magnitude to result in renal ischemia.
■ What findings would be expected on renal biopsy?	Though not necessary to make a diagnosis, if a biopsy were obtained, it would show acute tubular injury with flattened regenerative tubular epithelial changes and also degenerative changes and congestion of the vasa rectae with nucleated RBCs. Pigmented (brownish) intratubular myoglobin casts are also present, which can be confirmed by immunohistochemistry (Note: hemoglobin casts—i.e., after transfusion reaction—can also cause tubular injury and pigmented casts).

- **What is the most appropriate treatment for this condition?**

Treatment consists of early volume repletion with isotonic saline to enhance renal perfusion and increase urine flow to wash out obstructing casts. Volume repletion is less likely to be effective (and may lead to symptomatic volume overload) if begun after the first 6–12 hours, when renal failure is already established. An alkaline-mannitol diuresis, in which urine pH is raised > 6.5 , may diminish the renal toxicity of myoglobin, because heme pigments are more soluble in alkaline urine. Raising the pH, however, may promote the precipitation of calcium phosphate and lead to calculus formation.

► **CASE 4**

A 55-year-old, 70-kg man injured in a motor vehicle collision (MVC) presents to the emergency department somnolent, with multiple bruises and a large abdominal laceration. At the time of the MVC, he was not wearing a seat belt and was catapulted through the windshield of his car. His temperature is 36.7° C (98.1° F) heart rate is 135/min, blood pressure is 40 mm Hg over palpable, respiratory rate is 24/min, and oxygen saturation is 99% on a nonrebreather mask with an FiO_2 of 80%. On physical exam, the patient has dry mucous membranes, sunken eyes, and doughy skin. An abdominal CT reveals multiple broken ribs, a large liver laceration, and free fluid in the peritoneal cavity. His urine output has been 5 cc/hr since coming to the hospital. His urine sediment shows muddy brown granular and epithelial cell casts and free epithelial cells.

- | | |
|---|---|
| ■ What is the most likely diagnosis? | The two most common causes of acute kidney injury (AKI) in the setting of hypovolemia are prerenal azotemia and acute tubular injury (ATI; previously called acute tubular necrosis). Given the presence of epithelial cells and epithelial cell casts on urinalysis, the presumptive diagnosis is ATI (secondary to hypovolemic shock and prolonged hypoperfusion). |
| ■ What is the pathogenesis of this condition? | Renal diseases are classified as prerenal, due to lack of adequate renal perfusion; renal, due to intrinsic renal disease; or postrenal, due to obstruction to urine outflow. Renal hypoperfusion leading to decreased glomerular filtration rate (GFR) is an example of prerenal disease; therefore, there is no damage to the renal tubules histologically. ATI results from either progression of prerenal disease (due to prolonged ischemia) or from toxic injury from drugs. Histologically, the kidney damage in toxic ATI manifests as necrosis and denuding of the tubular epithelium and occlusion of the tubular lumen by casts and cellular debris. Ischemic ATI manifests as flattening of proximal tubular epithelial cells and regeneration changes, with occasional vacuolization of tubular cells. |
| ■ What is the typical presentation of this condition? | The history will suggest hypovolemia or prolonged hypotension from any cause (e.g., hemorrhage, diarrhea, vomiting, sepsis, intraoperative events). Alternatively, there will be a history of exposure to nephrotoxic substances (e.g., aminoglycosides, amphotericin B, IV contrast media).

Physical exam would show signs consistent with hypovolemia, including tachycardia, dry mucous membranes, sunken eyes, orthostatic blood pressure changes, and decreased skin turgor.

Patients with AKI can be oliguric or nonoliguric. Normal urine output for an adult is 0.5 cc/kg/hr. In the case of this patient, his urine output of 5 cc/hr was much lower than the expected 35 cc/hr for a 70-kg male. |
| ■ What is the most appropriate treatment for this condition? | Both prerenal disease and ATI are treated by optimizing volume status and blood pressure with IV fluids and pressor support to increase renal perfusion. When ATI is caused by nephrotoxic substances, management also includes removal of the offending agent. |
-

■ **How are prerenal failure and this condition differentiated clinically?**

Although the goals of treatment for both diseases are usually identical, it is helpful to determine whether a patient has prerenal disease or ATI for at least two reasons: (1) to gauge the severity of renal injury and (2) to rule out nephrotoxic substance exposure as the cause of the patient's AKI. In prerenal disease, the urine sediment will appear relatively normal, while in ATI, it will show necrosed tubular cells and cell casts. Since the tubules are still functioning in prerenal disease, the patient's fractional excretion of sodium (FENa) is appropriately low (i.e., the tubules will be appropriately reabsorbing sodium to maintain intravascular volume), while in ATI the FENa is high due to loss of the ability to reabsorb sodium. Similarly, urine sodium concentration tends to be low (< 20 mEq/L) in prerenal disease, while it is high (> 40 mEq/L) in ATI. Furthermore, the blood urea nitrogen (BUN)/plasma creatinine ratio is elevated in prerenal disease because of the increase in passive absorption of urea that follows proximal reabsorption of sodium and water. In contrast, this value is low in ATI because functional tubules are required for proximal reabsorption of sodium and water (see Table 16-1).

■ **What is the prognosis for patients with this condition?**

Nearly all patients with prerenal disease and most patients with ATI spontaneously recover renal function if they are resuscitated in a timely manner. In the case of ATI, prognosis depends on the severity and duration of the untreated ischemia (or exposure to nephrotoxic substances) and the patient's underlying comorbidities (e.g., renal disease, liver disease, cardiac disease, etc.).

TABLE 16-1. Distinguishing ATI from Prerenal Disease

	PRERENAL DISEASE	ATI
Causes	Hypovolemia	Hypovolemia (prolonged) or nephrotoxic substances
Urine sediment	Normal	Muddy brown granular and epithelial cell casts and free epithelial cells
Fractional excretion of sodium (FENa)	< 1%	> 2%
Urine sodium concentration	< 20 mEq/L	> 40 mEq/L
BUN/plasma creatinine ratio	> 20:1	< 15:1
Urine osmolality	> 500 mOsm/kg	< 400 mOsm/kg

► **CASE 5**

A 68-year-old man presents to the emergency department with severe lower abdominal pain. He has a constant desire to urinate but can produce only a small amount of urine. His past medical history is unremarkable, but he says he has experienced hesitancy before the onset of urination and decreased strength of his urinary stream for several months. Physical examination is significant for trace pedal edema, and his blood pressure is 140/86 mm Hg, with no orthostatic changes. He has marked tenderness in the suprapubic region and dullness to percussion to the level of the umbilicus. Rectal examination reveals a large, smooth, firm, midline mass located anteriorly. Laboratory tests show:

Sodium: 142 mEq/L
Potassium: 6.0 mEq/L
Chloride: 113 mEq/L
Bicarbonate: 17 mmol/L
Blood urea nitrogen (BUN): 110 mg/dL
Creatinine: 7 mg/dL
Hemoglobin: 15 g/dL
Hematocrit: 45%

-
- | | |
|---|---|
| ■ What is the most likely diagnosis? | This is an example of postrenal (obstructive) acute renal failure. The patient's chronic symptoms are suggestive of a partial bladder outlet obstruction. His acute symptoms suggest that the obstruction is now essentially complete. The suprapubic tenderness and dullness to percussion are due to a distended bladder. These signs and symptoms in elderly men are most commonly caused by benign prostatic hyperplasia, but prostate cancer must also be considered. |
| <hr/> | |
| ■ How do the laboratory findings help to confirm the diagnosis? | The elevations in BUN and creatinine levels indicate a significant reduction in glomerular filtration rate (GFR). This is due to the increased tubular hydrostatic pressure from the obstruction, which offsets glomerular capillary hydrostatic pressure. The BUN:creatinine ratio is increased because of decreased flow through the collecting duct, which causes enhanced urea reabsorption. The normal hemoglobin and hematocrit levels indicate that this is acute and not chronic renal failure, which almost always causes an anemia due to decreased bone marrow capacity. |
| <hr/> | |
| ■ What procedures and/or imaging tools could be used to confirm the diagnosis? | A catheter bypassing the obstruction may be placed in the bladder. This is sometimes difficult to do when the prostate is very enlarged. An ultrasound of the kidneys would show dilated renal collecting ducts (hydronephrosis) and bilateral ureteral dilatation. A bladder scan would show a markedly enlarged bladder. |
| <hr/> | |
| ■ What is the most appropriate treatment for this condition? | Temporary relief may be achieved with a transurethral catheter, if possible. A suprapubic catheter should be considered if the size of the prostate prevents passage of a catheter. A transurethral prostatectomy is the definitive procedure. In addition, a workup to distinguish benign from malignant prostatic disease should be conducted. |
-

■ **What are potential consequences of the treatment?**

Postobstructive diuresis is typical after the relief of prolonged urinary tract obstruction. The magnitude of the diuresis can reach several liters per day, and one must make sure the patient is appropriately rehydrated to prevent significant dehydration and worsening of the kidney injury. One mechanism for the diuresis is due to the elimination of sodium and water retained during the period of obstruction. Once the obstruction is removed, GFR increases and the excess sodium and water can be eliminated, which is a self-limiting process. Another mechanism is osmotic diuresis from retained urea, which is eliminated as GFR recovers.

► **CASE 6**

A 20-year-old woman with idiopathic membranoproliferative glomerulonephritis presents for her second visit to a nephrology clinic. In the course of 2 months, her serum creatinine concentration has increased from 2.2 to 4.0 mg/dL. Despite antihypertensive therapy with an angiotensin-converting enzyme (ACE) inhibitor, which was started after her first visit, her blood pressure is 160/100 mm Hg. Her weight is 67 kg (148 lb), up 1 kg (2.2 lb) from her last visit, and her legs are more edematous. She has been experiencing tension headaches, which are relieved by nonsteroidal anti-inflammatory drugs (NSAIDs), including ibuprofen and a cyclooxygenase-2 (COX-2) inhibitor. She is also increasingly fatigued. Laboratory values from her first and second visits are listed below:

	Na⁺ (mEq/L)	K⁺ (mEq/L)	Cl⁻ (mEq/L)	HCO₃⁻ (mmol/L)	BUN (mg/dL)	CREATININE (mg/dL)	HEMOGLOBIN (mg/dL)
Today	141	5.3	105	19	45	4.0	9.0
2 months ago	140	4.5	110	21	40	2.2	10.6

- **Is the rise in serum creatinine consistent with a chronic renal disease process?**

No; it represents a large decrement in glomerular filtration rate (GFR) over a short period of time, which suggests an acute-on-chronic process.

- **What are common causes of acute-on-chronic renal failure in this type of situation?**

Because a major determinant of GFR is glomerular capillary hydrostatic pressure, a function of afferent and efferent arteriolar tone, any factor that adversely affects this can cause acute renal failure. Such causes are systemic hypotension (a side effect of antihypertensive therapy), selective afferent arteriolar vasoconstriction (e.g., inhibition of prostaglandin E₂), and selective efferent vasodilation (e.g., inhibition of angiotensin II).

- **What is the most likely cause of the increased serum creatinine in this patient?**

She is hypertensive, has gained weight, and is edematous, all of which indicate she is not intravascularly volume depleted. However, her glomerular capillary hydrostatic pressure (and thus her GFR) is diminished because of her concurrent use of nonsteroidal anti-inflammatory drugs (NSAIDs; which reduce the synthesis of afferent arteriole dilating prostaglandins) and an angiotensin-converting enzyme (ACE) inhibitor (which prevents angiotensin II from adaptively constricting the efferent arteriole to compensate for the NSAID-induced afferent vasoconstriction). Stopping the NSAIDs should improve renal function.

- **How should her blood pressure be brought under control?**

Poorly controlled hypertension is a major risk factor for the progression of renal disease. The recommended goal is 120–130/70–80 mm Hg. Adding another antihypertensive (e.g., β-blocker, calcium channel blocker, or diuretic) may be necessary to reach that goal.

- **What is her acid-base status?**

She has an anion gap metabolic acidosis related to her renal failure. Decreased ammoniagenesis is the likely cause, but her GFR has fallen sufficiently for inorganic (e.g., phosphate, sulfate) and organic (e.g., hippurate, urate) acids to be retained.

- **What is the most likely cause of her fatigue, and how should it be corrected?**

A hemoglobin level below 10 mg/dL is a major cause of morbidity in patients with chronic kidney disease. Her anemia is most likely secondary to erythropoietin deficiency, but other causes, including iron deficiency, which is very common in chronic kidney disease patients and in menstruating young women, should be considered as well. Anemia associated with chronic kidney disease is a normocytic, normochromic, hypoproliferative anemia due to decreased erythropoietin production by the kidneys. She should be started on recombinant human erythropoietin (epoetin alfa) or darbepoetin alfa with the goal of maintaining her hemoglobin level between 11 and 12 mg/dL.

► **CASE 7**

A 55-year-old man with past medical history significant for hypertension presents to his primary care physician with the chief complaint of sexual problems. He reports gradual loss of the ability to have erections over the past year, including nocturnal and morning erections. He reports being depressed because of the resulting loss of intimacy with his wife, to whom he has been married for 30 years. He denies serious marital problems. He denies any other medical problems including problems voiding, but does report intermittent leg pain with exertion. He has not had any surgeries aside from a tonsillectomy at age 12 and denies any genitourinary trauma. His medications include amlodipine and aspirin. He has smoked one pack of cigarettes per day for the past 40 years but denies use of alcohol or illicit drugs. On examination, his pulse is 80/min, and blood pressure is 138/88 mm Hg. His visual fields are intact. His heart, lung, and abdominal examinations are within normal limits. He has normal radial pulses and weak femoral, popliteal, and dorsalis pedis pulses bilaterally. His testicles are somewhat asymmetric but normal in size. His cremasteric reflex is intact bilaterally. Examination of the penis reveals no abnormalities in the shaft, no signs of balanitis in the glans, and no phimosis. A digital rectal examination reveals a normal-sized prostate and normal rectal tone.

-
- **What is the most likely diagnosis?** This patient has male impotence (also called erectile dysfunction), which is defined as the inability to develop or sustain an erection 75% of the time. Gradual-onset impotence leading to complete loss of nocturnal and morning erections is due to either vascular or neurologic causes. Given the patient's history of smoking and hypertension, claudication symptoms, diminished lower-extremity pulses, normal sphincter tone, and intact cremasteric reflex, the most likely cause of his impotence is peripheral vascular disease (PVD) (specifically aortoiliac disease). A patient with purely neurologic impotence would be expected to have no claudication symptoms, normal peripheral pulses, absent or diminished cremasteric reflex, and possibly decreased anal sphincter tone if the neurologic cause of the impotence affected the S2–S4 nerves.
-
- **What conditions should be included in the differential diagnosis?** The differential diagnosis of male impotence is vast. The following clinical findings provided a clue to the diagnosis:
- Rapid onset of impotence (“happened overnight”) is due to either psychogenic causes (e.g., conversion disorder) or genitourinary trauma (e.g., radical prostatectomy).
 - Nonsustained erection (with detumescence after penetration) is due to either anxiety or vascular steal phenomenon.
 - Certain medications can cause impotence, especially selective serotonin reuptake inhibitors, spironolactone, sympathetic blockers (e.g., clonidine), and thiazide diuretics.
 - Impotence associated with gonadal atrophy is likely due to testosterone deficiency (secondary to hypogonadism).
 - Phimosis (inability to retract the foreskin) points to underlying diabetes mellitus.
 - Hard, plaquelike structures in the penile shaft suggest Peyronie's disease.
- Other causes of impotence include: depression, hypo- and hyperthyroidism, prolactinoma, and Klinefelter's syndrome.
-

■ **What is the most appropriate treatment for this condition?**

Once the diagnosis of peripheral vascular disease is confirmed with ankle-brachial indices and duplex ultrasound of the lower extremities, treatment proceeds in a stepwise fashion, starting conservatively with diet and lifestyle modifications (i.e., smoking cessation and a walking exercise program). If conservative management does not result in clinical improvement, revascularization surgery (e.g., aorto-bifemoral bypass, iliac artery angioplasty, stenting, etc.) is considered.

► **CASE 8**

A 36-year-old woman presents to the emergency department with a 2-week history of nonproductive cough, fatigue, and swelling in her legs. She reports that over the past 3 days she has not been urinating as frequently as she normally does and that her urine is darker than usual. Review of symptoms and past and family histories are otherwise unremarkable. A routine employment physical 1 year ago showed a blood pressure of 115/75 mm Hg and a normal urinalysis. Current physical examination reveals hypertension (165/95 mm Hg) and peripheral edema, but otherwise is normal. Laboratory testing reveals a serum creatinine level of 2.5 mg/dL. Urinalysis reveals a specific gravity of 1.022, 4+ blood, 2+ protein, many RBCs, occasional WBCs, and pigmented and RBC casts. She is admitted to the hospital for further workup; the following day, her creatinine is 3.2 mg/dL.

■ What renal syndrome does this patient have?	Acute glomerulonephritis (GN), which is defined as the sudden onset of hematuria, proteinuria, and red blood cell casts. Because of the rapidly declining glomerular filtration rate (GFR), she would further be classified as having rapidly progressive glomerulonephritis (RPGN).
■ What conditions should be included in the differential diagnosis?	The differential diagnosis is extensive but can be broken down into systemic or primary renal disease. In this patient, the nonproductive cough suggests extrarenal disease, and the history would be compatible with Wegener's granulomatosis, microscopic polyangiitis (MPA), or Goodpasture's syndrome, which all involve both the lung and kidney. Systemic lupus erythematosus (SLE) is another possibility.
■ What tests could be used to confirm the diagnosis?	Serum complement levels, antinuclear antibody (ANA), anti-DNA antibody, antineutrophil cytoplasmic antibodies (ANCA), and anti-glomerular basement membrane (anti-GBM) antibody serologies should be obtained (Table 16-2).
■ What are the typical findings on microscopic analysis?	Renal biopsy is the gold standard for diagnostic purposes in determining the cause of GN. Crescents are a frequent cause of RPGN. They arise when breaks in the glomerular basement membrane result in release of fibrinogen into Bowman's space, with subsequent fibrin formation, influx of macrophages and lymphocytes, and proliferation of the parietal epithelial cells. Crescentic GN is a lesion with multiple etiologies, including immune complex disease (e.g., postinfectious GN, systemic lupus erythematosus, and pauci-immune GN, which includes Wegener's and MPA); and anti-GBM antibody-mediated GN (Goodpasture's syndrome if lung is also involved).

TABLE 16-2. Distinguishing Features of Common Causes of RPGN

CONDITION	SERUM COMPLEMENT LEVELS	CIRCULATING AUTOANTIBODIES	LIGHT MICROSCOPE FINDINGS	IMMUNOFLUORESCENCE FINDINGS	ELECTRON MICROSCOPE FINDINGS
Anti-GBM	Normal	Anti-GBM antibodies (to type IV collagen)	Uninvolved glomeruli normal, crescents	Linear staining of GBM with anti-IgG	No deposits visible
SLE	Low C3 and CH50	Anti-DNA	Endocapillary proliferation, tram- tracking, crescents	"Sausage-like" staining along GBM and mesangium for IgG, IgA, IgM, C3, C1q	Lumpy deposits subendothelial, mesangial
Pauci-immune GN	Normal	Antineutrophil cytoplasmic antibody (ANCA)	Uninvolved glomeruli normal, crescents	No staining	No deposits visible

► **CASE 9**

A 48-year-old man presents to the emergency department with a 2-day history of confusion and weakness. He has been complaining of back pain for the past 2 months and has lost 9.1 kg (20 lb) over the past 6 months. He takes acetaminophen and ibuprofen occasionally for his back pain. His past medical history is unremarkable. On physical examination, the patient looks older than his stated age; his blood pressure is 110/80 mm Hg while supine and 90/60 mm Hg when standing, and his heart rate increases from 90/min to 112/min, respectively. The rest of his examination is unremarkable except for mild muscular weakness. Relevant laboratory findings are as follows:

Na⁺: 144 mEq/L Creatinine: 2.1 mg/dL
K⁺: 4.2 mEq/L Ca²⁺: 13.2 mg/dL
Cl⁻: 98 mEq/L Phosphorus: 3.4 mg/dL
HCO₃⁻: 29 mmol/L Albumin: 3.0 mg/dL
Blood urea nitrogen (BUN): 65 mg/dL

■ What is the most likely diagnosis?	Hypercalcemia of malignancy.
■ How should the workup proceed for this patient's condition?	Workup should be directed at determining the type and extent of malignancy so that appropriate therapy can be instituted (Table 16-3). <i>Note:</i> The patient's renal insufficiency and metabolic alkalosis are potential complications of chronic hypercalcemia.
■ What is the most appropriate treatment for this patient?	Immediate therapy is required because he is symptomatic, and his calcium level is > 13 mg/dL. Volume expansion with normal saline will increase the filtered load of calcium and decrease proximal tubular calcium reabsorption. After intravascular volume is restored, a loop diuretic (e.g., furosemide) may be added to decrease calcium reabsorption in the thick ascending limb of Henle (remember: Loops Lose calcium). Bisphosphonates (pamidronate or etidronate) are the agents most commonly used to treat hypercalcemia of malignancy. They inhibit bone resorption and reach maximal effect in 7–10 days.

TABLE 16-3. Cancer-Associated Mechanisms of Hypercalcemia

MECHANISM	FEATURES
Vitamin D–secreting lymphomas	Some lymphomas secrete calcitriol (1,25 dihydroxyvitamin D—i.e., the active form of Vitamin D), which increases bone resorption and enhances calcium absorption from the gut. Bone metastases are variable. Predominant cause of hypercalcemia in Hodgkin’s disease and in one-third of patients with non-Hodgkin’s lymphoma.
Parathyroid hormone–related protein (PTHrP)–secreting tumors	PTHrP increases bone resorption and enhances distal renal tubular reabsorption of calcium. Bone metastases are minimal or absent. Commonly associated malignancies include squamous cell tumors of the head and neck, esophagus, cervix or lung and renal, ovarian, and endometrial carcinomas.
Local osteolytic hypercalcemia	Tumor metastases to bone release cytokines that stimulate osteoclast production and action. Tumors most commonly associated with bony metastases: breast, lung, lymphoma, thyroid, kidney, prostate, and multiple myeloma (mnemonic: BL²T with a K osher P ickle, M ustard, and M ayo).
Ectopic hyperparathyroidism	Very rarely, some tumors will actually secrete parathyroid hormone (PTH).
Primary hyperparathyroidism	Cancer patients have a higher incidence of primary hyperparathyroidism than the general population; further, a serum PTH should always be obtained as part of the workup for hypercalcemia.

► **CASE 10**

A 45-year-old man with a history of depression is brought to the emergency department a few hours after ingesting 50 of his wife's potassium supplement tablets in a suicide attempt (each tablet contains 8 mEq of potassium). His physical examination is normal except for mild hyporeflexia. Laboratory studies show a serum potassium concentration of 7.0 mEq/L.

-
- | | |
|--|--|
| <p>■ How is an acute potassium load handled by the body?</p> | <p>Cellular potassium uptake and renal potassium excretion are the body's major defenses against lethal hyperkalemia. Approximately 40–50% of an acute load is excreted in the urine over 3–6 hours, with much of the remainder (~75%) being translocated into cells. Defects in renal excretion or cell uptake would produce proportionately greater rises in the plasma potassium concentration and would likely lead to cardiac arrest.</p> |
| <p>■ What are the typical electrocardiographic manifestations of hyperkalemia?</p> | <p>A tall, peaked T wave with a shortened QT interval is the first sign (Figure 16-1). With worsening hyperkalemia, the PR and QRS intervals widen. The P wave may eventually disappear and the QRS eventually widens to a “sine wave” pattern (as the QRS complex merges with the T wave). This may ultimately progress to ventricular fibrillation or asystole.</p> |
| <p>■ What therapies should be instituted for the emergent treatment of severe hyperkalemia, and what are their underlying mechanisms?</p> | <p>Listed in order of their rapidity of action, from fastest to slowest, the treatments are:</p> <ul style="list-style-type: none">■ Calcium: Antagonizes the membrane effects of hyperkalemia (mechanism unknown). Calcium is indicated only for severe hyperkalemia (i.e., as with widening of the QRS or loss of P waves, but not with peaked T waves alone). It acts within minutes but lasts less than an hour.■ Insulin and glucose: Insulin enhances the Na⁺/K⁺ ATPase pump in skeletal muscle, thereby driving potassium intracellularly. Effects are seen within 15–30 minutes and last for several hours. It is administered with a glucose drip or D50 injection to prevent hypoglycemia.■ Bicarbonate: Redistributes potassium into cells and may be particularly effective in patients with metabolic acidosis. Results may be seen in 30–60 minutes but it may take as long as a few hours.■ β₂-adrenergic agonists (e.g., albuterol): Like insulin, they stimulate the Na⁺/K⁺ ATPase, which drives potassium intracellularly. They should be avoided in patients with known or suspected coronary disease because the high doses given to achieve effect can cause tachycardia.■ Loop or thiazide diuretics: Permanently excrete potassium out of the body into the urine.■ Cation-exchange resins (e.g., Kayexalate): Bind up potassium in the gut, removing it from the body. <p>Patients with renal insufficiency may require emergent dialysis.</p> |
-

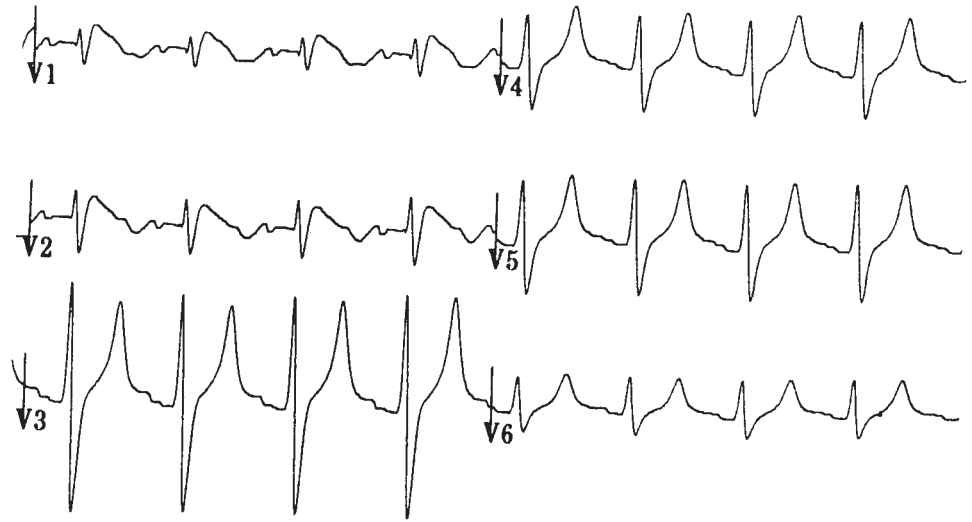


FIGURE 16-1. ECG manifestations of hyperkalemia. Wide QRS complexes are followed by peaked T waves (best seen in V3). (Reproduced, with permission, from Fuster V, Alexander RW, O'Rourke RA, eds; Roberts R, King SB III, Nash IS, Prystowsky EN, assoc. eds. *Hurst's The Heart*, 11th ed. New York: McGraw-Hill, 2004: Fig. B-33.)

► **CASE 11**

A 79-year-old woman who resides in a nursing home is brought to the hospital because of decreased mental acuity. She had been doing well until she developed a fever associated with an upper respiratory infection. She ate poorly and over 3 days became less responsive. She had been treated with antibiotics but not intravenous fluids. Physical examination reveals an obtunded elderly woman with a blood pressure of 110/78 mm Hg supine, 108/80 mm Hg sitting up in bed, heart rate of 96/min, respiratory rate of 20/min, and temperature of 39.1° C (102.4° F). She has poor skin turgor, her chest is clear to auscultation bilaterally, and her heart rhythm is regular with no murmurs or gallops; she has no abdominal masses and no peripheral edema. Laboratory studies are as follows:

Na ⁺ : 167 mEq/L	Creatinine: 1.0 mg/dL
K ⁺ : 4.3 mEq/L	Glucose: 100 mg/dL
Cl ⁻ : 105 mEq/L	Hemoglobin: 18.1 g/dL
HCO ₃ ⁻ : 24 mmol/L	Urine osmolality: 550 mOsm/kg
BUN: 40 mg/dL	

- **How do the history, physical examination, and laboratory data help in identifying the pathophysiologic mechanisms responsible for the hypernatremia?**

This information all points to excessive extrarenal water losses and inadequate water intake. Losses are incurred in this patient due to insensible losses associated with fever. It is estimated that for each 0.6° C (1.0° F) increase in body temperature above 37.8° C (100.0° F), an additional 1000 mL of electrolyte-free water is lost as sweat. Normally, insensible losses average 500 mL/day. Obtundation has decreased her thirst perception, which would normally drive water intake when serum sodium reaches the upper limits of normal (145 mEq/L). The elevated BUN and hemoglobin levels are due to hemoconcentration.

- **What has caused the patient's mental status change?**

Electrolyte-free water is lost in proportion to the normal distribution of water between the extra- and intracellular fluid compartments. Since two-thirds of the body's water is in the intracellular compartment, most of the losses are incurred there, causing cellular dehydration and altered mental status. Cerebral dehydration initially causes confusion and obtundation and can progress to seizures or coma.

- **If her urine osmolality were 150 mOsm/kg, what other conditions should be considered as potential causes for her hypernatremia?**

A high urine osmolality indicates the kidneys are conserving water appropriately in response to the hypernatremia. A low osmolality in this case would indicate renal instead of extrarenal electrolyte-free water loss. Renal losses are associated with less-than-maximal urine osmolality, and extrarenal losses are accompanied by maximal levels (generally > 500 mOsm/kg in hospitalized patients). Central or nephrogenic diabetes insipidus can cause hypernatremia if associated with decreased thirst perception and/or decreased access to water.

- **What is the most appropriate treatment for this patient's hypernatremia?**

Oral rehydration is the preferred method of electrolyte-free water repletion. That is not possible for this patient because of her obtunded state, so intravenous 5% dextrose in water should be used. Approximately 50% of the water deficit should be repleted in the first 24 hours, and the remainder corrected over the next 24–48 hours. Too rapid correction may lead to cerebral edema due to the accumulation of idiogenic osmoles within brain cells that have served to defend against cell volume contraction.

► **CASE 12**

A 37-year-old hypertensive obese man with a 1 week history of productive cough, fever, and chills becomes progressively more obtunded and on day 7 is brought to the emergency department, where he has a generalized tonic-clonic seizure. Physical examination reveals a blood pressure of 90/60 mm Hg, heart rate of 100/min, and temperature of 37.9° C (100.2° F). He responds to his name but is lethargic, has decreased skin turgor, no axillary sweat, no peripheral edema, and no focal neurologic signs. There is dullness to percussion and decreased lungs sounds in the right lower lobe of his lungs. Relevant laboratory findings are as follows:

Na ⁺ : 135 mEq/L	Blood urea nitrogen (BUN): 40mg/dL
K ⁺ : 3.5 mEq/L	Creatinine: 1.6 mg/dL
Cl ⁻ : 100 mEq/L	Glucose: 1200 mg/dL
CO ₂ : 24 mEq/L	Urinalysis: 4+ glucose, negative for ketones

- | | |
|---|--|
| ■ Given the low serum sodium concentration, is this patient hypo- or hypertonic? | This patient is hypertonic based on the following calculation: Plasma tonicity = $2 [\text{Na}] + [\text{glucose}]/18 = 370 \text{ mOsm/kg}$. Urea is not included in the calculation of plasma tonicity, since it is an ineffective solute that equilibrates between extracellular and intracellular fluid. |
| ■ What is the most likely diagnosis? | Hyperosmolar hyperglycemic state (HHS; previously called hyperosmolar hyperglycemic nonketotic coma), in this case caused by severe hypertonicity. In hypertonic states, fluid is shifted out of cells, leading to intravascular volume depletion, manifested by tachycardia and hypotension; it also causes cellular dehydration, which leads to mental status changes, decreased tissue turgor, and decreased axillary sweat. |
| ■ How does this patient's presentation differ from diabetic ketoacidosis (DKA)? | DKA is characterized by the triad of hyperglycemia, ketonemia, and wide anion gap metabolic acidosis. Although the patient has hyperglycemia, his anion gap is normal and his urinalysis is negative for ketones. |
| ■ What precipitated this crisis? | HHS is most commonly seen in either obese or elderly individuals, without a previous history of diabetes mellitus, who develop insulin resistance. Insulin resistance is precipitated by severe infections (pneumonia in this patient), pancreatitis, burns, surgical stress, corticosteroids, and hyperalimentation. |
| ■ What is the patient's corrected sodium level? | This is the concentration that would be expected if the serum glucose concentration were normal (i.e., reduced to 100 mg/dL). To calculate this, for each 100 mg/dL that the plasma glucose is increased over 100 mg/dL, increase the sodium by 2.4 mEq/L. With a glucose concentration of 1800 mg/dL, multiply 2.4 by $17 = 41 \text{ mEq/L}$, and add the product to the measured sodium concentration: $(135 \text{ mEq/L} + 41 \text{ mEq/L} = 176 \text{ mEq/L})$. This provides a better estimate of the patient's true water deficit. |
| ■ What is the first step in managing this patient's fluid and electrolyte abnormalities? | The first priority is to restore intravascular volume with intravenous normal saline. This must be done before treating the hyperglycemia. Giving insulin, which will cause glucose to move into cells, before correcting the volume status will cause further extracellular fluid contraction and could precipitate hypovolemic shock. |

► **CASE 13**

A 43-year-old woman presents with a fractured rib. She has diffuse bone pain and difficulty combing her hair, rising from a chair, and climbing stairs. She states she has had foul-smelling, bulky stools and has lost about 4.5 kg (10 lb) over the past 6 months, though her appetite has been normal. She has high calcium intake and normal sun exposure. She takes a multivitamin daily. Physical examination shows a normal abdomen, proximal muscle weakness, and tenderness over the spine and ribs. She walks with a waddling gait. Neurologic examination is otherwise normal. Blood studies show normal electrolytes, renal function, and liver function. Other pertinent laboratory data are as follows:

Calcium: 7.5 mg/dL

Phosphorus: 1.6 mg/dL

Magnesium: 1.3 mg/dL (normal: 1.5–2.0 mg/dL)

Albumin: 3.2 mg/dL

Parathyroid hormone (PTH): 96 pg/mL (normal: 10–55 pg/mL)

Calcidiol: 5 ng/mL (normal: 8–15 ng/mL)

■ **What are the possible causes of hypocalcemia?**

It is due in part to hypoalbuminemia; the corrected serum calcium is calculated by adding $0.8 \times$ (the difference between normal and measured albumin) to the measured calcium level = $7.5 + 0.8 \times (4.0 - 3.2) = 8.1$ mg/dL. This value is still below the normal serum calcium range, indicating the presence of clinically significant hypocalcemia. Magnesium deficiency can cause hypocalcemia, but only when magnesium levels are < 1.2 mg/dL. Renal function is normal, so renal failure cannot explain the hypocalcemia.

■ **What are the possible causes of low calcidiol levels?**

This may be caused by a nutritional deficiency, sunlight deprivation, malabsorption, impaired vitamin D metabolism, or excretion of vitamin D in the urine. Malabsorption (the likely culprit in this patient) can be due to intestinal disease, as in inflammatory bowel disease or celiac sprue. Chronic liver disease impairs the conversion of vitamin D to calcidiol, the substrate for the kidney's production of the active form of vitamin D, calcitriol.

■ **What would a bone biopsy show?**

It would show osteomalacia due to low circulating calcium and phosphate and the absence of the anabolic effects of vitamin D on bone. Looser's lines are symmetric bilateral pseudofractures and are pathognomonic for osteomalacia (Figure 16-2).

■ **What is the most appropriate treatment for this condition?**

Treatment includes vitamin D and oral calcium. Since there is no defect in the conversion of calcidiol to calcitriol, either vitamin D₂ (ergocalciferol) or calcidiol is appropriate.

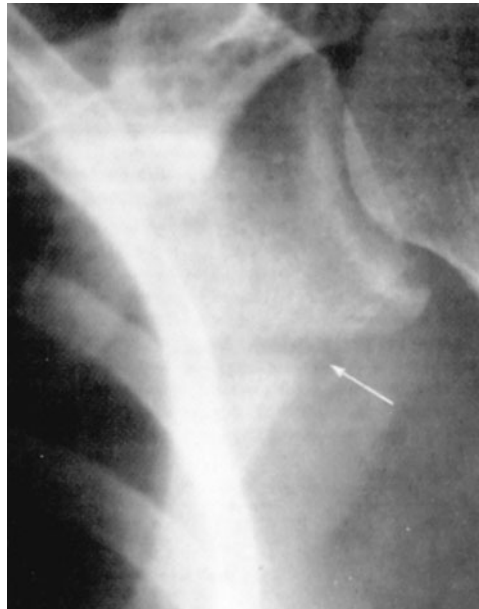


FIGURE 16-2. Radiograph of the scapula in a patient with phosphaturia as a cause of osteomalacia. Looser's zone (or pseudofracture) is indicated by the arrow. (Reproduced, with permission, from Kasper DL, Braunwald E, Fauci AS, Hauser SL, Longo DL, Jameson JL, Isselbacher J, et al. *Harrison's Principles of Internal Medicine*, 16th ed. New York: McGraw-Hill, 2005: Fig. 331.6.)

► **CASE 14**

A 55-year-old man with a past medical history of hypertension and congestive heart failure presents to the emergency department with a 1-day history of right flank pain, nausea, and vomiting. The pain was initially mild a few hours ago but progressed gradually over the course of 30 minutes to severe pain, followed by nausea and vomiting several times. The pain now radiates to his right testicle. He denies any history of recent trauma. On examination, his temperature is 36.7° C (98.0° F), pulse is 90/min, blood pressure is 140/72 mm Hg, and respiratory rate is 14/min. He is lying in bed, doubled over in pain. Auscultation of his heart reveals a normal S1 and S2 with an S3 gallop and no murmurs or rubs. He has faint crackles in the bases of both lungs. His abdomen is soft, nondistended, and somewhat tender in the right flank area, without guarding or rebound tenderness and with normal bowel sounds present. No abdominal or flank masses are appreciated. He has pitting edema to the ankles bilaterally. In the hour since coming to the hospital, he has put out 50 cc of pinkish urine. His medications include metoprolol, furosemide, captopril, amlodipine, and aspirin.

-
- **What is the most likely diagnosis?** A history of progressively worsening flank pain over a period of an hour combined with hematuria is highly suggestive of nephrolithiasis. Radiation of the pain to the groin (testicle or labia) suggests migration of the stone to the lower third of the ureter. The differential diagnosis of abdominal pain that progresses over a similar time course and pattern of radiation includes aortic dissection, lumbar disk disease, renal infarction, and intestinal disease. The differential of gross hematuria includes renal malignancy, infection, glomerulonephritis, and trauma.

 - **Which of the patient's medications likely precipitated his current symptoms?** Loop diuretics such as furosemide increase the concentration of calcium in the urine, thereby increasing the risk of calcium stone formation. Specifically, they inhibit the co-transport of Na⁺, Cl⁻, and K⁺ at the luminal membrane of the thick ascending limb of the loop of Henle, effectively decreasing the driving force for the reabsorption of Mg²⁺ and Ca²⁺ ("Loops Lose Calcium").

 - **What laboratory and imaging tools are used to evaluate this condition?**

The workup to evaluate suspected nephrolithiasis is as follows:

 - Urinalysis and urine sediment: To determine urine pH and evaluate the urine for crystals, because certain types of kidney stones are associated with specific urine pH and crystal findings. For instance, calcium stones (which account for ~80% of all kidney stones) tend to arise in alkaline environments (urine pH > 6) and generate the urine sediment findings seen in Figure 16-1.
 - Plain film of the abdomen: To look for radiopaque stones (90% of all renal stones).
 - Helical CT: When a plain film of the abdomen is inconclusive, but the clinical suspicion is high, helical CT has become the gold standard for diagnosing renal stones and ruling out alternative diagnoses (e.g., appendicitis, diverticulitis, aortic aneurysm, etc.).

 - **What is the most appropriate treatment for this condition?** The initial treatment consists of providing adequate hydration and pain relief. Additionally, the patient's loop diuretic should be replaced with a thiazide (e.g., hydrochlorothiazide), a diuretic that actually *increases* calcium reabsorption from the renal tubules while still providing potent diuresis for the patient's congestive heart failure. Small stones (< 5 mm) often pass on their own. Larger stones sometimes need to be removed with a urological procedure (e.g., extracorporeal shock-wave lithotripsy, retrograde ureteroscopy, percutaneous lithotripsy, or open lithotripsy).
-

► **CASE 15**

A 62-year-old man develops sudden onset pain in his right foot. On further inspection, he notices that his foot is cold and blue, and he is taken to the emergency department. His past medical history is significant for osteoarthritis of his knees, which limits his mobility. He takes nonsteroidal anti-inflammatory drugs (NSAIDs), which help the pain. On physical examination, his blood pressure is 145/90 mm Hg, heart rate is 92/min, and temperature is 37° C (98.6° F). His right foot is cool and pulseless, and there is 2+ pitting edema to the knees bilaterally. Urinalysis reveals a specific gravity of 1.026, 1+ blood, 3+ protein, occasional RBCs, and occasional hyaline casts.

<ul style="list-style-type: none"> ■ What is the most likely cause of the patient's lower extremity signs and symptoms? 	<p>The cool, pulseless, cyanotic foot indicates severely compromised blood flow to the right lower extremity. Patients with nephrotic syndrome lose both procoagulant proteins and anticoagulant proteins in the urine, and some patients develop either arterial or venous thromboses. This patient has developed an arterial thrombosis as a consequence of spilling anticoagulant proteins in his urine.</p>
<ul style="list-style-type: none"> ■ What primary renal diseases can cause this condition? 	<p>A wide variety of systemic diseases and a more limited number of renal diseases can cause nephrotic syndrome. Focal segmental glomerulosclerosis (FSGS), minimal change disease (MCD), and membranous nephropathy (MBN) make up the majority of the primary renal diseases presenting as nephrotic syndrome in adults.</p>
<ul style="list-style-type: none"> ■ What systemic diseases cause this condition? 	<p>Diabetes mellitus, systemic lupus erythematosus, amyloidosis, malignancy (lymphoma, adenocarcinoma), and viral infections (e.g., hepatitis, HIV) can all cause a nephrotic syndrome.</p>
<ul style="list-style-type: none"> ■ How should the workup proceed for this patient's condition? 	<p>Evaluation and treatment of the suspected arterial thrombosis is the top priority. Given the increased incidence of renal vein thrombosis in patients with nephrotic syndrome, renal angiography should be considered as part of the radiologic evaluation. In addition, the proteinuria should be quantified, creatinine clearance measured, and other characteristics typical of nephrotic syndrome sought (hypoalbuminemia and hyperlipidemia). Serologic evaluation should include tests for hepatitis B and C and HIV. NSAIDs and malignancy have been associated both with MCD and MBN, and in this elderly gentleman age-appropriate cancer screening should be performed.</p>
<ul style="list-style-type: none"> ■ What are the typical findings on renal biopsy? 	<ul style="list-style-type: none"> ■ FSGS: By light microscopy, segmental areas of sclerosis in some but not all glomeruli, negative immunofluorescence (IF), foot process effacement by electron microscopy (EM). ■ MCD: Histologically normal glomeruli by light microscopy; foot process effacement by EM. ■ MBN: Basement membrane thickening with little or no cellular proliferation or infiltration by light microscopy; capillary loop deposits by IF with corresponding subepithelial deposits by EM.
<ul style="list-style-type: none"> ■ In addition to thromboembolism, what are other potential complications of this condition? 	<p>Patients with nephrotic syndrome are at increased risk for anasarca, hypoalbuminemia, and hypogammaglobulinemia (loss of protein in urine), with consequent increased infection risk and hypovolemia (may rarely cause acute renal failure due to volume shifts).</p>

► **CASE 16**

A 56-year-old man presents to the emergency department following an episode of hematuria. He reports continuous bilateral flank pain and progressive worsening of fatigue, malaise, and nausea for the past several months, but he is uninsured and has not been able to seek medical care. When questioned, he states that he has been urinating less than previously. He believes his father suffered from something similar but is unclear on the details. His temperature is 36.9° C (98.4° F), heart rate is 88/min, and blood pressure is 168/99 mm Hg. There are bilateral masses palpated on abdominal exam. Laboratory findings include blood urea nitrogen of 64 mg/dL and creatinine of 3.1 mg/dL.

- | | |
|--|--|
| ■ What tests and/or imaging tools could be used next to confirm the diagnosis? | This patient is in renal failure. From this initial assessment, it is difficult to say whether this is an acute process or sudden worsening of chronic kidney disease. Causes of acute kidney injury should be eliminated (i.e., dehydration) before initiating dialysis therapy for his symptoms. The next steps in the workup would be a urinalysis and renal ultrasound or abdominal CT (which would have to be performed without contrast due to his renal failure), followed by biopsy if necessary. |
| ■ What is the most likely diagnosis? | Autosomal dominant polycystic kidney disease (ADPKD). This is a genetic condition marked by cyst formation in the kidneys, liver, spleen, and pancreas, leading to progressive worsening of kidney function with age. It is estimated that 2% of patients require dialysis by the age of 40, 20% by age 50, 40% by age 60, and 60% by age 70. Pain and hematuria are the most common presenting symptoms. |
| ■ What is the pathogenesis of this condition? | ADPKD is due to a genetic mutation, either in the polycystin 1 gene (PKD1) on chromosome 16 or in the polycystin 2 gene (PKD2) on chromosome 4. Generally speaking, PKD2 is less severe than PKD1, but neither disease is benign. Cysts form in a relatively small number of nephrons, so the mechanism of kidney failure is not entirely understood; the development of vascular sclerosis and interstitial fibrosis contributes. |
| ■ What risk factors are associated with an increased incidence of this condition? | <ul style="list-style-type: none">■ Younger age at diagnosis (earlier onset of symptoms)■ Male gender■ Gross hematuria■ Hypertension■ Proteinuria■ Kidney size |
| ■ What is the most appropriate treatment for this condition? | Management focuses on decreasing progression to end-stage renal disease (ESRD). Urinary tract infections (UTIs) are very common in these patients and must be treated quickly to prevent cyst infection. Tight blood pressure control, often with angiotensin-converting enzyme (ACE) inhibitors, also helps to prevent further kidney damage. Percutaneous drainage of large cysts may reduce pain but does not affect kidney function. Patients with ESRD are managed with dialysis or renal transplantation, typically with good results. |
-

- **This condition is associated with an increased risk of what other conditions?**

Patients with ADPKD have an increased incidence of aneurysms at the circle of Willis, known as berry aneurysms. Risk of rupture is exacerbated by uncontrolled hypertension. Mitral valve prolapse and diverticulosis are also frequently seen in these patients. Despite the presence of cysts in the liver, hepatic dysfunction is rare.

- **If similar findings of cystic disease were seen in an infant, what would be the likely diagnosis?**

Autosomal recessive polycystic kidney disease (ARPKD). This is a less common but more severe form of the disease that presents in infants and young children. These patients suffer liver cirrhosis and portal hypertension in addition to renal failure; this condition is often fatal in the first few years of life.

► **CASE 17**

A 44-year-old man with no significant past medical history presents to his primary care physician with a 3-month history of left flank pain. The pain is dull in character, constant, and has become progressively worse over time. Over the past week, he has also noticed a pink hue to his urine. He denies any history of trauma in the past year. On examination, his temperature is 37.2° C (99.0° F), pulse is 88/min, and blood pressure is 110/74 mm Hg. His heart and lung examinations are within normal limits. A palpable mass is noted in his left abdominal/flank region. The mass is firm, nontender, and moves with respiration. The rest of the abdomen is soft, nontender, nondistended, and with normal bowel sounds. Fullness is also noted in his left scrotum when the patient is recumbent. The fullness permits light penetration on transillumination.

- | | |
|--|---|
| ■ What is the most likely diagnosis? | The triad of (1) hematuria, (2) flank pain, and (3) a palpable abdominal/renal mass is classic for renal cell carcinoma (RCC). Although it is found in less than 10% of patients with RCC, when it occurs, the presence of this triad is a marker of locally advanced disease (“too-late triad”). Hematuria occurs only with tumor invasion of the collecting system. Any patient with hematuria who presents with blood clots in their urine should be rigorously evaluated for cancer, because clot formation does not occur with glomerular bleeding (e.g., nephritic syndrome or rapidly progressive glomerulonephritis). |
| ■ Why does the patient most likely have left scrotal fullness? | A minority of patients (~10%) with left-sided RCC will have left-sided scrotal varicoceles due to tumor obstruction of the left gonadal vein as it enters the left renal vein. |
| ■ What other symptoms are common in patients with this condition? | Other possible findings include: symptoms resulting from IVC invasion/obstruction (lower-extremity edema, ascites, hepatomegaly, etc.), paraneoplastic syndromes (from ectopic production of any number of hormones—e.g., hypercalcemia from parathyroid-like hormone, Cushing’s from adrenocorticotrophic hormone-like substance, hypertension from renin, erythrocytosis from erythropoietin, etc.), anemia, hepatic dysfunction, intermittent fever, weight loss, night sweats, and cachexia. |
| ■ What risk factors are associated with an increased incidence of this condition? | Patients at increased risk for RCC include those with certain inherited conditions (including Von Hippel–Lindau syndrome and tuberous sclerosis), end-stage renal disease, adult polycystic kidney disease, a strong family history of RCC, and prior kidney irradiation. |
| ■ What is the most appropriate next step in management? | Patients with unexplained hematuria or other signs and/or symptoms suspicious for RCC must undergo radiologic evaluation of their kidneys. The evaluation begins with a renal ultrasound to differentiate simple benign cysts from complex cysts and solid tumors. The finding of a simple cyst on ultrasound effectively rules out RCC, whereas the finding of complex cysts or a solid mass mandates further evaluation with an abdominal CT. A definitive diagnosis is obtained through histological evaluation via either a biopsy (rarely) or a nephrectomy or partial nephrectomy (more commonly). |
-

► CASE 18

A 64-year-old woman with a long history of diabetes mellitus and hypertension presents to her primary care physician for an annual checkup. Laboratory studies reveal a potassium level of 5.5 mEq/L. Repeat laboratory studies include serum electrolytes and an arterial blood gas. Relevant findings are as follows:

Na ⁺ : 143 mEq/L	Creatinine: 1.6 mg/dL
K ⁺ : 5.4 mEq/L	Arterial blood gas:
Cl ⁻ : 115 mEq/L	pH: 7.36
HCO ₃ ⁻ : 21 mmol/L	Pco ₂ : 33
BUN: 30 mg/dL	Po ₂ : 90

Additionally, plasma renin and aldosterone are both decreased.

- | | |
|--|--|
| ■ What is the cause of this patient's acidosis? | She has type IV renal tubular acidosis (RTA), characterized by hyperkalemia and a hyperchloremic metabolic acidosis. This is often seen in patients with diabetes mellitus and mild-to-moderate renal insufficiency. It is also seen in some patients who are taking nonsteroidal anti-inflammatory drugs, angiotensin-converting enzyme (ACE) inhibitors, cyclosporine/tacrolimus, or potassium-sparing diuretics. Patients who have interstitial renal diseases such as systemic lupus erythematosus, obstructive uropathy, and sickle cell disease or HIV nephropathy may also be affected. |
| ■ What is the mechanism behind this condition? | The basic defect is decreased potassium secretion by the distal tubule. It can result from hyporeninemic hypoaldosteronism or from an unresponsiveness of the renal tubule to aldosterone. A functional decrease in aldosterone activity reduces distal tubular reabsorption of sodium, thus reducing secretion of potassium and H ⁺ . The hyperkalemia inhibits ammonium production by the renal tubules, thus further inhibiting the excretion of H ⁺ into the urine and causing the acidosis. In spite of the aldosterone deficiency, most patients have normal sodium levels because there is no hypovolemia-induced stimulation of ADH release. |
| ■ What was her predisposing risk factor? | Diabetic patients can have low plasma renin activity due to an acquired defect in the conversion of the precursor prorenin to active renin. |
| ■ How do distal and proximal RTAs differ from type IV RTA? | Distal (type I) RTA is characterized by decreased net H ⁺ secretion in the collecting ducts. Urine pH remains elevated in the presence of a metabolic acidosis, regardless of the degree of lowered serum HCO ₃ ⁻ . Consequently, urine cannot be lowered beyond a pH of 5.3. Serum potassium levels may be high or low.

In proximal (type II) RTA, the principal defect is in HCO ₃ reabsorption in the proximal tubule. It presents as a hyperchloremic, hypokalemic metabolic acidosis. Urine pH is normal initially, but falls below 5.3 once the serum has become acidic. |
| ■ What is the most appropriate treatment for this condition? | Type IV RTA usually does not require therapy as long as there is no extracellular volume contraction. Some patients, however, will require potassium-wasting diuretics such as furosemide. A few may need mineralocorticoid replacement therapy to correct the hyperkalemia. |

► **CASE 19**

A 30-year-old Caucasian woman with a history of hyperlipidemia presents for evaluation of persistent hypertension. She was diagnosed with high blood pressure 18 months ago and was started on metoprolol, which did not significantly lower her pressures. A few months later, hydrochlorothiazide was added to her regimen, also with limited results. One week ago, she was started on captopril. She denies any symptoms from her hypertension, including palpitations, episodes of unexpected sweating, and headaches. She has no family history of hypertension and does not use oral contraceptives. She has smoked one pack of cigarettes per day for the past 10 years, does not use alcohol, and lives a sedentary lifestyle but denies alcohol use. Today, on examination, her pulse is 80/min; blood pressure is 152/90 mm Hg and relatively equal in all extremities. She has a normal, healthy body habitus. Her heart, lung, and abdominal examinations are all within normal limits. Her thyroid stimulating hormone (TSH) level is 2.9. The results of her two most recent basic metabolic panels are as follows:

DATE	Na ⁺ (mEq/L)	K ⁺ (mEq/L)	Cl ⁻ (mEq/L)	HCO ₃ ⁻ (mmol/L)	CREATININE (mg/dL)	BUN (mg/dL)	GLUCOSE (mg/dL)
Today	138	4.1	105	24	1.6	33	102
One week ago	139	4.0	103	24	1.1	20	105

- **What is the most likely diagnosis?** This patient has several clues suggestive of secondary (i.e., nonessential) hypertension: hypertension refractory to three or more medications (including a diuretic), age of onset < 30, and no family history or other risk factors (e.g., obesity, alcohol abuse). Other features of secondary hypertension include proven age of onset before puberty and hypertension arising acutely in a person with previously stable blood pressures. In this setting, the acute rise in the patient's plasma creatinine after institution of therapy with an angiotensin converting enzyme inhibitor (ACEI) is suggestive of renal artery stenosis (RAS; also called renovascular hypertension). Angiotensin II preferentially constricts the efferent renal arterioles that, in the setting of RAS, maintain intraglomerular pressure and thus the glomerular filtration rate (GFR). By decreasing the levels of angiotensin II, ACE inhibitors eliminate efferent vasoconstriction and cause a decrease in the GFR. Additionally, although abdominal bruits are highly specific for RAS, they are not very sensitive screening tools for this condition, so the absence of bruits on auscultation does not rule out RAS (Table 16-4).
- **What is the most likely etiology of this condition in this patient's case?** The most likely underlying cause of RAS in a young woman is fibromuscular dysplasia, a disorder that affects both renal arteries and leads to a "string of beads appearance" on digital subtraction angiography.

■ **What is the most appropriate treatment for this condition?**

She should receive medications. ACEI may be beneficial in this disease and considered first line of therapy, as long as there is close monitoring of potassium and creatinine levels. A rise in serum creatinine of 0.5–1.0 mg/dL is acceptable after initiating therapy with ACEI, and is expected based on ACEI’s mode of action. A thiazide diuretic should be added if BP is still not decreased to goal levels to help control her blood pressure and hyperlipidemia. She should be encouraged to stop smoking and to exercise. If medical management fails, she should be evaluated for an operative intervention (e.g., percutaneous transluminal angioplasty with or without vascular stent placement).

TABLE 16-4. Major Causes of Secondary Hypertension

CONDITION	CLINICAL FEATURES
Renal artery stenosis	Acute rise in plasma creatinine after administration of ACE inhibitor or angiotensin II receptor blocker. Hypertension in a person with diffuse atherosclerosis or a single small kidney. Variable presence of abdominal bruit or bruits across other vascular beds.
Pheochromocytoma	Paroxysmal elevations in blood pressure. T achycardia, S weating, and H eadaches (See Endocrine Case 16, “TSH” = pheochromocytoma).
Primary hyperaldosteronism (Conn’s syndrome)	For exam purposes, patients with Conn’s syndrome will have hypokalemia due to renal potassium wasting (in reality, however, over half of Conn’s patients are normokalemic). Weakness, paralysis, and/or paresthesias.
Cushing’s syndrome	Moon facies, acne, suprclavicular fat pads, abdominal striae, and central obesity.
Coarctation of the aorta	Hypertension in both arms or just right arm (if left subclavian artery is distal to the coarctation) and low pressures in both legs with diminished femoral pulses.
Oral contraceptives (OCPs)	Hypertension whose onset temporally coincides with the start of OCP use.
Hypothyroidism	Symptomatic hypothyroidism or elevated serum thyroid-stimulating hormone.

► **CASE 20**

A 23-year-old man presents to his primary care physician with an enlarged right scrotum. He first noticed a “fullness” in his scrotum 2 months ago when he sprained his hamstring playing soccer in an outdoor league; he was reluctant to seek medical help until now because of embarrassment. He has no significant past medical history and denies pain in the area. On examination, the patient is somewhat anxious appearing but alert and oriented and in no apparent distress. His pulse is 60/min, blood pressure is 120/72 mm Hg, and respiratory rate is 12/min. His heart, lung, and abdominal exams are all within normal limits. The patient has a firm nontender mobile mass in his right scrotum that does not transilluminate. There is no palpable inguinal adenopathy. No abnormalities are found on rectal examination.

- **What is the most likely diagnosis?** A painless, nontransilluminating testicular mass in a man younger than 40 is testicular cancer until proven otherwise. Most other common causes of a testicular mass—including testicular torsion, epididymitis, and epididymoorchitis—tend to cause local pain. Hydroceles, varicoceles, and spermatoceles generally allow light penetration on transillumination. Testicular cancer is usually asymptomatic, but incidental injuries (e.g., sprained hamstring) may bring the scrotal mass to the patient’s attention.
- **What is the most appropriate next step in management?** See Figure 16-3.
 - Scrotal ultrasound: to confirm that the lesion is a solid mass.
 - Pending the results of the ultrasound:
 - Preoperative workup: including serum tumor markers (especially β -hCG and AFP) and a chest x-ray to look for metastatic disease.
 - Radical inguinal orchiectomy (RIO): both to obtain a histological diagnosis and to provide local tumor control. The procedure removes the involved testis, epididymis, and spermatic cord up the internal inguinal ring. Since the testicular lymphatics do not drain to the scrotum, RIO is performed via an inguinal incision to avoid inoculating the scrotum with cancerous cells.
- **How does the histologic diagnosis affect treatment?** Ninety percent of testicular cancers are derived from germ cells. The remainder are from stromal cells. Half are pure seminomatous germ cell tumors (SGCT) and the other half—which includes mixed tumors—are nonseminomatous (NSGCT). SGCT are exquisitely sensitive to radiation therapy, while NSGCT are not radiosensitive.

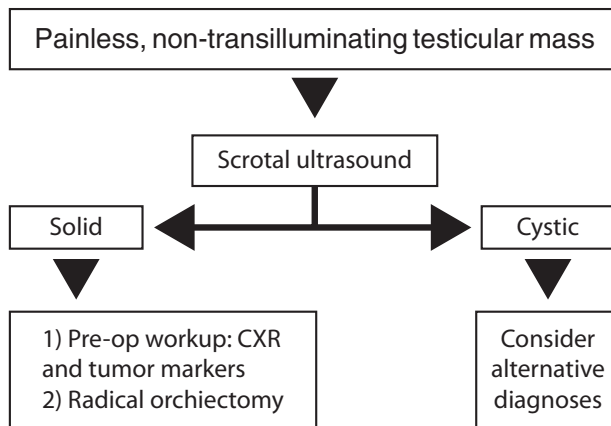


FIGURE 16-3. Algorithm for evaluation of a testicular mass.

► CASE 21

A 25-year-old man was the unrestrained driver of a motorcycle involved in a high-speed collision with a tree. The paramedics noted him at the scene to have a pulse of 120/min, blood pressure of 96/56 mm Hg, respiratory rate of 14/min, and Glasgow Coma Scale (GCS) of 10. The paramedics placed two large-bore peripheral intravenous lines and administered 2 liters of intravenous fluids during transportation to the nearest level-one trauma center. His vital signs on arrival at the emergency department are temperature 36.5° C (97.7° F), pulse 110/min, blood pressure 90/70 mm Hg, respiratory rate 14/min, and GCS 10. Multiple lacerations and abrasions are present on the face and upper and lower extremities. The heart, lung, and abdominal findings are all within normal limits. The bony pelvis is somewhat unstable and appears to have a fracture of the right pubic ramus. Marked scrotal swelling is noted. Peripheral pulses are present in all extremities. A digital rectal examination (DRE) reveals a high-riding prostate. As a nurse is about to insert the Foley catheter, she notes blood at the penile meatus.

<ul style="list-style-type: none"> ■ What is the most likely cause of the blood at the patient's penile meatus? 	<p>The presence of blood at the urethral meatus combined with the findings of scrotal swelling (and/or bruising) and a high-riding prostate on DRE are highly suggestive of traumatic urethral injury. This condition is commonly associated with pelvic fractures, occurring in 10–15% of cases. The posterior urethra is firmly attached to the pelvis by the puboprostatic ligaments, so displacement of the pelvis during a fracture often leads to tearing injuries.</p>
<ul style="list-style-type: none"> ■ What are the common mechanisms of this injury? 	<ul style="list-style-type: none"> ■ Blunt pelvic trauma. ■ Penetrating injury in the area of the urethra. ■ Straddle injuries. ■ Iatrogenic injury (traumatic catheterization, dilation, or transurethral procedures).
<ul style="list-style-type: none"> ■ What is the most appropriate next step in management? 	<p>A suspected diagnosis of traumatic urethral injury should be promptly confirmed with a retrograde urethrogram. Extravasation of contrast demonstrates the location of the tear. The urethrogram must be performed prior to insertion of a urethral catheter to avoid further injury to the urethra.</p>
<ul style="list-style-type: none"> ■ What are the long-term risks of this condition? 	<p>Incomplete or improper treatment frequently results in urethral stricture, leading to significant voiding problems long term. These patients also typically have associated orthopedic and neurologic injuries that must be addressed.</p>

Selected Topics in Emergency Medicine

Case 1	494
Case 2	495
Case 3	496
Case 4	498
Case 5	500
Case 6	502
Case 7	503
Case 8	504
Case 9	505
Case 10	506
Case 11	508
Case 12	510
Case 13	512
Case 14	514
Case 15	515
Case 16	516
Case 17	517
Case 18	518
Case 19	519
Case 20	520
Case 21	522
Case 22	524

► **CASE 1**

A 14-year-old girl is brought to the emergency department by her father after several hours of nausea and vomiting. Her father reports that she has not been “acting like herself” for several months. She has been staying in her room and skipping school. Prior to coming to the hospital he found an empty bottle of acetaminophen on her dresser. Physical examination reveals a temperature of 37.0° C (98.6° F), a pulse of 94/min, and a blood pressure of 108/72 mm Hg. She is diaphoretic, pale, and actively vomiting. Her mucous membranes are dry and a fundoscopic examination is within normal limits. A urine pregnancy test is negative. Relevant laboratory findings include an aspartate aminotransferase (AST) of 54 U/L, alanine aminotransferase (ALT) of 42 U/L, and serum creatinine of 1.1 mg/dL.

- **What is the most likely diagnosis?** Acetaminophen overdose. Although acetaminophen is widely available and safe at therapeutic doses, it accounts for more overdoses and overdose deaths annually in the United States than any other medication. Approximately 50% of all overdoses are unintentional, mostly due to acetaminophen being an active ingredient in many over-the-counter cough and cold medications. Ingestion of large amounts of acetaminophen causes the accumulation of an intermediate metabolite, *N*-acetyl-*p*-benzoquinoneimine (NAPQI), which causes glutathione depletion and oxidative liver injury. Acute tubular necrosis may also occur.

 - **What are the signs and symptoms associated with condition?** Patients with untreated acetaminophen overdose progress through four clinical stages:
 - Stage I (0.5–24 hours): Diaphoresis, anorexia, malaise, nausea, and vomiting. Laboratory studies typically remain normal while acetaminophen levels rise.
 - Stage II (24–72 hours): Stage I symptoms resolve, but hepatic aminotransferases begin to rise. Later, the patient may experience right upper quadrant pain, elevated prothrombin time, and increased total bilirubin. Oliguria and renal failure may become evident.
 - Stage III (72–96 hours): Liver function abnormalities peak. Stage I symptoms reappear with jaundice, hepatic encephalopathy, acute renal failure, and a bleeding diathesis. Death is most common in this stage.
 - Stage IV (4 days–2 weeks): Liver function recovery is usually complete by 1 week but could be prolonged in severely ill patients.

 - **What is the most appropriate treatment for this condition?** The effectiveness of activated charcoal, which prevents the systemic absorption of acetaminophen, is questionable. However, *N*-acetylcysteine, a glutathione precursor, is indicated for acetaminophen overdose of unknown time and quantity as well as for acetaminophen plasma levels above the “possible hepatic toxicity” line of the Rumack-Matthew nomogram.

 - **What is the prognosis for patients with this condition?** The outcome of acetaminophen overdose is almost universally positive if *N*-acetylcysteine is administered in a timely fashion. However, acetaminophen is the most common cause of acute liver failure in the United States. If there is a delay in the initiation of *N*-acetylcysteine therapy, morbidity and mortality increases significantly, often requiring transplantation.
-

► CASE 2

A 2-year-old boy is brought to the emergency department after eating lunch. His mother reports that he just finished eating a peanut butter sandwich when he started becoming irritable, scratching at his throat, and crying. He then developed hives over his chest and arms and began having difficulty breathing. Physical examination reveals an oral temperature of 37.5° C (99.6° F), a pulse of 170/min, a respiratory rate of 30/min, and a blood pressure of 92/44 mm Hg. He appears flushed all over his body, diaphoretic, and fussy. Examination of the oropharynx suggests laryngeal edema and the respiratory examination reveals diffuse wheezing bilaterally. Urticaria is noted on the chest and upper and lower extremities.

- | | |
|---|---|
| ■ What is the most likely diagnosis? | Anaphylactic shock. Anaphylaxis is an immediate and potentially life-threatening systemic hypersensitivity reaction to a variety of external stimuli. Anaphylaxis produces a spectrum of symptoms involving the cutaneous, respiratory, cardiovascular, and gastrointestinal systems. Anaphylaxis results in more than 400 deaths annually in the United States. |
| ■ What is the pathogenesis of this condition? | Anaphylaxis is caused by the activation and release of mediators from mast cells and basophils in response to a specific trigger. The release of these mediators results in many physiologic changes including increased vascular permeability, vasodilatation, respiratory smooth muscle contraction, and mucus secretion. Possible triggers include: <ul style="list-style-type: none"> ■ Bee and wasp stings. ■ Blood products. ■ Food (especially seafood, milk, and nuts). ■ Medications (particularly β-lactam antibiotics, nonsteroidal anti-inflammatory agents, antineoplastic agents, and angiotensin-converting enzyme inhibitors). ■ Radiographic contrast media. |
| ■ What are the signs and symptoms of this condition? | Patients typically develop symptoms of anaphylaxis 5–60 minutes after allergen exposure. The manifestations of anaphylaxis vary widely, with the most frequent being urticaria and angioedema. Shortness of breath, wheezing, laryngeal edema, and a variety of gastrointestinal symptoms have also been reported. |
| ■ What is a serious complication of this condition? | Anaphylactic shock, present in approximately one-third of anaphylaxis cases, occurs when anaphylaxis progresses until perfusion is inadequate to maintain vital organ function. It is characterized by an increase in cardiac output with a concomitant decrease in the pulmonary capillary wedge pressure and peripheral vascular resistance. These changes manifest clinically as tachycardia, hypotension, and syncope. |
| ■ What is the most appropriate treatment for this condition? | Airway, breathing, and circulation (ABCs) should dictate initial management: intubation for airway protection, assisted ventilation, and intravenous access with fluid resuscitation. Antihistamines, particularly H ₁ -blockers, should be given to all patients with anaphylaxis. However, if symptoms are severe, intramuscular or intravenous epinephrine can be added to reverse hypotension and bronchospasm. Corticosteroids are also routinely administered. |
-

► **CASE 3**

A 19-year-old man is brought to the emergency department by his roommate. He has been experiencing abdominal pain of 6 hours' duration with loss of appetite and vomiting. He reports 9/10 pain "all over," greater on the right side; the pain is dull and is not improved or exacerbated by anything in particular. On physical examination, his temperature is 38.0° C (100.4° F), blood pressure is 120/70 mm Hg, pulse rate is 80/min, and respiratory rate is 10/min. His abdominal examination is notable for absent bowel sounds and severe tenderness on deep palpation in both the right and left lower quadrants. He is also tender on passive internal rotation of the right hip. WBC count is 14,000/mm³, and urinalysis shows few RBCs and few WBCs. CT scan of the abdomen is shown in Figure 17-1.

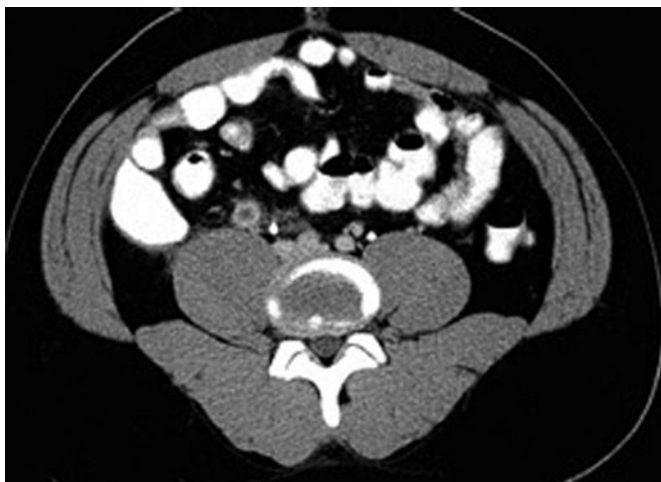

FIGURE 17-1. (Reproduced, with permission, from the Pathology Education Instructional Resource Digital Library [<http://peir.net>] at the University of Alabama, Birmingham.)

-
- **What is the most likely diagnosis?** Acute appendicitis. In the early stages, a patient presents with vague, generalized abdominal pain as visceral nerve fibers are irritated. It often progresses to a sharp, localized pain felt as the overlying parietal peritoneum (right lower quadrant) is irritated. Frank peritoneal signs (rebound tenderness or involuntary guarding) may also be present as somatic nerve fibers are involved. The patient's presentation, including the emesis, Rovsing's sign (tenderness in the right lower quadrant during palpation of the left lower quadrant), and the obturator sign (pain in the right lower quadrant on passive internal rotation of the hip) are consistent with this diagnosis. The median age at appendectomy is 22 years old, but a high index of suspicion should be held for all age groups.

 - **What is the pathogenesis of this condition?** The most common underlying event in appendicitis appears to be obstruction of the appendiceal lumen, followed by increased luminal and intramural pressures, ischemia, necrosis, bacterial overgrowth, and sometimes perforation and peritonitis. In younger patients, the initial obstruction is often caused by lymphoid follicular hyperplasia. In older patients, it is thought to be caused by neoplasia, fibrosis, or fecaliths.
-

■ **What conditions should be included in the differential diagnosis?**

- Meckel's diverticulum
- Inflammatory bowel disease
- Renal calculi
- Diverticular disease
- Constipation
- Gastroenteritis
- Urinary tract infection

■ **What are the typical laboratory findings in this condition?**

A large majority of adults with appendicitis have WBC count $>10,500$ cells/mm³ with neutrophilia $>75\%$. Pyuria >10 WBC and >3 RBCs per high-powered field on urinalysis is frequently seen and is consistent with bladder wall irritation from appendiceal inflammation.

■ **What are the typical imaging findings in this condition?**

CT scanning (most accurate) and ultrasonography are the imaging modalities of choice in suspected appendicitis. Appendicitis is suggested by a dilated appendix with a wall thickness >2 mm, a fecalith, a phlegmon, an abscess, free fluid, or fat stranding and/or right lower quadrant inflammation (see Figure 17-1).

■ **What is the most appropriate treatment for this condition?**

Surgical consult is necessary and the patient should be kept NPO with IV hydration for correction of electrolyte abnormalities and perioperative antibiotics. If perforation has occurred, treat with antibiotics until fever and abnormal WBC count resolve. If an abscess has formed, percutaneous drainage and broad-spectrum antibiotics are indicated, with an elective appendectomy performed in 6–8 weeks.

► **CASE 4**

A 4-year-old boy presents to the emergency department being carried by his mother. His mother reports that approximately 1 hour ago the child was “playing” with the family dog by pulling its tail and flicking its ears while it was eating. Consequently, the dog bit the child on the hand deep enough to draw blood. She decided to bring the child into the hospital because, despite her best efforts to alleviate his pain, her son continues to cry. His vital signs are normal, and on physical exam, he appears healthy yet extremely agitated and inconsolable. His right hand is erythematous and swollen about the proximal metacarpal phalangeal joints of the second, third, and fourth digits.

- | | |
|--|--|
| ■ What is the most likely diagnosis? | Animal bite. Bites from both animals and humans are associated with traumatic events and can have serious complications. Closed-fist injury, chomping to the finger, and puncture type around the head caused by a tooth can be very dangerous as they can introduce bacteria deep into tendons and fascial planes. See Table 17-1 for a comparison of different types of bites. |
| ■ What is the epidemiology of this condition? | Animal bites occur in an estimated 5 million Americans each year. They occur most frequently by dogs (85%), followed by cats (10%), and other animals such as rodents, ferrets, and rabbits (5%). Men are more likely to be bitten by dogs, while women are more likely to be bitten by cats. Bites are most common in the 5- to 24-year-old range, and approximately 20 people die annually. Human bites occur more frequently in men, but incidence is unknown, as most do not seek medical attention. |
| ■ What tests and/or imaging studies are could be used to confirm the diagnosis? | Lab studies are not necessary, as most injuries occur in a young, healthy population and the diagnosis of infection is clinical. (Culture of infections from animal bites can be collected, but infections resulting from animal and human bites are usually polymicrobial.) If a fracture or introduction of a foreign body (broken tooth) is suspected, a plain film is useful. |
| ■ What is the most appropriate treatment for this condition? | Assess airway, breathing, and circulation (ABCs), especially if the bite involves the head and neck area, followed by copious irrigation with normal saline under high pressure. Administer antibiotic coverage for staphylococci and anaerobes. Consider tetanus prophylaxis and rabies prophylaxis (in raccoons and unfamiliar animals). Consider surgical debridement for complicated wounds and consult an orthopedic surgeon for injuries involving hands, bones, or joints. |
| ■ What are possible complications of this condition? | Complications include wound infection and cellulitis, septic arthritis, deformities, poor healing, sepsis, meningitis, and rabies. |
-

TABLE 17-1. Comparison of Human, Dog, and Cat Bites

	HUMAN	DOG	CAT
Common causes	Result of incident involving alcohol, domestic violence, or child abuse	Provoked: Antagonizing/hurting animal Nonprovoked: Approaching animal's young or while animal is eating, approaching animal with rabies, entering animal's territory	
Gender commonly affected	Men	Men	Women
Types of bites/possible complications	Crush/destruction of tissue, infection	Crush/destruction of deep tissue, infection	Puncture—infection in 50% of cases
Prognosis	Generally excellent	Generally good to excellent	

► **CASE 5**

A 17-year-old boy is carried into the emergency department by his friends after he caught on fire while attending his high-school pep rally. He was standing by the bonfire when there was a unanticipated eruption of flames that set both of his pant legs on fire. Physical examination reveals a temperature of 37.3° C (98.6° F), a pulse of 120/min, a weight of 75 kg (165 lb), and a blood pressure of 100/66 mm Hg. He is in severe distress and moaning in discomfort. He recoils in pain when his legs are touched. Blisters and black areas, some circumferential, encompass feet, legs, and thighs bilaterally.

■ What is the most likely diagnosis?	Second- and third-degree thermal burns.
■ How is this condition classified?	Burns are categorized by type: chemical, thermal, or radiation. Specifically, thermal burns are classified by the depth of tissue destruction and the percentage of total body surface area affected. <ul style="list-style-type: none">■ First-degree burn: Only the epidermis is involved. The area is painful and erythematous, but blisters are notably absent. Capillary refill is intact.■ Second-degree burn: The epidermis and superficial thickness of the dermis are involved. The area is painful and blisters are present.■ Third-degree burn: The epidermis, the full thickness of the dermis, and potentially deeper tissue are involved. The area is painless, white, and charred.
■ How is the total body surface area burned (BSA) calculated?	“The Rule of Nines” is a tool to estimate the percentage of total body surface area affected by a burn in an adult, determined 24–48 hours after the injury (see Figure 17-2). <ul style="list-style-type: none">■ Entire head and neck (front and back) = 9%.■ Entire chest and abdomen = 18%.■ Entire back = 18%.■ Each arm (front and back) = 9%.■ Each leg (front and back) = 18%.■ Each palm or perineum = 1%.
■ What is the appropriate treatment for this condition?	Rinsing with a copious volume of clean, warm water helps stop the burning process. Airway status should be assessed and secured, with special attention to patients with burns secondary to fire. Patients with large burns should receive lactated Ringer’s solution according to the Parkland formula: $(4 \text{ cm}^3 \text{ of crystalloid}) \times (\% \text{ BSA burn}) \times (\text{body weight in kilograms})$. Half of the total fluid requirement is given over the initial 8 hours after injury, and half given over the following 16 hours, adjusted to maintain at least 1 mL/kg/hr of urine output. Opioid analgesics may be required for pain control. Bandaging with topical silver sulfadiazine and mafenide may be used prophylactically to prevent superinfection.
■ What other symptoms are common in patients with this condition?	Patients may become hypovolemic and hypothermic, making fluid resuscitation and warming an integral component of treatment. With circumferential third-degree burns, the eschar may act as a tourniquet and impair perfusion as edema increases; an escharotomy may be necessary to relieve pressure within the extremity.
■ What complications may develop over time?	Shock, acute renal failure, and superinfection are common complications of severe burn injuries. Superinfection of the burn wounds is most frequently due to <i>Pseudomonas aeruginosa</i> .

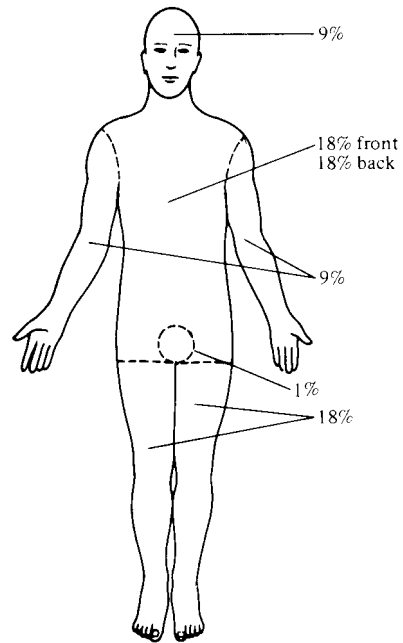


FIGURE 17-2. Rule of Nines to estimate percentage of burn. (Reproduced, with permission, from Tintinalli JE, Kelen GD, Stapczynski JS. *Tintinalli's Emergency Medicine: A Comprehensive Study Guide*, 6th ed. New York: McGraw-Hill, 2004: Fig. 199-1).

► **CASE 6**

A 57-year-old man comes to the emergency department because of palpitations. He reports that he was in his usual state of health until his daughter came for a visit yesterday. About 6 hours after she arrived, he states that he began to feel a bit shaky. His symptoms worsened overnight, and this morning he was so tremulous that he could barely sign his own name. He also began experiencing severe anxiety and the sensation that “my heart was jumping around in my chest.” He subsequently took a cab to the emergency department for evaluation. He adds, “My daughter probably thinks I’m with the boys at the bar, but I don’t drink a drop when she’s visiting.” Physical examination reveals an oral temperature of 37.5° C (99.6° F), an irregular pulse of 151/min, and a blood pressure of 132/78 mm Hg. He appears agitated and tremulous, with skin that is noticeably clammy. An electrocardiogram is consistent with atrial fibrillation. A blood alcohol test is negative.

- **What is the most likely diagnosis?** Atrial fibrillation secondary to alcohol withdrawal syndrome. The signs and symptoms of withdrawal typically begin within 12 hours of sobriety, although withdrawal can also occur as the result of a relative decrease in alcohol intake. Signs and symptoms vary depending on the time elapsed since the patient’s last drink but usually reach peak intensity after approximately 48 hours. Individual variation in the presentation of alcohol withdrawal syndrome reflects differences in alcohol intake, susceptibility to withdrawal symptoms, and comorbid medical conditions. It is more common in men than in women.

 - **What are the signs and symptoms of this condition?**
 - Mild withdrawal (presenting within 24 hours): mild autonomic hyperactivity including diaphoresis, anxiety, agitation, sinus tachycardia, atrial fibrillation, and GI upset.
 - Moderate withdrawal (presenting between 24 and 36 hours): intense anxiety, insomnia, and excessive adrenergic symptoms.
 - Severe alcohol withdrawal (presenting after 48 hours): disorientation, fever, seizures, and delirium tremens, characterized by confusion and visual hallucinations.

 - **What conditions should be included in the differential diagnosis?** The differential diagnosis of alcohol withdrawal syndrome must include conditions frequently associated with alcohol abuse. The seizures seen in severe alcohol withdrawal may also be secondary to head trauma sustained from alcohol-related injuries. The hallucinations associated with delirium tremens may be due to a psychiatric disorder or concomitant drug use.

 - **What tests and imaging tools could be used to confirm the diagnosis?** A toxicology screen is helpful in determining the patient’s blood alcohol concentration and what other drugs may be contributing to the patient’s symptoms. An electrocardiogram is indicated in patients with an abnormal cardiac examination. Head CT is indicated for patients with focal seizures or a history of head trauma with focal neurologic findings.

 - **What is the most appropriate treatment for this condition?** Patients are frequently volume depleted and hypoglycemic, requiring infusion with dextrose 50% in water. Concurrently, parenteral thiamine and magnesium sulfate should be administered. Thiamine deficiency is frequently seen in alcoholic populations and hypomagnesemia has been closely associated with tremors and seizures. The use of benzodiazepines, specifically lorazepam, is a validated treatment for alcohol withdrawal. Patients with moderate to severe withdrawal should be admitted for treatment and observation, particularly if their withdrawal is complicated by other medical conditions. Patients with mild withdrawal that responds to treatment may be referred for outpatient treatment of alcohol abuse.
-

► CASE 7

A 43-year-old man is brought to the emergency department by his wife after she found him in their winter cabin confused and dizzy. He drove up to the mountains the day before to prepare the cabin for their winter vacation. When she arrived, he was staggering around the cabin and complaining about a bad headache. His wife adds that he must have worked very hard to prepare the house because the cabin floors were swept and the old kerosene heater was working well. Physical examination reveals a temperature of 37.0° C (98.6° F), a pulse rate of 86/min, blood pressure of 126/82 mm Hg, and pulse oximetry of 99% on room air. He is not oriented to place or time and has a ruddy complexion. Significant laboratory findings include an arterial blood gas with a pH of 7.30, a PaCO₂ of 35 mm Hg, and a PaO₂ of 85 mm Hg.

-
- | | |
|--|---|
| <ul style="list-style-type: none"> ■ What is the most likely diagnosis? | <p>Carbon monoxide poisoning. Carbon monoxide is a colorless, odorless gas produced by hydrocarbon combustion. It binds to hemoglobin with greater affinity than oxygen and forms carboxyhemoglobin, which causes impaired oxygen transport and utilization. Carbon monoxide poisoning is a hypoxemic syndrome that is caused by overexposure to the gas through automobile exhaust, smoke inhalation, poorly functioning heating systems, and improperly vented fuel-burning devices.</p> |
| <ul style="list-style-type: none"> ■ What is the epidemiology of this condition? | <p>Carbon monoxide poisoning is responsible for up to 40,000 emergency department visits and over 5000 deaths annually. Accidental carbon monoxide poisoning is estimated to be responsible for approximately 10% of these deaths. Accidental poisoning demonstrates seasonal and regional variation and is most common in cold climates during the winter months.</p> |
| <ul style="list-style-type: none"> ■ What other symptoms are common in patients with this condition? | <p>Symptoms are highly variable. Mild carbon monoxide poisoning often presents with constitutional symptoms such as headache, malaise, nausea, and dizziness. Classically, the skin and lips may appear cherry red. Chronic low-level exposure to carbon monoxide may cause flulike symptoms with generalized myalgias. Severe carbon monoxide poisoning can cause seizures, syncope, coma, myocardial ischemia, ventricular arrhythmias, pulmonary edema, and profound lactic acidosis.</p> |
| <ul style="list-style-type: none"> ■ What are the typical laboratory findings in this condition? | <p>Carboxyhemoglobin analysis must be obtained from a venous or arterial blood gas, not pulse oximetry. The light sensors of the pulse oximeter erroneously interpret carboxyhemoglobin as regular hemoglobin, resulting in spuriously elevated oxygen saturation levels. Elevated blood levels of carboxyhemoglobin suggest carbon monoxide poisoning, but low levels do not rule out exposure. If significant time has elapsed since exposure or the patient receives 100% oxygen, carboxyhemoglobin levels may be falsely low. Chronic smokers may have persistently elevated carbon monoxide levels as high as 10%. Additionally, creatinine kinase–MB fraction or troponin may be elevated due to myocardial ischemia.</p> |
| <ul style="list-style-type: none"> ■ What is the most appropriate treatment for this condition? | <p>Patients should be removed from the carbon monoxide source and promptly started on 100% oxygen by nonrebreather face mask. Comatose patients or those with severely impaired mental status should be intubated and mechanically ventilated. Hyperbaric oxygen therapy is indicated for pregnant patients, patients with severely elevated carboxyhemoglobin, myocardial ischemia, or neurologic symptoms, including syncope, seizures, or coma. Hyperbaric oxygen therapy facilitates the displacement of carbon monoxide from hemoglobin.</p> |
-

► **CASE 8**

A 55-year-old man was walking through the hospital when he fell to the ground suddenly. It is confirmed at the scene that he is unresponsive, not breathing, and does not have a palpable heartbeat or pulse.

■ What is the most likely diagnosis?	Cardiac arrest (also known as sudden cardiac death). Cardiac arrest is defined as cessation of cardiac function, whether death occurs or not, and results in over 325,000 deaths per year. Placement of automated external defibrillators (AEDs) in the community and training of individuals has been a useful public health measure. The mechanisms of cardiac arrest include ventricular fibrillation (VF), pulseless ventricular tachycardia (pVT), pulseless electrical activity (PEA/electromechanical dissociation), and asystole (loss of all electrical activity).
■ What risk factors are associated with an increased incidence of this condition?	Men, coronary artery disease (CAD), family history of premature CAD, smoking, dyslipidemia, hypertension, diabetes, obesity, sedentary lifestyle, structural heart abnormalities (hypertrophic or dilated cardiomyopathy, valvular disease) atherosclerosis, heart failure, long QT syndrome, Wolff-Parkinson-White syndrome.
■ What is the most appropriate treatment for this patient?	A (airway), B (breathing) C (circulation) D (defibrillation) survey, then advanced cardiac life support (ACLS) protocol: <ul style="list-style-type: none">■ Secure airway with more invasive equipment, deliver 100% oxygen, obtain IV access, consider pacing, search for reversible causes.■ Follow specific ACLS protocol for pVT or VF, PEA, or asystole.■ Continue cardiopulmonary resuscitation (CPR) throughout, pausing only if necessary to intubate patient and to deliver shocks.■ Stabilization with medications appropriate to etiology and treatment for myocardial ischemia, heart failure, and electrolyte disturbances. Cardiology consultation and coronary angiography to assess status of CAD.
■ What tests and/or imaging tools may be used to confirm the diagnosis?	Cardiac enzymes, electrolytes (including calcium and magnesium), toxicology screen, thyroid-stimulating hormone, anti-arrhythmic drug levels (if applicable), electrocardiogram, chest x-ray.
■ What is a major adverse outcome of this condition?	Anoxic encephalopathy occurs in 30–80% of cases.
■ What is the prognosis for patients with this condition?	Upon emergency department presentation, the most important determinants of survival include the following: <ul style="list-style-type: none">■ Unsupported systolic blood pressure (SBP) > 90 mm Hg.■ Time from loss of consciousness to return of spontaneous circulation (ROSC) of < 25 minutes.■ Some degree of neurologic responsiveness. All cardiac arrest is associated with poor outcomes, especially out-of-hospital arrest; however, these outcome statistics (survival until hospital discharge) differ by etiology: <ul style="list-style-type: none">■ Asystole: 0–2%■ pVT: 60–70%■ PEA: 11%■ VF: 25–40%

► **CASE 9**

A 28-year-old woman is brought to the emergency department by her husband after she developed a high fever. She delivered a baby boy by cesarean section 5 days ago and then was discharged 3 days after delivery. Several hours ago, she began feeling flushed and her thermometer showed a fever of 38.2° C (100.8° F). Physical examination reveals an oral temperature of 38.7° C (101.7° F), a pulse of 105/min, and a blood pressure of 124/82 mm Hg. Abdominal examination is significant for a nontender abdomen with a normally healing cesarean section scar. Examination of the lower extremities reveals mild left lower-extremity edema with some pain on palpation without palpable cords.

■ What is the most likely diagnosis?	Deep venous thrombosis (DVT). A DVT is a common cause of postoperative fever 4–6 days after surgery. Risk factors for DVT include recent surgery, a history of immobilization, and pregnancy or postpartum status. Male to female ratio is 1:2.1.
■ What is the pathophysiology of this condition?	Virchow's triad (venous stasis, vessel wall injury, hypercoagulable state) is the primary mechanism for the development of venous thrombosis.
■ What are the possible causes of postop fever?	<p>The many causes of postoperative fever are best remembered as the "5 W's:"</p> <p>Wind (postoperative days 1–2): This is often the result of atelectasis. Reasons include ventilator support and shallow inspiration due to incisional pain.</p> <p>Water (postoperative days 3–5): Urinary tract infection (UTI). This is frequently secondary to urinary catheters used during and after surgery.</p> <p>Walking (postoperative days 4–6): Deep venous thrombosis can occur, most frequently in patients recovering from pelvic, orthopedic, or general surgery.</p> <p>Wounds (postoperative days 5–7): Wound infections or abscess formation must be considered.</p> <p>Wonder drugs (postoperative day 7+): Medications prescribed postoperatively may result in a febrile reaction.</p> <p>Of note, fevers prior to postoperative day 3 are unlikely to be infectious unless caused by <i>Clostridium difficile</i> or β-hemolytic streptococci.</p>
■ How can adverse events best be prevented postoperatively?	Early ambulation, prophylactic anticoagulation, and compression stockings can minimize the risk of DVT. Atelectasis is best prevented with incentive spirometry. The risk of UTIs can be minimized with short-term use of urinary catheters. Pre- and postoperative antibiotics can prevent wound infections.
■ What tests and/or imaging tools could be used to confirm the diagnosis?	DVT is most commonly diagnosed by duplex venous ultrasound. Atelectasis can be diagnosed by chest x-ray; UTI can be evaluated with urinalysis and urine culture. Potentially infected wounds should be carefully examined and cultured.
■ What is the most appropriate treatment for this condition?	Anticoagulation is the mainstay of therapy for DVT. After initial anticoagulation with heparin, long-term anticoagulation is usually maintained with warfarin. Mobilization of the limb is also encouraged.

► **CASE 10**

A 14-year-old boy arrives at the emergency department via ambulance accompanied by a neighbor who found him floating facedown in a nearby lake. The neighbor reports that he was jogging around the lake when he noticed an oddly shaped object floating out near the center of the water. He automatically jumped to save him. The neighbor reports that he seemed to “wake up” but has been acting funny since he was brought ashore. His vital signs include a temperature of 34.5° C (94.2° F), with a heart rate of 150/min, respiratory rate of 6/min, and pulse oximetry of 90%. On physical exam he appears cyanotic around the lips, withdraws to painful stimuli, uses inappropriate words and phrases, and opens his eyes to pain.

- | | |
|--|---|
| ■ What is the most likely diagnosis? | Drowning. Drowning results in primary respiratory impairment following submersion in a liquid medium, commonly water. A scenario depicting a motionless individual floating in water is more typical than the classic image of someone thrashing about. Deaths in the United States surpass 800 per year, with a bimodal distribution, with children < 4 years drowning in bathtubs and swimming pools, and adolescent/young adults 15–24 years old drowning in natural bodies of water. The male:female ratio is 12:1 for boat-related incidents and 4:1 for non-boat-related incidents. |
| ■ What is the pathophysiology of this condition? | After initial gasping and possible aspiration, immersion stimulates hyperventilation, voluntary apnea, and laryngospasm. Asphyxia leads to relaxation of the airway, and water may enter the lungs (“wet drowning”), or laryngospasm may continue until cardiac arrest (“dry drowning”). Water entering the lungs significantly impairs gas exchange, leading to hypoxia and metabolic acidosis with injury to body systems, particularly the heart and central nervous system (CNS). |
| ■ How is this condition classified? | <ul style="list-style-type: none">■ Asymptomatic.■ Symptomatic: altered vital signs, anxious, breathing abnormalities, metabolic acidosis, altered level of consciousness.■ Cardiac arrest: apnea, cardiac arrhythmias (asystole, ventricular tachycardia/fibrillation, bradycardia).■ Obviously dead: apnea, rigor mortis, dependent lividity, no CNS activity, normothermic with asystole. |
| ■ What is the Glasgow Coma Scale score for this patient? | Patients score on this scale depending on their motor response, verbal response, and eye opening. For this patient: withdrawal to pain = 4, uses inappropriate words and phrases = 3, eyes open to pain = 2. 4 + 3 + 2 = 9. |
| ■ What other conditions are associated with this condition? | Underlying conditions that may have contributed to the incident include: anxiety/panic disorder, major depression/suicide, poor neuromuscular control, diabetes, hypoglycemia, myocardial infarction, and seizure disorder. |
-

<ul style="list-style-type: none"> ■ What tests and/or imaging tools could be used to confirm the diagnosis? 	<p>Continuous pulse oximetry and electrocardiogram are necessary. Lab tests include an arterial blood gas (ABG), rapid glucose, complete blood count, electrolytes, lactate level, blood alcohol level, and toxicological studies. Chest x-ray should be ordered as well as head CT if suggested by history.</p>
<ul style="list-style-type: none"> ■ What are possible complications of this condition? 	<p>Complications include neurologic injury, pulmonary edema, acute respiratory distress syndrome, secondary pulmonary infection, multiple organ system failure, acute tubular necrosis, myoglobinuria, and/or hemoglobinuria.</p>
<ul style="list-style-type: none"> ■ What is the prognosis for patients with this condition? 	<p>Those who are alert or mildly obtunded at presentation have excellent chance for full recovery. If patients have received cardiopulmonary resuscitation and have fixed and dilated pupils or no spontaneous respiration, their prognosis is poor.</p>

► **CASE 11**

A 40-year-old man with no significant past medical history is brought to the emergency department by his wife, who reports that he has been drooling, vomiting, wheezing, and sweating uncontrollably for the past hour. He is an otherwise healthy man who takes no medication, denies allergies, and works as a tomato farmer. He appears somewhat lethargic and is having trouble speaking due to his shortness of breath. His wife reports that he was testing a new pesticide that morning. On physical examination, his temperature is 37.0° C (98.6° F), blood pressure is 100/70 mm Hg, pulse rate is 40/min, and respiratory rate is 6/min. His cardiac examination is notable for a regular but slow rhythm, and his skin is moist with sweat.

- | | |
|---|--|
| ■ What is the most likely diagnosis? | Acute organophosphate poisoning. Organophosphates are potent cholinesterase inhibitors that can cause severe toxicity after ingestion, inhalation, or cutaneous exposure. They have been used in both military and terrorist applications as well as medically to reverse neuromuscular blockade and treat glaucoma, myasthenia gravis, and Alzheimer's disease. Most toxicity results from exposure to pesticides (102,754 injuries in 2007). |
| ■ What symptoms are common in patients with this condition? | Signs and symptoms of cholinergic toxicity can be remembered by the mnemonic DUMBBELS :
Defecation/diarrhea
Urination
Miosis
Bronchospasm/Bronchorrhea/Bradycardia
Emesis
Lacrimation
Salivation

Additionally, muscle weakness, fasciculations, lethargy, respiratory depression, excitability, seizures, and coma may develop. |
| ■ How is this condition classified? | Three clinical stages (not all stages occur in each poisoning): <ul style="list-style-type: none">■ Acute toxicity: clinical syndrome described above.■ Intermediate syndrome (24–96 hours after exposure): neck flexion and weakness, decreased deep tendon reflexes, cranial nerve abnormalities, proximal muscle weakness, and respiratory insufficiency.■ Delayed neurotoxicity: transient, painful, stocking-glove paresthesias with symmetric flaccid motor polyneuropathy; associated with specific organophosphate agents. |
| ■ Administration of which medication can confirm this diagnosis? | If the diagnosis is in doubt, an atropine challenge may be used; anticholinergic signs and symptoms should not appear in patients with organophosphate poisoning. |
-

■ What are the typical laboratory findings in this condition?	The best index of the degree of poisoning, as well as the response to treatment, is the RBC acetylcholinesterase activity. If unavailable, measure plasma cholinesterase activity (which does not correlate as well with clinical severity).
■ What management is most appropriate for this condition?	Prevent contamination of hospital staff or other patients, remove affected clothing, wash skin with soap and water, endotracheal intubation, continuous electrocardiography, volume resuscitation, atropine titrated to the resolution of bronchoconstriction and respiratory secretions, pralidoxime given for nicotinic blockade, diazepam for seizure prophylaxis.

► **CASE 12**

A 63-year-old man presents to the clinic complaining of 4 days of “seeing spider webs” in his right eye. He senses clear-colored spidery patterns in his lower field of vision, only in his right eye. The sensation began upon awakening in the morning and has increased slightly over the past 4 days. He now feels that he has difficulty seeing the lower periphery with his right eye. In addition, he says his vision gets “darker” in that area after he is in a bright room. He denies headache, eye pain, eye discharge, or any other neurological symptoms. He denies recent eye trauma, although he did have a cataract removed 1 year ago. He is otherwise healthy, with no significant past medical history other than baseline myopia. On physical examination, his vital signs are within normal limits and he appears generally well. His head, eyes, ears, nose, and throat (HEENT) examination is remarkable for the use of corrective lenses and a slight lower hemispheric visual field defect in his right eye on visual field confrontation examination; otherwise, his exam is normal.

-
- **What is the most likely diagnosis?** Retinal detachment. Most “floaters,” which this patient describes as a “clear spider web,” are idiopathic vitreous floaters. However, a new floater followed by progressive loss of peripheral vision likely represents posterior vitreous detachment (PVD) followed by retinal detachment.

 - **How is this condition classified?** Retinal detachments are classified as rhegmatogenous (break in retina) or nonrhegmatogenous (leakage or exudation beneath retina or vitreous traction on retina). Rhegmatogenous detachments are the most common.

 - **What is the pathophysiology of this condition?** Rhegmatogenous detachments are usually a direct consequence of PVD. PVD results from liquefied vitreous breaking through the posterior vitreous face that causes the vitreous to detach. This process can put tension on vitreoretinal adhesions, which then leads to an actual retinal tear. Fluid can leak into the tear and force the neurosensory retina to separate from the underlying pigment epithelium and choroid. Nonrhegmatogenous retinal detachments tend to occur in patients with inflammatory conditions or retinal neovascularization from diabetes. Inflammatory conditions can lead to exudative fluid accumulation beneath the retina, causing detachment without tear. Neovascularization can cause strong vitreoretinal adhesions that lead to direct detachment. Direct trauma can cause both types, depending on whether the retina is torn or if a contracting fiber-optic transvitreal retinal band is formed after the trauma, leading to tractional detachment.

 - **What risk factors are associated with an increased incidence of this condition?** The most common risk factor is myopia, which increases risk 4- to 10-fold. Up to half of nontraumatic, nonsurgical retinal detachments may be attributed to myopia. Other risk factors include aphakia (cataract removal without lens placement), removal of a cataract complicated by loss of vitreous fluid, and lattice degeneration (focal thinning of the retinal periphery present in 6–8% of the general population).
-

■ **What is the most appropriate treatment for this condition?**

All patients with symptoms of PVD (e.g., floaters, photopsias, other visual disturbances) or retinal detachment (progressive loss of peripheral and eventually, central vision) should be urgently referred to an ophthalmologist for a dilated eye examination. Close observation by an ophthalmologist is appropriate only in patients with PVD who do not have a retinal tear. Laser photocoagulation and cryoretinopexy are first-line interventions in patients with symptomatic PVD with retinal tears. Patients who progress to retinal detachment can be treated with pneumatic retinopexy, scleral buckle, or vitrectomy. All patients should be counseled regarding their increased risk of involvement of the contralateral eye, and should be followed accordingly.

► **CASE 13**

A 28-year-old previously healthy female is brought to the emergency department by her boyfriend because of palpitations. Her boyfriend states that they had just left a bar when she began having a “fluttering” sensation in her chest. She quickly became short of breath and light-headed. Physical examination reveals an oral temperature of 37.0° C (98.6° F), a pulse rate of 193/min, a respiratory rate of 20/min, and a blood pressure of 96/46 mm Hg. Examination of the lungs is unremarkable, and a cardiac examination is significant only for tachycardia. Her electrocardiogram is shown in Figure 17-3.

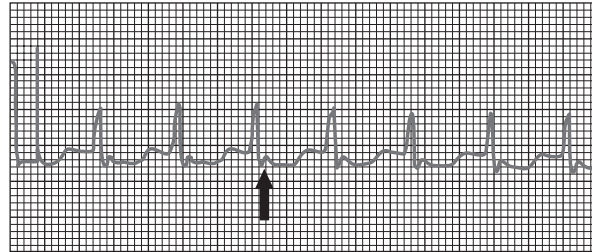


FIGURE 17-3. (Reproduced, with permission, from Kasper DL, Braunwald E, Fauci AS, Hauser SL, Longo DL, Jameson JL, Isselbacher J, et al. *Harrison's Principles of Internal Medicine*, 16th ed. New York: McGraw-Hill, 20054: Fig. 214-7).

■ What is the most likely diagnosis?	Paroxysmal supraventricular tachycardia (PSVT) refers to a number of tachyarrhythmias, the majority of which occur as a result of a reentrant mechanism. Atrioventricular nodal reentrant tachycardia (AVNRT) is the most common of these tachyarrhythmias, accounting for 50–60% of cases. Patients with this condition have a heart rate between 120 and 250/min and suffer from the sudden onset and termination of palpitations, hypotension, and syncope. Some patients may be asymptomatic. Precipitating factors include alcohol, caffeine, and sympathomimetic amines.
■ What is the epidemiology of this condition?	AVNRT commonly presents in the third or fourth decade of life in patients without underlying heart disease. Seventy percent of patients are women.
■ What is the pathogenesis of this condition?	In patients with AVNRT, the AV node is divided into two pathways with varying conduction speeds and refractory periods. The tachycardia is initiated when an appropriately timed atrial complex is blocked in one pathway and conducted down the other to the ventricles. As the impulse is conducted, the previously blocked pathway recovers so that the impulse can now be conducted up toward the atria. This sets up the reentrant circuit.
■ What tests and/or imaging tools could be used to confirm the diagnosis?	An electrocardiogram is invaluable in diagnosing PSVT or, in this case, AVNRT. Because the causative reentrant mechanism commonly occurs within the AV node itself, the atria and ventricles are stimulated simultaneously. The P waves are therefore difficult to visualize (see arrow in Figure 17-3) because they occur concurrently with the narrow QRS complexes.

■ **What is the most appropriate treatment for this condition?**

If the patient is hemodynamically stable, therapeutic intervention should begin with vagotonic maneuvers, such as the Valsalva maneuver or carotid sinus massage. These techniques enhance parasympathetic tone and can hasten arrhythmia termination. If these maneuvers are unsuccessful, intravenous adenosine is the treatment of choice. β -Blockers are considered to be second-line agents. Cardioversion is indicated only with severe hemodynamic compromise. Patients who require chronic therapy may benefit from radiofrequency catheter modification of the AV node.

► CASE 14

A 69-year-old woman with a history of acute myeloblastic leukemia who is currently receiving high-dose chemotherapy is brought to the emergency department because she is breathing rapidly and lapsing in and out of consciousness. Her nurse reports that she has been doing well with her chemotherapeutic regimen and has been maintaining her weight with minimally decreased appetite and little nausea or vomiting. She has no other significant medical, surgical, or developmental history other than the placement of a tunneled central venous infusion port 1 week ago into her left subclavian vein. On physical examination, she is diaphoretic and appears disoriented to person, place, and time. Her temperature is 40° C (104° F), blood pressure is 70/50 mm Hg, pulse rate is 140/min, and respiratory rate is 30/min. Examination of her head and neck is unremarkable, with no erythema, masses, or discharge noted, and there is no photophobia or neck stiffness. Otherwise, the exam is normal.

-
- | | |
|--|--|
| ■ What is the most likely diagnosis? | Severe sepsis, possibly septic shock. Although the clinical picture in this patient (delirium, tachypnea, fever, hypotension, tachycardia) is relatively nonspecific, her immunosuppression and the presence of a foreign body (infusion port) make infection more likely. |
| <hr/> | |
| ■ How is this condition classified? | The term <i>sepsis</i> is a clinical syndrome that lies on a spectrum of disease severity, as follows: <ul style="list-style-type: none">■ Infection: invasion of normally sterile host tissue by microorganisms.■ Bacteremia: presence of bacteria in the blood.■ Systemic inflammatory response syndrome (SIRS): two or more of the following: temperature > 38° C (100.4° F) or < 36° C (96.8° F); heart rate > 90/min; respiratory rate > 20/min or PaCO₂ < 32 mm Hg; WBC > 12,000/mm³, < 4000/mm³, or > 10% band forms.■ Sepsis: presence of SIRS and definitive evidence of infection.■ Severe sepsis: sepsis with organ dysfunction, hypotension, or hypoperfusion.■ Septic shock: sepsis and hypotension despite adequate fluid resuscitation, along with oliguria, change in mental status, or lactic acidosis (evidence of perfusion abnormalities). |
| <hr/> | |
| ■ What laboratory tests could be used to confirm the diagnosis? | Staining the buffy coat (white cells) with Gram stain or acridine orange is the best rapid test available to demonstrate bacteria that are causing sepsis. Blood culture, urinalysis, and urine culture are also helpful. |
| <hr/> | |
| ■ What is the most appropriate treatment for this condition? | Following stabilization of the airway, fluid resuscitation is crucial to normalizing blood pressure; vasopressors are often utilized to augment the weakened endogenous vascular tone. Invasive blood pressure monitoring (arterial line), central venous pressure monitoring (central venous catheter), continuous arterial pulse oximetry, and frequently arterial blood gas measurement and lactate levels are obtained. Identify the source of infection by culturing skin inoculation sites, catheters, urine, blood, sputum (if any), and stool. Internal fluid collections must be drained and cultured immediately. Patients with sepsis must be started on empiric, broad-spectrum antibiotics and switched to more specific coverage once the bug is identified. Stress-dose corticosteroids may be considered if the patient's condition is refractory to persistent fluid challenges and/or pressor support. |
-

► CASE 15

A 56-year-old woman presents to the emergency department following a syncopal episode. She was working in her garden and had just stood up from a flowerbed when she began feeling light-headed. She remembers her vision going gray before she lost consciousness and fell to the ground. She does not know how long she was out but was oriented when she awoke. She denies loss of bowel or bladder continence. On physical examination, she is alert, oriented, and interactive. Her vital signs include a temperature of 37.1° C (98.8° F), heart rate of 95/min, blood pressure of 113/68 mm Hg, and respiratory rate of 12/min. Her heart has a normal rate and regular rhythm without murmurs, rubs, or gallops. There are no abnormalities on neurological examination.

-
- | | |
|--|---|
| <ul style="list-style-type: none"> ■ What are the potentially life-threatening causes of this condition? | <p>There are several life-threatening conditions that must be ruled out in patients with syncope. These include cardiac syncope, blood loss, pulmonary embolism, and subarachnoid hemorrhage. Cardiac causes include arrhythmia, ischemia, and structural abnormalities (e.g., valvular disease, cardiac tamponade, atrial myxoma, or cardiomyopathy). Seizure, stroke, and head injury can also manifest as a syncopal episode. Patients with cardiac syncope have significantly increased risk for sudden death at short-term and 1-year follow-ups.</p> |
| <ul style="list-style-type: none"> ■ What are the benign causes of this condition? | <ul style="list-style-type: none"> ■ Neurocardiogenic ■ Micturition ■ Situational ■ Carotid sinus hypersensitivity ■ Orthostatic syncope ■ Volume loss ■ Autonomic dysfunction ■ Medication-related syncope |
| <ul style="list-style-type: none"> ■ What are important components of the history and physical exam? | <ul style="list-style-type: none"> ■ History: <ul style="list-style-type: none"> ■ Age: young patients are more likely to have neurocardiogenic syncope. ■ Associated symptoms: chest pain, palpitations, dyspnea, headache, etc. ■ Position: prolonged standing is likely neurocardiogenic; moving from lying to standing suggests orthostasis; syncope while lying is concerning for arrhythmia. ■ Onset: sudden onset suggests arrhythmia. ■ Exertional syncope: necessitates a cardiac workup. ■ Physical exam: <ul style="list-style-type: none"> ■ Vital signs. ■ Cardiac exam: might suggest structural causes or heart failure. ■ Lung exam: can suggest heart failure or other pathology. ■ Neurological exam: might suggest stroke. ■ Neck exam: check for carotid bruits, aortic stenosis, elevated jugular venous pressure. |
| <ul style="list-style-type: none"> ■ What should the workup of this patient include? | <p>While the patient's history and exam findings are most suggestive of orthostatic syncope, the clinician must rule out possible life-threatening etiologies. She should be placed on cardiac monitoring and an electrocardiogram should be obtained to evaluate for heart block, bradycardia, pre-excitation, prolonged QT intervals, or Q waves. In patients with altered mental status, glucose and electrolyte levels should be checked. A complete blood count may be useful if blood loss is suspected. Abnormal findings on neurologic exam necessitate brain imaging.</p> |
-

► **CASE 16**

A 14-year-old boy presents to the emergency department with groin pain. He was playing basketball until he felt a sudden shooting pain originating from the left side of his scrotum and radiating upward into his belly. The pain has been severe and unremitting and has caused him to vomit more than once. Physical examination reveals a nervous adolescent in moderate distress with a temperature of 37.0° C (98.6° F), a pulse of 120/min, and a blood pressure of 105/60 mm Hg. The left side of his scrotum is erythematous, edematous, and exquisitely tender to palpation, with loss of cremaster reflex on the ipsilateral side. There is no relief of pain upon elevation of his left testicle that is lying horizontally.

- | | |
|--|---|
| ■ What is the most likely diagnosis? | Testicular torsion. The testicle spins on the spermatic cord, which may result in venous occlusion, engorgement, and arterial ischemia, leading to infarction of the testicle. |
| ■ What conditions should be included in the differential diagnosis? | <ul style="list-style-type: none">■ Acute appendicitis■ Epididymitis■ Fournier gangrene■ Hernia■ Hydrocele■ Orchitis■ Scrotal and/or testicular trauma, with hematoma or rupture■ Spermatocele■ Testicular tumors: seminomatous, nonseminomatous■ Varicocele |
| ■ What tests and/or imaging tools could be used to confirm the diagnosis? | None. Testicular torsion is a clinical diagnosis and imaging studies are not necessary when history and physical exam strongly suggest this diagnosis. However, testicular ultrasound is often used for evaluation if the diagnosis remains questionable. |
| ■ What is the most appropriate treatment for this condition? | Manual detorsion (turning the testicle medial to lateral 180 degrees 2–3 times to relieve pain) and emergent urologic consultation for surgical detorsion and orchiopexy to avoid loss of testicular tissue. “Time is testicle.” Administer analgesia with caution as it may bias future physical exams. |
| ■ What are possible adverse outcomes of this condition? | Poor outcomes include infarction and loss of the testicle, infertility, infection, and cosmetic deformity. |
| ■ What risk factors are associated with an increased incidence of this condition? | Patients have an inappropriately high attachment of the tunica vaginalis that covers the testicle, called the bell clapper deformity. The testicle can rotate freely, so the long axis of the testicle may be oriented transversely rather than craniocaudal. Other suspected associations include having an undescended testicle, sexual arousal and/or activity, trauma, exercise, active cremaster reflex, and cold weather. |
-

► **CASE 17**

A 25-year-old man is brought to the emergency department by ambulance after a motor vehicle collision. The paramedics report that his vehicle, which was not equipped with airbags, hit a telephone pole at 35 mph. His temperature is 37.0° C (98.6° F), heart rate is 91/min, respiratory rate is 13/min, and blood pressure is 116/78 mm Hg. He is alert and oriented to person and place, but does not recall the date or any of the events leading up to the accident. He also reports that he feels very dizzy whenever he looks up at the ceiling. Examination of the head and neck reveals slight enophthalmos of the left orbit with infraorbital and upper lip anesthesia.

■ What is the most likely diagnosis?	Orbital fracture. Blowout fractures are the result of blunt trauma to the globe with rapid expansion of the orbital contents and rupture through the bony floor. A blowout fracture can also be the result of a direct blow to the orbital rim.
■ What is the epidemiology of this condition?	Facial fractures secondary to motor vehicle and recreational accidents are more common in rural areas, whereas penetrating trauma and assault-related injuries are more common in urban populations. Domestic violence and abuse should always be considered as a possible cause of the injury.
■ How is this condition classified?	Orbital fractures are classified in terms of anatomical considerations: <ul style="list-style-type: none"> ■ Internal orbital fracture: blow-out or blow-in fractures. ■ Orbital apex fracture: involving the orbital rim (superior, inferior, lateral). ■ Associated with other fractures of the facial skeleton.
■ What other symptoms are common in patients with this condition?	Diplopia on upward gaze suggests inferior rectus muscle entrapment but the etiology may be multifactorial. Infraorbital anesthesia is the result of a contused infraorbital nerve. Anesthesia of the maxillary teeth and upper lip is common. Rarely, patients demonstrate enophthalmos, or a sunken globe, when a large section of the globe has ruptured. Occasionally, a stepoff deformity can be palpated over the infraorbital rim or subcutaneous emphysema results from fracture into a sinus or nasal antrum.
■ What tests and/or imaging tools could be used to confirm the diagnosis?	Plain films are useful in the diagnosis of blowout fractures. The “hanging teardrop” sign suggests orbital fat herniating into the maxillary sinus. Once a blowout fracture is suspected, CT scan of the face with coronal sections is the modality of choice and can be used to determine the surface area of the broken orbital floor.
■ What is the most appropriate treatment for this condition?	All orbital fractures may have repair delayed for 1–2 weeks; however, opinions regarding surgical repair vary among providers. Antibiotics against sinus pathogens are recommended for patients with subcutaneous emphysema.

► **CASE 18**

A 72-year-old woman with a history of atrial fibrillation and gout is brought to the emergency department with severe pain throughout her abdomen. She was watching television when the pain began very suddenly and quickly became the worst pain she has ever experienced. She also reports having the sudden urge to defecate after the onset of the pain. She describes the pain as “knifelike,” and nothing improves or worsens the pain. She also denies radiation of the pain, chest pain, shortness of breath, blood in her stool, vomiting, or change in dietary habits. Her physical examination reveals a well-developed, well-nourished elderly woman writhing on the bed. She has a temperature of 37.5° C (99.5° F), blood pressure of 155/100 mm Hg, an irregular pulse rate of 90/min, a respiratory rate of 14/min, and an oxygen saturation of 98% on room air. Her physical examination is remarkable for an irregularly irregular heart rhythm, mild tenderness to palpation in the periumbilical region, and minimal bowel sounds, but no rebound, guarding, or flank tenderness. Her rectal exam is guaiac negative. Her pelvic examination is unremarkable.

■ What is the most likely diagnosis?	Acute mesenteric ischemia (AMI) occurs in patients over the age of 60. It has three possible etiologies: embolic (often a cardiac thrombus occluding the SMA), thrombotic (in settings of underlying atherosclerotic disease, a thrombus forms in two splanchnic vessels), and nonocclusive (severe and prolonged intestinal vasoconstriction in systemic illness and cardiac shock). Patients will typically present with pain out of proportion to their physical exam. Given this patient's active atrial fibrillation, AMI from a mesenteric artery embolus is the likely etiology.
■ What conditions should be included in the differential diagnosis?	<ul style="list-style-type: none">■ Aortic aneurysm rupture■ Intestinal obstruction■ Peritonitis■ Cholangitis■ Cholecystitis and biliary colic■ Appendicitis■ Pancreatitis
■ What risk factors are associated with an increased incidence of this condition?	<ul style="list-style-type: none">■ Advanced age■ Atherosclerosis■ Cardiac arrhythmias■ Intra-abdominal malignancy■ Low cardiac output states■ Recent myocardial infarction■ Severe cardiac valvular disease
■ What are the typical laboratory findings in this condition?	Patients with acute abdominal pain and metabolic acidosis have intestinal ischemia until proven otherwise. Lab findings frequently include leukocytosis, elevated hematocrit (hemoconcentration), and metabolic acidosis (ischemia). However, mesenteric ischemia may exist even in the presence of normal lab values.
■ What tests and/or imaging tools could be used to confirm the diagnosis?	CT scan is the diagnostic test of choice if suspicion of AMI is high. Angiography is the gold standard of diagnostic tests. Despite being highly invasive and not suitable for critically ill patients, it allows for treatment with thrombolytics at the site of occlusion.

► CASE 19

A 22-year-old woman is brought to the emergency department following a motor vehicle collision in which she was an unrestrained driver. Paramedics report she was driving a four-door sedan that was “T-boned” on the driver’s side. She denied any allergies or pertinent medical history before becoming unconscious at the scene. Physical exam at that time showed a mechanically unstable pelvic girdle and a systolic blood pressure of 80 mm Hg.

- | | |
|--|---|
| <p>■ What is the most likely diagnosis?</p> | <p>Mechanically and hemodynamically unstable pelvic fracture, specifically a lateral compression fracture as she was hit from the side. Hemorrhage is a common cause of death in patients with pelvic fractures, as up to 4 L of blood can accumulate in the retroperitoneal space before a self-limiting tamponade occurs.</p> |
| <p>■ What is the “primary survey”?</p> | <p>This primary survey helps to triage and manage acutely unstable patients. It can be remembered using the mnemonic ABCDE:</p> <p>Airway/Breathing (maintaining cervical spine precautions): Visualize and auscultate an adequate respiratory effort by the patient. Establish a patent and definitive airway and adequate oxygenation and ventilation.</p> <p>Circulation/Compression of bleeding wound: Place two large-bore peripheral IVs and use 3:1 isotonic fluid resuscitation or 1:1 blood product resuscitation for blood loss; monitor blood pressure frequently, and compress bleeding wounds.</p> <p>Disability: Assess neurologic status using the Glasgow Coma Scale (GCS).</p> <p>Exposure: Completely disrobe patient to assess for occult injuries and temperature status.</p> <p>Causes of immediate death can frequently be ruled out by this survey, including tension pneumothorax, cardiac tamponade, airway obstruction, aortic disruption, exsanguination, and hemothorax.</p> |
| <p>■ What is the “secondary survey”?</p> | <p>The secondary survey is undertaken after the patient is initially stabilized. It consists of a full physical examination, a “trauma series” (anteroposterior chest radiograph, anteroposterior pelvic radiograph, anteroposterior/lateral/odontoid radiograph of the cervical spine), placement of a Foley catheter (after ruling out urethral injury), and pertinent laboratory studies.</p> |
| <p>■ What is the most appropriate treatment for this condition?</p> | <p>Perform a focused abdominal sonography for trauma (FAST) exam to rule out intraperitoneal and intrapericardial hemorrhage. The pelvis must be mechanically stabilized in order to manage bleeding. Give analgesics and begin massive volume resuscitation with intravenous fluids (lactated Ringer’s solution, normal saline, and/or blood products) via large-bore peripheral IVs. Place a Foley catheter <i>only</i> when urethral damage has been ruled out by physical exam or retrograde urethrography. A CT scan should be done as soon as practical. Consult an orthopedic surgeon once the fracture is diagnosed. Continued blood loss is an indication for angiography and embolization of bleeding vessels, as open surgical exploration is fraught with morbidity and mortality in hemodynamically unstable patients.</p> |
-

► **CASE 20**

A 20-year-old man is brought to the emergency department by ambulance after being stabbed in the neck. The paramedics at the scene report that neither the assailant nor the weapon was present upon their arrival. Physical examination reveals an oral temperature of 37.0° C (98.6° F), a pulse of 115/min, a respiratory rate of 19/min, and a blood pressure of 106/64 mm Hg. He is able to speak without difficulty and is oriented to person, place, and time. The stab wound is horizontal and approximately 3 cm long on the left side of the neck below the angle of the mandible and above the inferior cricoid cartilage. Although it appears that the weapon penetrated the platysma muscle, the wound does not appear to be actively bleeding. No other injuries are noted.

- **What is the most likely diagnosis?** Penetrating neck trauma occurs when a missile or sharp object pierces the platysma. The two most immediate concerns are massive hemorrhage and airway compromise due to an expanding hematoma. Beyond these considerations, management is dictated by the cause of the injury, the patient's condition, and the anatomic location of the wound.

 - **How is this condition classified?** Penetrating neck wounds are described by their anatomic location, as shown in Figure 17-4:
 - Zone I: bordered by the suprasternal notch, clavicles, and inferior aspect of the cricoid cartilage.
 - Zone II: between the inferior cricoid cartilage and the angle of the mandible.
 - Zone III: between the angle of the mandible and the base of the skull.

 - **What is the most appropriate treatment for this condition?** Patients who are actively bleeding should be taken immediately to the operating room for surgical exploration. Stable patients with wounds that penetrate the platysma muscle are managed based on the function of the zone of the neck affected. There is *no* role for probing or local exploration of the neck in the emergency department, as this could dislodge a clot and initiate uncontrollable hemorrhage. All patients should undergo esophageal evaluations to rule out injury.
 - Zone I injuries: often associated with injury to the great vessels and require imaging to exclude major arterial injury. Angiography is considered to be the gold standard.
 - Zone II injuries: usually evaluated surgically. May image the vessels and nonvascular structures.
 - Zone III injuries: preoperative imaging of the injury is important as surgical exploration may be difficult.

This patient has suffered a penetrating injury to zone II. Since he is stable, the affected area can be imaged to determine whether surgery is warranted. If the penetrating instrument had remained in place, the wound would be imaged and the patient sent to surgery for removal and treatment. If the patient had suffered a bullet wound, imaging would be critical, as injury can result distant from the point of entry.
-

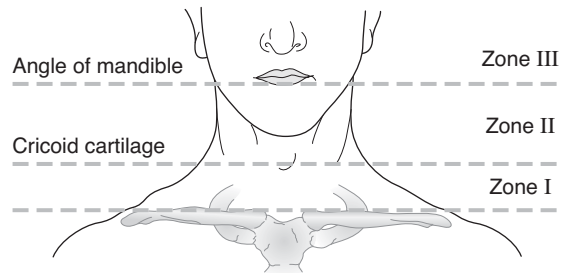


FIGURE 17-4. Zones of the neck. (Reproduced, with permission, from Stone CK, Humphries RL. *Current Emergency Diagnosis & Treatment*. New York: McGraw-Hill, 2004: Fig. 38-1).

► **CASE 21**

A 61-year-old man is brought to the emergency department by his daughter because of difficulty walking. His daughter reports that 2 days ago she noticed that his steps were very short and that he could not walk a distance of more than 5 feet without staggering. She assumed that her father's symptoms were the result of another drinking binge, but when they did not resolve with time, she decided to seek medical attention. Physical examination reveals an oral temperature of 37.0° C (98.6° F), a pulse rate of 84/min, and a blood pressure of 122/74 mm Hg. The patient appears distracted and is oriented to person only. Neurological examination reveals bilateral horizontal nystagmus on lateral gaze, diminished pain and vibratory sensation below the knee bilaterally, and a wide-based gait with slow, short-spaced steps. Blood alcohol concentration is 18 mg/dL. A cardiac examination is within normal limits.

-
- **What is the most likely diagnosis?** Wernicke's encephalopathy secondary to thiamine deficiency. Wernicke's encephalopathy is an acute neurologic disorder caused by thiamine deficiency and characterized by the classic triad of encephalopathy, oculomotor dysfunction, and gait ataxia. However, all 3 manifestations are found in only about one-third of cases. The majority of affected patients are alcoholics, with an incidence as high as 12.5%.

 - **What is the pathogenesis of this condition?** Thiamine deficiency in alcohol abusers results from a combination of inadequate dietary intake, reduced intestinal absorption, decreased hepatic storage, and impaired utilization. Wernicke's encephalopathy also occurs in nonalcoholic patients with malnutrition due to vomiting, starvation, bariatric surgery, dialysis, malignancy, and AIDS. The mechanism by which thiamine deficiency causes brain lesions is unclear.

 - **What other neurologic syndrome can this patient expect to develop over time?** Alcoholics with untreated or incompletely treated Wernicke's encephalopathy may develop Korsakoff syndrome, a neuropsychiatric disorder of selective anterograde and retrograde amnesia.

 - **What conditions should be included in the differential diagnosis?** All patients with gait disturbances should be evaluated for acute strokes and hemorrhages, particularly cerebellar hemorrhage and subdural hematomas. Additionally, thiamine deficiency can also result in adult dry beriberi (characterized by a symmetric peripheral sensory and motor neuropathy affecting the distal extremities) or wet beriberi (characterized by neuropathy with signs of cardiac involvement). Signs associated with wet beriberi include cardiomegaly, congestive heart failure, peripheral edema, and tachycardia.

 - **What tests and/or imaging tools could be used to confirm the diagnosis?** Wernicke's encephalopathy is a clinical diagnosis; there are no laboratory studies that are diagnostic. Thiamine deficiency can be detected by measurement of erythrocyte thiamine transketolase; however, such measurements are not necessary for diagnostic or treatment purposes. Diagnostic imaging is not necessary in all patients, but magnetic resonance imaging can be helpful in difficult cases.
-

- **What is the most appropriate treatment for this condition?**

In the acute setting, administration of both parenteral glucose solution and thiamine are recommended. Parenteral magnesium sulfate may be necessary also, as patients will not respond to thiamine in the setting of hypomagnesemia. High-dose oral thiamine supplementation should continue after parenteral treatment is complete.

- **What is the prognosis for patients with this condition?**

Improvement in ocular impairments should be seen within hours to days and improvement in ataxia and confusion within days to 1 week. Despite appropriate treatment, most patients are left with permanent symptoms of thiamine deficiency; only 20% fully recover.

► **CASE 22**

A 35-year-old man is brought by ambulance to the trauma bay of the emergency department. The paramedic team reports that he appears to have been shot in the abdomen and had an unknown amount of blood loss at the scene. No other history surrounding the incident is known. His initial trauma survey reveals a temperature of 37.5° C (99.5° F), blood pressure of 90/60 mm Hg, a pulse rate of 110/min, a respiratory rate of 18/min, and an oxygen saturation of 98% on room air.

■ What is the next step in management for this patient?	In all trauma patients, the primary survey is the first set of diagnostic and treatment steps that must be done (airway, breathing, circulation, disability, exposure). It is important to ensure ventilatory and hemodynamic stability immediately. This patient needs immediate fluid resuscitation with intravenous lactated Ringer's, normal saline solution, or colloid (packed red blood cells) through large-bore peripheral IVs.
■ What factor(s) determine the order of subsequent steps?	This patient will need an emergent exploratory laparotomy to thoroughly assess any organ damage. Imaging prior to surgery depends on patient stability; portable x-rays of the chest, abdomen, and pelvis may be taken before the laparotomy, if the patient is too unstable for the CT scanner.
■ What is "damage control" surgery?	"Damage control" surgery is management that identifies the most immediately life-threatening injuries and prioritizes their repair. In penetrating abdominal trauma, organs that have the largest surface area when viewed from the anterior aspect of the body tend to be injured most frequently (i.e., small bowel, liver, colon), and accompanying vascular injuries are much more common than in blunt trauma.
■ What system could be used to assess or classify this patient's health upon entering the intensive care unit?	Though there are several systems, the APACHE II system is probably the most widely used in the United States, and uses underlying health, chronic disease states, and physiological variables to calculate a predicted mortality risk for the first 24 hours of admission.
■ What adverse events are possible following surgery?	<ul style="list-style-type: none">■ Transfusion-related complications (hypothermia, coagulopathy, hypocalcemia, acute lung injury/acute respiratory distress syndrome, multiple organ failure).■ Contrast media-associated nephropathy.■ Deep venous thrombosis (DVT)/pulmonary embolus.■ Gastric stress ulcers.
■ What prophylactic measures should be used to prevent these adverse events?	<ul style="list-style-type: none">■ To prevent transfusion-related complications, warm blood adequately, closely monitor coagulation studies (as well as ionized calcium levels), and treat with calcium gluconate as indicated.■ To prevent contrast media-associated nephropathy, prehydrate patients for several hours with normal saline plus sodium bicarbonate. In patients with chronic renal failure, use nonionic contrast agent and prehydrate with normal saline and acetylcystine.■ To prevent DVT/pulmonary embolus, use subcutaneous heparin, pneumatic compression devices, and/or surveillance duplex ultrasound, depending on risk factors.■ To prevent gastric stress ulcers, use oral proton pump inhibitors in patients with nasogastric or orogastric tubes; otherwise, use intravenous H₂-blockers.

CASE INDEX

CASE TITLE	CHAPTER	PAGE
Abdominal Aortic Aneurysm	Cardiovascular	2
Abortion	Obstetrics	292
Abuse	Pediatrics	360
Acanthosis Nigricans	Dermatology	44
Acetaminophen Overdose	Selected Topics in Emergency Medicine	494
Achalasia	Gastrointestinal	134
Acid-Base Disorders	Renal/Genitourinary	460
Acne Vulgaris	Dermatology	46
Acromegaly	Endocrinology	72
Acute Cardiogenic Pulmonary Edema	Cardiovascular	3
Acute Cholecystitis	Gastrointestinal	130
Acute Coronary Syndrome	Cardiovascular	4
Acute Interstitial Nephritis	Renal/Genitourinary	461
Acute Kidney Injury	Renal/Genitourinary	462
Acute Lymphoblastic Leukemia	Hematology/Oncology	166
Acute Myelogenous Leukemia	Hematology/Oncology	164
Acute Myocardial Infarction — Long-Term Management	Cardiovascular	8
Acute Pancreatitis	Gastrointestinal	132
Acute Respiratory Distress Syndrome	Pulmonary	434
Acute Respiratory Failure	Pulmonary	436
Acute Tubular Injury	Renal/Genitourinary	464
Adrenal Insufficiency (Addison's Disease)	Endocrinology	76
Alcoholism	Psychiatry	404
Amenorrhea, Primary	Gynecology	328
Amenorrhea, Secondary	Gynecology	330
Amphetamine Intoxication	Psychiatry	402
Amyloidosis	Hematology/Oncology	167
Amyotrophic Lateral Sclerosis	Neurology	250
Anaphylactic Shock	Selected Topics in Emergency Medicine	495
Ankylosing Spondylitis	Musculoskeletal and Connective Tissue	220
Anorexia Nervosa	Psychiatry	405
Aortic Dissection	Cardiovascular	6
Aortic Regurgitation	Cardiovascular	9
Aortic Stenosis	Cardiovascular	21
Appendicitis, Acute	Selected Topics in Emergency Medicine	496
Asthma	Pulmonary	438
Atopic Dermatitis	Dermatology	47
Atrial Fibrillation	Cardiovascular	10
Atrial Fibrillation	Selected Topics in Emergency Medicine	502
Attention-Deficit/Hyperactivity Disorder	Psychiatry	406
Atypical Pneumonia	Pulmonary	440
Autism	Psychiatry	407
AZT-Induced Anemia	Infectious Disease	196

CASE TITLE	CHAPTER	PAGE
Bacterial Vaginosis	Gynecology	332
Basal Cell Carcinoma	Dermatology	48
Benign Positional Paroxysmal Vertigo	Neurology	254
Benign Prostatic Hyperplasia	Renal/Genitourinary	466
Bias and Confounding	Epidemiology and Preventive Medicine	102
Bioterrorism	Epidemiology and Preventive Medicine	104
Bipolar I	Psychiatry	423
Bites, Animal and Human	Selected Topics in Emergency Medicine	498
Breast Cancer	Gynecology	331
Breast Cancer Screening	Epidemiology and Preventive Medicine	106
Bulimia	Psychiatry	408
Bullous Pemphigoid	Dermatology	50
Burn, Thermal	Selected Topics in Emergency Medicine	500
Carbon Monoxide Poisoning	Selected Topics in Emergency Medicine	503
Carcinoid	Gastrointestinal	135
Cardiac Arrest	Selected Topics in Emergency Medicine	504
Cardiac Tamponade	Cardiovascular	12
Carpal Tunnel Syndrome	Musculoskeletal and Connective Tissue	222
Celiac Disease	Gastrointestinal	138
Cervical Cancer	Gynecology	334
Cervicitis	Gynecology	347
Chancroid	Gynecology	336
Chlamydia	Infectious Disease	197
Chronic Granulomatous Disease	Pediatrics	362
Chronic Kidney Disease	Renal/Genitourinary	468
Chronic Lymphocytic Leukemia	Hematology/Oncology	168
Chronic Obstructive Pulmonary Disease	Pulmonary	441
Cocaine Dependence	Psychiatry	410
Cohort Studies	Epidemiology and Preventive Medicine	108
Colorectal Cancer	Gastrointestinal	136
Compartment Syndrome	Musculoskeletal and Connective Tissue	223
Conduct Disorder	Psychiatry	412
Confidentially and Disclosure	Ethics and Legal Issues	124
Congenital Adrenal Hyperplasia	Pediatrics	364
Congenital Infections	Pediatrics	365
Congestive Heart Failure	Cardiovascular	14
Contraception	Obstetrics	293
Crohn's Disease	Pediatrics	366
Croup	Pediatrics	370
Cushing's Syndrome	Endocrinology	74
Deep Vein Thrombosis	Selected Topics in Emergency Medicine	505
Deep Venous Thrombosis	Cardiovascular	16
Deep Venous Thrombosis	Obstetrics	294
Delirium	Psychiatry	413
Dementia	Neurology	256
Dermatomyositis	Musculoskeletal and Connective Tissue	224
Developmental Dysplasia of the Hip	Pediatrics	368
Developmental Milestones	Pediatrics	371
Diabetes Insipidus	Endocrinology	77
Diabetes Mellitus, Type 1	Endocrinology	78
Diabetic Ketoacidosis	Endocrinology	79
Diastolic Heart Failure	Cardiovascular	20
Dilated Cardiomyopathy (Alcoholic)	Cardiovascular	18
Disseminated Intravascular Coagulation	Obstetrics	295

CASE TITLE	CHAPTER	PAGE
Dissociative Fugue	Psychiatry	414
Diverticulitis	Gastrointestinal	139
Domestic Violence	Psychiatry	415
Down Syndrome	Pediatrics	372
Drowning	Selected Topics in Emergency Medicine	506
Duchenne's Muscular Dystrophy	Musculoskeletal and Connective Tissue	225
Duodenal Atresia	Pediatrics	374
Ectopic Pregnancy	Obstetrics	296
Emphysema	Pulmonary	442
Endocarditis	Infectious Disease	200
End-of-Life Issues (Advance Directives and Withdrawal of Care)	Ethics and Legal Issues	125
Endometriosis	Gynecology	340
Epidural Abscess	Neurology	258
Epidural Hematoma	Neurology	260
Erectile Dysfunction	Renal/Genitourinary	470
Esophageal Carcinoma	Gastrointestinal	140
Factitious Disorder	Psychiatry	416
Factor V Leiden	Hematology/Oncology	170
Failure to Thrive	Pediatrics	376
Fanconi's Anemia	Hematology/Oncology	171
Febrile Seizure	Pediatrics	377
Fetal Monitoring	Obstetrics	298
Fibrocystic Breast Disease	Gynecology	338
Fibroids	Gynecology	342
Fibromyalgia	Musculoskeletal and Connective Tissue	229
Gastroesophageal Reflux Disease	Gastrointestinal	141
Generalized Anxiety Disorder	Psychiatry	417
Genital Warts	Gynecology	344
Gestational Diabetes	Obstetrics	300
Glaucoma	Neurology	262
Glioblastoma Multiforme	Neurology	264
Glomerulonephritis	Renal/Genitourinary	472
Glucose-6-Phosphate Dehydrogenase Deficiency	Hematology/Oncology	172
Gonococcal Infection	Infectious Disease	201
Gout	Musculoskeletal and Connective Tissue	228
Guillain-Barré Syndrome	Neurology	266
Hairy Cell Leukemia	Hematology/Oncology	174
Headache	Neurology	267
Health Care Screening	Epidemiology and Preventive Medicine	109
Hemochromatosis	Gastrointestinal	142
Hemophilia	Hematology/Oncology	175
Hemorrhage, Drug-Induced	Hematology/Oncology	178
Henoch-Schönlein Purpura	Pediatrics	378
Herniated Lumbar Disk	Musculoskeletal and Connective Tissue	226
Herpes Simplex	Dermatology	51
Hiatal Hernia	Gastrointestinal	144
Hidradenitis Suppurativa	Dermatology	52
Hirschsprung Disease	Pediatrics	380
Histoplasmosis	Infectious Disease	202
Hodgkin's Lymphoma	Hematology/Oncology	182
Huntington's Disease	Neurology	268

CASE TITLE	CHAPTER	PAGE
Hydatidiform Mole	Obstetrics	302
Hypercalcemia of Malignancy	Renal/Genitourinary	474
Hypercholesterolemia	Cardiovascular	22
Hyperkalemia	Renal/Genitourinary	476
Hypermnatremia	Renal/Genitourinary	478
Hyperosmolar Hyperglycemic State	Renal/Genitourinary	479
Hyperparathyroidism	Endocrinology	84
Hypertension	Obstetrics	303
Hypertension—Essential	Cardiovascular	23
Hypertension—Renal Artery Stenosis	Cardiovascular	24
Hyperthyroidism (Graves' Disease)	Endocrinology	80
Hypertrophic Obstructive Cardiomyopathy	Cardiovascular	26
Hypocalcemia	Renal/Genitourinary	480
Hypokalemia (Hyperaldosteronism)	Endocrinology	82
Hypothyroidism (Hashimoto's Thyroiditis)	Endocrinology	85
Idiopathic Pulmonary Fibrosis	Pulmonary	444
Idiopathic Thrombocytopenic Purpura	Hematology/Oncology	183
Incidence and Prevalence	Epidemiology and Preventive Medicine	110
Infantile Spasms	Neurology	269
Infectious Mononucleosis	Infectious Disease	204
Infective Endocarditis	Cardiovascular	30
Infertility	Obstetrics	304
Inflammatory Bowel Disease	Gastrointestinal	146
Influenza Vaccine	Epidemiology and Preventive Medicine	112
Informed Consent	Ethics and Legal Issues	126
Internuclear Ophthalmoplegia	Neurology	252
Intussusception	Pediatrics	382
Irritable Bowel Syndrome	Gastrointestinal	150
Isoimmunization	Obstetrics	305
Juvenile Rheumatic Arthritis	Musculoskeletal and Connective Tissue	230
Kaposi Sarcoma	Dermatology	53
Kawasaki Disease	Pediatrics	384
Legg-Calvé-Perthes Disease	Musculoskeletal and Connective Tissue	231
Lichen Planus	Dermatology	54
Liver Cirrhosis	Gastrointestinal	148
Lung Cancer	Pulmonary	443
Lyme Disease	Infectious Disease	206
Major Depression	Psychiatry	418
Malaria	Infectious Disease	208
Mastitis	Obstetrics	306
Melanoma	Dermatology	70
Meningitis	Neurology	270
Meningitis	Pediatrics	385
Menopause	Gynecology	345
Mesenteric Ischemia, Acute	Selected Topics in Emergency Medicine	518
Mesothelioma	Pulmonary	446
Metabolic syndrome	Endocrinology	88
Methicillin-Resistant <i>Staphylococcus aureus</i>	Infectious Disease	209
Microcytic Anemia	Hematology/Oncology	180
Minors	Ethics and Legal Issues	127
Mitral Regurgitation	Cardiovascular	28

CASE TITLE	CHAPTER	PAGE
Molluscum Contagiosum	Dermatology	56
Multiple Endocrine Neoplasia, Type I	Endocrinology	86
Multiple Endocrine Neoplasia, Type II	Endocrinology	89
Multiple Myeloma	Hematology/Oncology	184
Multiple Sclerosis	Neurology	272
Myasthenia Gravis	Neurology	275
Myocardial Infarction	Cardiovascular	32
Necrotizing Enterocolitis	Pediatrics	386
Necrotizing Fasciitis	Infectious Disease	210
Nephrolithiasis	Renal/Genitourinary	482
Nephrotic Syndrome	Renal/Genitourinary	483
Neutropenia	Hematology/Oncology	186
Neutropenic Fever	Infectious Disease	212
Normal Labor	Obstetrics	307
Normal Physiology of Pregnancy	Obstetrics	308
Nutrition in Pregnancy	Obstetrics	309
Obesity Effects on Health	Epidemiology and Preventive Medicine	114
Omphalocele	Pediatrics	387
Onychomycosis	Dermatology	69
Opioid Withdrawal	Psychiatry	422
Organophosphate Poisoning, Acute	Selected Topics in Emergency Medicine	508
Osteoarthritis	Musculoskeletal and Connective Tissue	234
Osteomyelitis	Infectious Disease	214
Osteoporosis	Endocrinology	90
Osteosarcoma	Musculoskeletal and Connective Tissue	238
Otitis Media	Pediatrics	388
Ovarian Cancer	Gynecology	346
Paget's Disease of Bone	Endocrinology	92
Papillary Muscle Rupture	Cardiovascular	34
Parkinson's Disease	Neurology	278
Partial Complex Seizures	Neurology	281
Pelvic Inflammatory Disease	Gynecology	348
Pemphigus	Dermatology	58
Peptic Ulcer Disease	Gastrointestinal	151
Pericarditis	Cardiovascular	36
Perineal Laceration	Obstetrics	312
Peripheral Vascular Disease	Cardiovascular	37
Personality Disorder, Cluster A	Psychiatry	420
Personality Disorder, Cluster B	Psychiatry	424
Personality Disorder, Cluster C	Psychiatry	425
Pheochromocytoma	Endocrinology	94
Physiologic Jaundice	Pediatrics	389
Pityriasis Rosea	Dermatology	60
Placenta Previa	Obstetrics	313
Placental Abruption	Obstetrics	310
Pleural Effusion	Pulmonary	448
Pneumocystosis	Infectious Disease	198
Pneumothorax	Pulmonary	450
Polycystic Kidney Disease	Renal/Genitourinary	484
Polycystic Ovarian Syndrome	Gynecology	350
Polycythemia	Hematology/Oncology	190
Polymyalgia Rheumatica	Musculoskeletal and Connective Tissue	240
Porphyria	Hematology/Oncology	191

CASE TITLE	CHAPTER	PAGE
Positive Predictive Value, and Negative Predictive Value	Epidemiology and Preventive Medicine	121
Postmenopausal Bleeding	Gynecology	351
Postpartum Hemorrhage	Obstetrics	316
Postpartum Infection	Obstetrics	314
Postterm Pregnancy	Obstetrics	318
Posttraumatic Stress Disorder	Psychiatry	428
Preeclampsia	Obstetrics	317
Prenatal Screening	Obstetrics	320
Preterm Labor	Obstetrics	321
Preterm Premature Rupture of Membranes	Obstetrics	322
Primary Sclerosing Cholangitis	Gastrointestinal	152
Primary Syphilis	Gynecology	352
Pseudomembranous Colitis	Gastrointestinal	153
Psoriasis	Dermatology	62
Pulmonary Embolus	Pulmonary	447
Pulmonary Hypertension	Pulmonary	452
Pyelonephritis	Obstetrics	323
Pyloric Stenosis	Pediatrics	390
Randomized Clinical Trial	Epidemiology and Preventive Medicine	116
Reliability and Validity	Epidemiology and Preventive Medicine	120
Renal Cell Carcinoma	Renal/Genitourinary	486
Renal Tubular Acidosis	Renal/Genitourinary	487
Renovascular Hypertension/ Secondary Hypertension	Renal/Genitourinary	488
Respiratory Distress in the Newborn	Pediatrics	391
Respiratory Syncytial Virus Infection	Pediatrics	392
Retinal Detachment	Selected Topics in Emergency Medicine	510
Rheumatoid Arthritis	Musculoskeletal and Connective Tissue	244
Rocky Mountain Spotted Fever	Infectious Disease	215
Sarcoidosis	Pulmonary	453
Schizophrenia	Psychiatry	426
Scleroderma	Musculoskeletal and Connective Tissue	245
Second-Degree Heart Block	Cardiovascular	38
Sensitivity and Specificity	Epidemiology and Preventive Medicine	118
Sepsis	Selected Topics in Emergency Medicine	514
Septic Arthritis	Infectious Disease	216
Sheehan's Syndrome	Obstetrics	326
Sickle Cell Anemia	Hematology/Oncology	176
Sleep Apnea	Pulmonary	458
Slipped Capital Femoral Epiphysis	Musculoskeletal and Connective Tissue	242
Small Bowel Obstruction	Gastrointestinal	154
Somatization Disorder	Psychiatry	429
Spinal Stenosis	Musculoskeletal and Connective Tissue	232
Spontaneous Bacterial Peritonitis	Gastrointestinal	156
Stevens-Johnson Syndrome	Dermatology	64
Stroke	Neurology	276
Subacute Combined Degeneration	Neurology	282
Subacute Granulomatous Thyroiditis (de Quervain's thyroiditis)	Endocrinology	100
Subarachnoid Hemorrhage	Neurology	284
Subdural Hematoma	Neurology	286
Suicidal Ideation	Psychiatry	432
Supraventricular Tachycardia	Selected Topics in Emergency Medicine	512

CASE TITLE	CHAPTER	PAGE
Syncope	Selected Topics in Emergency Medicine	515
Syndrome of Inappropriate Antidiuretic Hormone Secretion	Endocrinology	96
Systemic Lupus Erythematosus	Musculoskeletal and Connective Tissue	246
Tabes Dorsalis	Neurology	290
Takayasu Arteritis	Musculoskeletal and Connective Tissue	247
Tay-Sachs Disease	Pediatrics	393
Temporal Arteritis	Musculoskeletal and Connective Tissue	236
Testicular Cancer	Renal/Genitourinary	490
Testicular Torsion	Selected Topics in Emergency Medicine	516
Tetralogy of Fallot	Pediatrics	394
Thalassemia	Hematology/Oncology	192
Thrombophlebitis	Infectious Disease	217
Thrombotic Thrombocytopenic Purpura with Hemolytic Uremic Syndrome	Hematology/Oncology	188
Thyroid Nodule	Endocrinology	98
Tonic-Clonic Seizures	Neurology	288
TORCH Infections	Obstetrics	324
Tourette's Syndrome	Psychiatry	430
Toxic Shock Syndrome	Gynecology	353
Transplant Rejection	Hematology/Oncology	193
Trauma, Fracture, Orbital	Selected Topics in Emergency Medicine	517
Trauma, Fracture, Pelvis	Selected Topics in Emergency Medicine	519
Trauma, Penetrating, Abdomen	Selected Topics in Emergency Medicine	524
Trauma, Penetrating, Neck	Selected Topics in Emergency Medicine	520
Traumatic Urethral Injury	Renal/Genitourinary	491
Trichomonas	Gynecology	354
Tuberculosis	Pulmonary	454
Tuberous Sclerosis	Dermatology	68
Urinary Incontinence	Gynecology	356
Urinary Tract Infection	Infectious Disease	218
Varicella	Pediatrics	396
Varicella-Zoster Virus	Dermatology	66
Ventricular Septal Defect	Pediatrics	398
Viral Hepatitis	Gastrointestinal	157
Von Willebrand's Disease	Hematology/Oncology	194
Vulvovaginal Candidiasis	Gynecology	357
Wegener's Granulomatosis	Pulmonary	456
Wernicke's Encephalopathy	Selected Topics in Emergency Medicine	522
Wilms' Tumor	Pediatrics	399
Wilson's Disease	Gastrointestinal	160
Wolff-Parkinson-White Syndrome	Cardiovascular	40
Zollinger-Ellison Syndrome	Gastrointestinal	162

Index

A

- A-a gradient, 436
- Abdominal aortic aneurysm (AAA), 2
- Abnormal squamous cells of undetermined significance (ASCUS), 335
- Abortion, 292
- Acanthosis, 63
- Acanthosis nigricans (AN), 44–45
- ACE inhibitors, 8, 15, 19, 20, 23, 78, 488–489
- Acetaminophen overdose, 494
- Achalasia, 134
- Acid-base disorders, 460
- Acid reflux, in pregnancy, 308
- Acne vulgaris, 46
- Acromegaly, 72–73, 222
- Actinobacillus actinomycetemcomitans*, 214
- Acute appendicitis, 496–497
- Acute cardiogenic pulmonary edema, 3
- Acute coronary syndrome (ACS), 4–5
- Acute intermittent porphyria (AIP), 192
- Acute interstitial nephritis (AIN), 461
- Acute kidney injury (AKI), 462–463, 464
- Acute lymphoblastic leukemia (ALL), 166
- Acute mesenteric ischemia (AMI), 58
- Acute myelogenous leukemia (AML), 164–165
- Acute otitis media (AOM), 388
- Acute renal failure, 8, 34, 205, 466–467. *See also* Acute kidney injury
- postrenal (obstructive), 466–467
- Acute respiratory distress syndrome (ARDS), 434–435, 507
- Acute respiratory failure, 436–437
- Acute tubular injury (ATI), 464–465. *See also* Acute tubular necrosis
- distinguishing from prerenal disease, 465
- Acute tubular necrosis, 205, 461, 507. *See also* Acute tubular injury
- Addison's disease, 76
- Adenomatous polyposis (APC), 136
- Adrenal insufficiency, 76, 96
- Advance directive, 125
- Aggregatibacter aphrophilus*, 214
- AIDS, 53, 57
- Akathisia, 427
- Alagille syndrome, 395
- Alcohol withdrawal syndrome, 404, 502
- atrial fibrillation secondary to, 502
- Alcoholic cardiomyopathy, 18–19
- Alcoholism, 404
- Aldosterone deficiency, 76
- Aldosterone inhibitor, 8
- Allis's sign, 368
- α_1 -antitrypsin deficiency, 148, 441, 442
- α -blockers, 23
- α -fetoprotein (AFP), 320, 387
- α -thalassemia, 188–189
- Alzheimer's disease (AD), 252
- Amenorrhea
- primary, 328–329
- major causes of, 329
- secondary, 330
- Amniocentesis, 320
- Amnioinfusion, 299
- Amphetamine intoxication, 402–403
- Amyloidosis, 20, 167, 222, 483
- Amyotrophic lateral sclerosis (ALS), 250–25
- Anaphylactic shock, 495
- Anasarca, 483
- Androgen insensitivity, 328
- Anemia
- autoimmune hemolytic, 201
- AZT-induced, 196
- Fanconi's (FA), 171
- iron-deficiency, 178–179
- pregnancy-related, 309
- sickle cell, 16, 186–187
- Angina, unstable, 4, 5
- Angiofibromas, 68
- Angioplasty, 36
- percutaneous, 25
- Angiotensin receptor blockers, 15, 20
- Animal bite, 498
- Anion gap acidosis, 460
- Ankle-brachial index (ABI), 36
- Ankylosing spondylitis (AS), 220–221
- Anorexia nervosa, 405
- Anthrax, 104
- Anticentromere antibodies, 236
- Antidepressants, 265
- Antidiuretic hormone (ADH), 7
- Anti-double-stranded DNA (dsDNA), 241
- Antiepileptics, 265, 309
- during pregnancy, 309
- Anti-glomerular basement membrane (anti-GBM) antibody, 472, 473
- Antineutrophil cytoplasmic antibody (c-ANCA), 456, 472

- Antinuclear antibody (ANA), 236, 241, 472
- Antithrombin III deficiency, 16
- Antiplatelet therapy, 8
- Antiphospholipid antibody syndrome, 16
- Anti-Smith antibodies, 241
- Antitopoisomerase I (anti-scl-70), 236
- Aortic aneurysm, 6
- Aortic coarctation, 6, 24, 489
- Aortic dissection, 6–7, 34
- Aortic regurgitation, 9, 20, 352
- Aortic root aneurysms, 352
- Aortic stenosis (AS), 21, 33
- Aortic valve replacement, 6
- Aortoiliac occlusion (Leriche's syndrome), 36
- Aortitis, 352
- Aphakia, 510
- Appendicitis, acute, 496–497
- Areflexia, 263
- Argyll Robertson pupil, 290, 352
- Arthritis, 146, 367
 - gouty, 228
 - oligoarticular, 62
 - osteoarthritis, 114, 244
 - rheumatoid, 6, 222, 230, 234–235, 444, 449, 452
 - juvenile (JRA), 230
 - septic, 216, 498
- Asbestosis, 444
- Ascaris lumbricoides*, 382
- Asherman's syndrome, 330
- Asperger's disorder, 407
- Aspergillus* species, 209, 362
- Associations, 103
- Asthma, 438–439
 - classification, diagnosis, and management of, 439
- Atheroembolism, 8
- Atherosclerosis, 2, 25, 36, 504, 518
- Atopic dermatitis, 47
- Atrial fibrillation (AF), 10–11, 20, 37, 278, 502
 - ECG characteristic of, 10
 - secondary to alcohol withdrawal syndrome, 502
- Atrial septal defect, 395
- Atrioventricular block, second-degree (Mobitz type II), 38–39
- Atrioventricular nodal reentrant tachycardia, 512–513
- Atrioventricular reciprocating tachycardia (AVRT), 40–41
- Attention-deficit/hyperactivity disorder (ADHD), 406
- Atypical pneumonia, 440
- Autism, 407
- Autosomal dominant polycystic kidney disease (ADPKD), 484–485
- Autosomal recessive polycystic kidney disease (ARPKD), 485
- ## B
- Bacillus* species, 209
- Bacterial vaginosis (BV), 332–333
- Bacteroides* species, 323, 332, 348
- “Bamboo spine,” 221
- Barlow maneuver, 368
- Basal cell carcinoma, 48–49
- Becker's sign, 9
- Beck's sign, 12
- Beckwith-Wiedemann syndrome, 399
- Bell's palsy, 203
- Benign positional paroxysmal vertigo (BPPV), 269
- Beriberi, wet, 19
- β -blockers, 2, 5, 7, 8, 11, 19, 20, 23, 26, 31, 37, 38, 265
- Bias, 102, 108
- Bicuspid aortic valve, 6
- Bilevel positive airway pressure (BiPAP), 441
- Bilirubin, increased production of, 389
- Binge eating disorder, 405
- Bioterrorism, 104–105
- Bipolar disorder, 423
- Bites, human and animal, 498
 - comparison of human, dog, and cat bites, 499
- Blood pressure values, recommendations for, 109
- Body dysmorphic disorder, 416
- Body mass index (BMI), 114–115
- Boerhaave's syndrome, 408
- Borderline personality disorder, 42
- Borrelia burgdorferi*, 202–203
- Botulism, 104, 436
- Boutonnière deformities, 234
- Brain abscess, 214, 255
- Brain natriuretic peptide (BNP), 14, 15
- Breast cancer, 106–107, 331
- Breast-feeding, 294
 - jaundice associated with, 389
 - mastitis in, 306
- Bronchiolitis, 392
- Brucella*, 104
- Brudzinski's sign, 385
- Bulimia nervosa, 405, 408–409
- Bullous pemphigoid, 50
 - differentiation of pemphigus from, 59
- “Bull's-eye” rash, 202
- Burkholderia cepacia*, 362
- Burns, thermal, 500–501
- ## C
- Calcium channel blockers, 11, 20, 37, 38, 265
- Calymmatobacterium granulomatis*, 337
- Cameron's lesions, 145
- Campylobacter jejuni*, 263
- Cancer screening measures, recommended, 109
- Candida albicans*, 357, 362
- Candida* species, 209, 323, 357
- Candidiasis, vulvovaginal, 357
- Capital femoral epiphysis, 231, 242–243
 - avascular necrosis of, 231
 - slipped, 242–243
- Caput medusae, 148
- Carbon monoxide poisoning, 503
- Carcinoembryonic antigen (CEA), 136
- Carcinoid syndrome, 135
- Cardiac arrest, 504
- Cardiac catheterization, 6
- Cardiac fibrosis, 225
- Cardiac murmur, 32–33
 - major characteristics, 33
- Cardiac tamponade, 12–13, 35
- Cardiobacterium hominis*, 214
- Cardiomyopathy, 18–19, 26–27, 33, 225, 504
 - alcoholic, 18–19
 - dilated, 504

- hypertrophic obstructive (HOCM), 26–27, 33, 504
- Carditis, 203
- Carotid stenosis, 278
- Carpal tunnel syndrome (CTS), 72, 222
- Case-control study, 102–103, 108
- Cauda equina syndrome, 239
- Causal relationships, 103
- Cavernous venous thrombosis, 255
- Celiac disease, 138
- Cellulitis, 255, 498
- Cerebral atrophy, 267
- Cerebral hemorrhage, 214
- Cerebral infarction, “insular ribbon sign” in, 279, 280
- Cerebritis, 214
- Cervical carcinoma, 334–335
 - precancerous lesions, diagnostic screening of, 335
- Cervicitis, 347
- Chagas’ disease, 134
- Chancroid, 336–337
 - genital ulcerative lesions, differential diagnosis of, 337
- Chickenpox, 396
- Child abuse, 360–361
- Chlamydia trachomatis*, 197, 198, 199, 337, 347, 348
 - L1–L3, 337
- Chlamydia pneumoniae*, 197, 440
- Chlamydia psittaci*, 197
- Cholecystitis, acute, 130–131
 - cholecystectomy, 131
 - percutaneous cholecystotomy, 131
- Cholesterol levels, recommended, 109
- Chorioamnionitis, 322
- Choriocarcinoma, 302
- Chorionic villus sampling, 320
- Chorioretinitis, 362
- Chronic granulomatous disease (CGD), 362–363
- Chronic kidney disease, 468–469
- Chronic lymphocytic leukemia (CLL), 168–169
- Chronic obstructive pulmonary disease (COPD), 441, 442, 450
- Chylothorax, 449
- Cirrhosis, liver, 148–149, 485
- Civatte bodies, 55
- Claudication, 36, 238–239, 245
 - arm, 245
 - intermittent, 36
 - neurogenic, 238–239
- Closed-angle glaucoma, 258
- Clostridium difficile*, 146, 153, 505
- Clostridium perfringens*, 208
- Coagulation cascade, 295
- Coal miner’s disease, 444
- Cocaine dependence, 410–411
- Codman’s triangle, 233
- Cohort studies, 108
- Collagen vascular disease, 34
- Compartment syndrome, 223
- Colon cancer, 136–137
- Condoms, 293
- Conduct disorder, 41
- Condyloma acuminata (genital warts), 344
- Condyloma lata, 352
- Confidentiality, 124, 127
- Confounding, 102
- Congenital infections, 365
- Congenital adrenal hyperplasia (CAH), 364
- Congenital heart disease, 394
- Congestive heart failure (CHF), 14–15, 23, 29, 142, 449
 - guidelines for classification and treatment of, 15
 - stages of, 15
 - in transudative pleural effusion, 449
- Conjunctivitis, neonatal (ophthalmia neonatorum), 197
- Conn’s syndrome, 82, 489
- Consumptive coagulopathy, 295
- Continuous positive airway pressure (CPAP), 458
- Contraception, 293
- Conversion disorder, 416
- Coronary artery disease, 3, 20, 22, 25, 504
- Coronary artery bypass grafting, 6
- Cortisol deficiency, 76
- Corynebacterium jeikeium*, 209
- Couvellaire uterus, 310
- Coxsackievirus, 157
- Crack cocaine use, 6
- Cranial nerve palsies, 203
- CREST syndrome, 237
- Crohn’s disease (CD), 146–147, 366–367
- Croup (laryngotracheobronchitis), 370
- Cullen sign, 132
- Cushing’s disease, 22, 74, 75, 87
- Cushing’s syndrome, 24, 45, 74–75, 87, 364, 489
 - obesity and, 114
- Cushing’s triad, 256
- Cyclothymia, 423
- Cystic fibrosis, 376, 382, 450
- Cystitis, 218
- Cytomegalovirus (CMV), 157, 201, 325, 365
- ## D
- Dawn phenomenon, 78
- De Quervain’s thyroiditis, 100
- DeBaKey classification, 6
- Decision-making capacity, 126
- Deep venous thrombosis (DVT), 16–17, 170, 217, 294, 447, 505
 - thrombophlebitis due to, 217
- Dehydroepiandrosterone sulfate (DHEAS), 350
- Delirium, 413
- Delirium tremens (DTs), 404
- Dementia, 252–253, 266
 - frontotemporal (FTD), 251
- deMussset’s sign, 9
- Denys-Drash syndrome, 399
- Depression, major, 418–419
- Dermatitis, atopic, 47
- Dermatomyositis (DM), 224
- Developmental dysplasia of the hip (DDH), 368–369
- Developmental milestones, 371
- Dexamethasone challenge, 75
- Diabetes insipidus (DI), 77
- Diabetes mellitus, 20, 22, 36, 45, 72, 78, 114, 222, 278, 483, 487, 504
 - gestational, 300–301
 - pregestational, 301
 - type 1, 78
- Diabetic ketoacidosis (DKA), 79, 479
- Diastolic dysfunction, 3, 20

- DiGeorge syndrome, 395
 Digital rectal examination, 109
 Disease prevalence, 110
 Disseminated gonococcal infection (DGI), 198–199
 Disseminated intravascular coagulation (DIC), 295, 434
 Dissociative fugue, 414
 Diuretics, 20, 22, 37
 loop, 3, 482
 potassium-sparing, 83
 potassium-wasting, 487
 thiazide, 23, 96, 228, 482
 Diverticulitis, 139
 Dix-Hallpike maneuver, 269
 Domestic violence, 415, 517
 “Double bubble” sign, 374
 Down syndrome, 372–373, 375, 380
 Dressler’s syndrome, 34
 Drowning, 506–507
 DTaP (diphtheria/tetanus/pertussis) vaccine, 371
 Duchenne’s muscular dystrophy (DMD), 225
 Duke criteria, 28
 Duodenal atresia, 374–375
 Dupuytren’s contractures, 148
 Duroziez’s sign, 9
 Dyslipidemia, 22, 114, 278, 504
 Dysphagia, 134, 140
 Dystonia, acute, 427
- E**
- Early decelerations, 298
 Eating disorders, 405
 Ectopic pregnancy, 296–297, 349
 Eczema, 47
 Edrophonium test, 275
 Edwards’ syndrome (trisomy 18), 373, 387
 Ehlers-Danlos syndrome, 6
Eikenella corrodens, 214
 Electroconvulsive therapy (ECT), 418–419
 Emancipated minor, 127
 Emphysema, 441, 442, 452
 Empyema, 449
 Encephalitis, 214, 276
 Encephalopathy, anoxic, 504
 Enchondromatosis, 232
- End-of-life decisions, 125
 Endocarditis, infective (IE), 28–29, 214
 subacute, 214
 Endometrial hyperplasia, 351
 Endometriosis, 304, 340–341
 frequent sites of deposits in, 341
 Endometritis, 314–315
 Endoscopic retrograde cholangiopancreatography (ERCP), 131, 132
 End-stage renal disease (ESRD), 484
 Enterocolitis, 381
Enterococcus, 156
 Enzyme-linked immunosorbent assay (ELISA), 202
 Epidemiological classification, 113
 Epidural abscess, 254–255
 Epidural hematoma (EDH), 256–257
 Epiglottitis, 370
 Epilepsy, 289
 Episcleritis, 146
 Epistaxis, 190
 Epstein-Barr virus (EBV), 157, 176, 201
 Erectile dysfunction, 470–471
 Erythema migrans, 202
 Erythema multiforme, 65
 Erythema nodosum, 146, 367
Escherichia coli, 156, 191, 216, 218, 323, 348, 385
 Esophageal carcinoma, 140
 Esophageal rupture, 449
 Ethics and legal issues, 123–127
 advance directive, 125
 confidentiality, 124
 decision-making capacity, 126
 end-of-life decisions, 125
 euthanasia, 125
 life-sustaining interventions, 125
 palliative care, 125
 physician-assisted suicide (PAS), 125
 Euthanasia, 125
 Euvolemia, 96
- F**
- Factor V Leiden, 16, 170
 mutation, 170
- Factor VIII, 175, 194, 295
 Failure to thrive (FTT), 376
 Fanconi’s anemia (FA), 171
 Fasciotomy, 223
 Fecal occult blood test, 109
 Fetal monitoring, 298–299
 Fibrocystic breast disease, 338–339
 Fibromuscular dysplasia, 25
 Fibromyalgia, 229
 Fibrous dysplasia, 232
 Fifth disease, 397
 FIGO staging system, 334
 Fine-needle aspiration (FNA), 118–119, 338
 Fitz-Hugh–Curtis syndrome, 349
 Flexible sigmoidoscopy, 109
 Fluorescent treponemal antibody absorption test (FTA-ABS), 290, 352
 Focal segmental glomerulosclerosis (FSGS), 483
 Focused abdominal sonogram for trauma (FAST), 12
 Folic acid, 309
 Follicle-stimulating hormone (FSH), 328, 345, 350
 Frontotemporal dementia (FTD), 251
- G**
- Galeazzi’s sign, 368
 Gardner’s disease, 136
Gardnerella vaginalis, 323, 332
 Gaskin all-fours maneuver, 319
 Gastrinoma, 162
 Gastroesophageal reflux disease (GERD), 114, 141
 Gastrointestinal bleeding, in infants, 382
 Gastroschisis, 387
 Generalized anxiety disorder (GAD), 417
 Genital ulcerative lesions, differential diagnosis of, 337
 Genital warts (condyloma acuminata), 344
 Gerhard’s sign, 9
 Gestational diabetes, 300–301
 Giant cell arteritis, 6, 246
 Glasgow Coma Scale, 506

- Glaucoma, 258–259
 closed-angle, 258
 open-angle, 259
- Glioblastoma multiforme (GBM), 260–261
- Glioneural hamartomas, 68
- Glomerulonephritis (GN), 214, 456, 461, 462, 472–473
 pauci-immune, 473
 rapidly progressive, 472–473
 distinguishing feature of
 common causes of, 473
- Glucose-6-phosphate dehydrogenase (G6PD) deficiency, 172–173
- Gonioscopy, 258
- Gonococcal infection, disseminated (DGI), 198–199
- Goodpasture’s syndrome, 472
- Gottron’s papules, 224
- Gout, 114, 228
- Gouty arthritis, 228
- Gower’s sign, 225
- Granulocytopenia, 196
- Graves’ disease, 52, 80–81
 severe ophthalmopathy associated with, 81
- Grey Turner sign, 132
- Group B streptococci, 323, 385
- Growth hormone (GH), hypersecretion of, 72–73
- Guillain-Barré syndrome (GBS), 262–263, 436
- Gynecomastia, 443
- H**
- HACEK organisms, 214
- Haemophilus aphrophilus*, 214
- Haemophilus ducreyi*, 336
- Haemophilus influenzae*, 180, 254, 348, 385, 388
 type B vaccine, 271, 370
- HAIR-AN syndrome, 45
- Hairy cell leukemia, 174
- Hantavirus, 104
- Hashimoto’s thyroiditis, 52, 85
- Health care screening, 109
- Heinz bodies, 173
- Helicobacter pylori*, 151, 162
- HELLP syndrome, 317
- Hemochromatosis, 20, 142–143, 148
- Hemoglobin H disease, 188–189
- Hemoglobinuria, 507
- Hemolytic uremic syndrome, thrombotic thrombocytopenic purpura with (TTP-HUS), 191
- Hemophilia, 175
- Hemothorax, 449
- Henderson-Paterson bodies, 56, 57
- Henoch-Schönlein purpura (HSP), 378–379, 382
- Hepatic necrosis, fulminant, 201
- Hepatic failure, 72
- Hepatic primary sclerosing cholangitis, 367
- Hepatitis, viral, 55, 157–159
 clinical and laboratory features of, 158
 common serologic patterns in
 hepatitis B, 159
 hepatitis C, 55
- Hepatobiliary disease, 114
- Hereditary multiple exostoses, 232
- Hereditary nonpolyposis colon cancer (HNPCC), 136
- Herniated disk, 226–227
- Herpes simplex virus (HSV), 51, 157, 325, 347, 365
- Herpes zoster, 66–67
- Hiatal hernia, 144–145
- Hidradenitis suppurativa, 52
- High-grade squamous intraepithelial lesion (HSIL), 335
- Hill’s sign, 9
- Hirschsprung disease, 380–381
- Histoplasmosis, 200
- HIV, 53, 57, 201, 452
- Hodgkin’s lymphoma, 176–177, 475
- Hormone replacement therapy (HRT), 16, 345, 351
- Horner’s syndrome, 443
- Howell-Jolly bodies, 187
- Human herpesvirus 8, 53, 61, 397
- Human leukocyte antigen-B27 (HLA-B27), 220
- Human papillomavirus (HPV), 334, 344, 347
- Huntington’s disease, 266
- Hydatidiform mole, 30
- Hydronephrosis, 218, 466
- Hydrops fetalis, 305
- 21-Hydroxylase deficiency, 364
- Hyperaldosteronism, 24, 82–83, 489
- Hypercalcemia, 84, 132, 443, 453, 474–475
 cancer-associated mechanisms of, 475
 local osteolytic, 475
 of malignancy, 474–475
- Hypercarbia, 436–437
- Hypercholesterolemia, 22
- Hypercortisolism, 75
- Hyperglycemia, 79, 88, 479
 fasting, 88
 hyperosmolar hyperglycemic state (HHS), 479
- Hyperhomocysteinemia, 16
- Hyperkalemia, 76, 166, 462, 476–477, 487
 ECG manifestations of, 476, 477
- Hypernatremia, 478
- Hyperosmolar hyperglycemic state (HHS), 479
- Hyperparathyroidism, 84, 87, 90
 ectopic, 475
 primary, 84, 90, 475
- Hyperphosphatemia, 166, 462
- Hyperprolactinemia, 329
- Hypertension, 2, 3, 6, 20, 36, 109, 114, 245, 278, 468–469, 504
 poorly controlled, 468–469
 in pregnancy, 303
 primary (essential), 23
 renovascular, 83, 488–489
 secondary, 24, 488–489
 major causes of, 489
- Hyperthyroidism, 11, 80–81, 470
- Hypertriglyceridemia, 88, 132
- Hypertrophic obstructive cardiomyopathy (HOCM), 26–27, 33
- Hyperuricemia, 115, 166, 196, 462
- Hypoalbuminemia, 148, 480, 483
- Hypocalcemia, 166, 276, 480–481
- Hypochondriasis, 416

Hypofibrinogenemia, 295
Hypogammaglobulinemia, 483
Hypoglycemia, 276, 413
Hypokalemia, 19, 31, 82–83, 115
 electrocardiographic manifesta-
 tion of, 82
 weight loss and, 115
Hypomagnesemia, 19, 31
Hyponatremia, 76, 96–97, 215,
 276, 413
 euvolemic, 96
Hypotension, 8, 26, 76, 450, 462
Hypothalamic obesity, 114
Hypothermia, 11
Hypothesis testing, errors in, 116
Hypothyroidism, 22, 100, 222, 329,
 470, 489
Hypovolemia, 464
Hypoxemia, 3, 436
Hypsarrhythmia, 267

I

Idiopathic pulmonary fibrosis
 (IPF), 444–445
Idiopathic thrombocytopenic pur-
 pura (ITP), 182
Impotence. *See* Erectile dysfunction
Incidence, 110–111
 cumulative, 110
 rate, 111
Incontinence, urinary, 356
Infantile spasms (West syndrome),
 267
Infective endocarditis (IE), 28–29
Inflammatory bowel disease, 16,
 146–147
Influenza vaccine, 112–113
Informed consent, 116
Insulin resistance, 114
Insulin-like growth factor 1 (IGF-
 1), 72
Internuclear ophthalmoplegia
 (INO), 268
Inter-rater reliability, 119
Interstitial lung disease (ILD),
 444–445, 453
Intimate partner violence (IPV),
 415
Intrinsic factor, 282
Intussusception, 382–383
Iron-deficiency anemia, 178–179

Irritable bowel syndrome, 150
IUD (intrauterine device), 293, 355

J

Janeway lesions, 28, 214
Jaundice, breast-feeding, 389
Juvenile rheumatoid arthritis (JRA),
 230

K

Kallmann's syndrome, 328, 329
Kaposi sarcoma (KS), 53
Kawasaki disease, 84
Kayser-Fleischer rings, 160
Keratitis, 67
Kernicterus, 389
Kernig's sign, 270, 385
Ketonemia, 79
Kidney disease
 autosomal dominant polycystic
 (ADPKD), 484–485
 autosomal recessive polycystic
 (ARPKD), 485
 chronic, 23, 468–469, 484
Kingella kingae, 209, 214
Klebsiella pneumoniae, 156
Klinefelter's syndrome, 470
Korsakoff's syndrome, 404, 522
Kussmaul's sign, 12

L

Labor, normal, 307
Lactic acidosis, 196
Lambert-Eaton syndrome, 443
Laryngotracheobronchitis (croup),
 370
Legal issues. *See* Ethics and legal is-
 sues
Legg-Calvé-Perthes disease
 (LCPD), 231
Legionella pneumoniae, 440
Lentigo maligna, 70
Leptin deficiency, 114
Leriche's syndrome (aortoiliac oc-
 clusion), 36
Leukemia
 acute lymphoblastic (ALL), 166
 acute myelogenous (AML), 164–
 165

 chronic lymphocytic (CLL),
 168–169
 hairy cell, 174
Lewy bodies, 281
Lhermitte's phenomenon, 272
Li-Fraumeni syndrome, 232
Lichen planus, 54–55
Light's criteria, 449
Lipemia retinalis, 22
Listeria monocytogenes, 322
Liver, cirrhosis of, 148–149
Looser's lines, 480
Low-grade squamous intraepithe-
 lial lesion (LSIL), 335
Lumbar puncture (LP), 385
Lung cancer, 443
Luteinizing hormone (LH), 350
Lyme disease, 202–203
Lymphomas, vitamin D-secreting,
 475
Lynch II syndrome, 346

M

Magnesium deficiency, 480
Major depression, 418–419
Malabsorption, 283, 376, 480
Malaria, 204–205
Malingering, 416
Mammography, 106–107, 109
Marfan's syndrome, 6, 9
Mastitis, 306
Mayne's sign, 9
McDonald criteria for diagnosing
 multiple sclerosis, 273,
 274
McRoberts maneuver, 319
Meckel's diverticulum, 382
Meconium aspiration syndrome
 (MAS), 318–319
Melanoma, 70
Membranous nephropathy (MBN),
 483
Ménière's disease, 269
Meningitis, 67, 203, 214, 270–271,
 276, 385, 498
 bacterial, 270–271, 385
Menstruation, retrograde, 304
Mesothelioma, 446
Metabolic acidosis, 79, 468, 487,
 506
 anion gap, 468, 479

- Metabolic alkalosis, 390, 460
 hypochloremic, 390
- Metabolic syndrome, 88
- Methicillin-resistant *Staphylococcus aureus* (MRSA), 206–207, 208
- Microcephaly, 267
- Microscopic polyangiitis (MPA), 472
- Migraine with aura, 264–265
- Minimal change disease (MCD), 483
- Mitral prolapse, 33
- Mitral regurgitation (MR), 20, 33, 37
- Mitral stenosis, 33
- MMR (measles/mumps/rubella) vaccine, 324, 371
- Mobiluncus* species, 332
- Mohs' micrographic surgery, 49
- Molluscum contagiosum, 56–57
- Mononucleosis, infectious, 201
- Monro's microabscesses, 63
- Moraxella*, 254
- Moraxella catarrhalis*, 388
- Mueller's sign, 9
- Multiple endocrine neoplasia
 type 1 (MEN1), 86–87, 162
 type 2a (MEN2a), 89, 162
- Multiple myeloma (MM), 90, 180, 475
- Multiple sclerosis (MS), 268, 272–274
 McDonald criteria for diagnosing, 273, 274
- Munchausen's syndrome, 416
- Murphy's sign, 130
- Muscular dystrophy, Duchenne's (DMD), 225
- Myasthenia gravis (MG), 275, 436
- Mycobacterium tuberculosis*, 454
- Mycoplasma*, 348
- Mycoplasma hominis*, 332
- Mycoplasma pneumoniae*, 64, 440
- Myocardial infarction (MI), 4–5, 8, 23, 30–33, 34
 acute anterior wall, 30–31
 diagnosis and management of
 mechanical complications
 in, 31
 non-ST-elevation (NSTEMI),
 4–5, 8
 papillary muscle rupture follow-
 ing, 32
 ST-elevation (STEMI), 4–5, 8
- Myocardial ischemia, 4–5
- Myoglobin, 462
- Myoglobinuria, 507
- Myopia, 510
- N**
- Neck trauma, penetrating, 520–521
 zones of the neck, 521
- Necrotizing enterocolitis (NEC), 386
- Necrotizing fasciitis, 208
- Negative predictive value (NPV), 121
- Neisseria gonorrhoeae*, 197, 198–199, 216, 347, 348
- Neisseria meningitidis*, 270, 385
- Nephritis, acute interstitial (AIN), 461
- Nephroblastoma, 399
- Nephrolithiasis, 218, 482
- Nephropathy, radiocontrast, 8
- Nephrotic syndrome, 16, 22, 449, 483
- Neural tube defects, 309
- Neuroblastoma, 399
- Neurogenic claudication, 238–239
- Neutropenic fever, 183, 209
- Nikolsky's sign, 58, 59
- Nipah virus, 104
- Nocardia* species, 362
- Nonaccidental trauma, 360
- Non-small cell lung cancer (NSCLC), 443
- Nystagmus, 269
- O**
- Obesity, 114–115, 504
- Obsessive-compulsive disorder (OCD), 425, 430
- Obsessive-compulsive personality disorder (OCPD), 425
- Obstructive sleep apnea (OSA), 452, 458
- Omphalocele, 387
- Onychomycosis (OM), 69
- Open-angle glaucoma, 259
- Ophthalmia neonatorum, 197
- Ophthalmoplegia, 263, 268, 272
 internuclear (INO), 268, 272
- Opiate overdose, 436–437
- Opioid withdrawal, 422
- Optic neuritis, 272
- Oral contraceptives (OCPs), 489
- Orbital cellulitis, 255
- Orbital fracture, 517
- Organophosphate poisoning, acute, 508–509
- Ortolani maneuver, 368
- Osler's nodes, 28, 214
- Osteoarthritis, 114, 244
- Osteomalacia (vitamin D deficiency), 90–91, 480
- Osteomyelitis, 214
 acute, 210–211
 of the frontal bone (Pott's puffy tumor), 255
- Osteopenia, 90
- Osteoporosis, 90–91, 180
- Osteosarcoma, 232–233
- Otitis media, acute (AOM), 388
- Ovarian cancer, 346
- Oxytocin, 316
- P**
- Pacemaker, 39
- Paget's disease of bone, 91, 92–93, 232
 bone scan of, 93
 early and late radiographs of, 93
- Pain disorder, 416
- Palliative care, 125
- Pancreatitis, acute, 132–133, 460
 Ranson's criteria for predicting
 mortality risk in, 133
- PANDAS (pediatric autoimmune
 neuropsychiatric disorders
 associated with streptococ-
 cal infections), 430
- Panic attacks, 417
- Panton-Valentine leukocidin, 207
- Pap smear, 109, 334
- Papillary muscle rupture, 32
- Paraganglioma, 95
- Parainfluenza virus, 370
- Parakeratosis, 63
- Paramyxovirus, 397

- Parathyroid hormone (PTH), excess secretion of, 84
- Parathyroid hormone–related protein (PTHrP)–secreting tumors, 475
- Parkinsonism, 266, 281, 427
- Parkinson’s disease, 281
- Paroxysmal nocturnal hemoglobinuria, 16
- Paroxysmal supraventricular tachycardia (PSVT), 512–513
- Parvovirus B19, 397
- Patau’s syndrome (trisomy 13), 373
- Patent ductus arteriosus (PDA), 33
- Pavlik harness, 369
- Pelvic fracture, 519
- Pelvic inflammatory disease (PID), 348–349
- Pemphigus, 58–59
 - differentiation from bullous pemphigus, 59
- Penetrating abdominal trauma, 524
- Penetrating neck trauma, 520–521
- Peptic ulcer disease (PUD), 151, 162
- Peptostreptococcus*, 332
- Pericardiocentesis, 13, 34
- Pericarditis, 20, 34–35, 214
 - acute, 34–35
 - constrictive, 20
- Perimenopause, 345
- Perineal laceration, 312
- Perinuclear antineutrophil cytoplasmic antibody (p-ANCA), 456
- Peripheral vascular disease (PVD), 23, 25, 36, 470
- Peritonitis, spontaneous bacterial (SBP), 156
- Pervasive developmental disorders (PDDs), 407
- Peyronie’s disease, 470
- Phalen maneuver, 222
- Phenylketonuria (PKU), 267
- Pheochromocytoma (PCC), 24, 94–95, 489
- Phimosis, 470
- Physical abuse, 415, 517
- Physician-assisted suicide (PAS), 125
- Pituitary adenomas, 87
- Pituitary insufficiency, 326
- Pityriasis rosea, 60–61
- Placebo effect, 116
- Placenta previa, 311, 313
- Placental abruption, 310–311, 313
- Placental “migration,” 313
- Plasmodium* species, 204
- Pleural effusion, 448–449
- Pneumoconioses, 444
- Pneumocystis jiroveci*, 212
 - pneumonia (PCP), 212, 213, 450
 - ground-glass appearance on chest radiography in, 213
- Pneumocystosis, 212–213
- Pneumonia, 212, 213, 434, 440, 449
 - atypical, 440
 - community-acquired, 440
 - Pneumocystis jiroveci* (PCP), 212, 213, 450
 - usual interstitial (UIP), 445
- Pneumothorax, 450–451
- Pneumovax, 271
- Polycystic kidney disease, 77, 484–485
 - autosomal dominant (ADPKD), 484–485
 - autosomal recessive (ARPKD), 485
- Polycystic ovarian syndrome (PCOS), 330, 350, 351
 - obesity and, 114
- Polycythemia vera, 184–185
- Polymyalgia rheumatica (PMR), 247
- Porphyrias, 192
- Portal hypertension, 485
- Positive end-expiratory pressure (PEEP), 435
- Positive predictive value (PPV), 120
- Posterior vitreous detachment (PVD), 510
- Postherpetic neuralgia, 66, 67
- Postictal state, 288
- Postpartum hemorrhage, 316
- Postpartum infection, 314
- Postpartum pituitary necrosis (Sheehan’s syndrome), 326
- Post-thrombotic syndrome, 217
- Posttraumatic stress disorder (PTSD), 428
- Pott’s puffy tumor, 255
- Prader-Willi syndrome, 114
- Precordial auscultation, sites of, 32
- Predictive value, 121
- Preeclampsia-eclampsia, 317
- Pregnancy
 - ectopic, 296–297
 - normal physiology of, 308
 - nutrition in, 309
- Prenatal screening, 320
- Prerenal disease, 461, 464–465
 - distinguishing ATI from, 465
- Preseptal cellulitis, 255
- Preterm labor (PTL), 321
- Preterm premature rupture of membranes (PPROM), 322
- Preventative health measures, classification of, 113
- Primary sclerosing cholangitis (PSC), 152, 367
- Primary survey, 519, 524
- Prolactin, 350
- Prolactinoma, 470
- Propionibacterium acnes*, 46
- Prospective cohort study, 108
- Protein C and S deficiency, 16
- Proteus*, 323
- Proton pump inhibitors (PPIs), 141, 308
- Pseudomembranous colitis, 153
- Pseudomonas aeruginosa*, 209, 216, 500
- Psittacosis, 197
- Psoriasis, 62–63
- Pulmonary arterial hypertension (PAH), 452
- Pulmonary edema, 3, 14, 503, 507
 - acute cardiogenic, 3
- Pulmonary embolism (PE), 11, 217, 447, 449
- Pulmonary fibrosis, idiopathic (IPF), 444–445, 452
- Pulmonic stenosis, 33, 394
 - subvalvular, 394
- Pulsus paradoxus, 34
- Purified protein derivative (PPD), 455
- Pyelonephritis, 218, 321, 323
- Pyloric stenosis, 390
- Pyoderma gangrenosum, 146

Q

Quincke's pulses, 9

R

Rabies, 498
Radiocontrast nephropathy, 8
Ramsay Hunt syndrome, 67
Randomized clinical trial (RCT), 116–117
Ranson's criteria, 133
Rapid plasma reagin (RPR), 290, 352
Rapidly progressive glomerulonephritis (RPGN), 472–473
distinguishing features of common causes of, 473
Raynaud's phenomenon, 237, 245
Reed-Sternberg cells, 176–177
Refeeding syndrome, 405
Reliability, 120
Renal artery stenosis, 24–25, 489
Renal cell carcinoma (RCC), 486
Renal failure, 23, 72
acute, 8, 34
Renal infarction, 214
Renal insufficiency, 228
Renal tubular acidosis (RTA), 376, 487
Renovascular hypertension, 488–489
Reperfusion injury (RI), 8
Respiratory alkalosis, 447
Respiratory distress syndrome (RDS), 391
Respiratory failure, acute, 436–437
Respiratory syncytial virus, 370, 391
Retinal detachment, 510–511
Retinopathy, 23, 78
Retrospective cohort study, 108
Rett's disorder, 407
Reverse Woods screw, 319
Rhabdomyolysis, postictal, 462
Rhabdomyoma, cardiac, 68
Rheumatic fever, 34
Rheumatoid arthritis, 6, 222, 230, 234–235, 444, 449, 452
juvenile (JRA), 230
Richter's syndrome, 168
Ricin toxin, 104
Rickettsia rickettsii, 215

Right ventricular hypertrophy, 394
Robertsonian translocation, 372
Rocky Mountain spotted fever (RMSF), 215
Rosenbach's sign, 9
Roseola, 397
Rothmund-Thomson syndrome, 232
Roth's spots, 28, 214
Rotterdam criteria, 350
Rubella, 324, 325, 365, 397
congenital, 324, 325, 365
Rubeola, 397
Rubin II maneuver, 319
"Rule of Nines" to estimate percentage of burns, 500, 501

S

Salmonella, 210
Sandhoff disease, 393
Sarcoidosis, 20, 222, 453
Schizoaffective disorder, 426
Schizoid personality disorder, 420–421
Schizophrenia, 426–427
Schizophreniform disorder, 426
Schizotypal personality disorder, 420–421
Sclerodactyly, 237
Scleroderma, 236–237, 444, 452
Secondary survey, 519
Seizures, 214, 276–277, 377, 503
febrile, 377
generalized tonic-clonic (GTCS), 288–289
partial complex, 276–277
Sensitivity, 118–119
Sepsis, 434, 498, 514
Septic arthritis, 216, 498
Serratia marcescens, 362
Sexually transmitted infections, 323
Shagreen patch, 68
Sheehan's syndrome (postpartum pituitary necrosis), 326
Shigella, 191
Shingles, 66–67
Sickle cell anemia, 16, 186–187
osteomyelitis in, 210
Silicosis, 444
Sinusitis, 254–255, 456
chronic, 456
Sjögren's disease, 444
"Slapped cheek" rash, 397
Sleep apnea, obstructive (OSA), 452, 458
Slipped capital femoral epiphysis (SCFE), 242–243
Small bowel obstruction, 154–155
Small cell lung cancer (SCLC), 443
Smallpox, 104–105
Social phobia, 417
Somatization disorder, 416, 429
Somatoform disorders, 416
Specificity, 118–119
Spinal stenosis, 238–239
Splenic rupture, 201
Spontaneous bacterial peritonitis (SBP), 156
Stanford classification, 6
Staphylococcus species, 362
Staphylococcus aureus, 29, 209, 210, 211, 216, 218, 306, 353, 362
methicillin-resistant (MRSA), 206–207, 208
Staphylococcus epidermidis, 216
Statins, 8, 22
Steatohepatitis, nonalcoholic, 148
Stenotrophomonas species, 209
Stent, 8
bare metal (BMS), 8
drug-eluting (DES), 8
Stevens-Johnson syndrome (SJS), 64–65, 347
Streptococcus
group A β -hemolytic, 430
group B, 323, 385
Streptococcus pneumoniae, 156, 180, 210, 254, 270, 385, 388
meningitis caused by, 270, 385
Streptococcus viridans, 146, 214
Stroke, 23, 114, 278–280
acute ischemic, 278–280
brain stem, 268
embolic, 214
Subacute combined degeneration, 282–283

Subacute granulomatous thyroiditis (SGT), 100
 Subacute infective endocarditis, 214
 Subarachnoid hemorrhage (SAH), 284–285
 Subdural hematoma (SDH), 286–287
 Substance abuse, 426
 Subvalvular pulmonic stenosis, 394
 Sudden cardiac death (SCD), 26, 504
 Suicide, 432
 Swan-neck deformities, 234, 235
 Syncope, 26, 38, 40, 503, 515
 Syndrome of inappropriate antidiuretic hormone secretion (SIADH), 96–97
 Synovitis, 235
 Syphilis, 290, 325, 352, 365
 primary, 352
 secondary, 352
 tertiary, 290, 352
 Syphilitic aortitis, 6
 Systemic lupus erythematosus (SLE), 191, 198, 240–241, 452, 472, 473, 483
 Systolic dysfunction, 3

T

Tabes dorsalis, 290, 352
 Takayasu's arteritis, 6, 245
 Tarasoff rule, 124
 Tardive dyskinesia, 427
 Tay-Sachs disease, 393
 Telangiectasias, 237
 Temporal arteritis (TA), 6, 246
 Tenosynovitis, 198
 flexor, 222
 Tension pneumothorax, 450–451
 Test validity, 119
 Test-retest reliability, 119
 Testicular cancer, 490
 Testicular mass, algorithm for evaluation of, 490
 Testicular torsion, 516
 Tetralogy of Fallot (TOF), 394
 Therapeutic privilege, 124
 Thiamine deficiency, 19, 522
 Thalassemias, 188–189
 Thrombocytopenia, 215

Thrombolysis in Myocardial Infarction (TIMI) risk score, 5
 Thrombophilia, hereditary, 16
 Thrombophlebitis, 217
 Thrombotic thrombocytopenic purpura with hemolytic uremic syndrome (TTP-HUS), 191
 Thyroid nodule, 98–99
 Thyroid-stimulating hormone (TSH), 85, 98, 350
 Thyroiditis, subacute granulomatous (de Quervain's), 100
 Thyrotoxicosis, 11
 Thyroxine (T₄), 100
 Tinel sign, 222
 TORCH infections, 324, 325
 overview of, 325
 ToRCHeS infections, 365
 Tourette's disorder, 430–431
 Toxic epidermal necrolysis, 65
 Toxic megacolon, 153
 Toxic shock syndrome (TSS), 353
 Toxoplasmosis, 324, 325, 365
 Transesophageal echocardiography (TEE), 7, 28, 32, 214
 Transient ischemic attack (TIA), 23, 32
 Transient tachypnea of the newborn (TTN), 391
 Transjugular intrahepatic portosystemic shunt (TIPS), 149
 Transplant rejection, acute, 193
 Transthoracic echocardiography (TTE), 28, 214
 Traube's sign, 9
 Trauma, nonaccidental, 360
 Traumatic urethral injury, 491
Treponema pallidum, 337, 352
Trichomonas, 347
Trichomonas vaginalis, 323
Trichophyton rubrum, 69
 Tricuspid regurgitation, 33
 Tricuspid stenosis, 33
 Triiodothyronine (T₃), 100
 Trisomy 13 (Patau's syndrome), 373
 Trisomy 18 (Edwards' syndrome), 373, 387
 Trisomy 21, 372, 395
 Tuberculosis, 449, 454–455
 Tuberosus sclerosis (TS), 68, 267, 486

Turner's syndrome, 6, 328
 Tzanck smear, 67

U

Ulcerative colitis (UC), 146–147
 Ulnar deviation, 234, 235
 Unstable angina, 4, 5
 Urethral injury, traumatic, 491
 Urinary incontinence, 356
 Urinary tract infection (UTI), 218, 461, 484
 Usual interstitial pneumonia (UIP), 445
 Uterine atony, 316
 Uterine leiomyomata, 342–343
 Uterine rupture, 311
 Uveitis, 67, 146, 258, 367

V

Vaccinia immune globulin, 104
 Vaginal infections, 323
 Vaginitis, trichomonal, 354–355
 Vaginosis, bacterial (BV), 332–333
 Vanillylmandelic acid (VMA), elevated, 399
 Varicella, 396, 397
 Varicella-zoster virus (VZV), 66–67, 396, 397
 Vasa previa, 311
 Vascular claudication, 238
 Venereal Disease Research Laboratory (VDRL) test, 290, 352
 Ventilation/perfusion (V/Q) mismatch, 436, 447
 Ventricular arrhythmia, sustained, 8
 Ventricular fibrillation, nonsustained, 26
 Ventricular septal defect, 394, 398
 nonrestrictive, 398
 Vertigo, 269
 Viral exanthems, features of common, 397
 Virchow's triad, 217, 447, 505
 Viridans streptococci, 146, 214
 Vitamin A, 309
 Vitamin B₁₂ deficiency, 252, 282–283
 Vitamin D deficiency (osteomalacia), 90–91, 480

Vitamin D-secreting lymphomas, 475
Volume resuscitation, 13
Volvulus, 381
Von Hippel-Lindau syndrome, 486
von Willebrand factor (vWF), 175, 194
von Willebrand's disease (vWD), 194, 399
Vulvovaginal candidiasis, 357

W

WAGR syndrome, 399
Warfarin, subtherapeutic levels, 190

Wegener's granulomatosis, 456-457, 472
Weight loss, adverse events associated with, 115
Wermer's syndrome (MEN1), 86-87
Wernicke-Korsakoff syndrome, 404
Wernicke's encephalopathy, 404, 522-523
West syndrome, 267
Western blot, 202
Wilms' tumor, 399
Wilson's disease, 148, 160-161
Wolff-Parkinson-White (WPW) syndrome, 40-41, 504

Woods screw, 319
Wrist compression test, 222

X

Xanthelasma, 22
Xanthomas, 22
Xeroderma pigmentosum, 70

Z

Zidovudine, 196
Zollinger-Ellison syndrome, 86, 87, 151, 162



Tao Le, MD, MHS



Elizabeth Eby Halvorson, MD

Tao Le, MD, MHS

Tao has been a well-recognized figure in medical education for the past 15 years. As senior editor, he has led the expansion of *First Aid* into a global educational series. In addition, he is the founder of the *USMLERx* online test bank series as well as a co-founder of the *Underground Clinical Vignettes* series. As a medical student, he was editor-in-chief of the University of California, San Francisco *Synapse*, a university newspaper with a weekly circulation of 9000. Tao earned his medical degree from the University of California, San Francisco in 1996 and completed his residency training in internal medicine at Yale University and allergy and immunology fellowship training at Johns Hopkins University. At Yale, he was a regular guest lecturer on the USMLE review courses and an adviser to the Yale University School of Medicine curriculum committee. Tao subsequently went on to cofound Medsn and served as its chief medical officer. He is currently pursuing research in asthma education at the University of Louisville.

Elizabeth Eby Halvorson, MD

Elizabeth is a pediatrics intern at Wake Forest who plans to subspecialize in infectious disease, cardiology, or critical care. She worked on a previous *First Aid* project while in medical school at Vanderbilt. Outside of school, Elizabeth enjoys running marathons, cooking, and spending time with her pets. She is recently married to an orthopedic surgery resident.

ABOUT THE AUTHORS

usmle

From the Authors of **FIRST AID**[®]



STEP 2 CK Qmax

- ▶ **2600+** high yield Step 2 CK questions with detailed explanations

- ▶ Create highly custom tests

- ▶ Select questions by difficulty level

- ▶ Simulate a half-day or full-day exam

- ▶ Predictive of actual USMLE performance

- ▶ Pass guarantee – pass or we will double your subscription

www.usmlerx.com
Your Prescription for USMLE Success